BGD Lecture - Face and Ear Development

Introduction

 Face Development Movie	The face is the anatomical feature which is truly unique to each human, though the basis of its general development is identical for all humans and similar to that seem for other species. The face has a complex origin arising from a number of head structures and sensitive to a number of teratogens during critical periods of its development. The related structures of upper lip and palate significantly contribute to the majority of face abnormalities.

Head

The head and neck structures are more than just the face, and are derived from pharyngeal arches 1 - 6 with the face forming from arch 1 and 2 and the frontonasal prominence. Each arch contains similar Arch components derived from endoderm, mesoderm, neural crest and ectoderm.

Because the head contains many different structures also review notes on sensory, respiratory, Integumentary (tooth), endocrine (thyroid, parathyroid, pituitary, thymus) and cleft lip/cleft palate.

Hearing

We use the sense of balance and hearing to position ourselves in space, sense our surrounding environment, and to communicate. Importantly hearing is linked into postnatal neurological development (milestones) involved with language and learning.

Hearing development is generally divided into the 3 anatomical regions (inner ear, middle ear, outer ear) each having separate origins. The first structure observed is the otic placode, on the embryo head surface, that sinks into the mesenchyme to eventually form the inner ear.

2018 Lecture

Lecture Objectives

Lecture Archive [Expand]

To introduce the developmental embryology of both the face and ear, and their associated abnormalities.

1. To understand the formation and contribution of the pharyngeal arches to face and neck development.
2. To know the main structures derived from components of the pharyngeal arches (groove, pouch and arch connective tissue).
3. To know the 3 major parts (external, middle and inner) of hearing development and their embryonic origins.
4. To briefly understand some abnormalities associated with face and hearing development.

1 Minute Embryology
UNSW theBox

Textbooks [Expand]

Head Movies [Expand]

Week 3

Buccopharyngeal Membrane and Pharynx [Expand]

Buccopharyngeal Membrane

These images of the Week 4 embryo (23 - 26 days, Stage 11) show the

breakdown of the buccopharyngeal (oral) membrane.

- Low power ventral view of the Buccopharyngeal Membrane
- Higher power ventrolateral view of the Buccopharyngeal Membrane
- Close up view of the degenerating Buccopharyngeal Membrane
- Buccopharyngeal Membrane
- Buccal and Nasal Cavities

The Pharynx

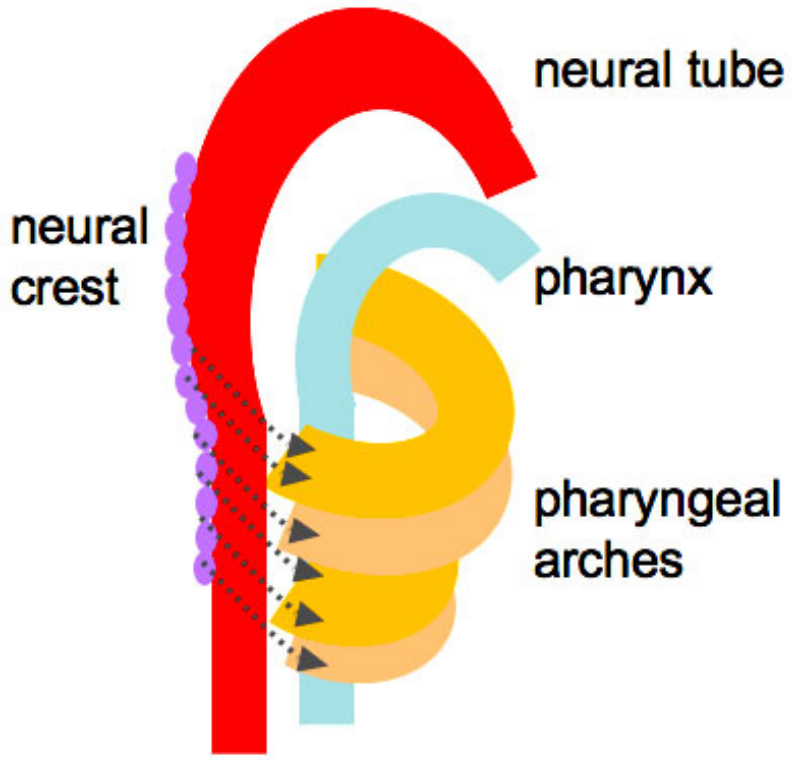

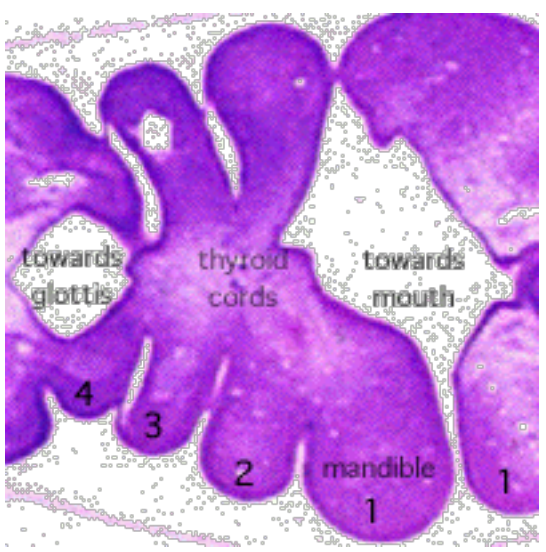

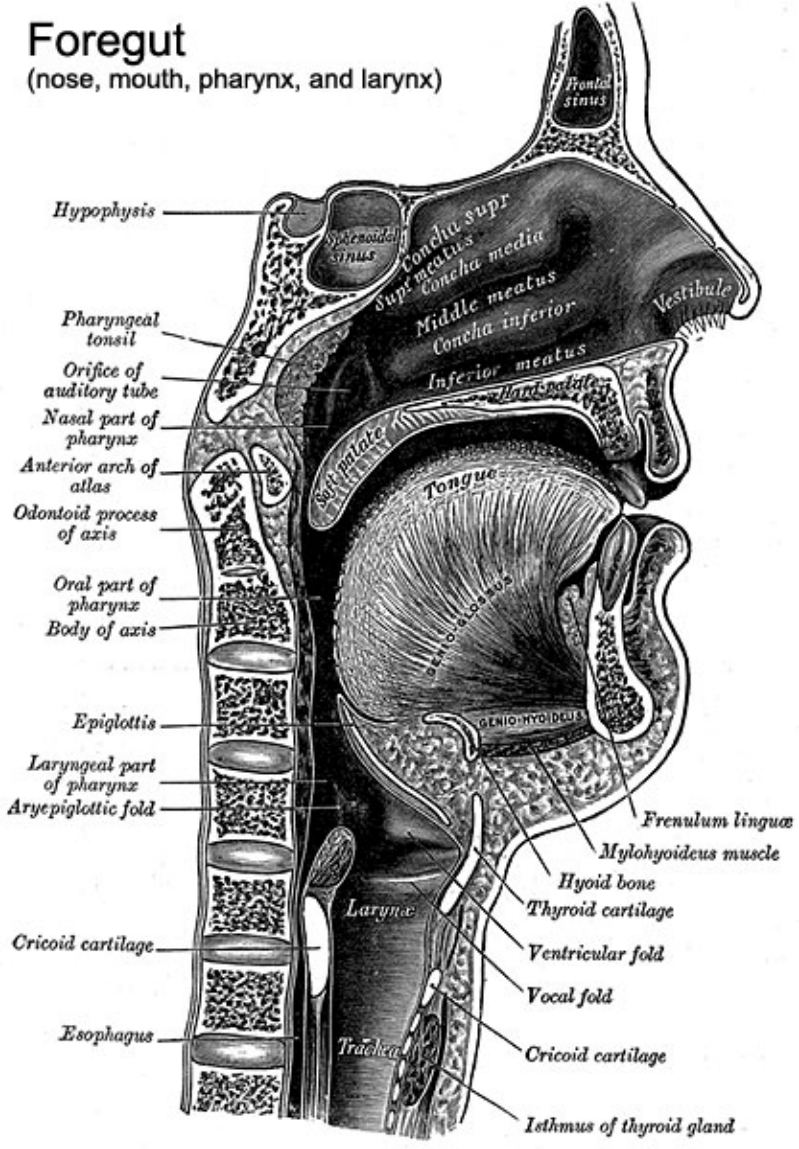

The cavity within the pharyngeal arches forms the pharynx.

- begins at the buccopharyngeal membrane (oral membrane), apposition of ectoderm with endoderm (no mesoderm between)
- expands behind pharyngeal arches
- narrows at glottis and bifurcation of gastrointestinal (oesophagus) and respiratory (trachea) systems
- regions on roof, walls and floor have important contributions to endocrine in oral and neck regions
- also contributes to tongue development

Week 4

Week 4 - Arches (Carnegie stage 11) [Expand]

Pharyngeal Arch Components

Week 4 (Carnegie stage 12)

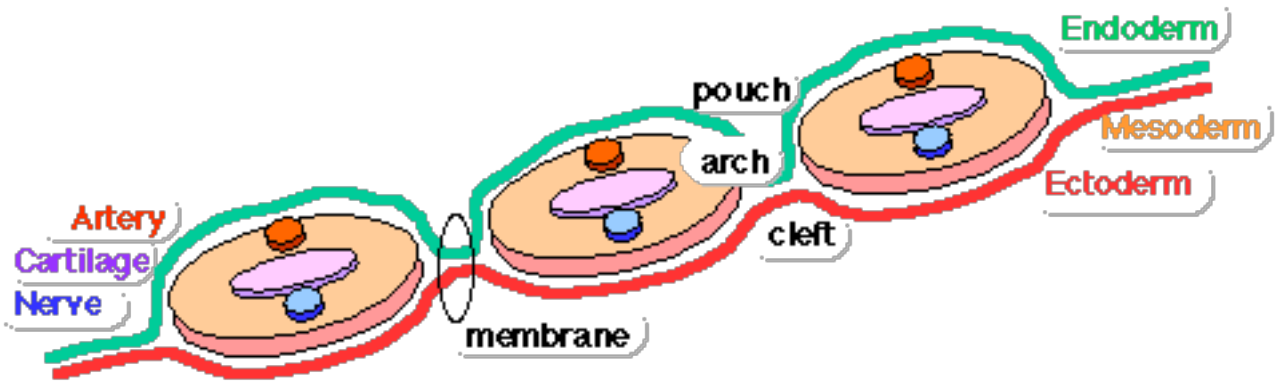

Major features to identify for each: **arch**, **pouch**, **groove** and **membrane**. Contribute to the formation of head and neck and in the human appear at the 4th week. The first arch contributes the majority of

upper and lower jaw structures.

Pharyngeal Arch Development

Pharyngeal (branchial) arch (Greek. *branchia* = gill) consists of all 3 trilaminar embryo layers

- ectoderm - outside surface and core neural crest
- mesoderm - core of mesenchyme
- endoderm - inside pharynx

Pharynx Week 4 (stage 13) [Expand]	Foregut - Week 4 (stage 13) [Expand]

Neural Crest

- Mesenchyme invaded by neural crest generating connective tissue components
- cartilage, bone, ligaments
- arises from midbrain and hindbrain region

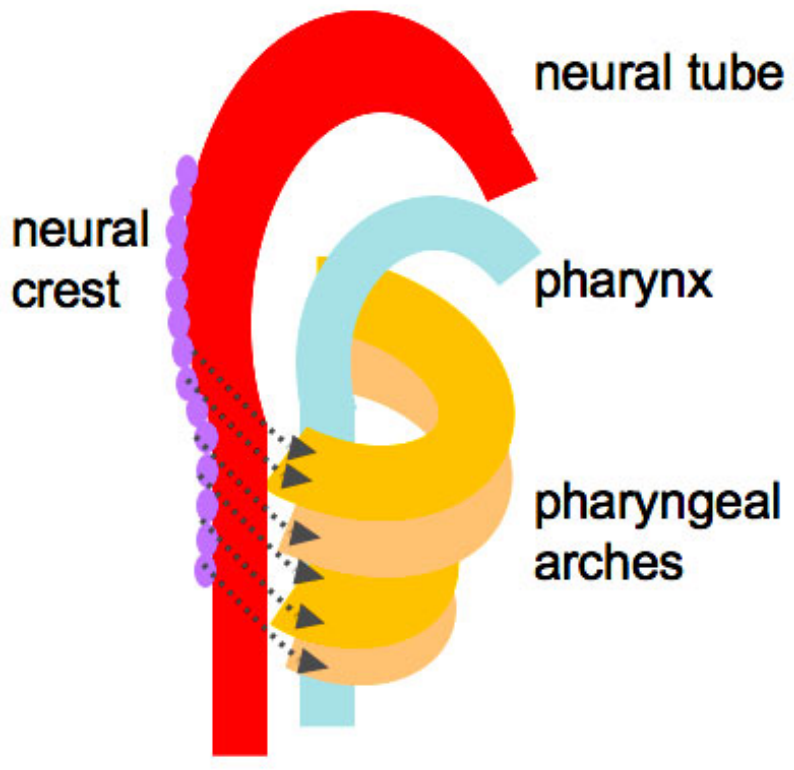

Neural Crest Migration [Expand]

Arch Features

Each arch contains: artery, cartilage, nerve, muscular component

Arches and Phanynx Form the face, tongue, lips, jaws, palate, pharynx and neck cranial nerves, sense organ components, glands

- Humans have 5 arches - 1, 2, 3, 4, 6 (Arch 5 does not form or regresses rapidly)
- form in rostro-caudal sequence, Arch 1 to 6 (from week 4 onwards)
- arch 1 and 2 appear at time of closure of cranial neuropore

- Face - mainly arch 1 and 2
- Neck components - arch 3 and 4 (arch 4 and 6 fuse)

- **arch**
- **groove** - (cleft) externally separates each arch (only first pair persist as external auditory meatus)
- **pouch** - internally separates each arch (pockets out from the pharynx)
- **membrane** - ectoderm and endoderm contact regions (only first pair persist as tympanic membrane)

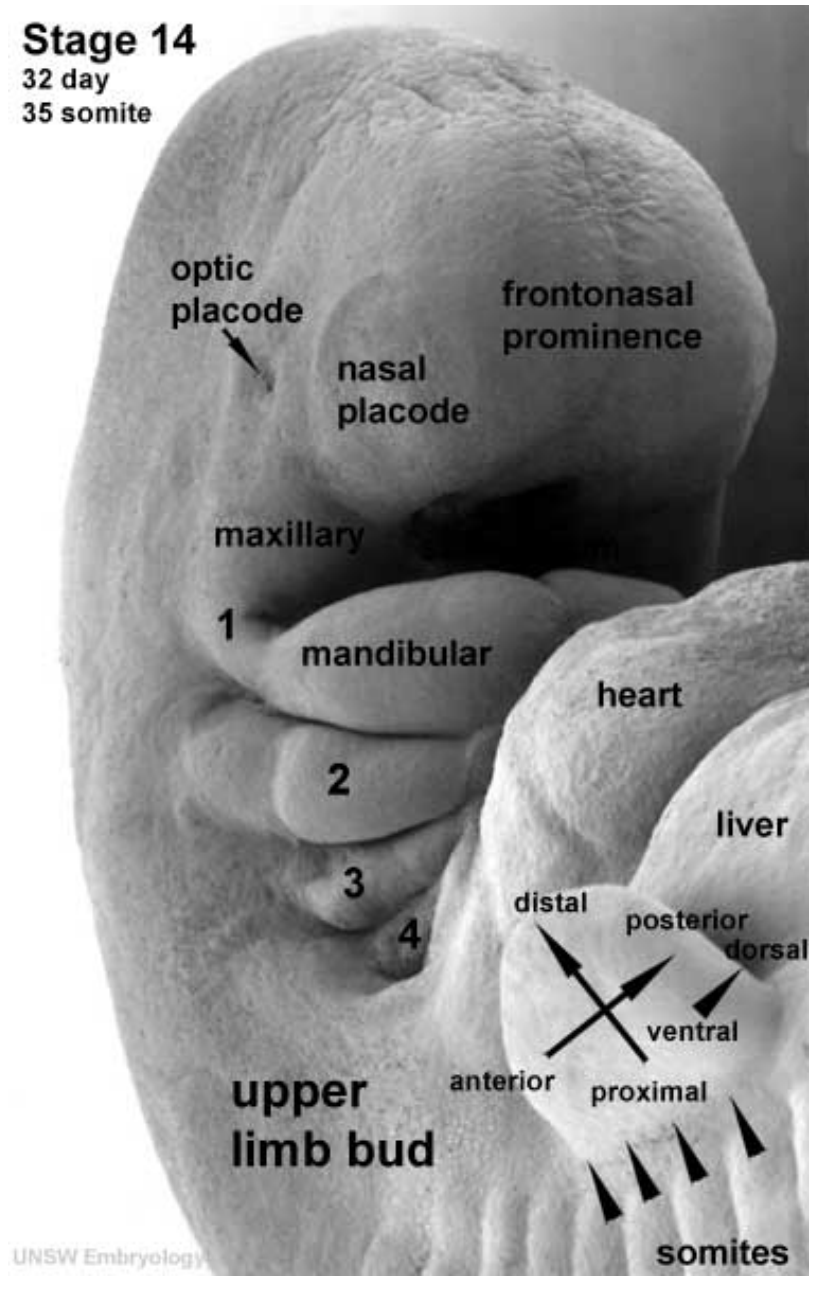

Pharyngeal arches Week 5 (Stage 14 sensory)

Pharyngeal Arch 1 (Mandibular Arch) has 2 prominences

- smaller upper - maxillary forms maxilla, zygomatic bone and squamous part of temporal
- larger lower - mandibular, forms mandible

Pharyngeal Arch 2 (Hyoid Arch)

- forms most of hyoid bone

Arch 3 and 4

- neck structures

Arch Arteries [Expand]

Arch Cartilage [Expand]

Arch Muscle [Expand]

Arch Nerve [Expand]

Arch Pouches [Expand]

Pharyngeal Arch - Summary Table [Expand]

Endocrine

The arch pouches contribute to endocrine organ development, except for the thyroid and pituitary. Note endocrine development will be covered in detail in another later BGD lecture.

{{thyroid))	Anterior pituitary
• not a pouch structure • first endocrine organ to develop day 24 • from **floor of pharynx** • descends thyroglossal duct (which closes) • upper end at foramen cecum 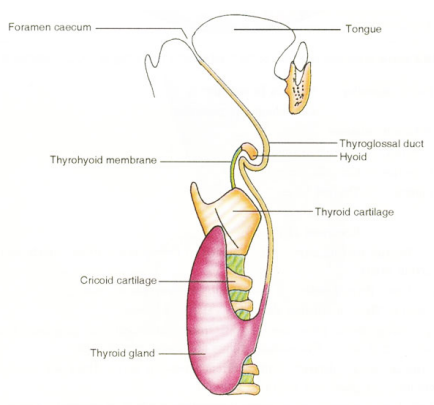 	• not a pouch structure • boundary epitheilal ectoderm placode • forms a pocket (Rathke's pouch) that comes into contact with the ectoderm of developing brain. ◦ Rathke's pouch is named after German embryologist and anatomist Martin Heinrich Rathke (1793 — 1860). 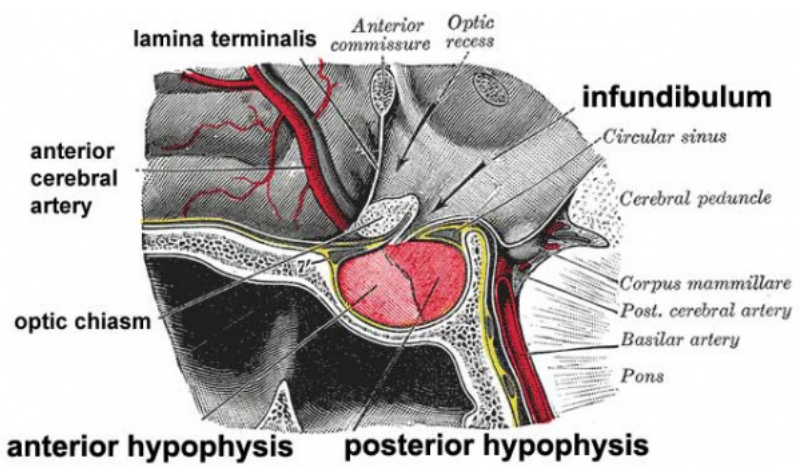

Face Development

Begins week 4 centered around stomodeum, external depression at oral membrane

5 initial primordia from neural crest mesenchyme (week 4)

- **single frontonasal prominence** (FNP) - forms forehead, nose dorsum and apex
  - nasal placodes develop later bilateral, pushed medially

- **paired maxillary prominences** - form upper cheek and upper lip
- **paired mandibular prominences** - lower cheek, chin and lower lip

-
-
-
-

- Stage 15 (35 - 38 days)

Week 4 onward | Week 6-7

Week 8

• End of the embryonic period. • MRI scan through the stage 23 embryo head from left to right. Identify head, neural and sensory structures.	

Head/Skull

Cranium (Neurocranium) surrounds brain.

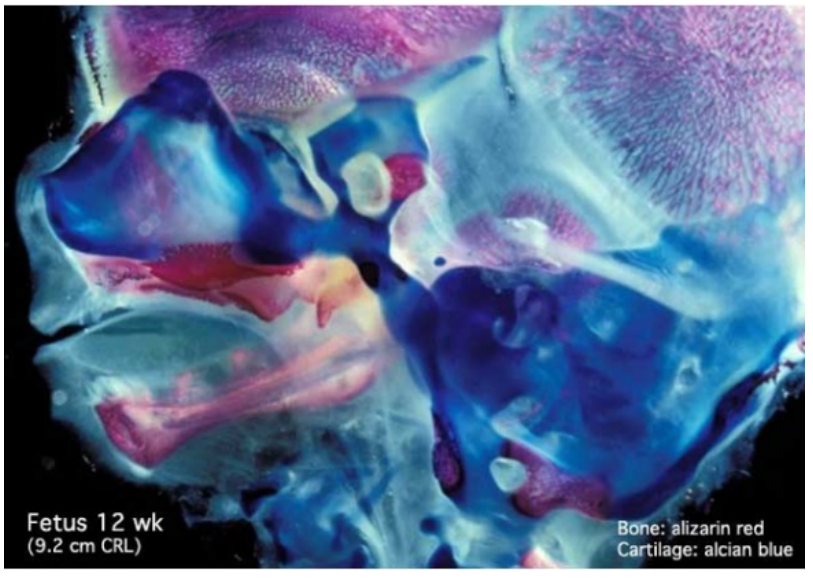

- dermatocranium **intramembranous ossification** - skull calvarial vault
- chondrocranium (**endochondral ossification**) - skull base
- 8 bones - occipital, 2 parietals, frontal, 2 temporals, sphenoidal, ethmoidal.

Face (Viscerocranium) development of the facial bones

- 14 bones - 2 nasals, 2 maxillæ, 2 lacrimals, 2 zygomatics, 2 palatines, 2

inferior nasal conchæ, vomer, mandible.

Calveria - bone has no cartilage (direct ossification of mesenchyme)

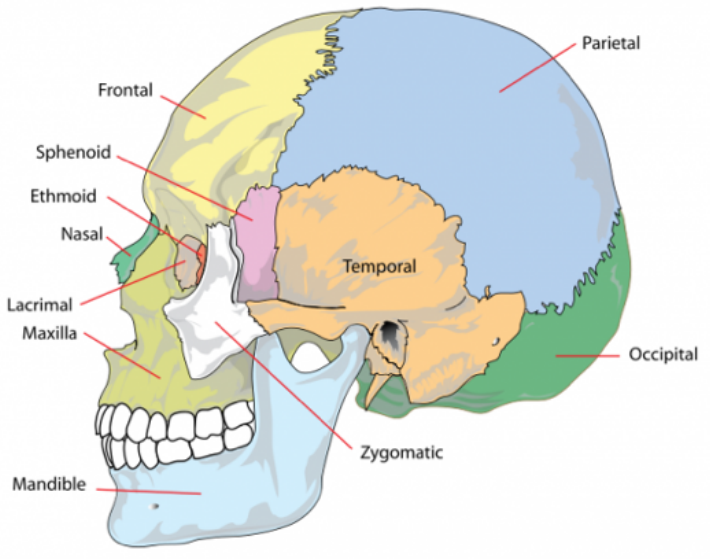

Head Growth

Bones do not fuse, fibrous sutures

1. allow distortion to pass through birth canal
2. allow growth of the brain

- 6 fontanelles - posterior closes at 3 months, anterior closes at 18 months
- puberty growth of face

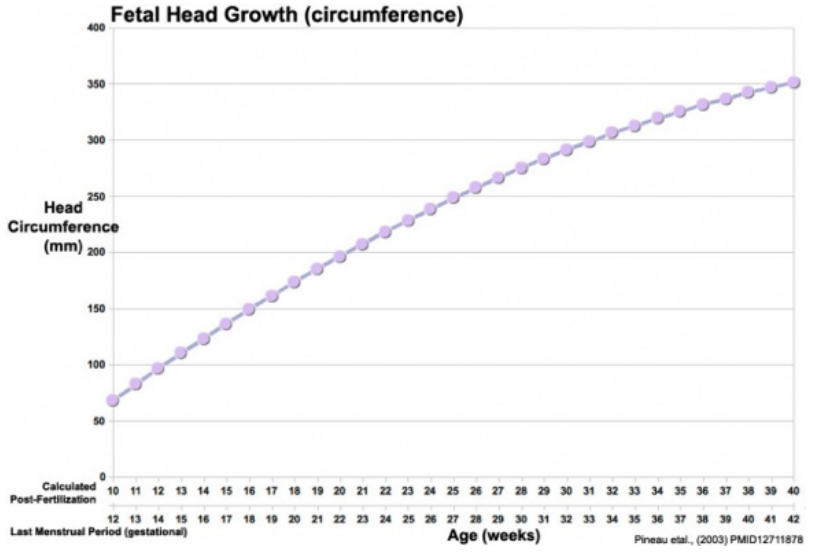

Fetal head growth circumference

- **Newborn**
-
-

- CT Vertex and Lateral

- CT Endocranial and vertex

Links: skull

Sensory Placodes

- During week 4 a series of thickened surface ectodermal patches "placodes" form in pairs rostro-caudally in the head region.
- These sensory placates later

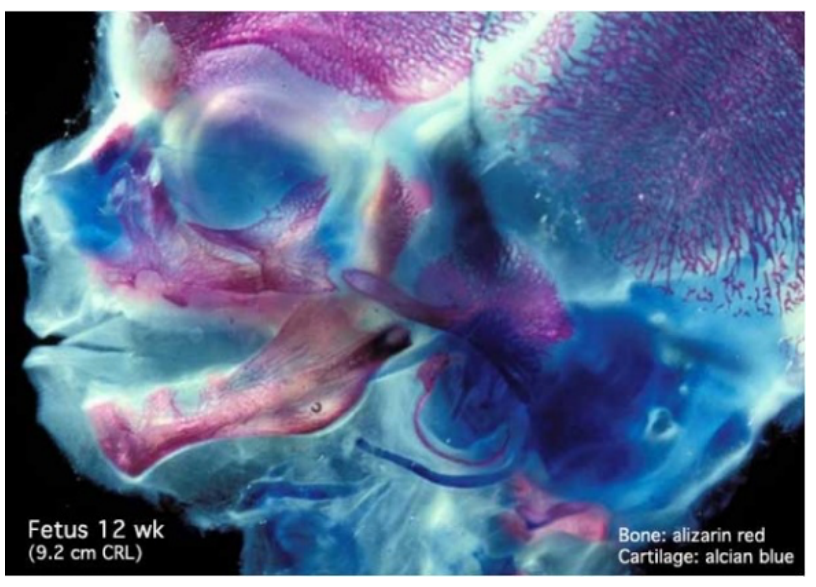

Fetal Head (12 weeks) showing bone and cartilage

contribute key components of each of our special senses (vision, hearing and smell).
- Initial placode postion on the developing head is significantly different to their final position in the future sensory system

Placode Research [Expand]

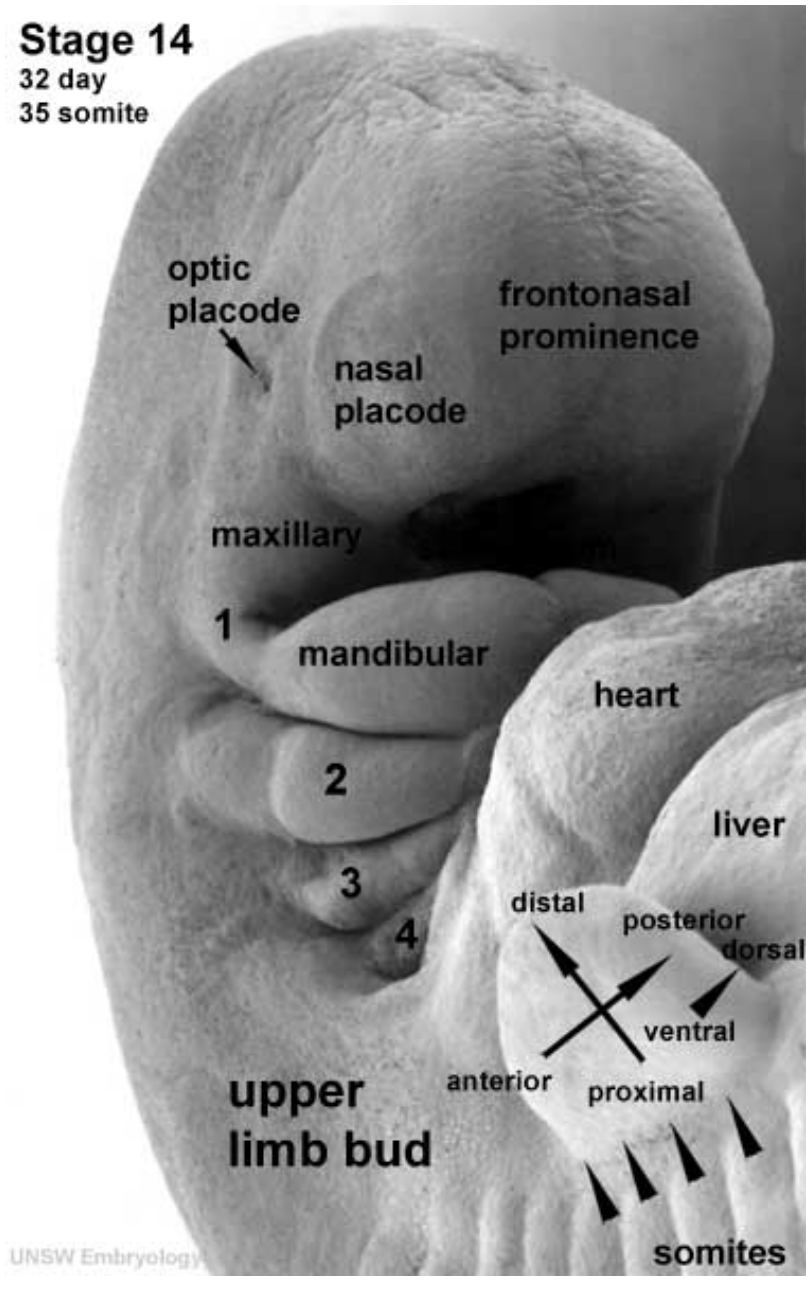

Stage 14 sensory placodes

Otic Placode

- Carnegie stage 12 still visible on embryo surface.
- Carnegie stage 13/14 embryo (shown below) the otic placode has sunk from the surface ectoderm to form a hollow epithelial ball, the otocyst, which now lies beneath the surface surrounded by mesenchyme (mesoderm). The epithelia of this ball varies in thickness and has begun to distort, it will eventually form the inner ear membranous labyrinth.

Lens Placode

- (optic placode) lies on the surface, adjacent to the outpocketing of the nervous system (which will for the retina) and will form the lens.

Nasal Placode

- Has 2 components (medial and lateral) and will form the nose olefactory epithelium.

Hearing Development

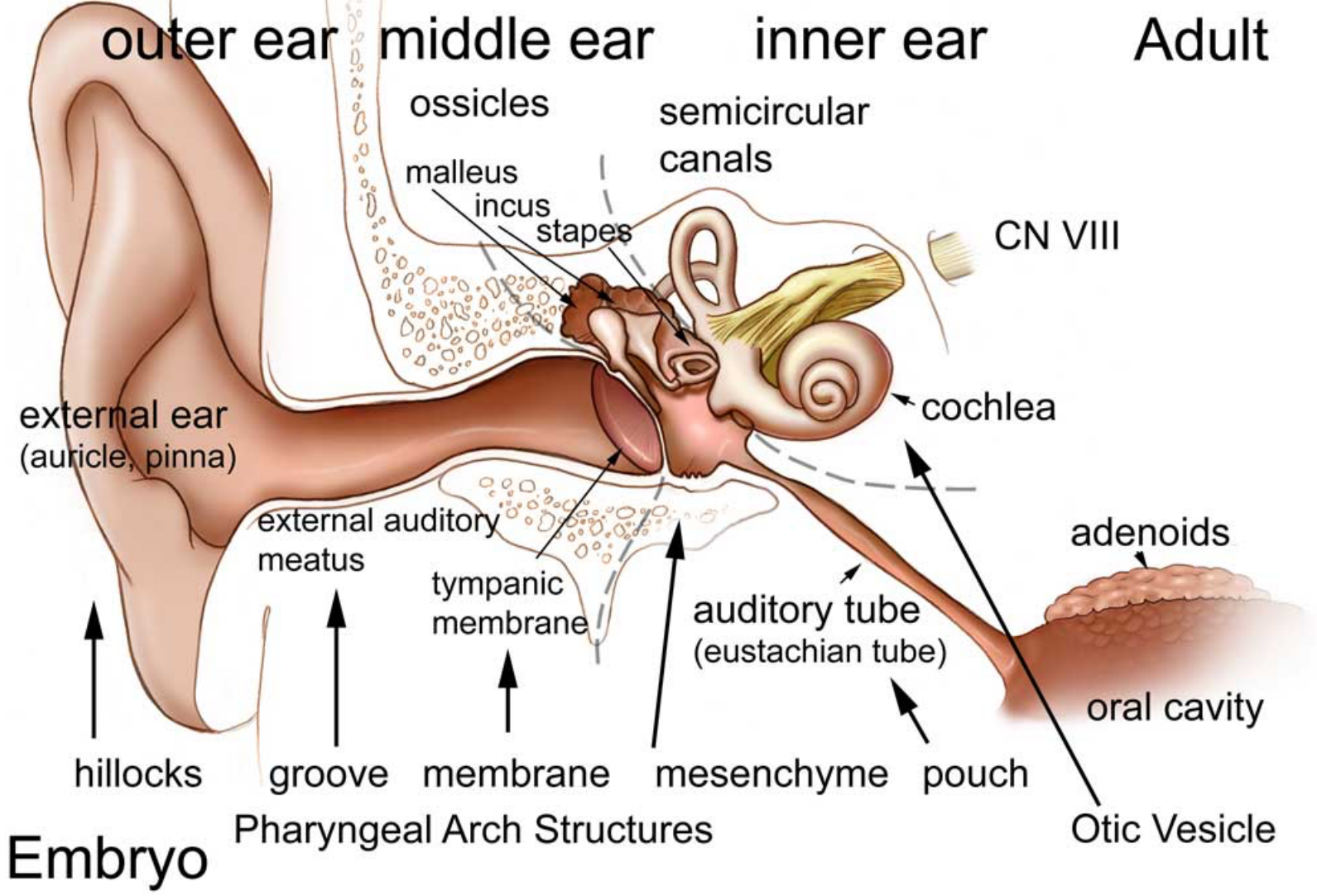

Inner Ear

Week 5	Week 8
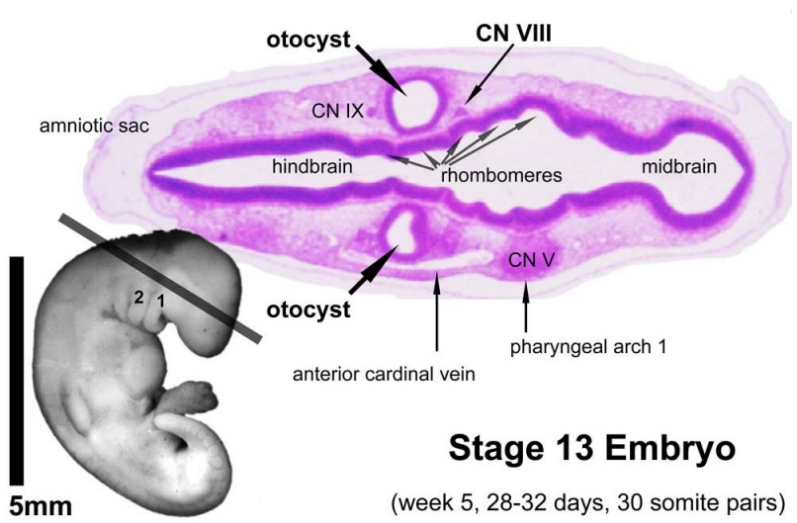	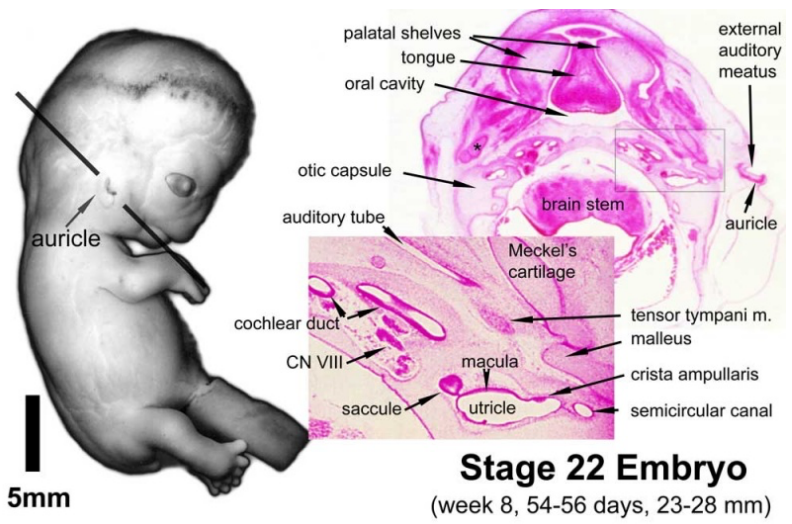
Otocyst (Week 5, Stage 13)	Inner Ear (Week 8, Stage 22)

- Inner Ear Labyrinth
  - Cochlea - Otic vesicle - Otic placode (ectoderm)
  - Semicircular canals - Otic vesicle - Otic placode (ectoderm)
  - Saccule and utricle - Otic vesicle - Otic placode (ectoderm)
- Cranial Nerve VIII
  - Auditory component - Otic vesicle and neural crest (ectoderm)
  - Vestibular component - Otic vesicle and neural crest (ectoderm)

Middle Ear

- Middle Ear Ossicles
  - Malleus and incus - Pharyngeal Arch 1 cartilage Neural crest (ectoderm)
  - Stapes - Pharyngeal Arch 2 cartilage Neural crest (ectoderm)
- Middle Ear Muscles
  - Tensor tympani - Pharyngeal Arch 1 (mesoderm)
  - Stapedius - Pharyngeal Arch 2 (mesoderm)
- Middle ear cavity - Pharyngeal Arch 1 pouch (endoderm)

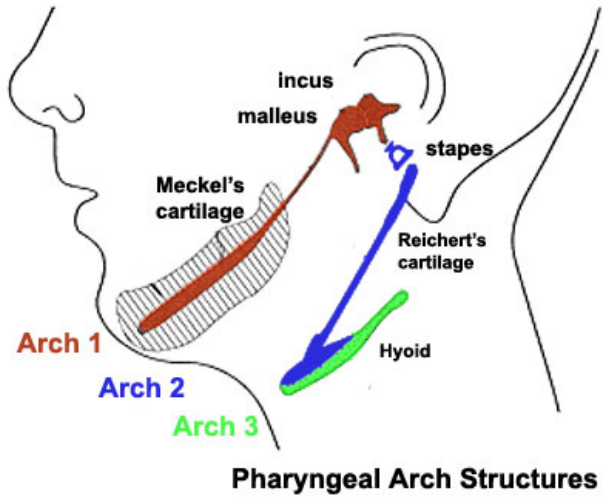

Pharyngeal arch cartilages

External Ear

- **Auricle** - Pharyngeal Arches 1 and 2 (ectoderm, mesoderm)
  - form from 6 hillocks (week 5) 3 on each of arch 1 and 2
- **External Auditory Meatus** - Pharyngeal Arch 1 groove or cleft (ectoderm)
- **Tympanic Membrane** - Pharyngeal Arch 1 membrane (ectoderm, mesoderm, endoderm)

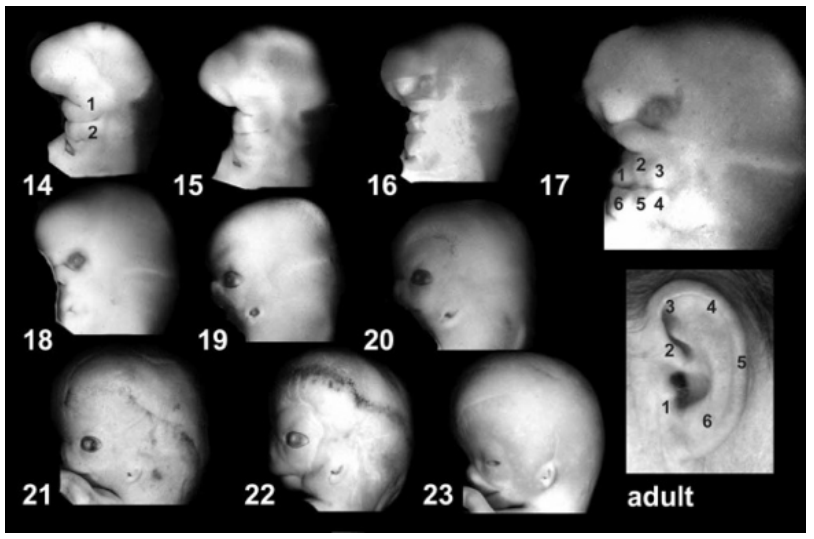

External ear stages 14-23 and adult (not to scale)

Postnatal Changes

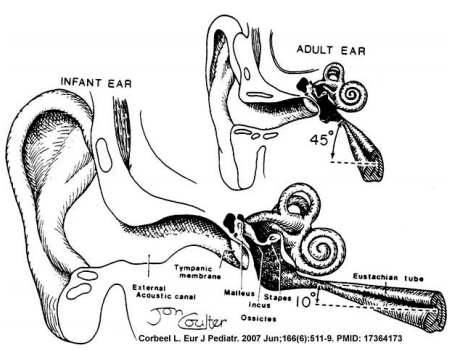

Adult - longer (twice as long), wider and runs at approximately 45 degrees to the horizontal, tube is opened by two separate muscles (tensor palati and levator palati)

At birth - shorter (17-18 mm), narrower and runs almost horizontal, tube is opened by a single muscle (tensor palati muscle)

- Auditory tube = Eustachian, otopharyngeal or pharyngotympanic tube.
- Connects middle ear cavity to nasopharynx portion of pharynx
- Ventilation - pressure equalization in the middle ear
- Clearance - allow fluid drainage from the middle ear Tube is normally closed and opened by muscles

Links: Hearing Development

Palate

Embryonic

Primary palate, fusion in the human embryo between week 6-7 (stage 17 and 18, GA Week 8-9), from an epithelial seam to the mesenchymal bridge. Phases of Primary Palate Formation Carnegie stages 17 to 18 (epithelial seam to mesenchymal bridge)	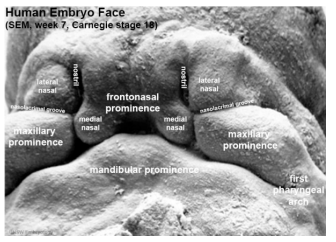

Fetal

Secondary palate, fusion in the human embryo in week 9 (GA week 11). This requires the early palatal shelves growth, elevation and fusion during the early embryonic period. The fusion event is to both each other and the primary palate. palatal shelf elevation | secondary palate

Tongue Development

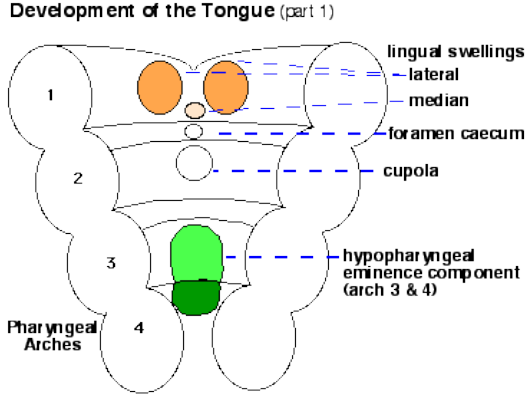

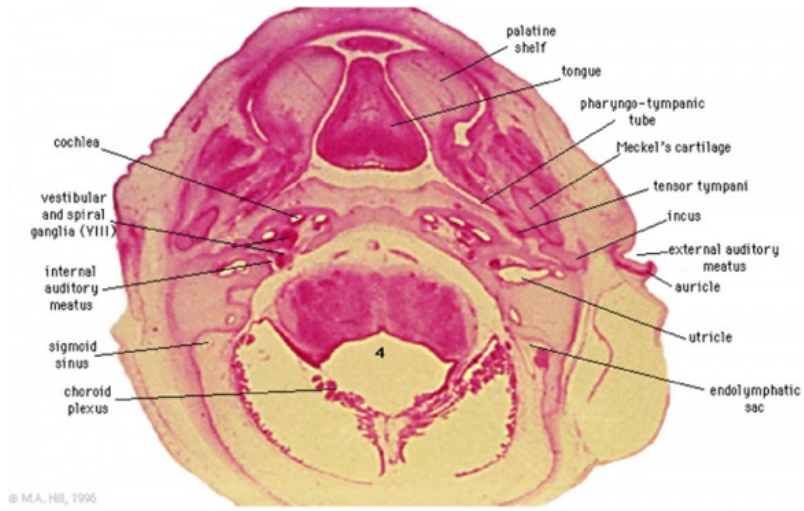

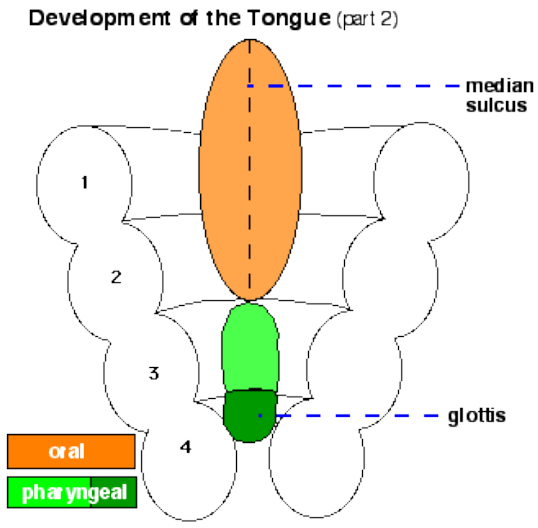

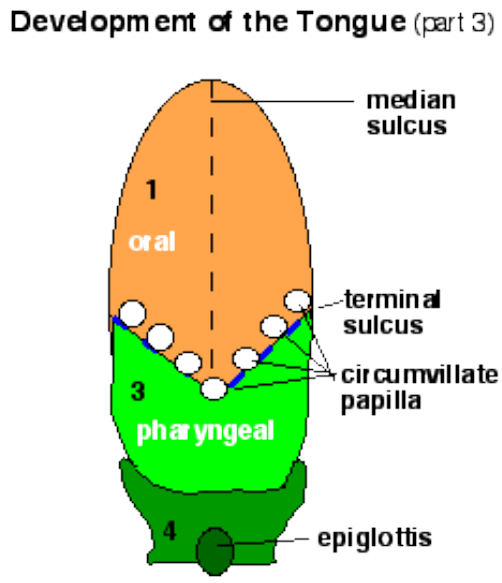

- Ectoderm of the first arch surrounding the stomodeum forms the epithelium lining the buccal cavity.
- Also the salivary glands, enamel of the teeth, epithelium of the body of the tongue.
    - As the tongue develops "inside" the floor of the oral cavity, it is not readily visible in the external views of the embryonic (Carnegie) stages of development.

- Contributions from all arches, which changes with time
- begins as swelling rostral to foramen cecum, **median tongue bud**

-
    - Arch 1 - oral part of tongue (ant 3/2)
    - Arch 2 - initial contribution to surface is lost

- Arch 3 - pharyngeal part of tongue (post 1/3)
- Arch 4 - epiglottis and adjacent regions

tongue development animation

Tongue Muscle

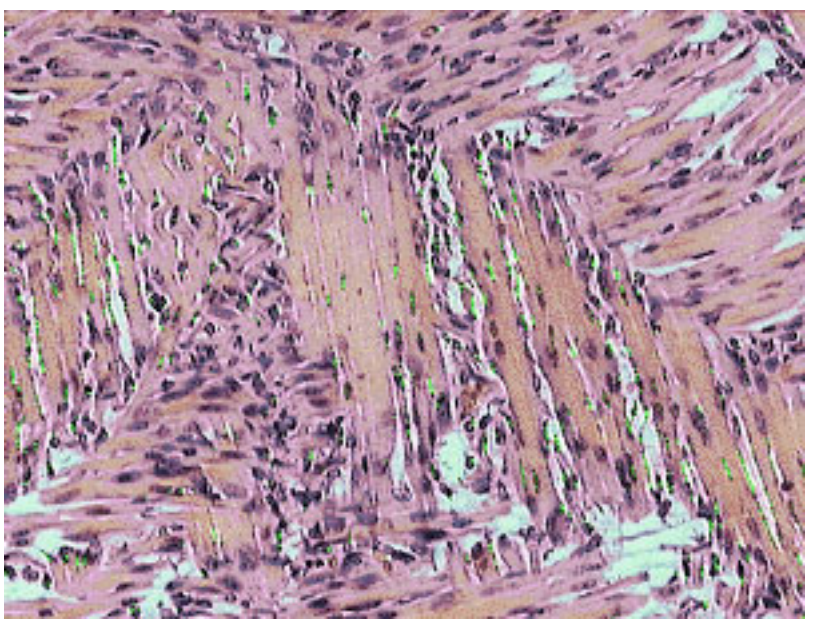

- Skeletal muscle originate from the somites.
- Tongue muscles develop before masticatory muscles and is completed by birth.

Masticatory muscles

- Originate from the somitomeres. These muscles develop late and are not complete even at birth.
- paraxial mesoderm in cranial region forms somitomeres that do not become somites.

Salivary Glands

- epithelial buds in oral cavity (wk 6-7) extend into mesenchyme
- parotid, submandibular, sublingual

Abnormalities

Will be covered in detail in the associated practical class.

Cleft Lip and Palate

- 300+ different abnormalities, different cleft forms and extent, upper lip and ant. maxilla, hard and soft palate

Statistics - The ten most frequently reported birth defects in Victoria between 2003-2004.

Victoria - 10 most reported birth anomalies [Expand]

USA Statistics [Expand]

Cleft Palate

- Cleft palate has the International Classification of Diseases code 749.0.
- In Australia the national rate (1982-1992) for this abnormalitity in births was 4.8 - 6/10,000 births, which represented 1,530 infants 5.5% were stillborn and 11.5% liveborn died during neonatal period and slightly more common in twin births than singleton.

Cleft Lip

- The International Classification of Diseases code 749.1 for isolated cleft lip and 749.2 for cleft lip with cleft palate.
- In Australia the national rate (1982-1992) for this abnormalitity was 8.1 - 9.9 /10,000 births. Of 2,465 infants 6.2% were stillborn and 7.8% liveborn died during neonatal period and the rate was similar in singleton and twin births.

Palate Links: palate | cleft lip and palate | cleft palate | Head Development | Category:Palate

First Arch Syndrome

- There are 2 major types of associated first arch syndromes, Treacher Collins (Mandibulofacial dysostosis) and Pierre Robin (Pierre Robin complex or sequence), both result in extensive facial abnormalites.

Treacher Collins Syndrome

Pierre Robin Syndrome

- Hypoplasia of the mandible, cleft palate, eye and ear defects.
- Initial defect is small mandible (micrognathia) resulting in posterior displacement of tongue and a bilateral cleft palate.

DiGeorge Syndrome

- absence of thymus and parathyroid glands, 3rd and 4th pouch do not form
- disturbance of cervical neural crest migration

Cysts

- Many different types

Facial Clefts

-
    - extremely rare
- Holoprosencephaly
    - shh abnormality

Maternal Effects

- Retinoic Acid - present in skin ointments
- 1988 associated with facial developmental abnormalities

Fetal Alcohol Syndrome

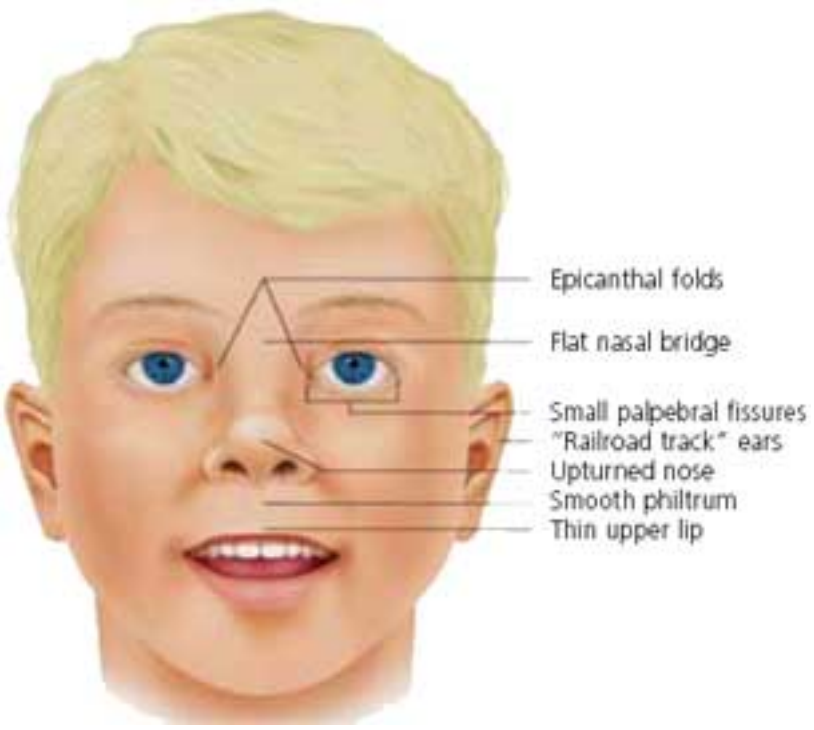

Due to alcohol in early development (week 3+) leading to both facial and neurological abnormalities

- lowered ears, small face, mild+ retardation
- Microcephaly - leads to small head circumference
- Short Palpebral fissure - opening of eye
- Epicanthal folds - fold of skin at inside of corner of eye

- Flat midface
- Low nasal bridge
- Indistinct Philtrum - vertical grooves between nose and mouth
- Thin upper lip
- Micrognathia - small jaw

Exposure of embryos in vitro to ethanol simulates premature differentiation of prechondrogenic mesenchyme of the facial primordia (1999)

Links: Fetal Alcohol Syndrome

Table - Structures derived from Arches

Arch	Nerve	Skeletal Structures	Muscles	Ligamen
1 (maxillary/mandibular)	trigeminal (V)	mandible, maxilla, malleus, incus		ant lig of r sphenoma ligament
2 (hyoid)	facial (VII)	stapes, styloid process, lesser cornu of hyoid, upper part of body of hyoid bone		stylohyoid ligament
3	glossopharyngeal (IX)	greater cornu of hyoid, lower part of body of hyoid bone		
4 & 6	superior laryngeal and recurrent laryngeal branch of vagus (X)	thyroid, cricoid, arytenoid, corniculate and cuneform cartilages		

Structures derived from Pouches

Each pouch is lined with endoderm and generates specific structures.

POUCH	Overall Structure	Specific Structures
1	tubotympanic recess	tympanic membrane, tympanic cavity, mastoid antrum, auditory tube
2	intratonsillar cleft	crypts of palatine tonsil, lymphatic nodules of palatine tonsil
3	inferior parathyroid gland, thymus gland	
4	superior parathyroid gland, ultimobranchial body	
5	becomes part of 4th pouch	

Structures derived from Grooves

Only the **first groove** differentiates into an adult structure and forms part of the external acoustic meatus.

Structures derived from Membranes

At the bottom of each groove lies the membrane which is formed from the contact region of ectodermal groove and endodermal pouch.

Only the **first membrane** differentiates into an adult structure and forms the tympanic membrane.

References

Additional Resources [Expand]

Terms

Terms [Expand]

Hearing Terms [Expand]

External Links

***External Links Notice** - The dynamic nature of the internet may mean that some of these listed links may no longer function. If the link no longer works search the web with the link text or name. Links to any external commercial sites are provided for **information purposes only** and should never be considered an endorsement. UNSW Embryology is provided as an educational resource with no clinical information or commercial affiliation.*

Embryo Images Unit [Expand]

BGDB: Lecture - Gastrointestinal System | Practical - Gastrointestinal System | **Lecture - Face and Ear** | Practical - Face and Ear | Lecture - Endocrine | Lecture - Sexual Differentiation | Practical - Sexual Differentiation | Tutorial

Glossary Links

Glossary: A | B | C | D | E | F | G | H | I | J | K | L | M | N | O | P | Q | R | S | T | U | V | W | X | Y | Z | Numbers | Symbols

Cite this page: Hill, M.A. (2018, May 8) **Embryology** *BGD Lecture - Face and Ear Development*. Retrieved from https://embryology.med.unsw.edu.au/embryology/index.php/BGD_Lecture_-_Face_and_Ear_Development

What Links Here?

© Dr Mark Hill 2018, ***UNSW Embryology*** ISBN: 978 0 7334 2609 4 - UNSW CRICOS Provider Code No. 00098G