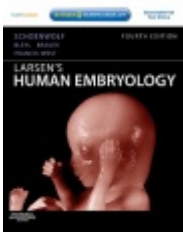



# Development of the skin and its derivatives



Resources:  
<http://php.med.unsw.edu.au/embryology/>  
Larsen's Human Embryology  
The Developing Human: Clinically Oriented Embryology



Dr Annemiek Beverdam – School of Medical Sciences, UNSW  
Wallace Wurth Building Room 234 – A.Beverdam@unsw.edu.au

# Lecture overview

Skin

Skin origins

Development of the overlying epidermis

Development of epidermal appendages:

*Hair follicles*

*Glands*

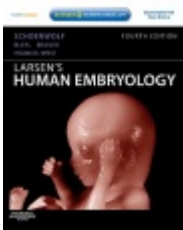
*Mammary glands*

*Nails*


*Teeth*

Development of melanocytes

Development of the Dermis



Resources:  
<http://php.med.unsw.edu.au/embryology/>  
Larsen's Human Embryology  
The Developing Human: Clinically Oriented Embryology



Dr Annemiek Beverdam – School of Medical Sciences, UNSW  
Wallace Wurth Building Room 234 – A.Beverdam@unsw.edu.au

# Skin

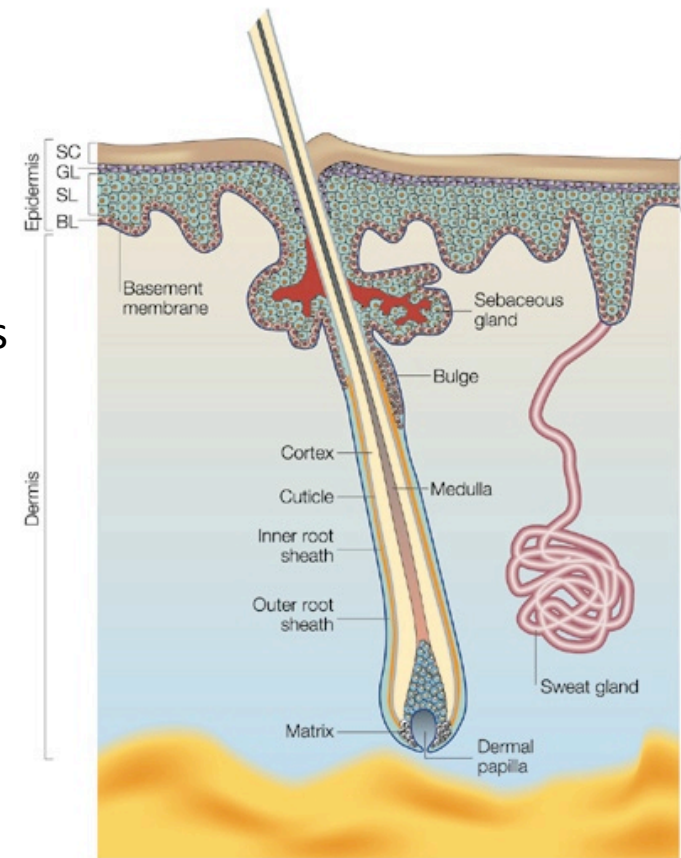
Largest organ of our body

Protects inner body from outside world (pathogens, water, sun)

Thermoregulation

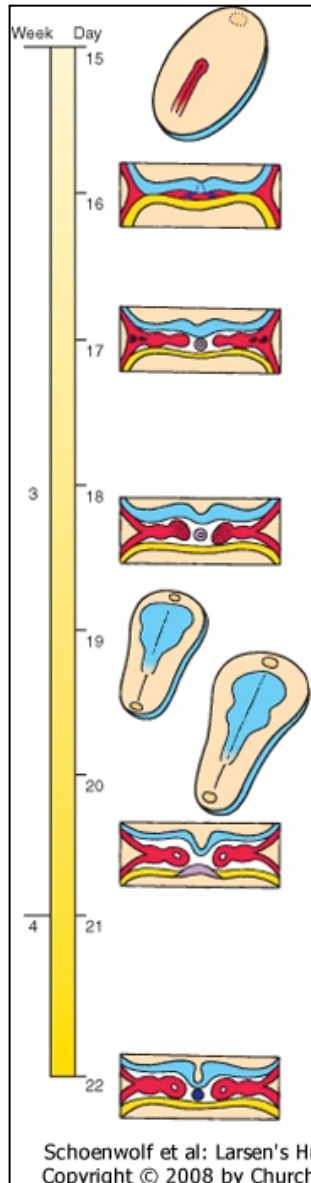
Consists of:

- Overlying epidermis
- Epidermal appendages:
  - hair follicles,
  - sebaceous glands, sweat glands, apocrine glands
  - Mammary glands
  - Nails
  - Teeth
- Melanocytes
- Dermis
- Hypodermis



# Skin origins

## Trilaminar embryo



### Ectoderm (Neural crest)

brain, spinal cord, eyes, *peripheral nervous system*  
epidermis of skin and associated structures, *melanocytes*  
*cranial connective tissues (dermis)*

### Mesoderm

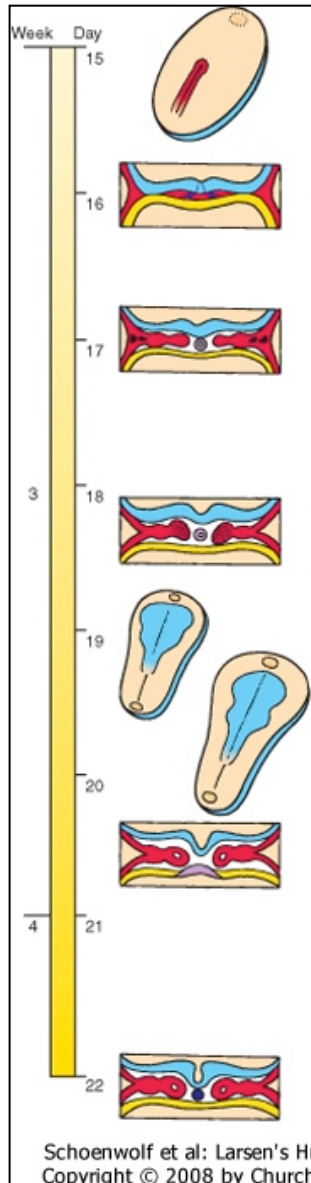
musculo-skeletal system  
limbs  
connective tissue of skin and organs  
urogenital system, heart, blood cells

### Endoderm

epithelial linings of gastrointestinal and respiratory tracts

# Skin origins

## Trilaminar embryo



### Ectoderm (Neural crest)

brain, spinal cord, eyes, *peripheral nervous system*  
*epidermis of skin* and associated structures,  
*melanocytes, cranial connective tissues (dermis)*

### Mesoderm

musculo-skeletal system  
limbs  
*connective tissue of skin* and organs  
urogenital system, heart, blood cells

### Endoderm

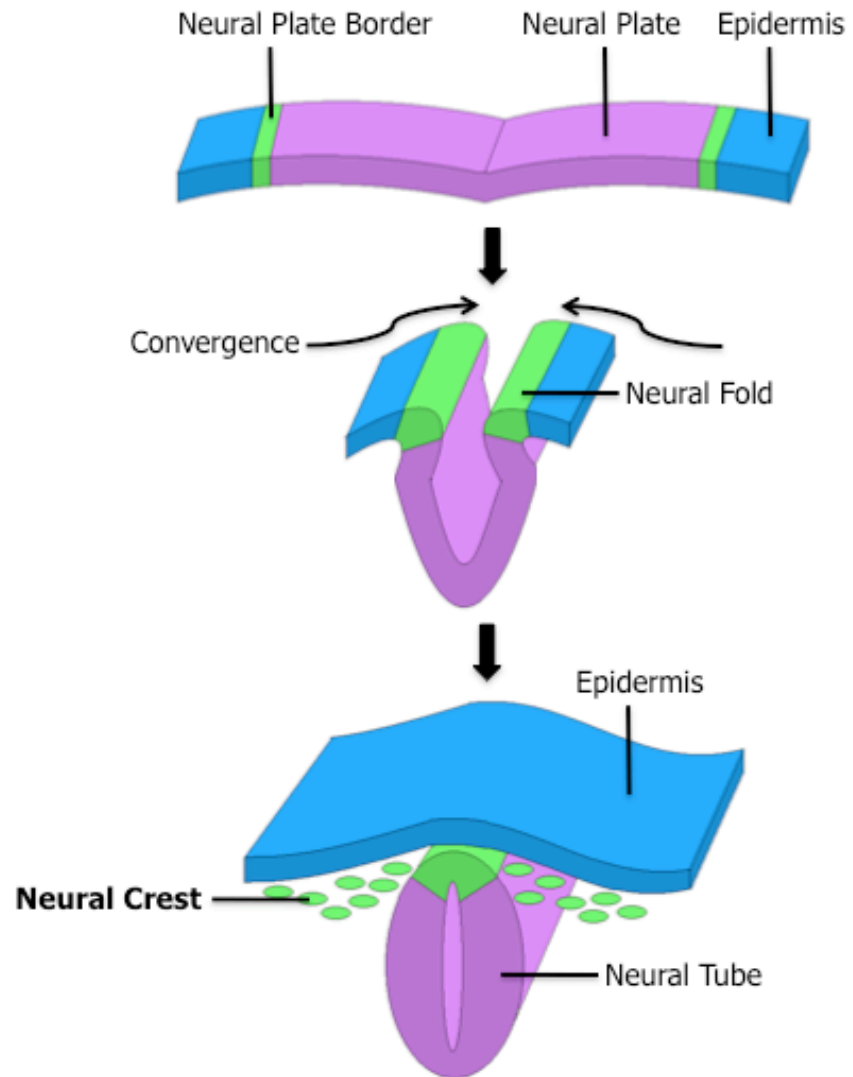
epithelial linings of gastrointestinal and respiratory tracts

# Ectoderm

Overlying epidermis + epidermal appendages



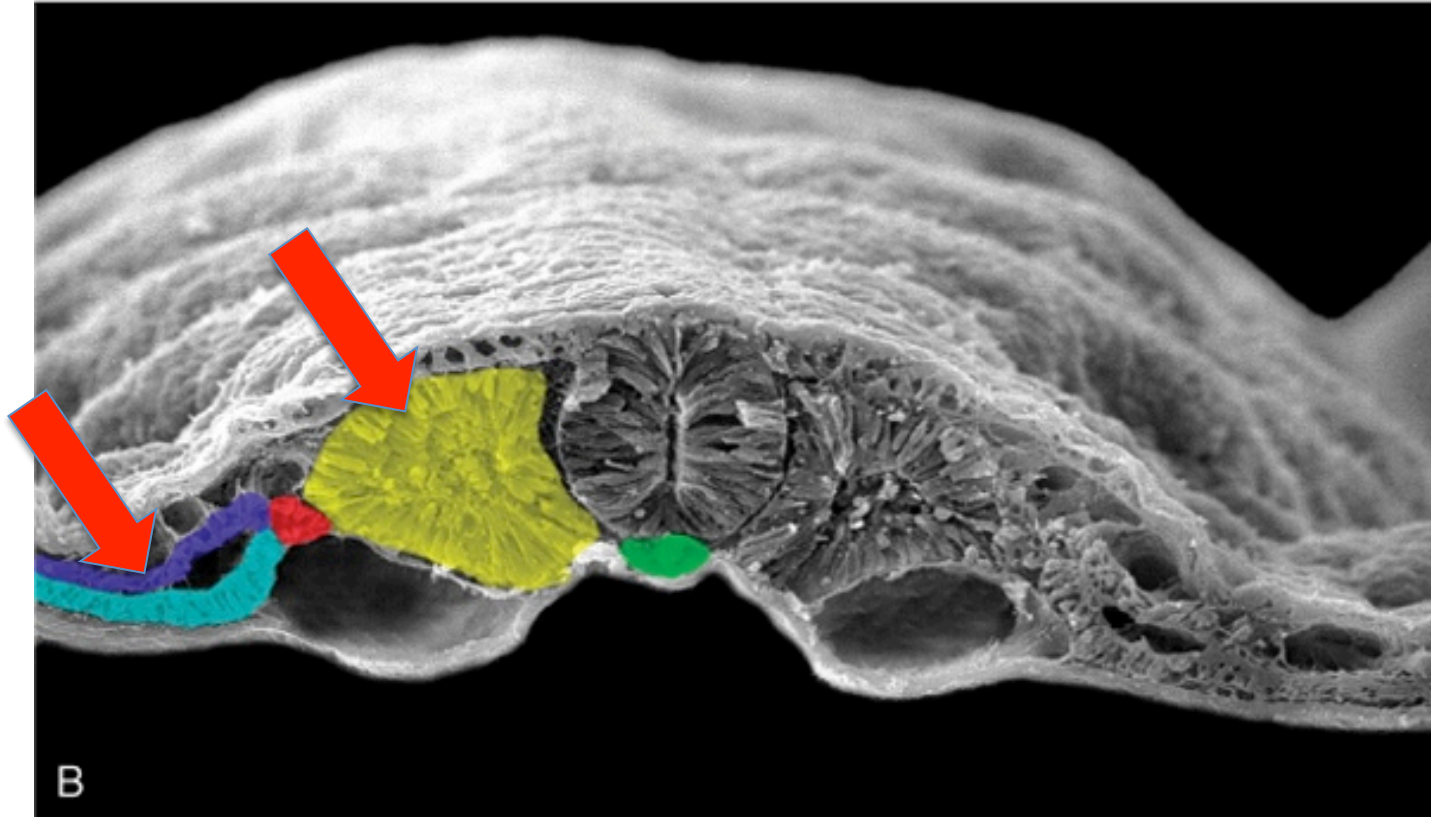
# Neural Crest Melanocytes





# Mesoderm

## Dermis, Hypodermis



Schoenwolf et al: Larsen's Human Embryology, 4th Edition.  
Copyright © 2008 by Churchill Livingstone, an imprint of Elsevier, Inc. All rights reserved

Somitic mesoderm (yellow): dermomyotome  
Somatic lateral plate mesoderm (purple)



# Epidermal development

## Surface ectoderm

Skin/Interfollicular epidermis

Appendages:

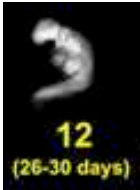- Hair follicles

- Glands (sebaceous, sweat, apocrine, mammary)

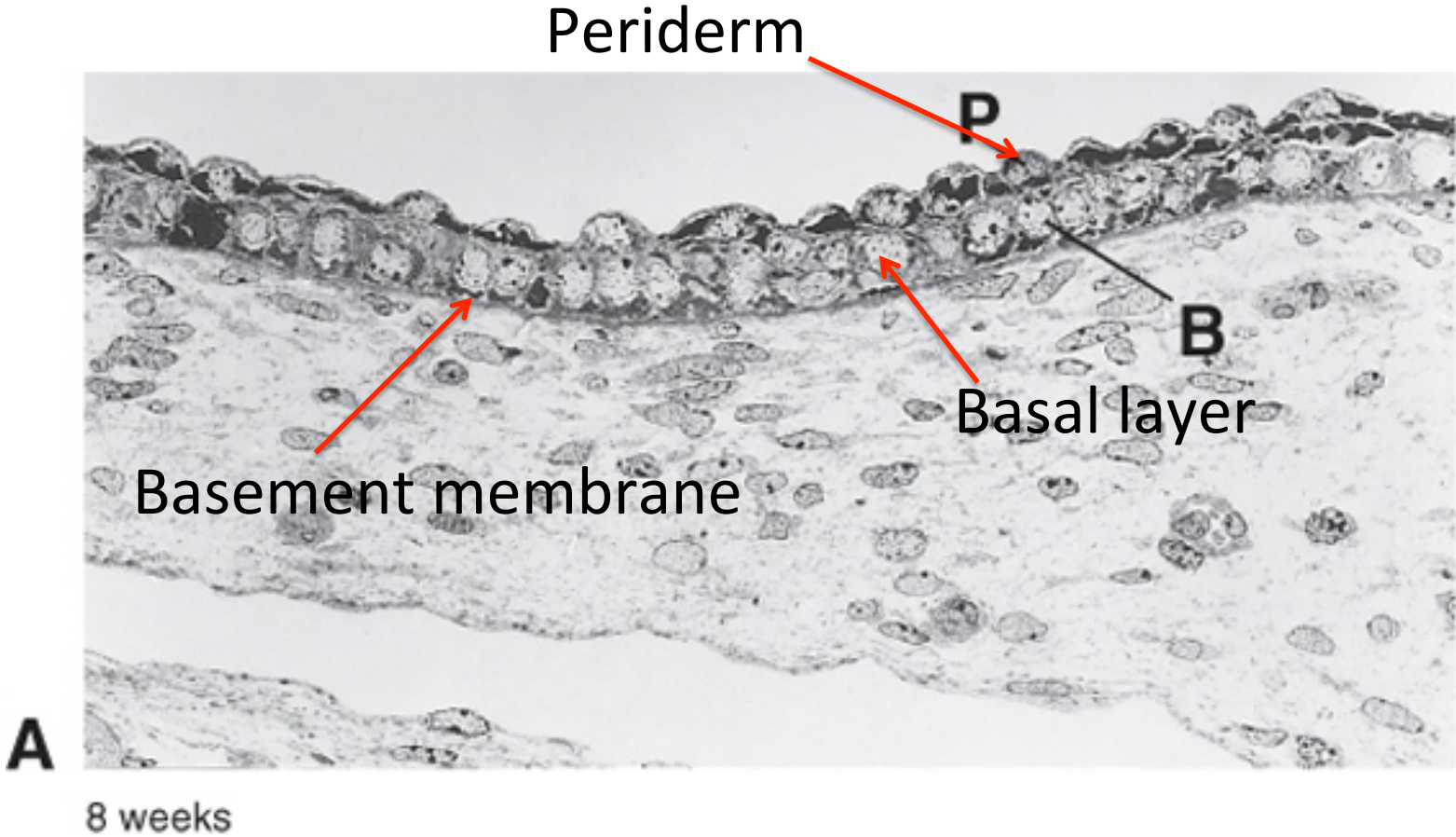
- Nails

- Teeth

# Development of Skin/interfollicular epidermis (IFE)

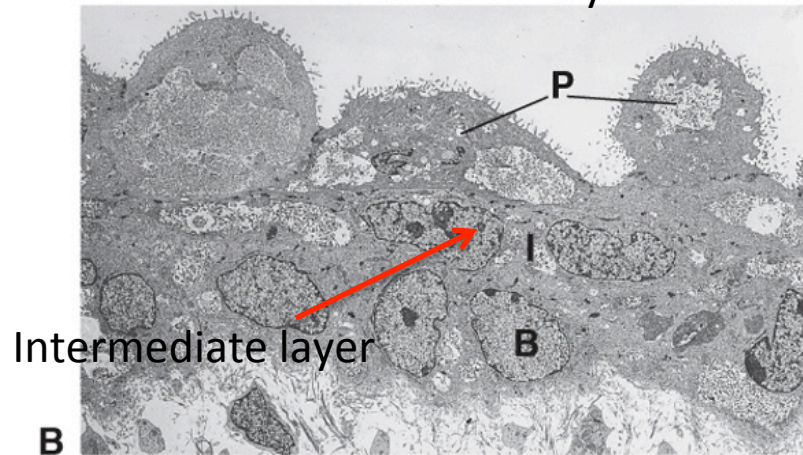


Periderm formation: 4 weeks



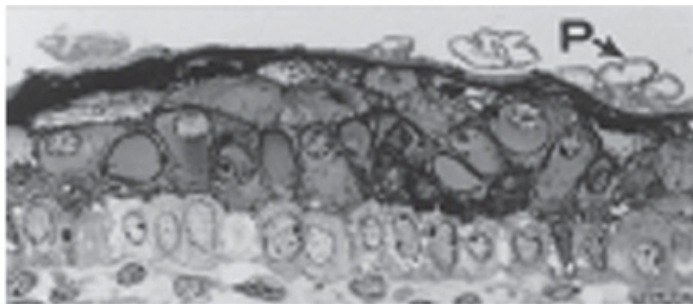
# Development of Skin/interfollicular epidermis (IFE) Stratification

Week 11: intermediate layer

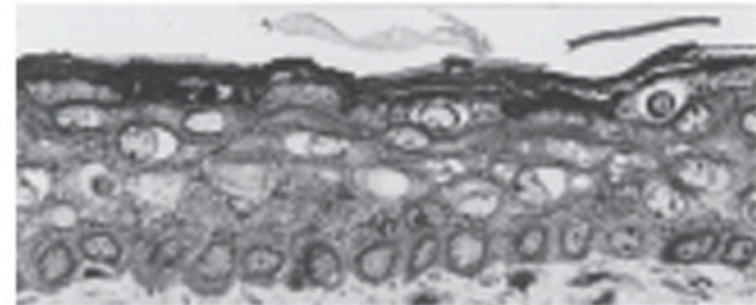


11 weeks  
Schoenwolf et al: Larsen's Human Embryology, 4th Edition.  
Copyright © 2008 by Churchill Livingstone, an imprint of Elsevier, Inc. All rights reserved

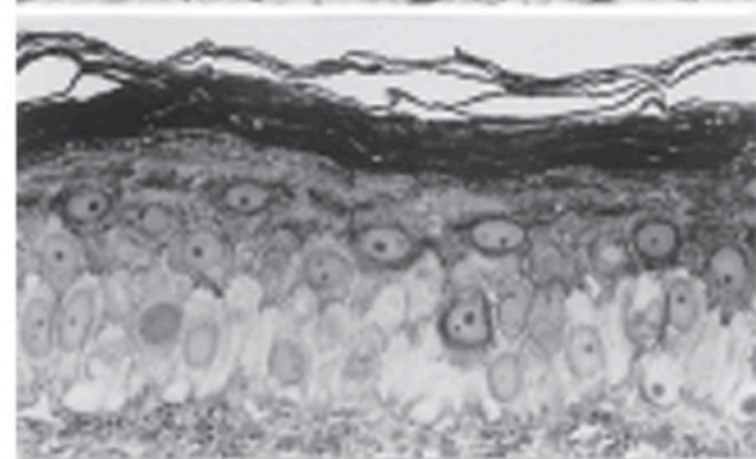
17 weeks



24 weeks



Adult

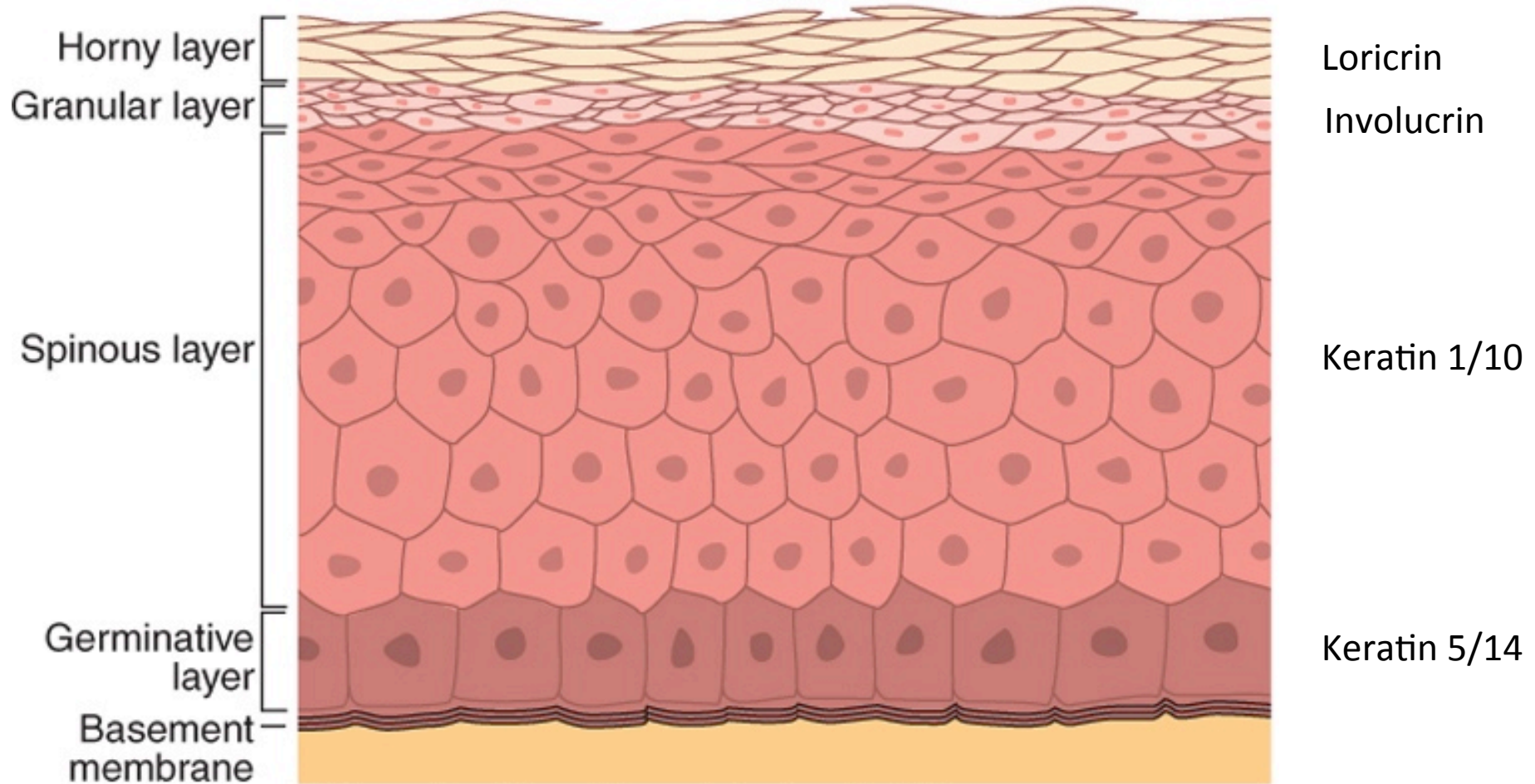


Schoenwolf et al: Larsen's Human Embryology, 4th Edition.  
Copyright © 2008 by Churchill Livingstone, an imprint of Elsevier, Inc. All rights reserved



# Stratified skin/IFE

## Epidermis

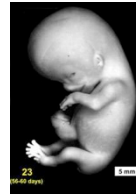

Schoenwolf et al: Larsen's Human Embryology, 4th Edition.  
Copyright © 2008 by Churchill Livingstone, an imprint of Elsevier, Inc. All rights reserved.

# Hair follicle development and cycling

Epidermal appendage

Involved in thermoregulation/sun protection



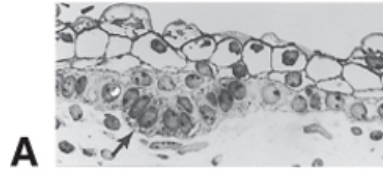
Month 2-4: Onset hair follicle development

Hair follicles develop first in cranial region

Month 5: most hair follicles present  $\approx$  5,000,000 hair follicles

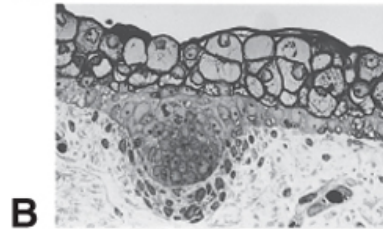
# Hair follicle development

Hair germ



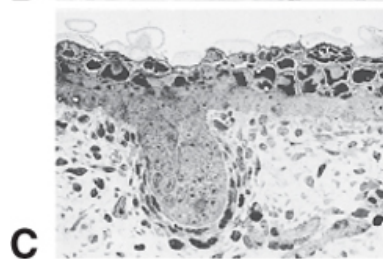
**A**

Hair peg



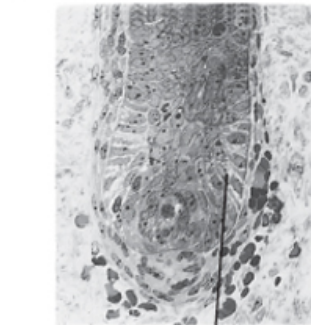
**B**

Bulbous hair peg



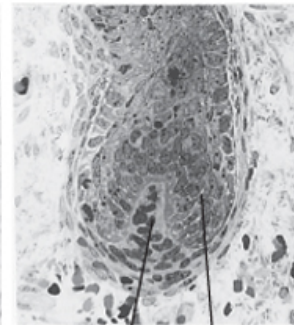
**C**

Invasion of dermis cells



**D**

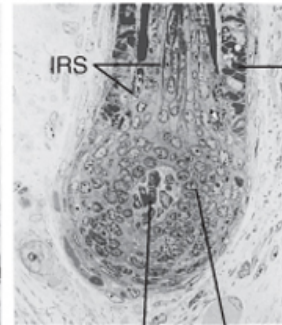
GM



**E**

DP

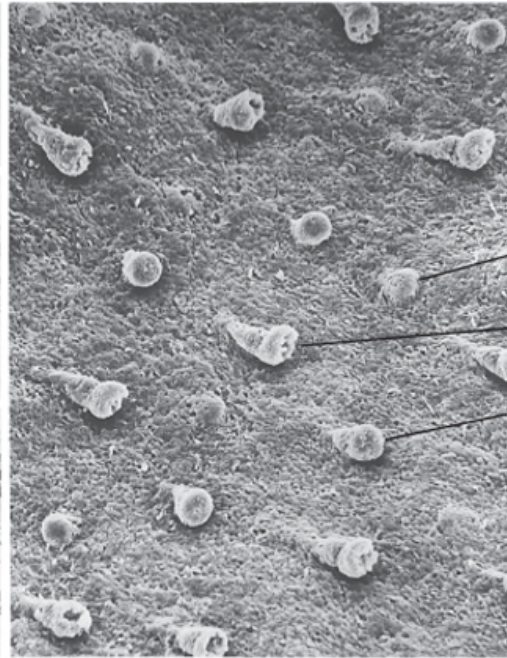
GM



**F**

DP

GM



**G**

HG

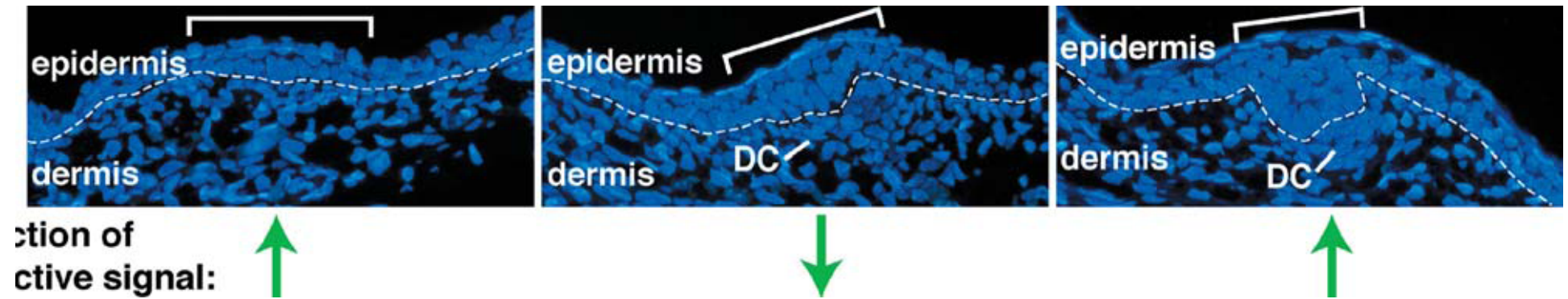
BHP

HP

ORS

IRS

# Hair follicle development





# Hair follicle development

## Formation of:

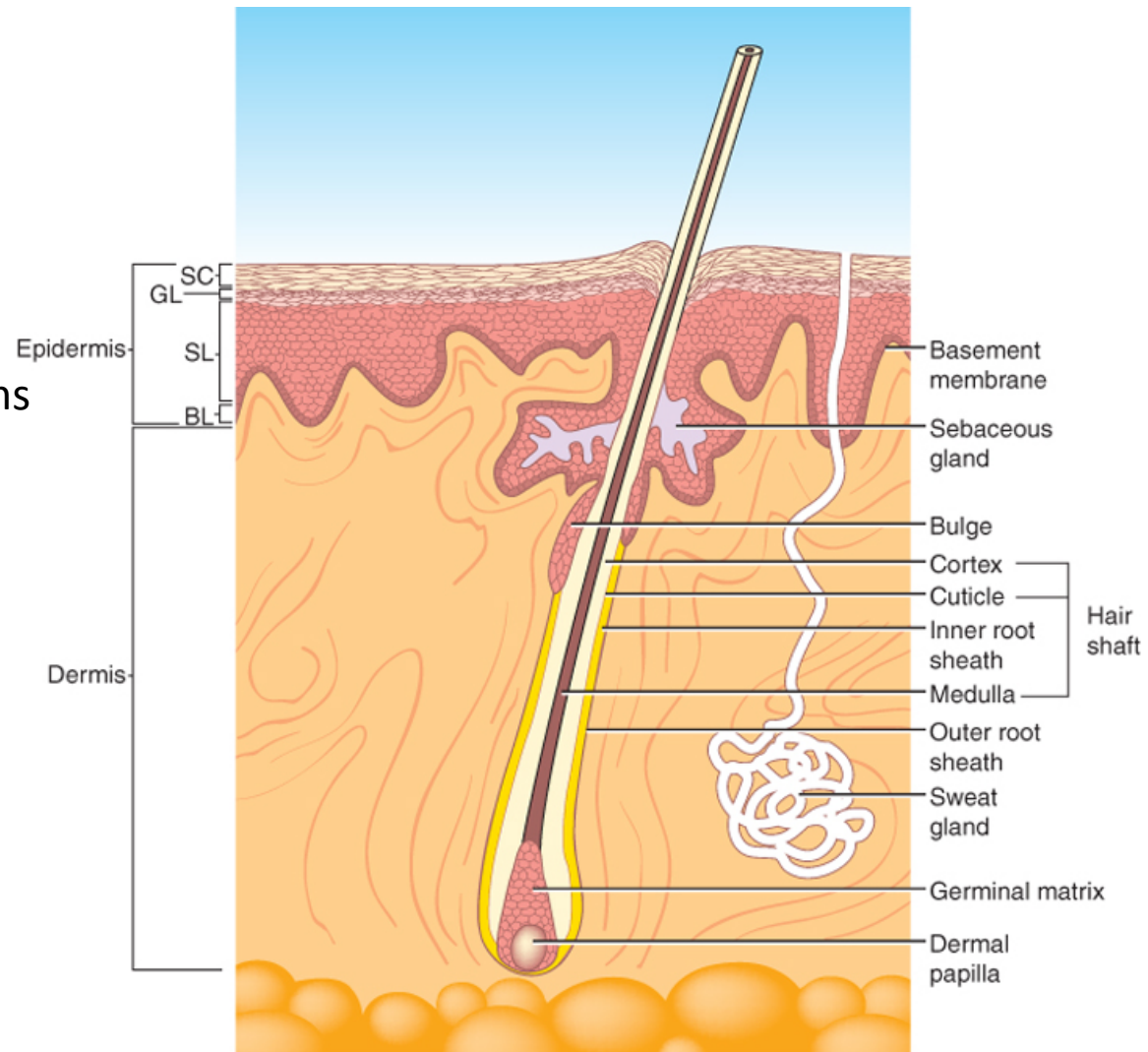
Arrector pili muscle

Hair follicle bulge

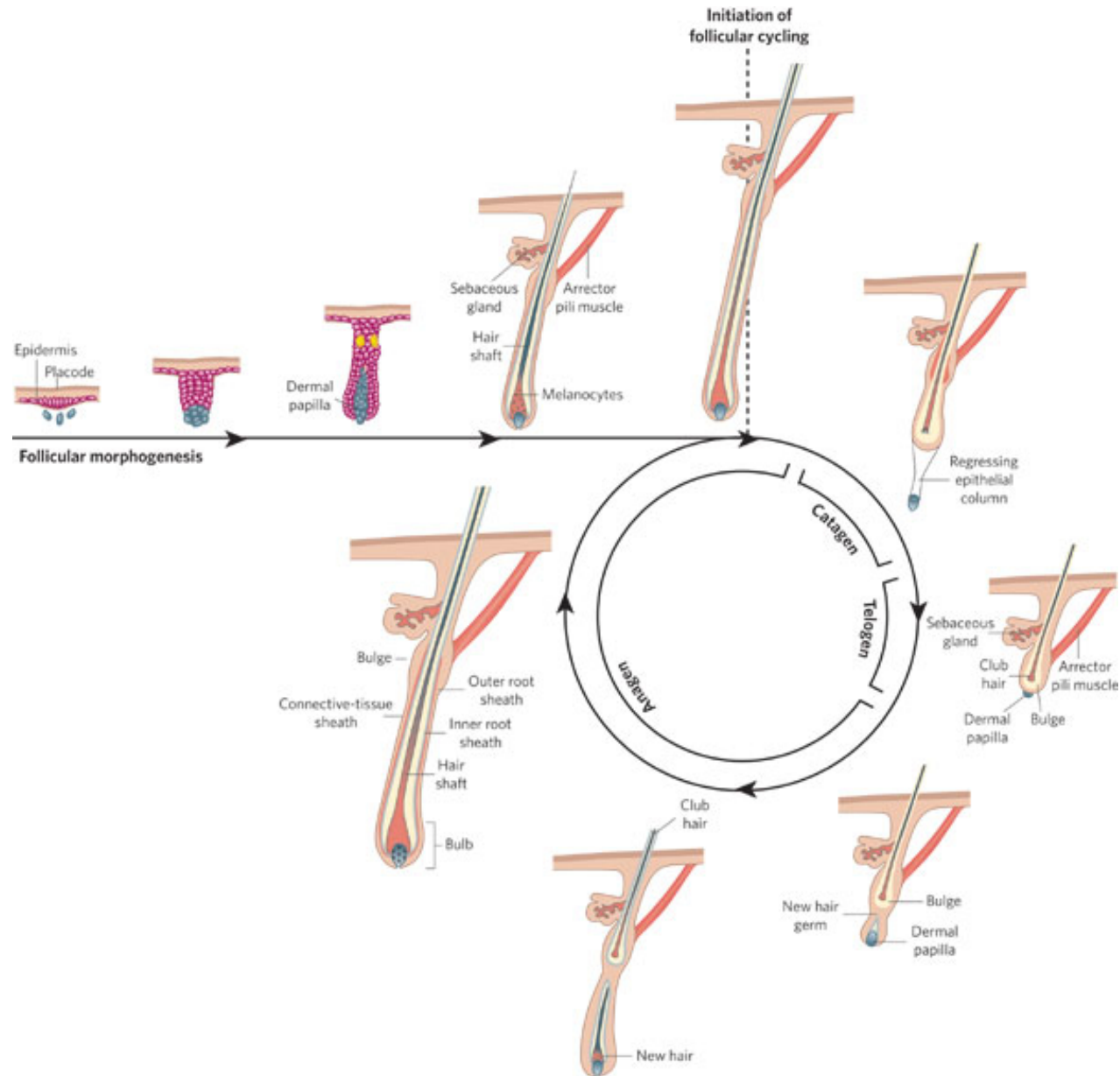
Germinal matrix

Inner and outer root sheaths

Babies are born with first generation of fine un-pigmented hairs: lanugo



# Postnatal hair follicle cycling



# Epidermal gland development

## Epidermal appendages

Sebaceous glands: sebum/vernix

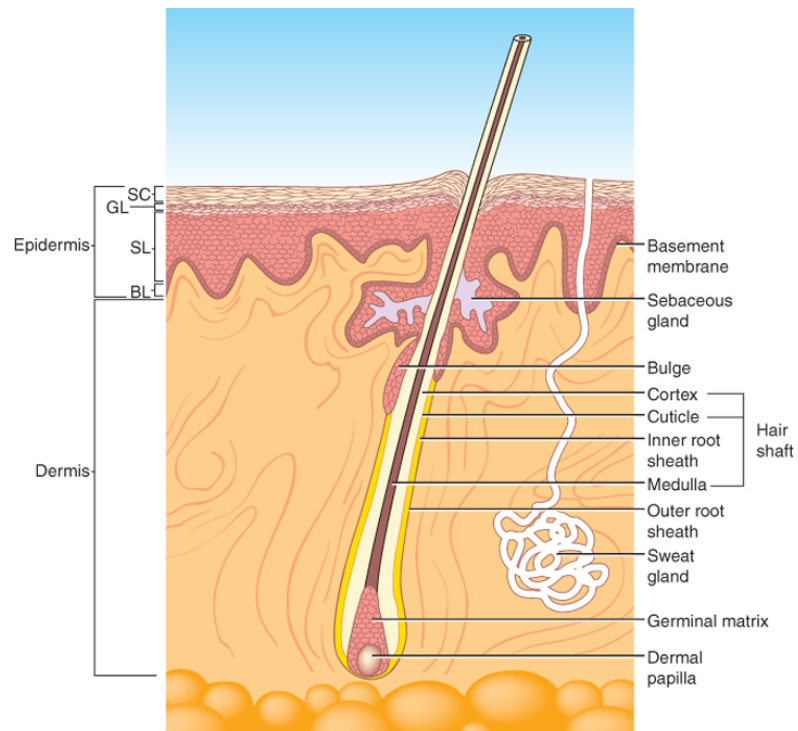
Sweat glands

Apocrine glands ('smelly' glands)

Mammary glands

Salivary glands

Lacrimal glands



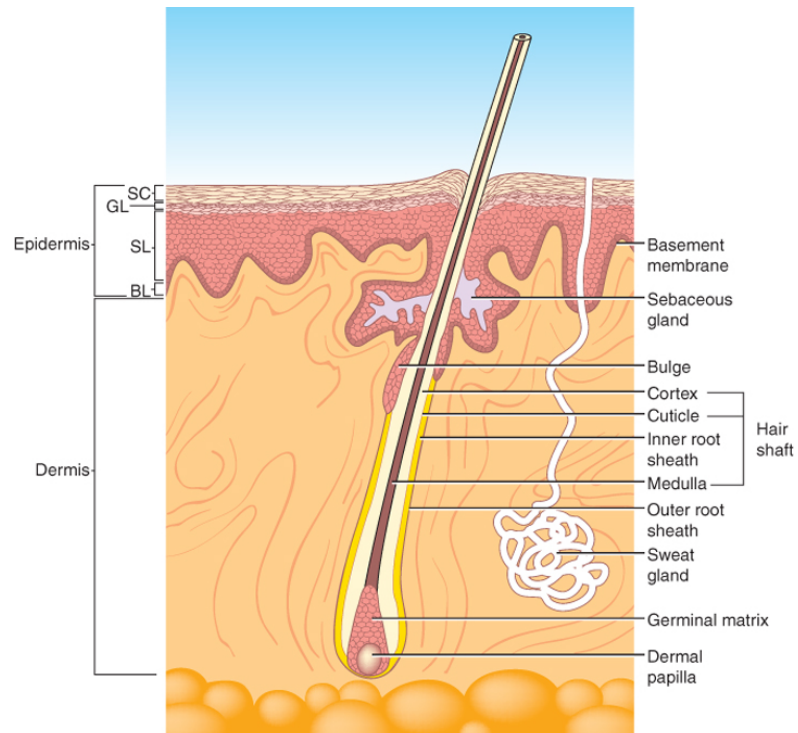
# Epidermal gland development

## Epidermal appendages

Sebaceous glands: develop from hair follicle (4 weeks +)

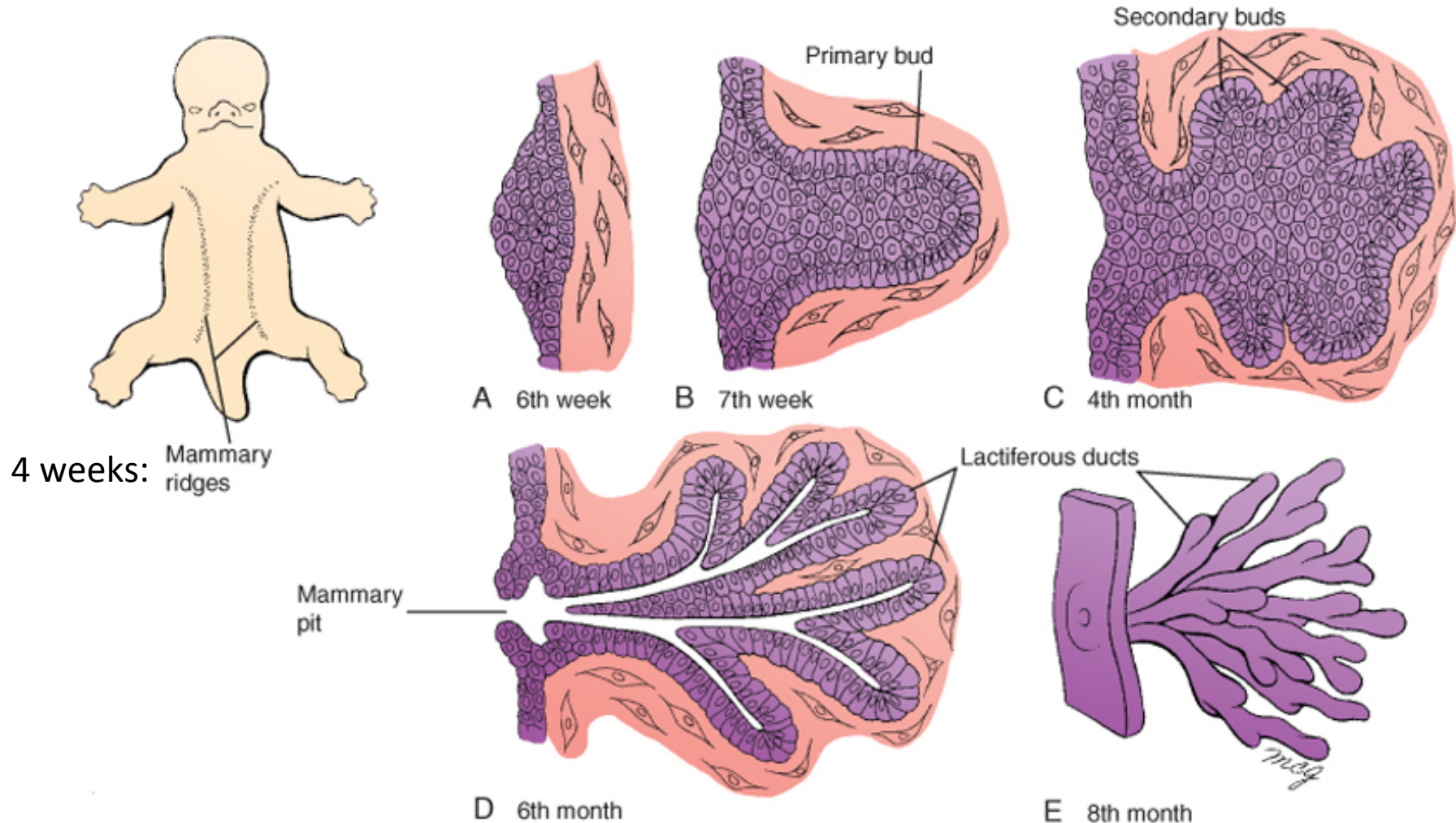
Sweat glands: develop from basal layer IFE (20 weeks+)

Apocrine glands: develop in association with HFs, most lost late in fetal dev.



# Mammary gland development

## Epidermal appendage



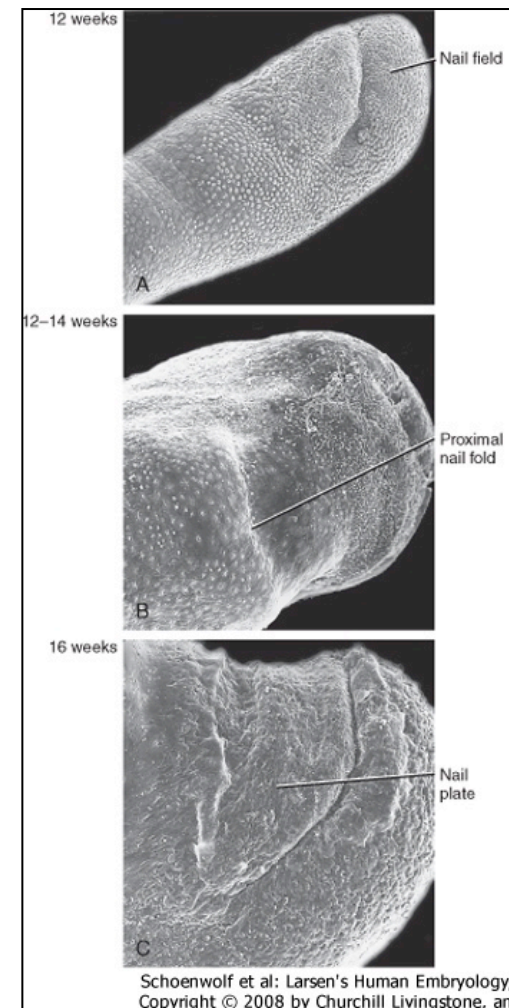


# Nail development

## Ectoderm

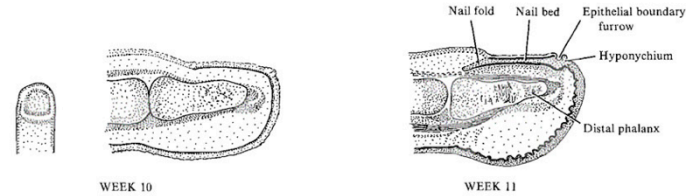
Week 10: epidermal thickening, nail field

Week 11: nail anlagen moves proximally, nail folds, proximal nail fold: formation of formative zone



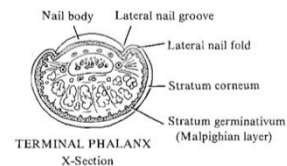
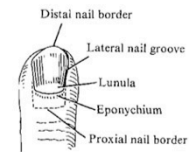
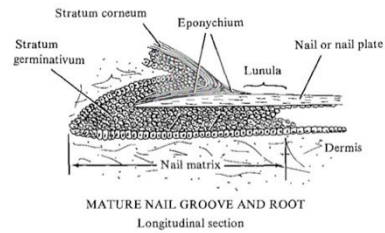
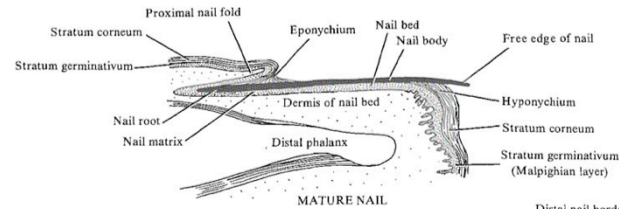
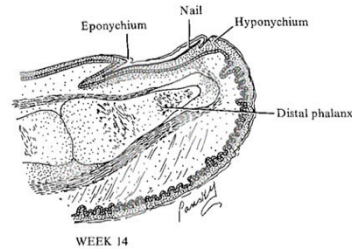
# Nail development

## Ectoderm



### DEVELOPMENT OF FINGERNAIL

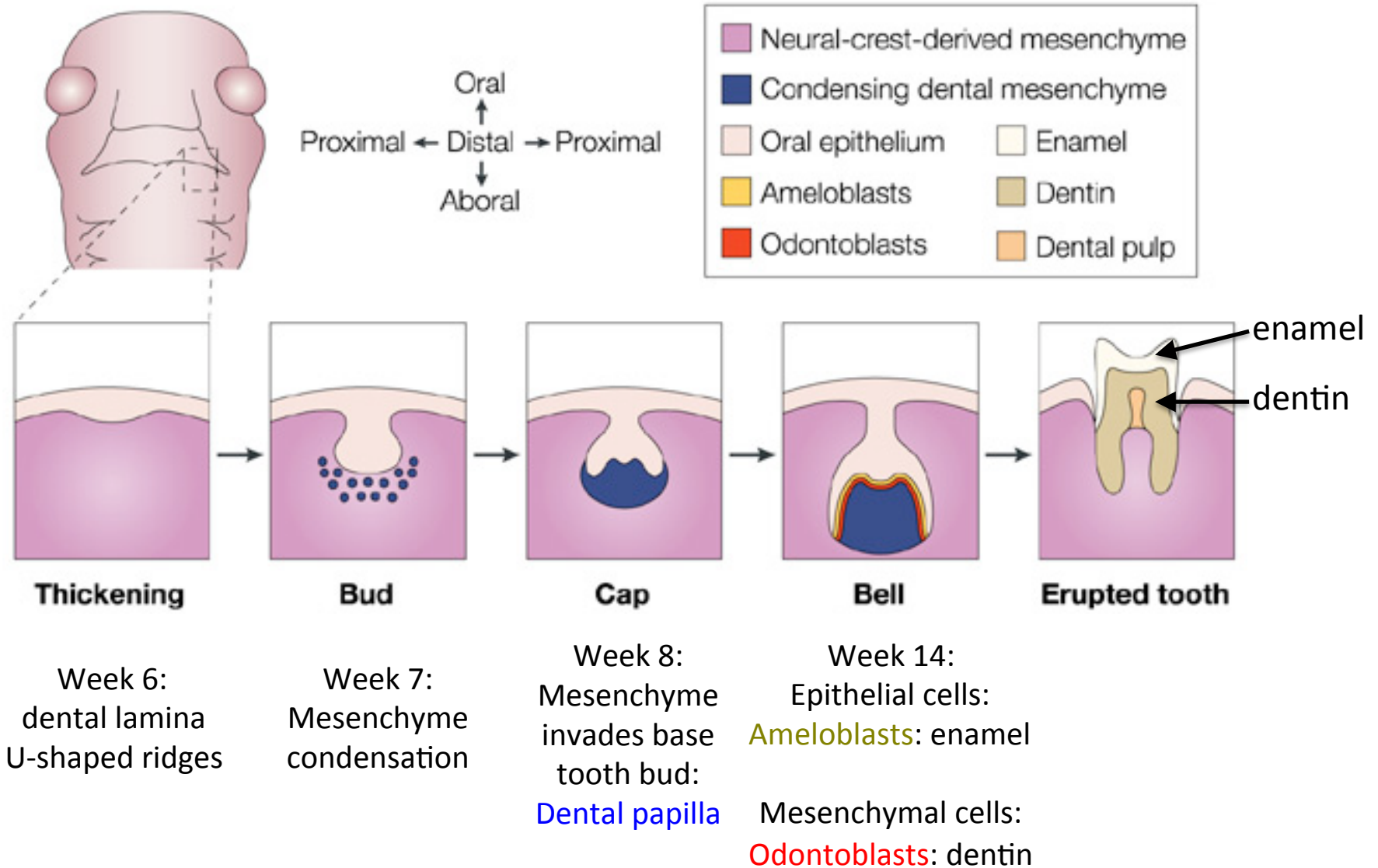
Sections of fingertip





# Tooth development

Ectoderm/cranial neural crest derived mesenchyme

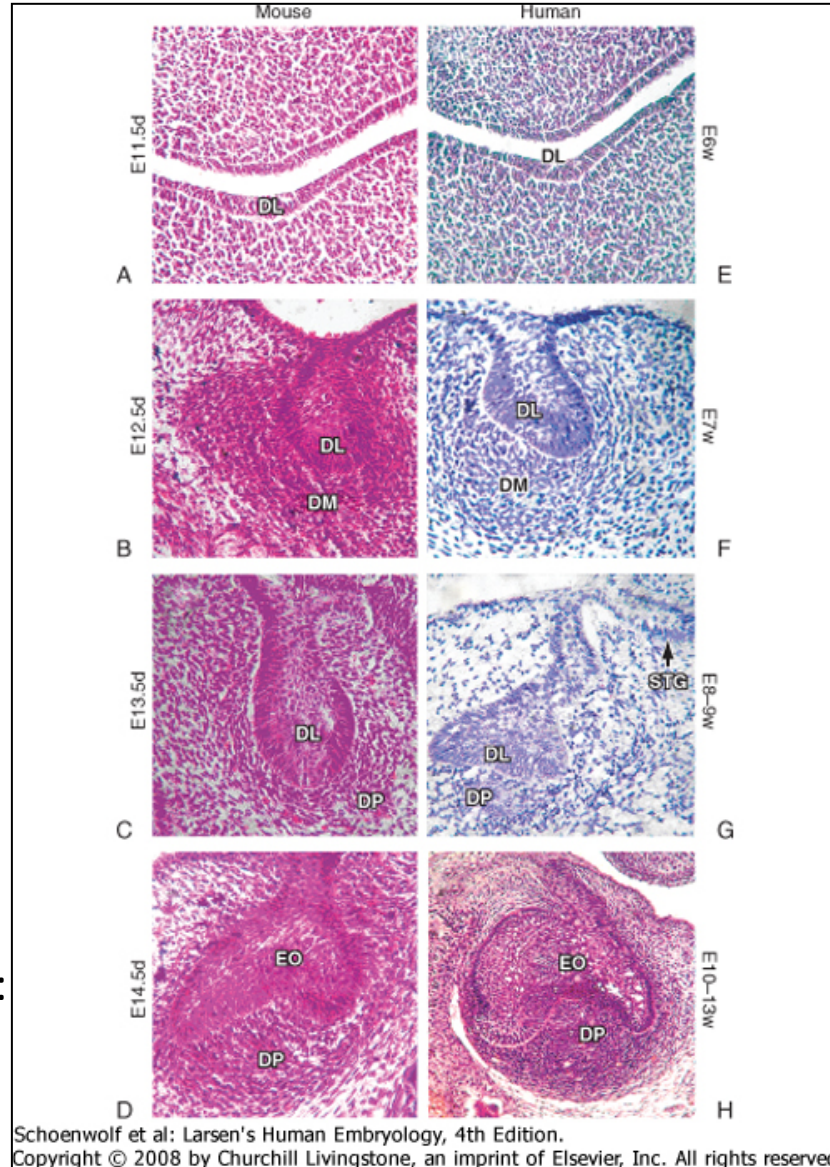


# Tooth development

Week 6: dental lamina forms

Week 7-8: formation of tooth buds

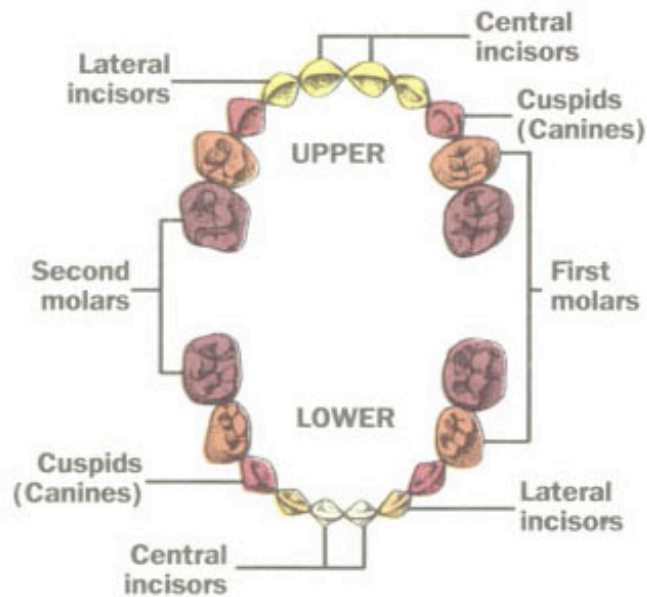
Week 8: formation of dental papilla:  
Bell Stage









# Tooth development

Primary teeth

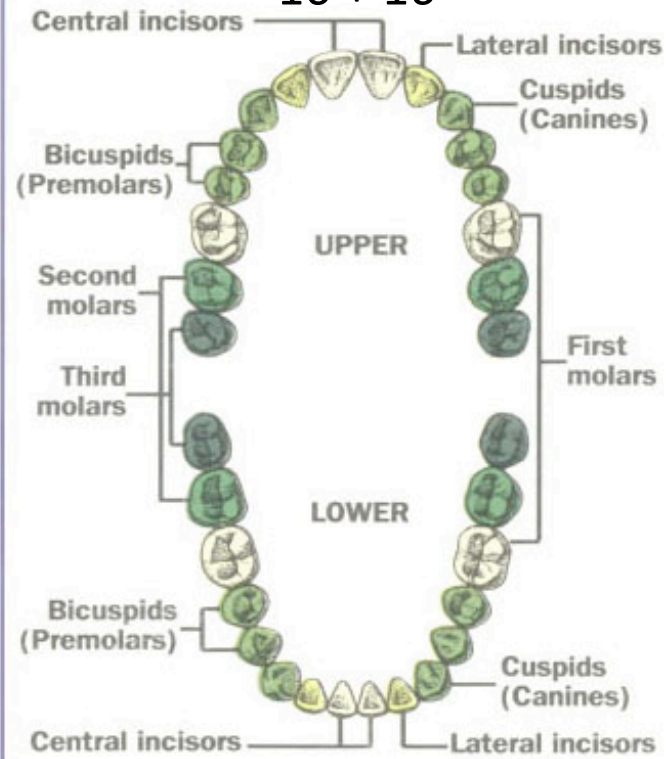
10 + 10



 6-10 months	 13-19 months
 8-13 months	 16-23 months
 10-16 months	 23-33 months

Adult teeth

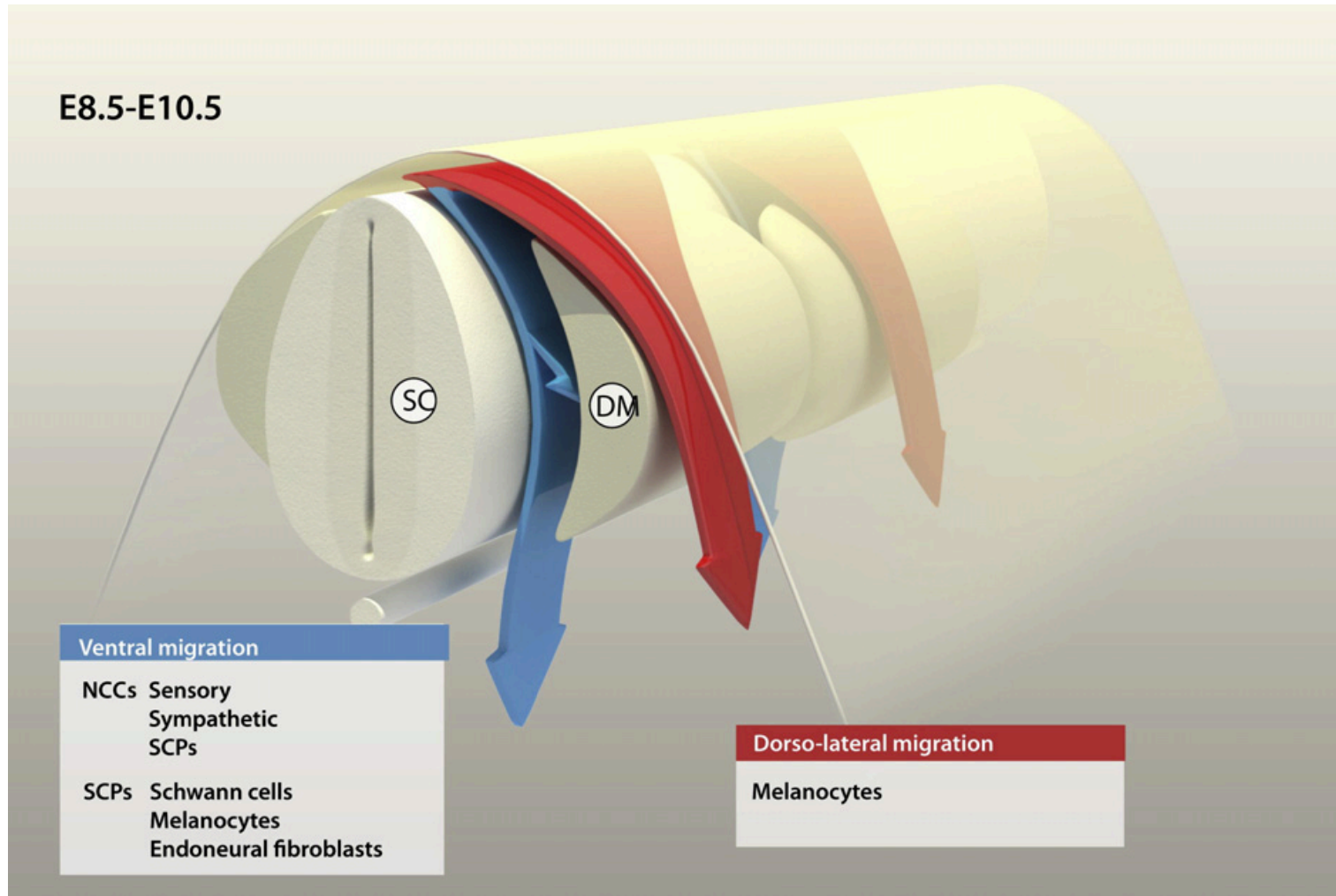
16 + 16



 6-8 years	 11-13 years
 7-9 years	 17-21 years
 9-12 years	

# Melanocyte development

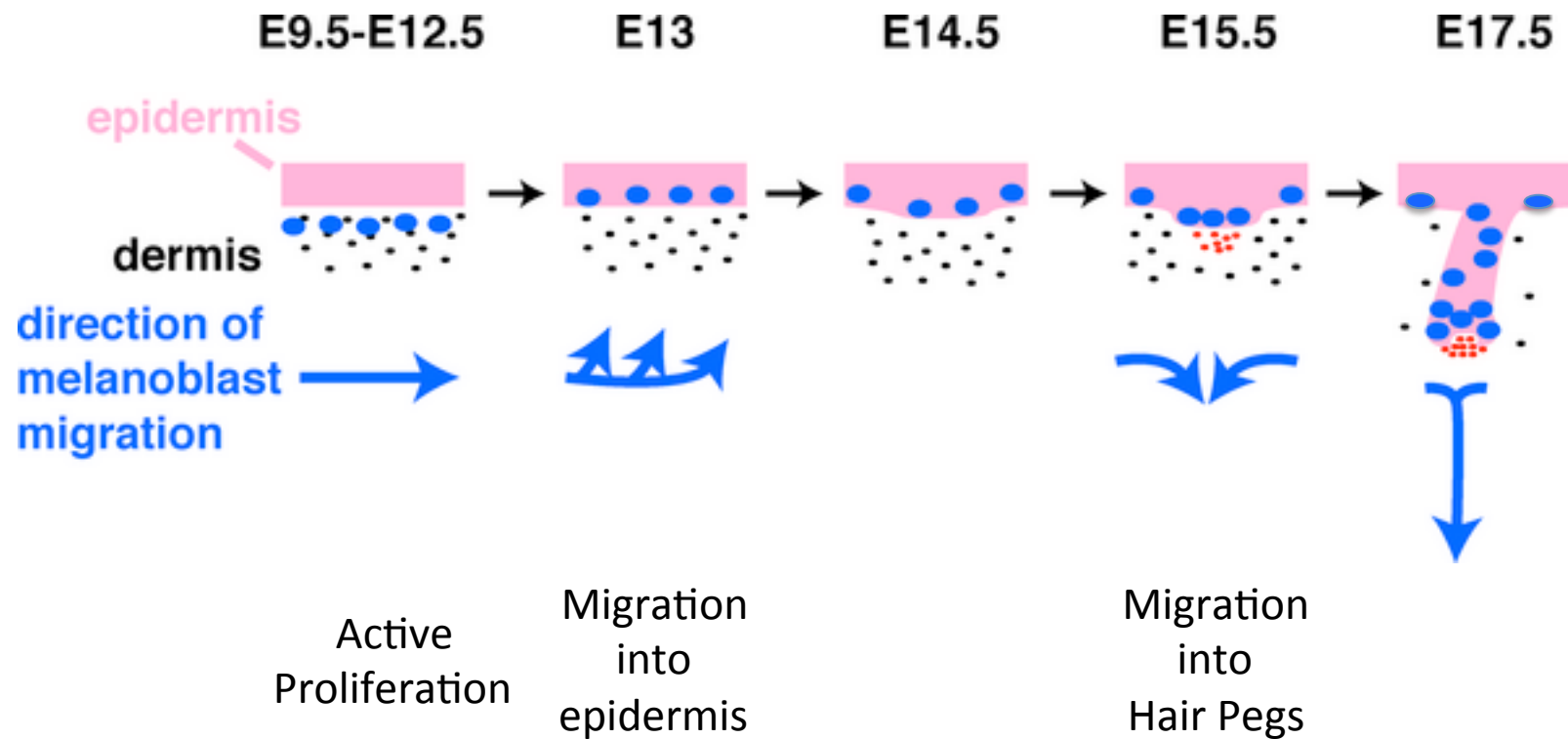
## Neural crest



Ernfors, Exp Cell Res 2010

# Melanocyte development

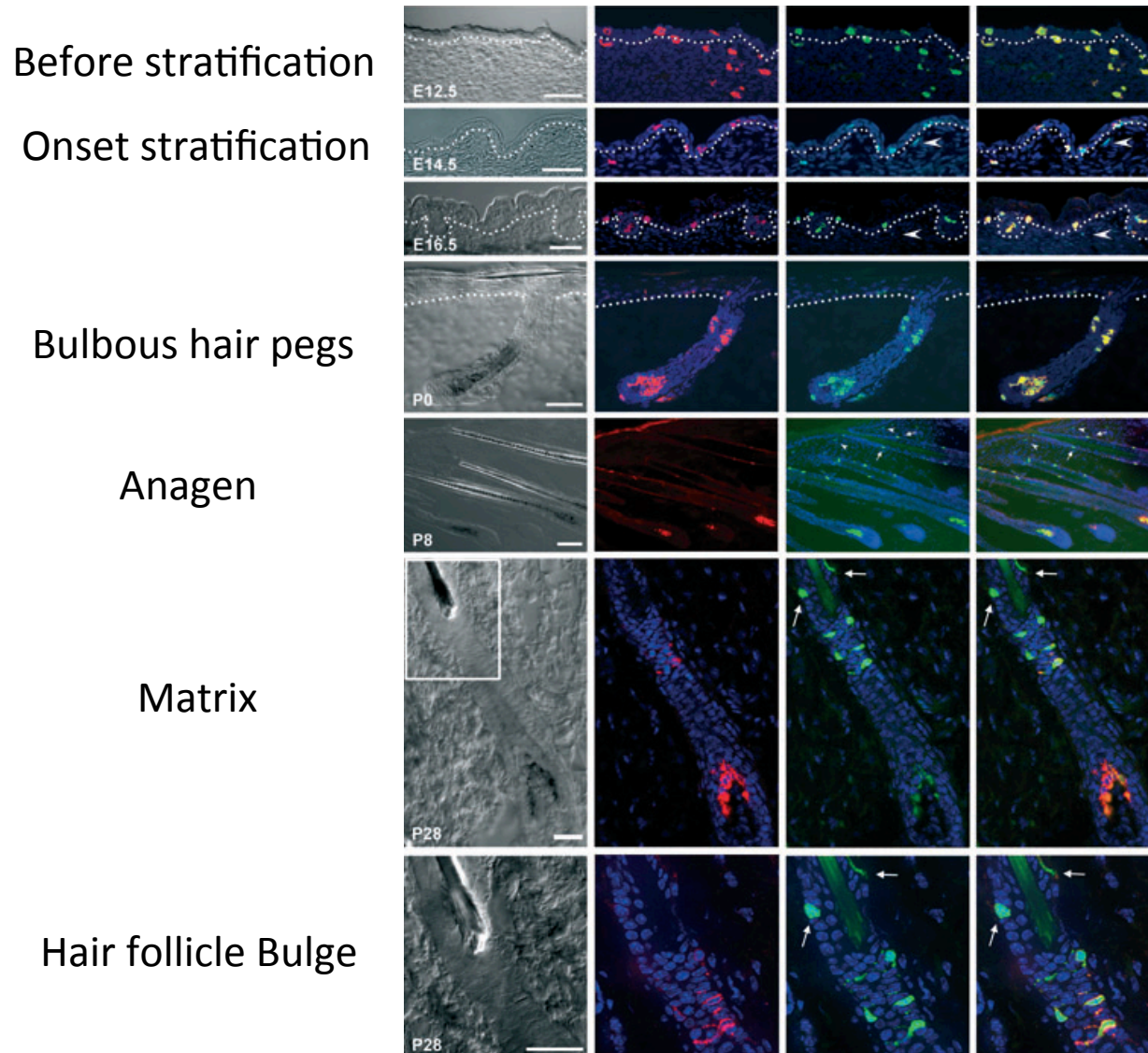
## Neural crest





# Melanocyte development

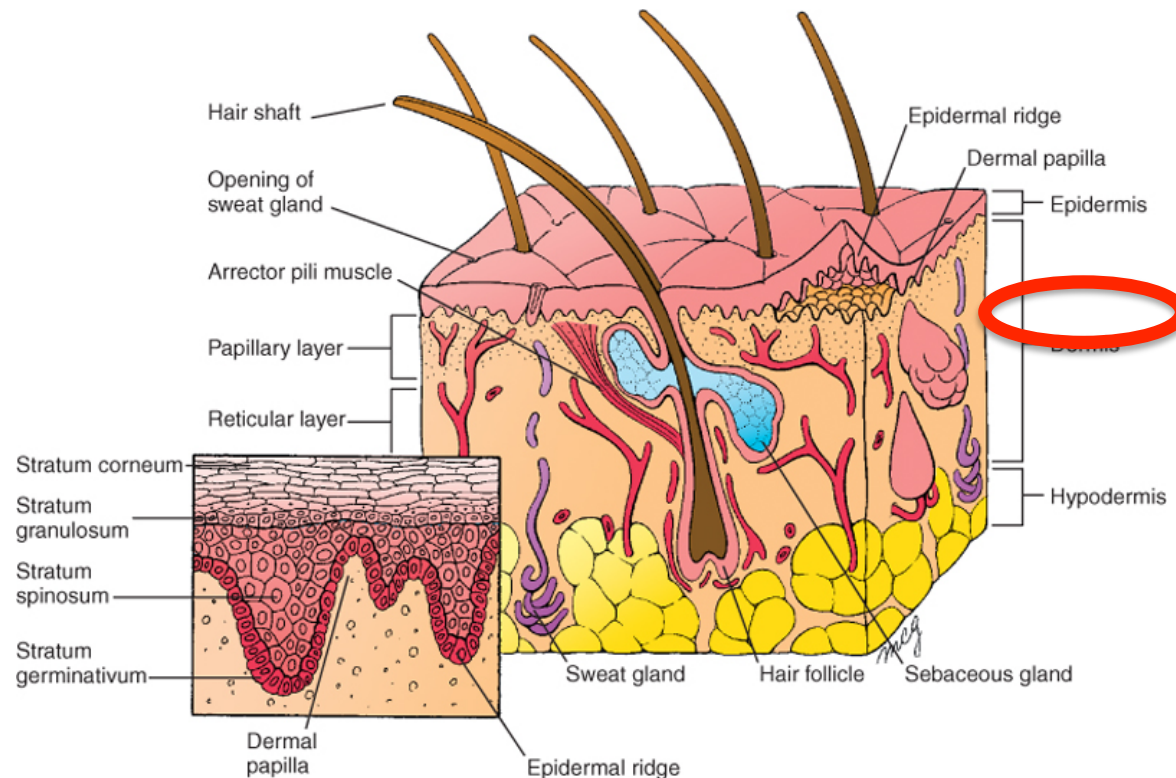
## Neural crest



Djian-Zaouche,  
Pigment Cell Melanoma Res 2012

# Dermis

Connective tissue with:  
Fibroblasts  
Blood vessels  
Nerve endings  
Sensory receptors  
Muscle bundles



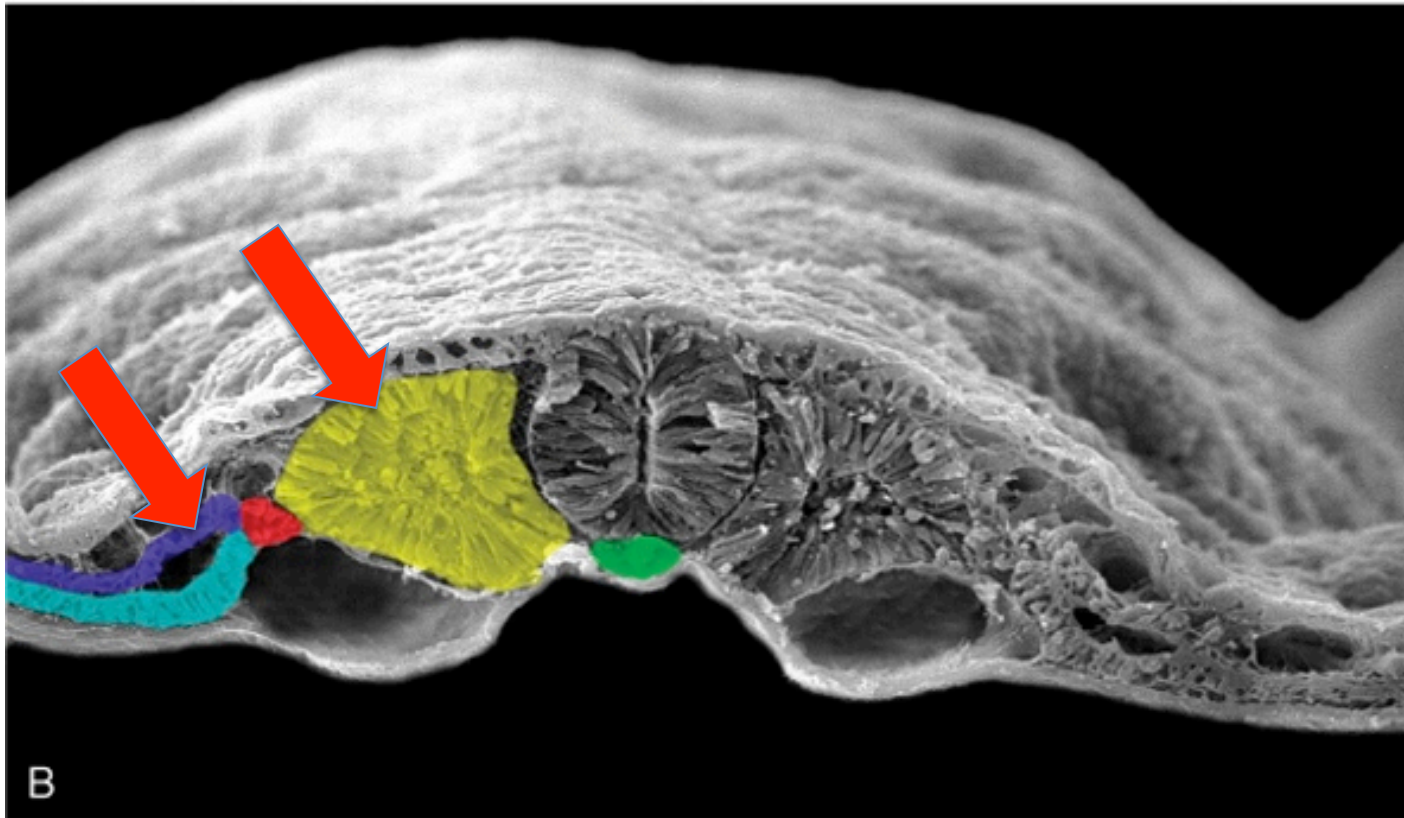


# Dermis development

Somitic mesoderm

Somatic lateral plate mesoderm

Cranial neural crest derived mesenchyme

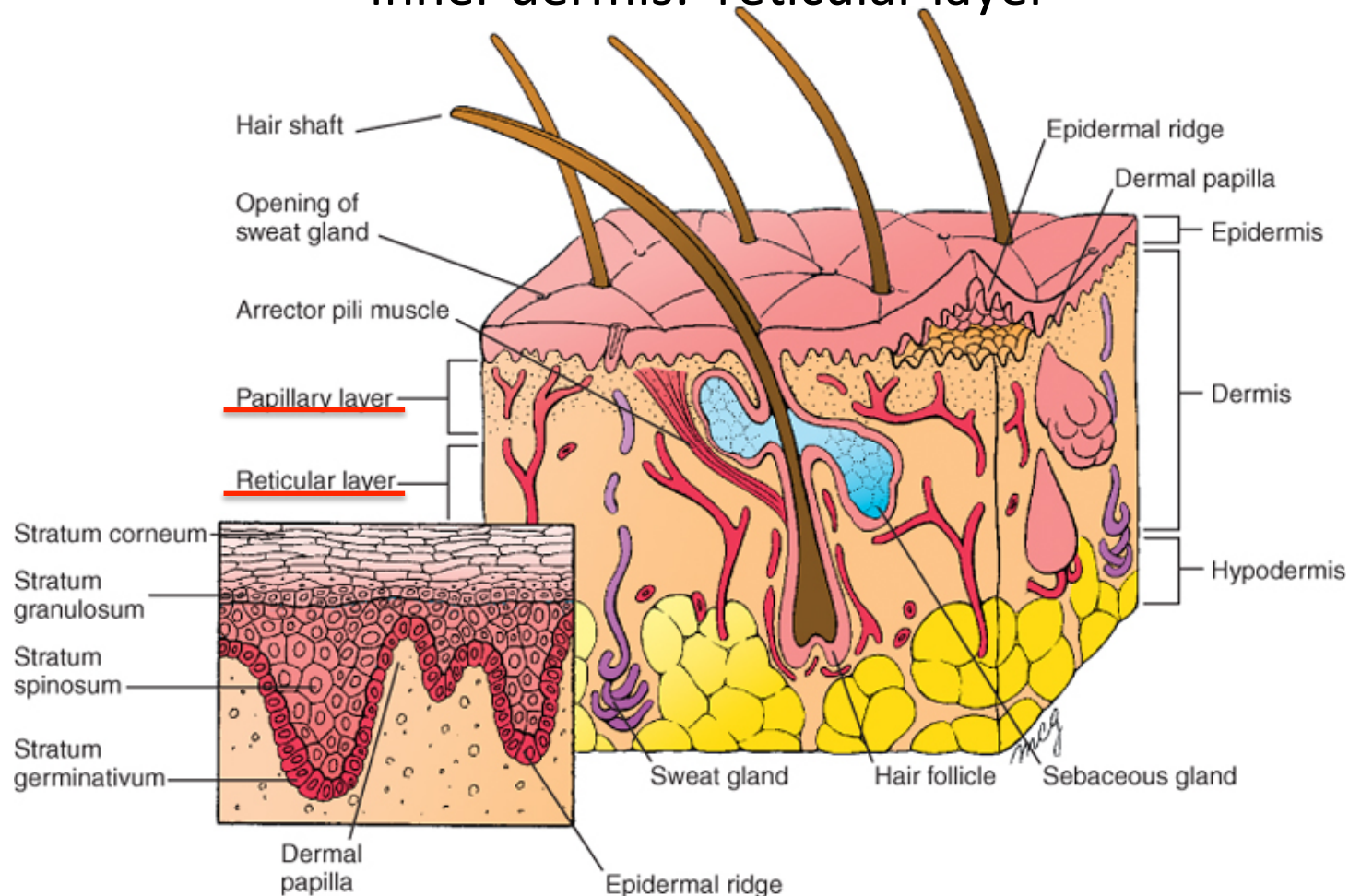


Schoenwolf et al: Larsen's Human Embryology, 4th Edition.  
Copyright © 2008 by Churchill Livingstone, an imprint of Elsevier, Inc. All rights reserved

# Dermis development

3 Months: formation of papillary layer  
(dermal papillae and epidermal ridges)

Inner dermis: reticular layer



Schoenwolf et al: Larsen's Human Embryology, 4th Edition.

Copyright © 2008 by Churchill Livingstone, an imprint of Elsevier, Inc. All rights reserved

# Lecture overview

Skin

Skin origins

Development of the overlying epidermis

Development of epidermal appendages:

*Hair follicles*

*Glands*

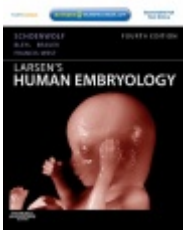
*Mammary glands*

*Nails*


*Teeth*

Development of Melanocytes

Development of the Dermis



Resources:  
<http://php.med.unsw.edu.au/embryology/>  
Larsen's Human Embryology  
The Developing Human: Clinically Oriented Embryology



Dr Annemiek Beverdam – School of Medical Sciences, UNSW  
Wallace Wurth Building Room 234 – A.Beverdam@unsw.edu.au