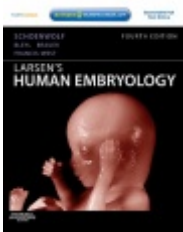



Development of the skin and its derivatives



Resources:
<http://php.med.unsw.edu.au/embryology/>
Larsen's Human Embryology
The Developing Human: Clinically Oriented Embryology



Dr Annemiek Beverdam – School of Medical Sciences, UNSW
Wallace Wurth Building Room 234 – A.Beverdam@unsw.edu.au

Lecture overview

Skin

Skin origins

Development of the overlying epidermis

Development of epidermal appendages:

Hair follicles

Glands

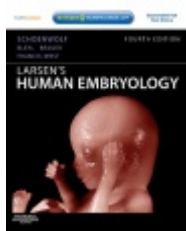
Mammary glands

Nails

Teeth

Development of melanocytes

Development of the Dermis



Resources:
<http://php.med.unsw.edu.au/embryology/>
Larsen's Human Embryology
The Developing Human: Clinically Oriented Embryology



Dr Annemiek Beverdam – School of Medical Sciences, UNSW
Wallace Wurth Building Room 234 – A.Beverdam@unsw.edu.au

Skin

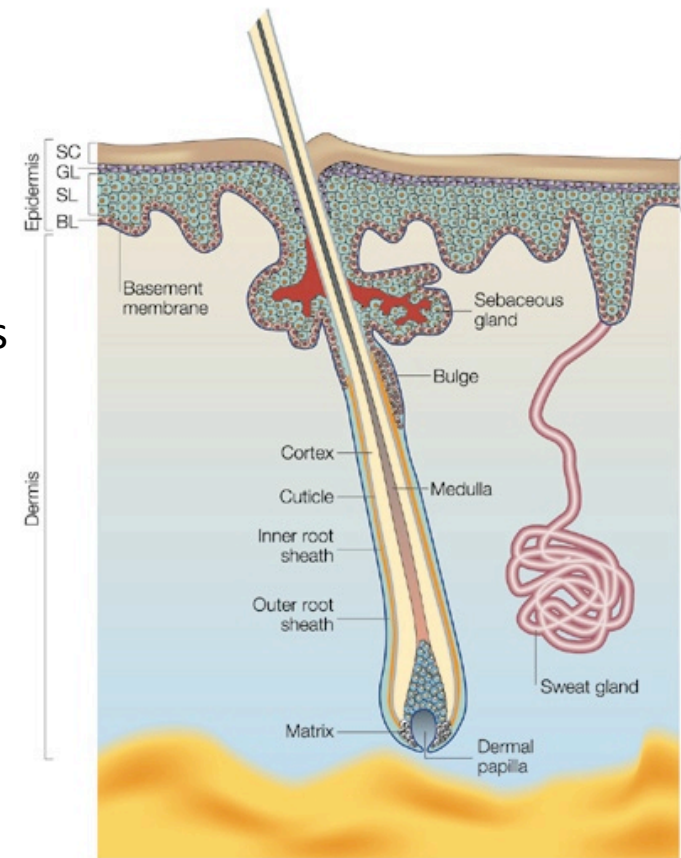
Largest organ of our body

Protects inner body from outside world (pathogens, water, sun)

Thermoregulation

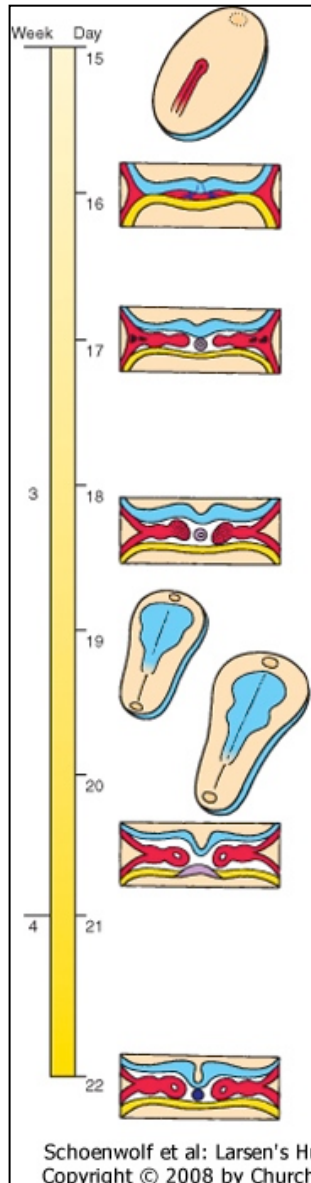
Consists of:

- Overlying epidermis
- Epidermal appendages:
 - hair follicles,
 - sebaceous glands, sweat glands, apocrine glands
 - Mammary glands
 - Nails
 - Teeth
- Melanocytes
- Dermis
- Hypodermis



Skin origins

Trilaminar embryo



Ectoderm (Neural crest)

brain, spinal cord, eyes, *peripheral nervous system*
epidermis of skin and associated structures, *melanocytes*
cranial connective tissues (dermis)

Mesoderm

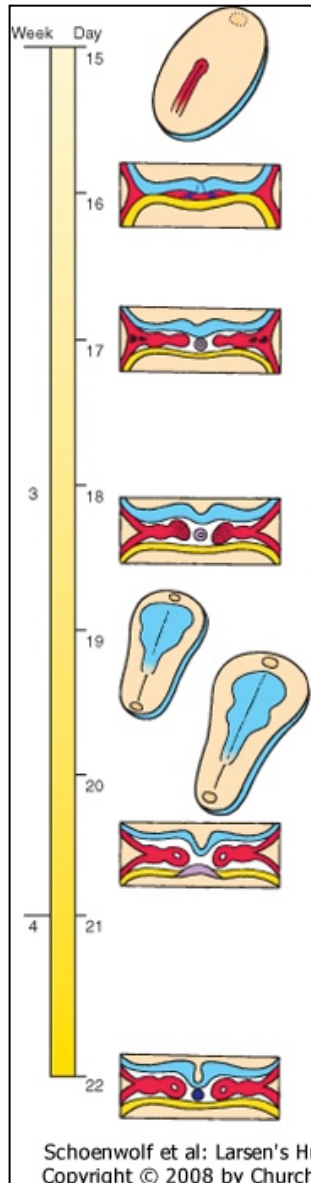
musculo-skeletal system
limbs
connective tissue of skin and organs
kidneys, heart, blood cells

Endoderm

epithelial linings of gastrointestinal and respiratory tracts

Skin origins

Trilaminar embryo



Ectoderm (Neural crest)

brain, spinal cord, eyes, *peripheral nervous system*
epidermis of skin and associated structures,
melanocytes, cranial connective tissues (dermis)

Mesoderm

musculo-skeletal system
limbs
connective tissue of skin and organs
kidneys, heart, blood cells

Endoderm

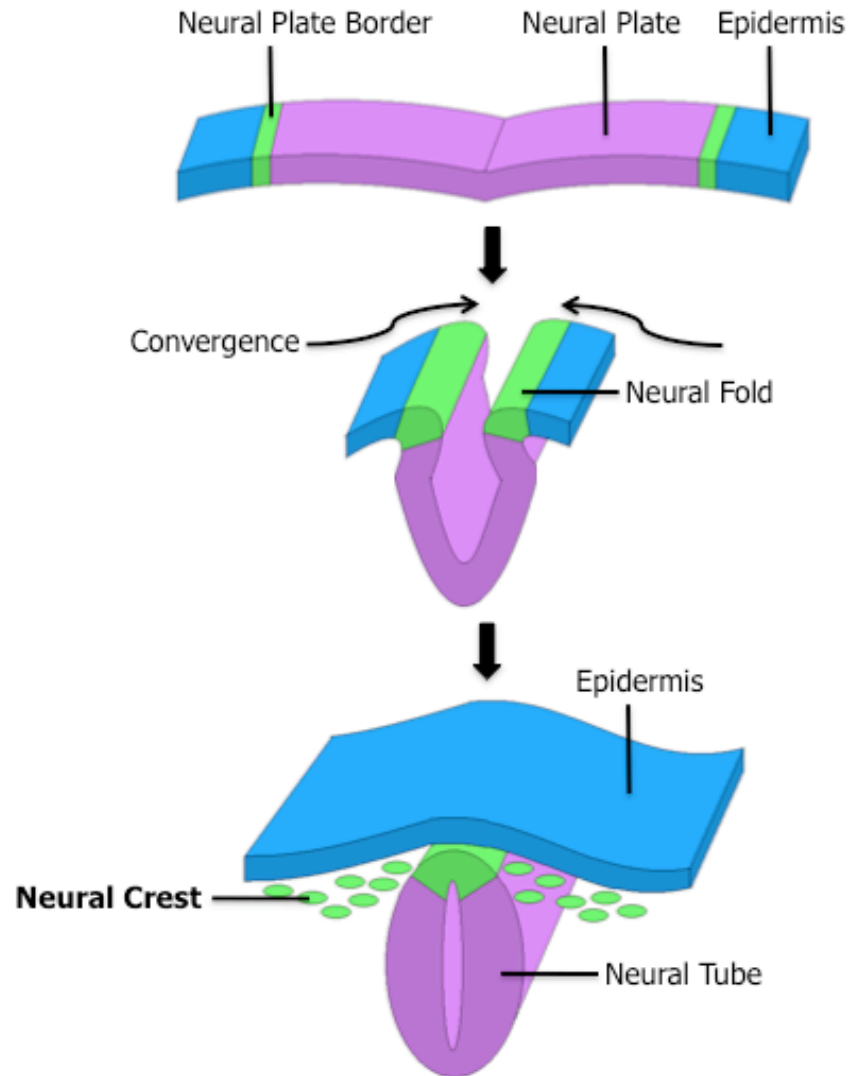
epithelial linings of gastrointestinal and respiratory tracts

Ectoderm

Overlying epidermis + epidermal appendages

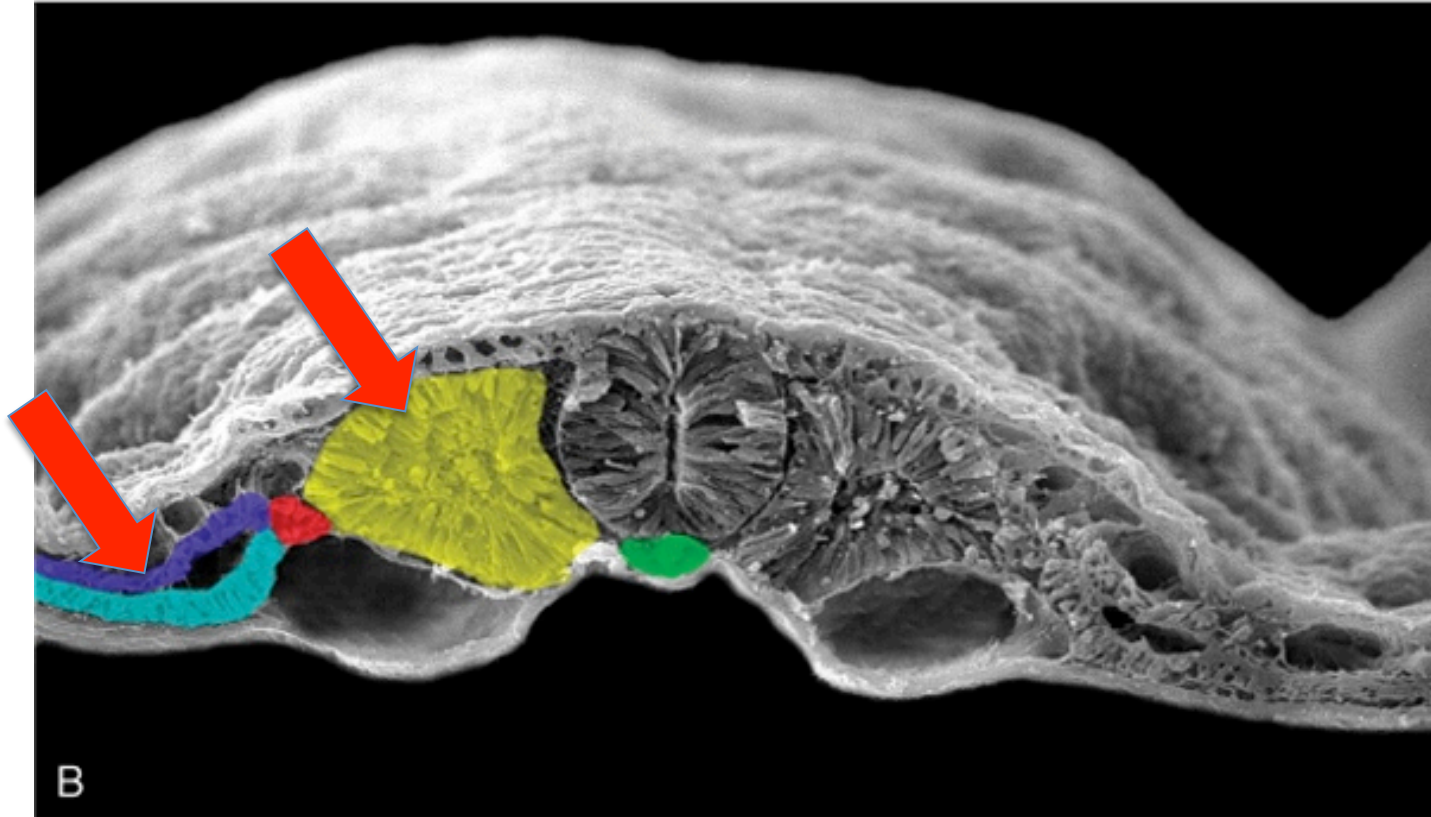


Neural Crest Melanocytes



Mesoderm

Dermis, Hypodermis



Schoenwolf et al: Larsen's Human Embryology, 4th Edition.
Copyright © 2008 by Churchill Livingstone, an imprint of Elsevier, Inc. All rights reserved

Somitic mesoderm (yellow): dermomyotome
Somatic lateral plate mesoderm (purple)

Epidermal development

Surface ectoderm

Skin/Interfollicular epidermis

Appendages:

- Hair follicles

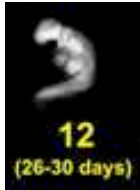- Glands (sebaceous, sweat, apocrine)

- Mammary glands

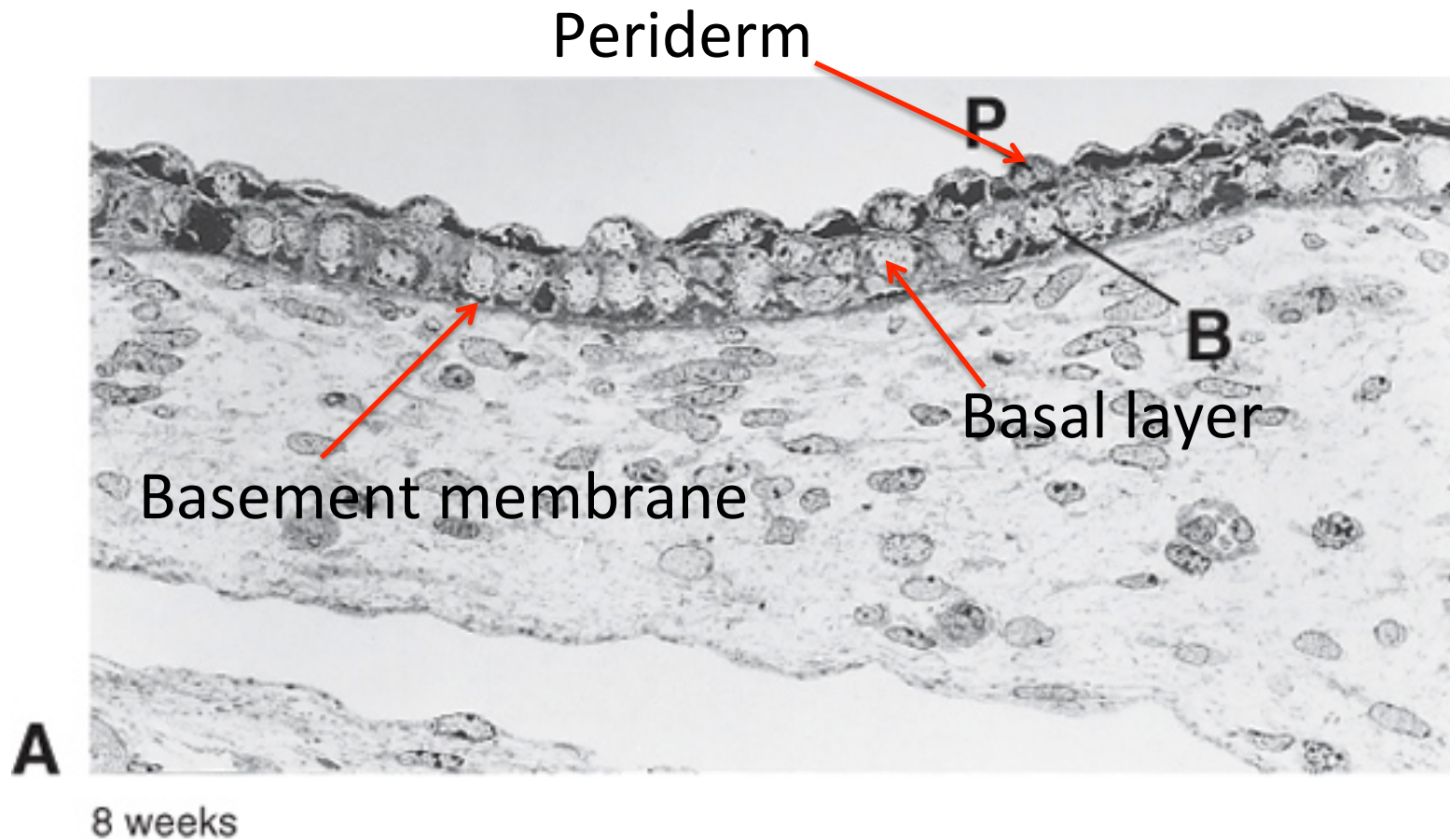
- Nails

- Teeth

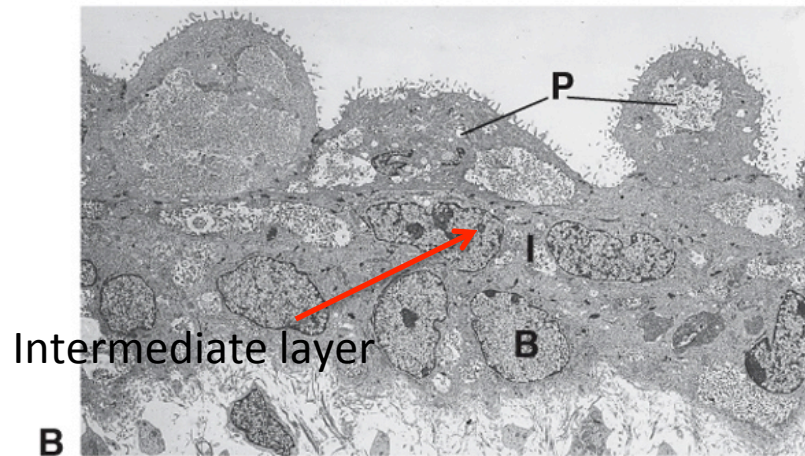
Development of Skin/nterfollicular epidermis (IFE)



Periderm formation: 4 weeks



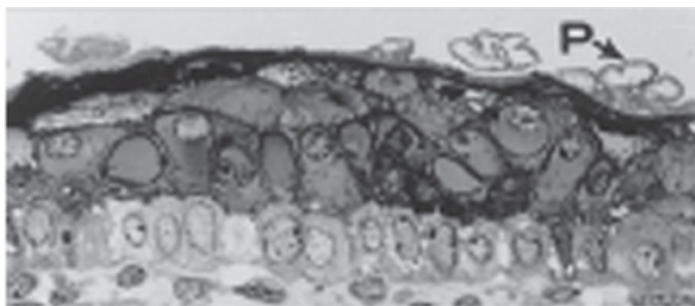
Development of Skin/nterfollicular epidermis (IFE) Stratification



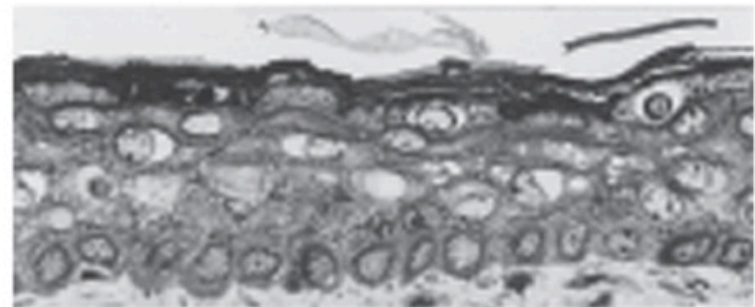
B

11 weeks
Schoenwolf et al: Larsen's Human Embryology, 4th Edition.
Copyright © 2008 by Churchill Livingstone, an imprint of Elsevier, Inc. All rights reserved

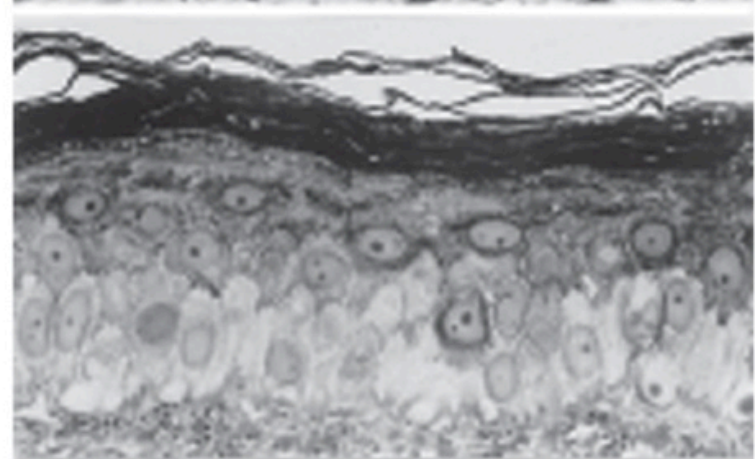
17 weeks



24 weeks



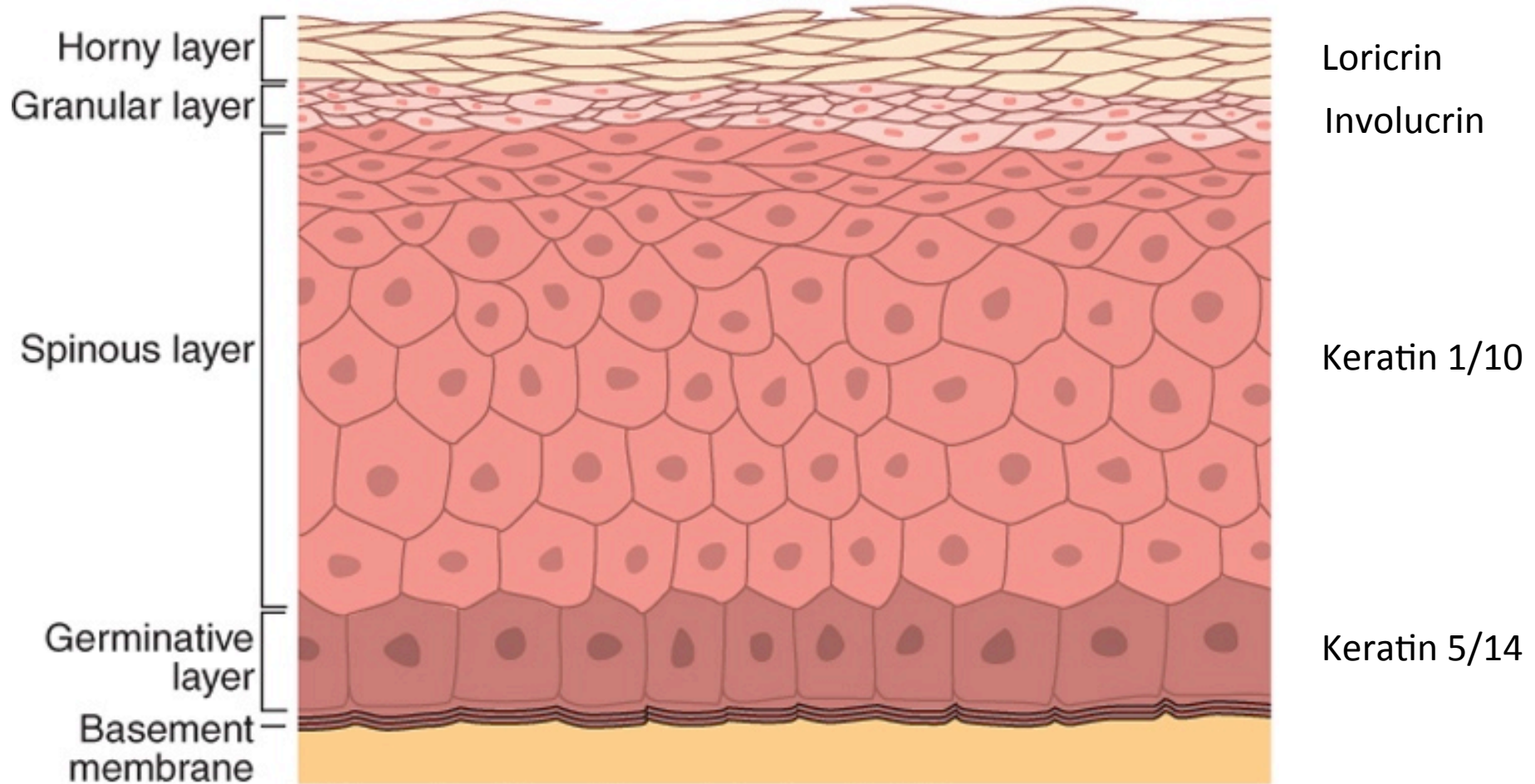
Adult



Schoenwolf et al: Larsen's Human Embryology, 4th Edition.
Copyright © 2008 by Churchill Livingstone, an imprint of Elsevier, Inc. All rights reserved

Stratified skin/IFE

Epidermis

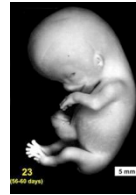

Schoenwolf et al: Larsen's Human Embryology, 4th Edition.
Copyright © 2008 by Churchill Livingstone, an imprint of Elsevier, Inc. All rights reserved.

Hair follicle development and cycling

Epidermal appendage

Involved in thermoregulation/sun protection



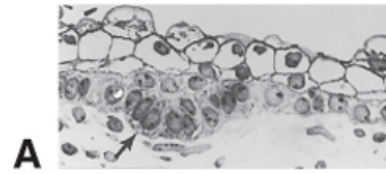
Month 2-4: Onset hair follicle development

Hair follicles develop first in cranial region

Month 5: most hair follicles present \approx 5,000,000 hair follicles

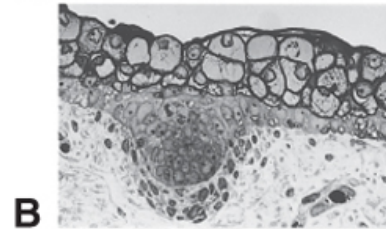
Hair follicle development

Hair germ



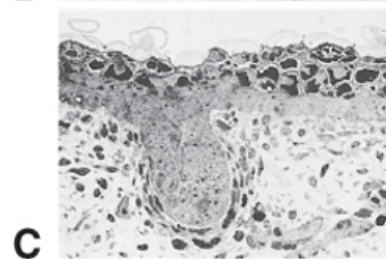
A

Hair peg



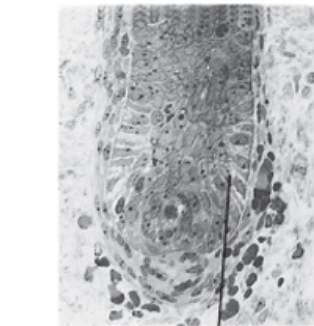
B

Bulbous hair peg



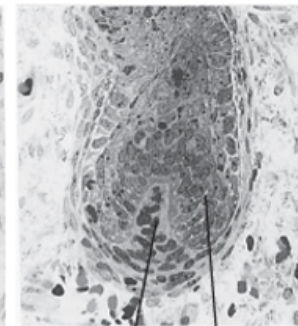
C

Invasion of dermis cells



D

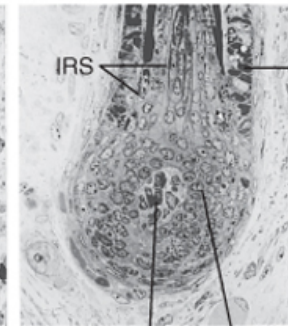
GM



E

DP

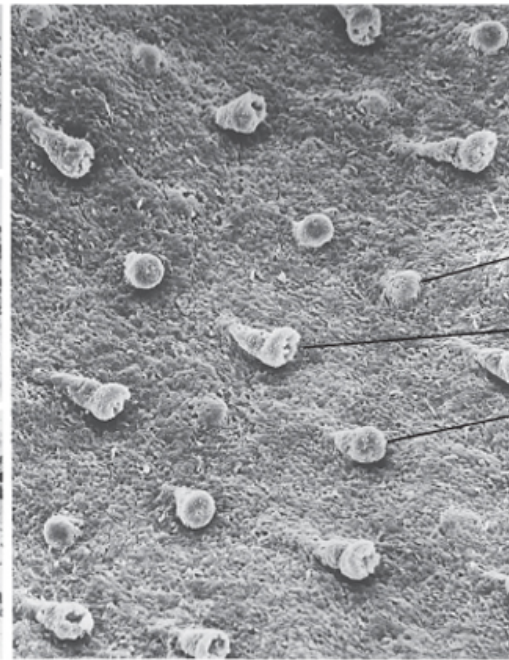
GM



F

DP

GM



G

HG

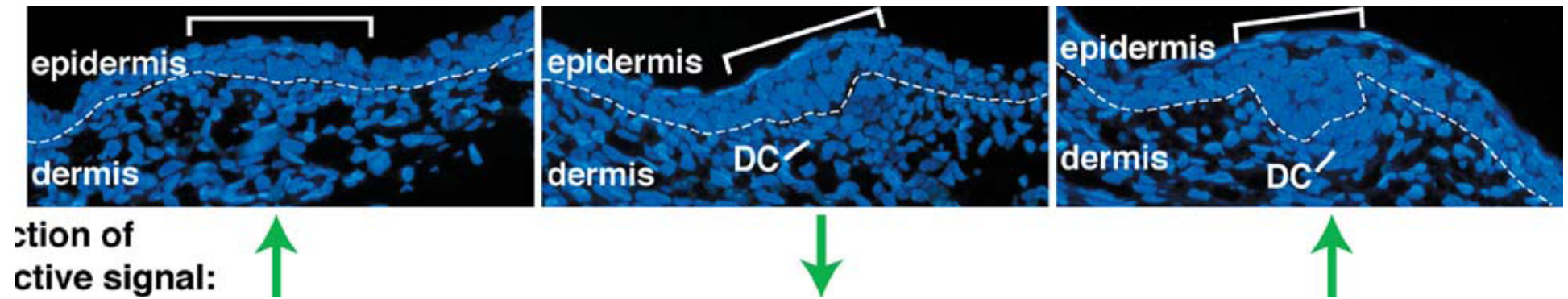
BHP

HP

ORS

IRS

Hair follicle development



Hair follicle development

Formation of:

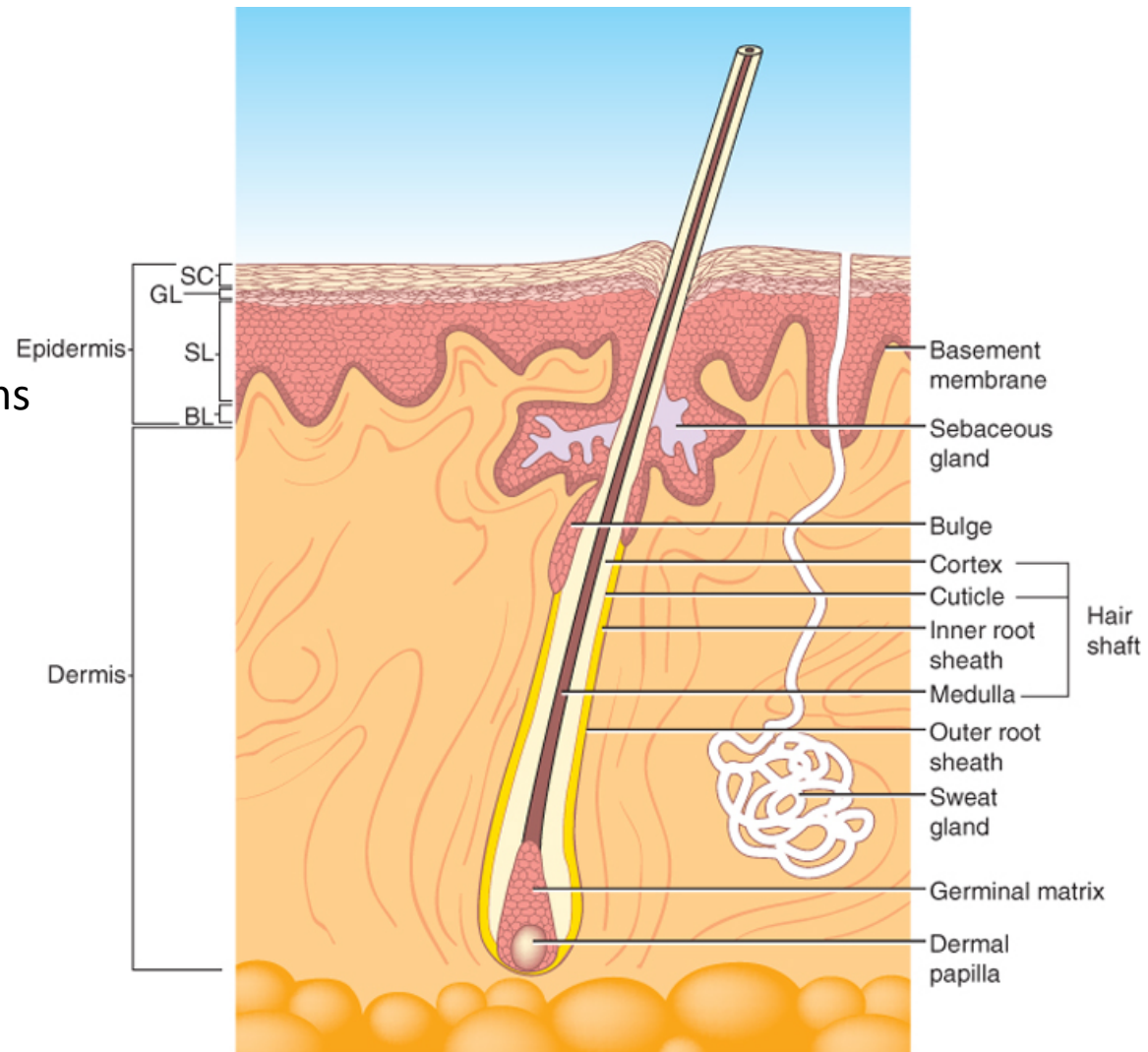
Arrector pili muscle

Hair follicle bulge

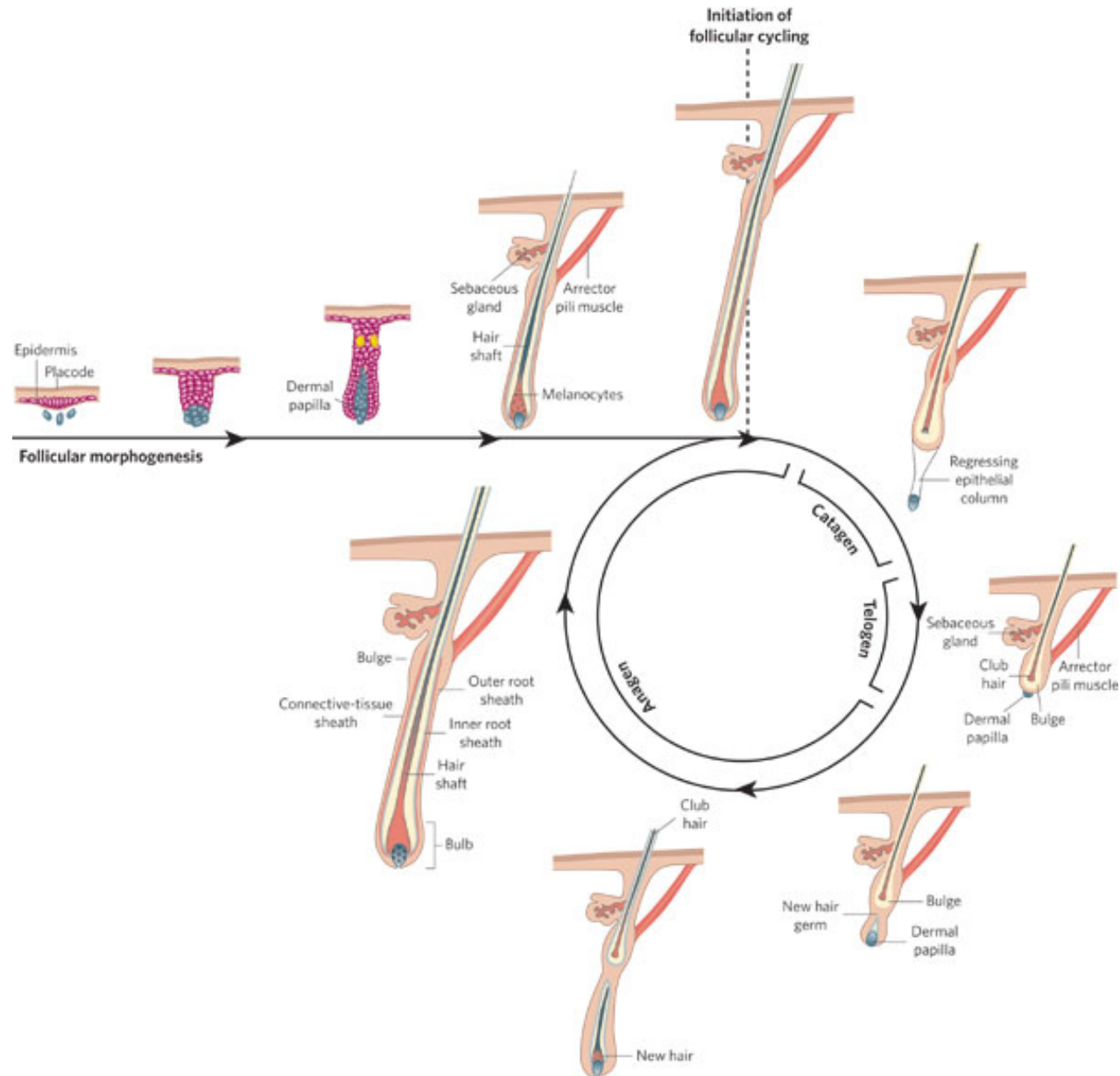
Germinal matrix

Inner and outer root sheaths

Babies are born with first generation of fine un-pigmented hairs: lanugo



Postnatal hair follicle cycling



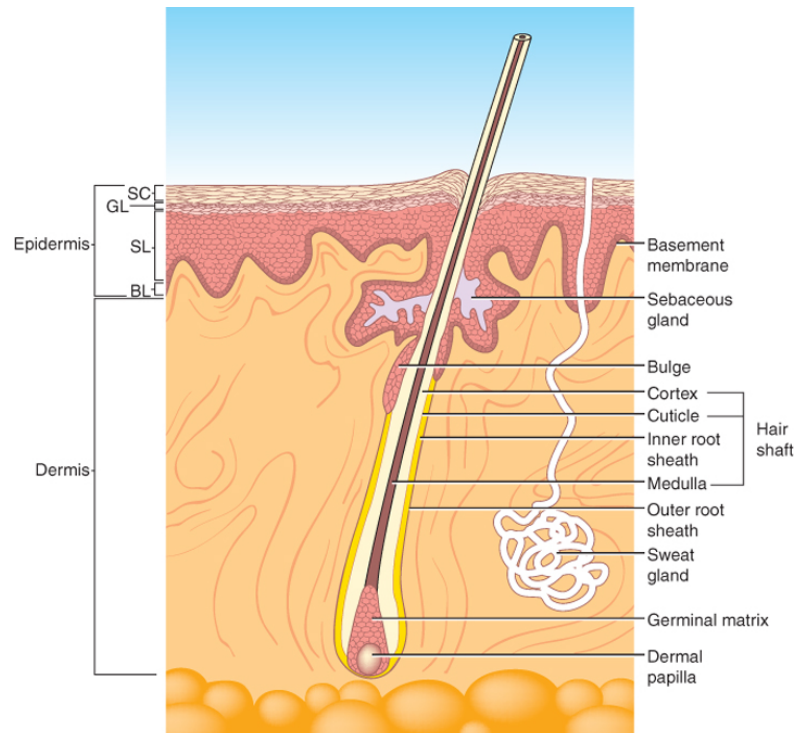
Epidermal gland development

Epidermal appendages

Sebaceous glands: sebum/vernix

Sweat glands

Apocrine glands ('smelly' glands)



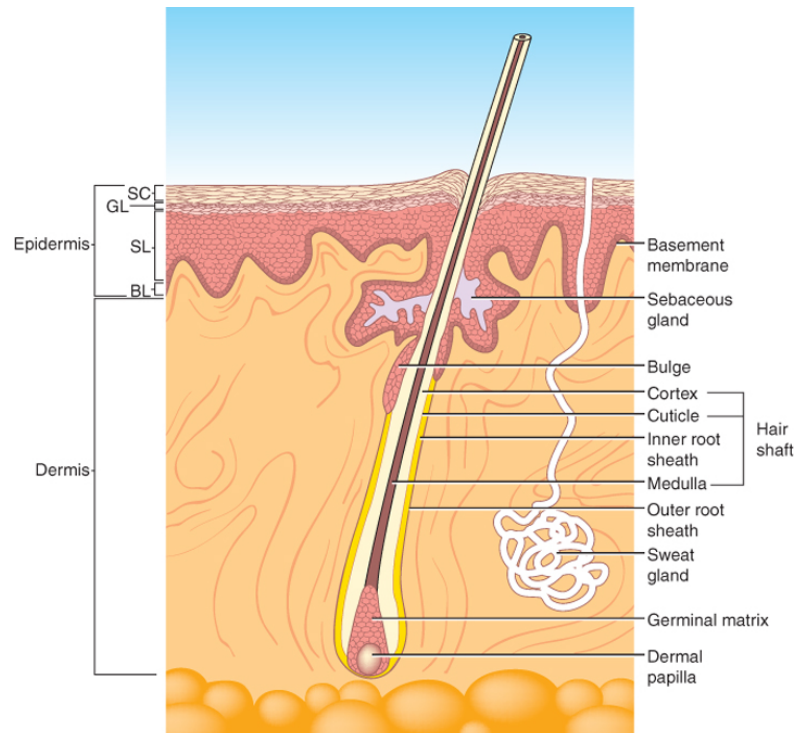
Epidermal gland development

Epidermal appendages

Sebaceous glands: develop from hair follicle (4 weeks +)

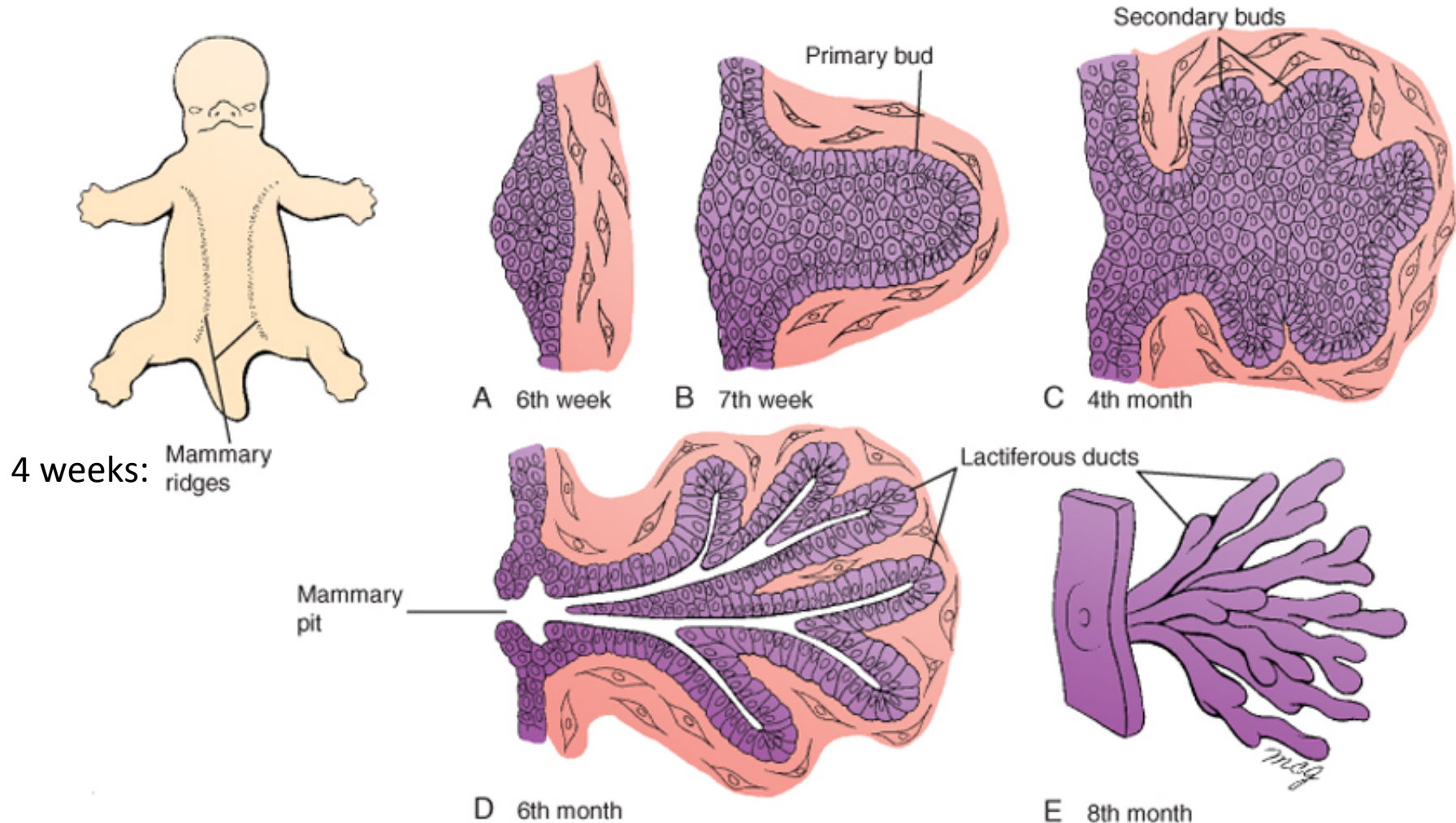
Sweat glands: develop from basal layer IFE (20 weeks+)

Apocrine glands: develop in association with HFs, most lost late in fetal dev.



Mammary gland development

Epidermal appendage

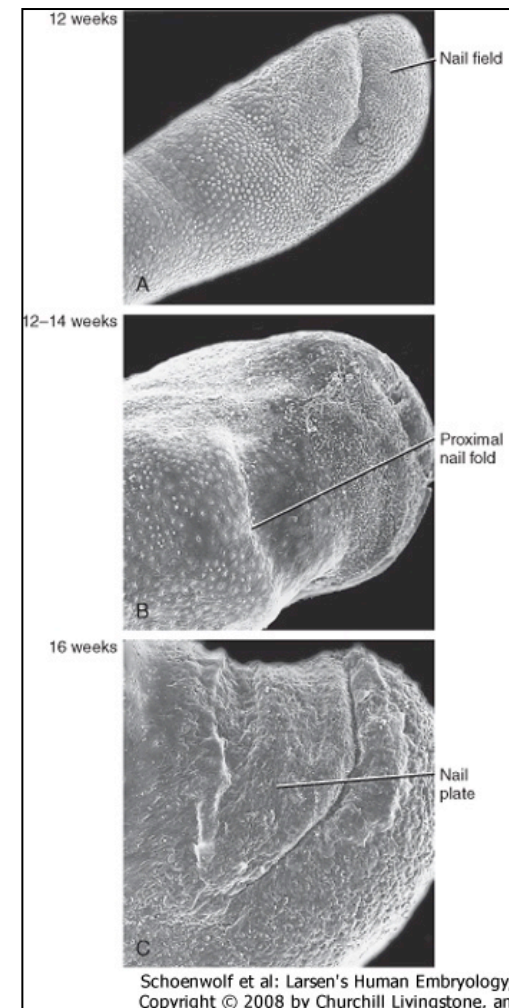


Nail development

Ectoderm

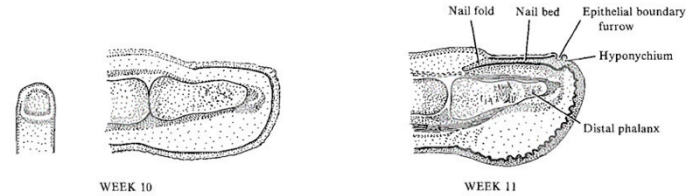
Week 10: epidermal thickening, nail field

Week 11: nail anlagen moves proximally, nail folds, proximal nail fold: formation of formative zone



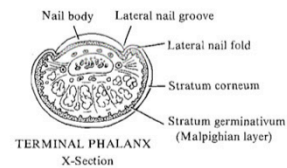
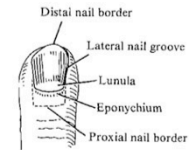
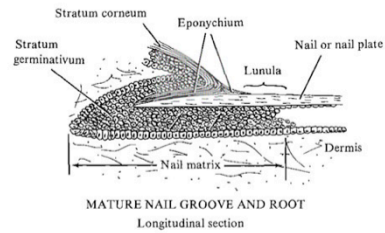
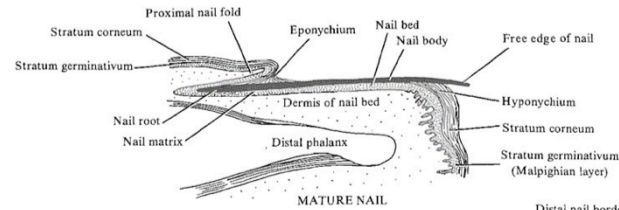
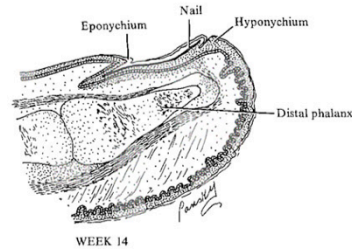
Nail development

Ectoderm



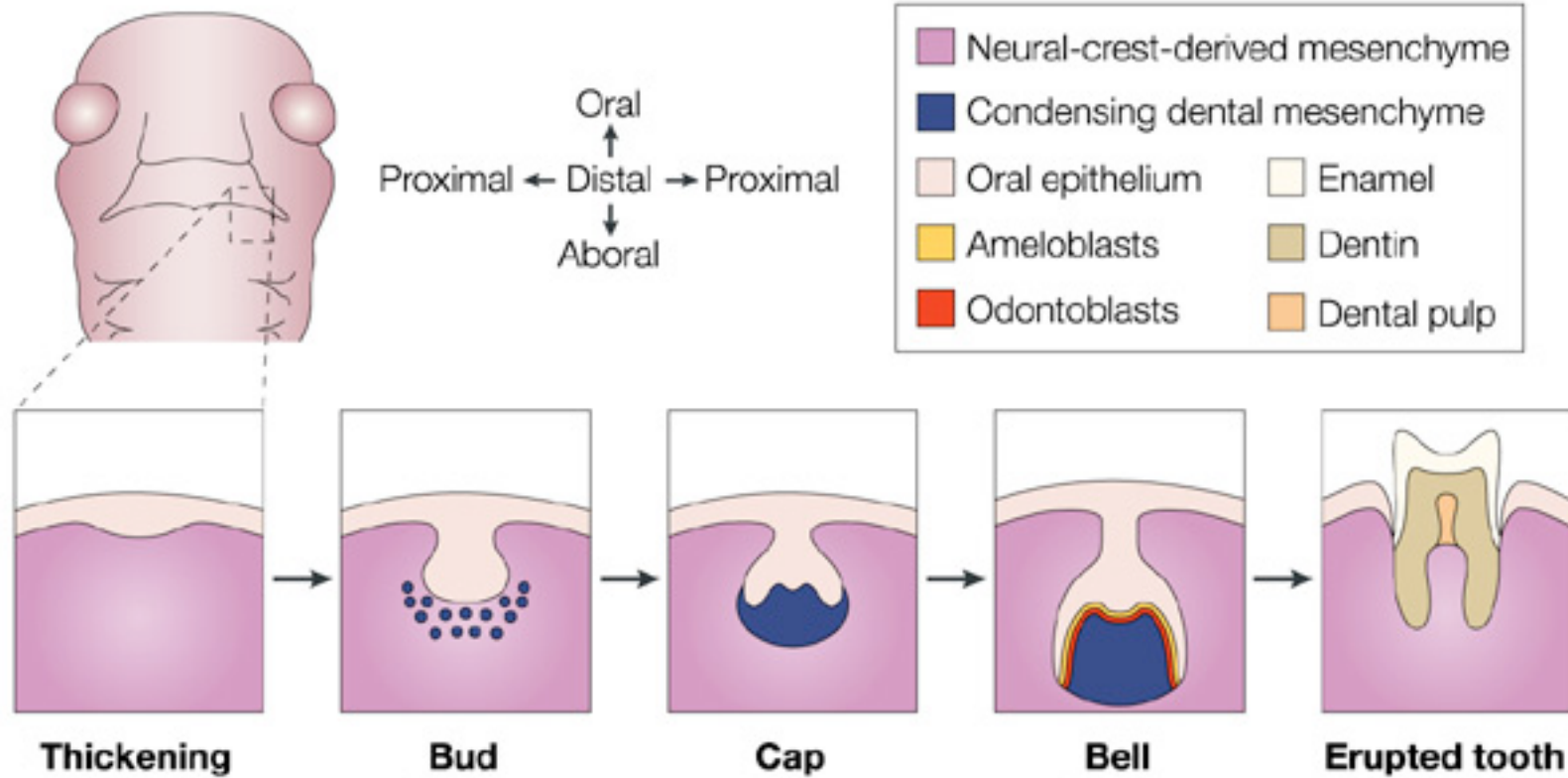
DEVELOPMENT OF FINGERNAIL

Sections of fingertip



Tooth development

Ectoderm/cranial neural crest derived mesenchyme



Week 6:
dental lamina

Week 7-8:

Week 8:
Dental Papilla

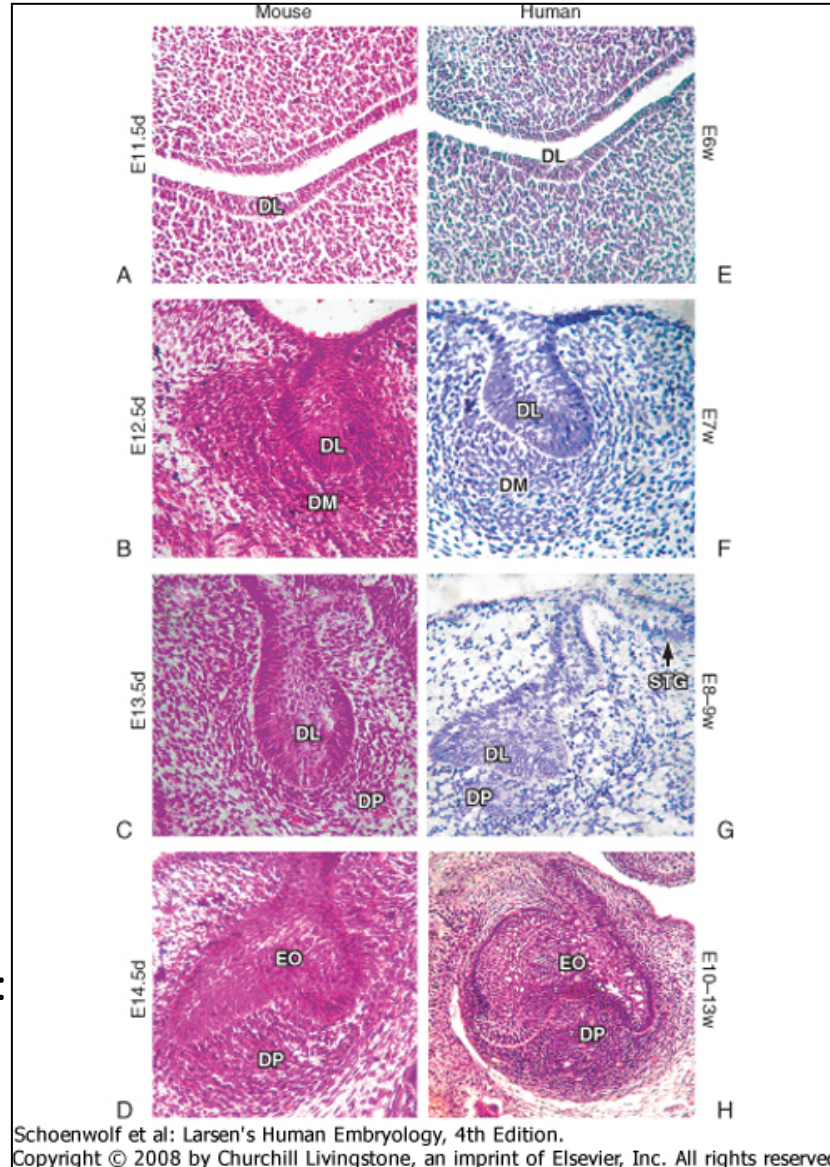
Ameloblasts: enamel
Odontoblasts: dentin

Tooth development

Week 6: dental lamina forms

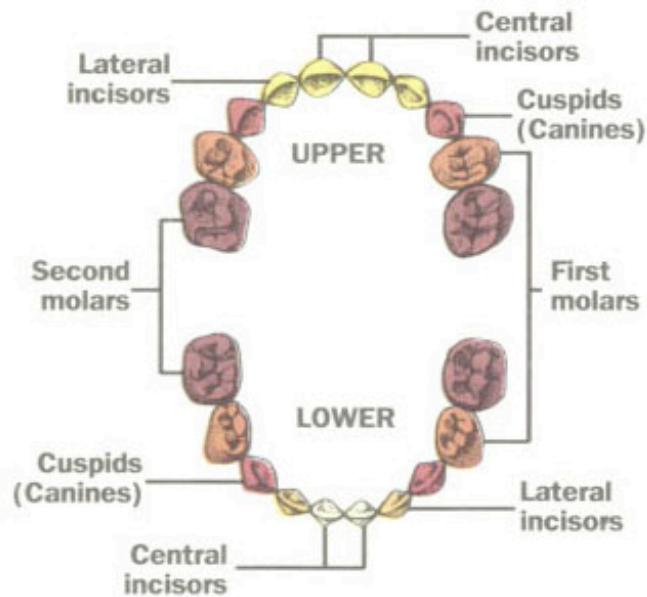
Week 7-8: formation of tooth buds







Week 8: formation of dental papilla:
Bell Stage



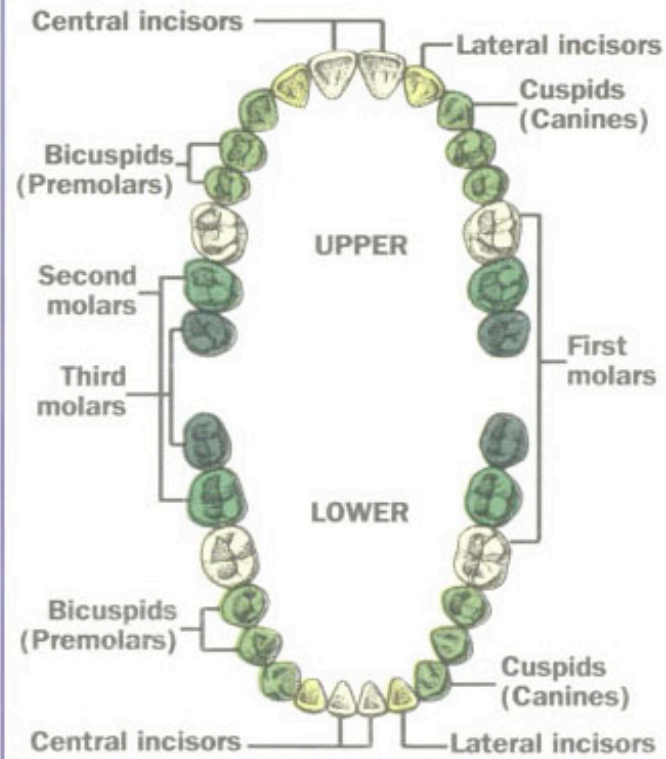
Tooth development

Primary teeth



- | | |
|--|--|
|  6-10 months |  13-19 months |
|  8-13 months |  16-23 months |
|  10-16 months |  23-33 months |

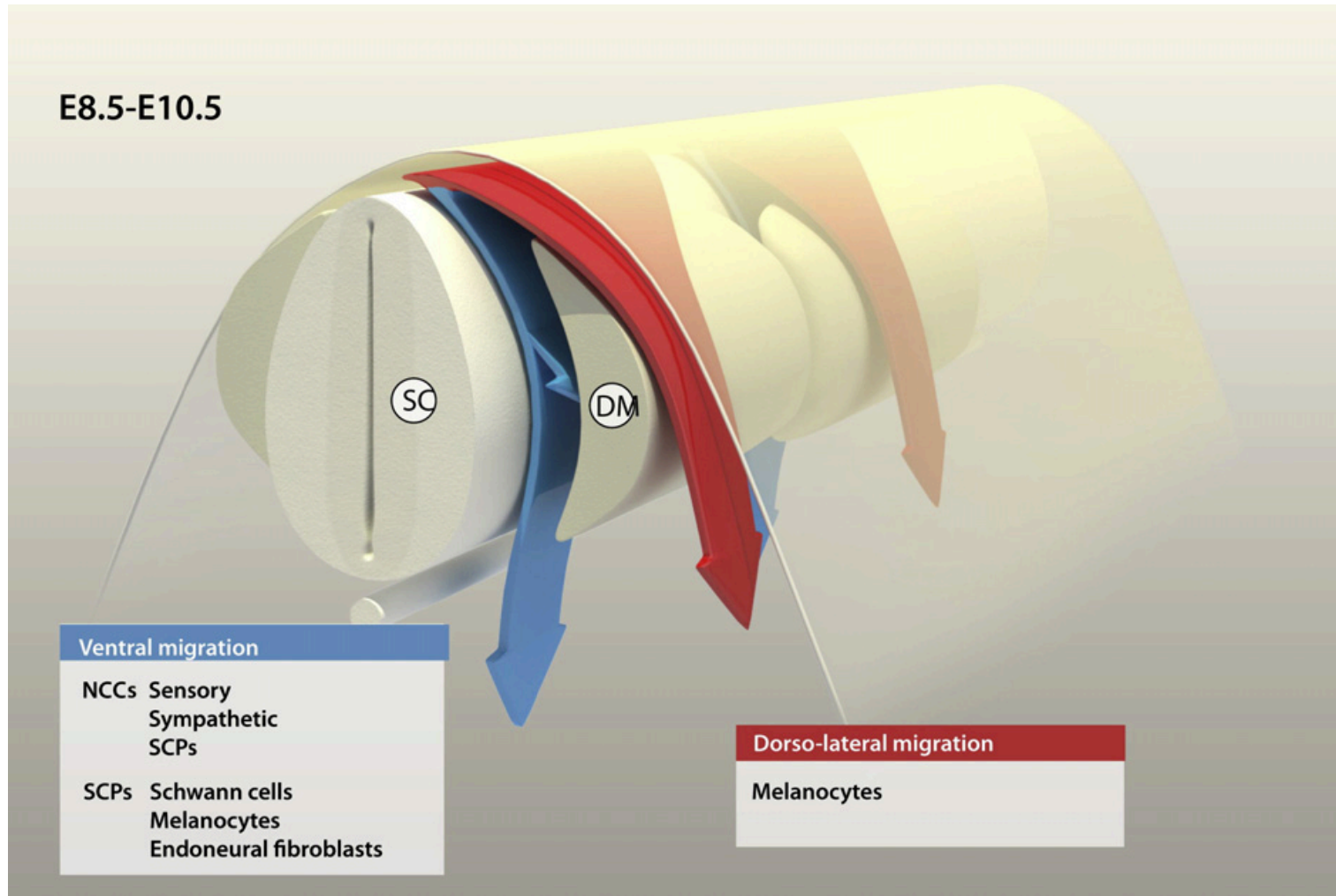
Adult teeth



- | | |
|--|---|
|  6-8 years |  11-13 years |
|  7-9 years |  17-21 years |
|  9-12 years | |

Melanocyte development

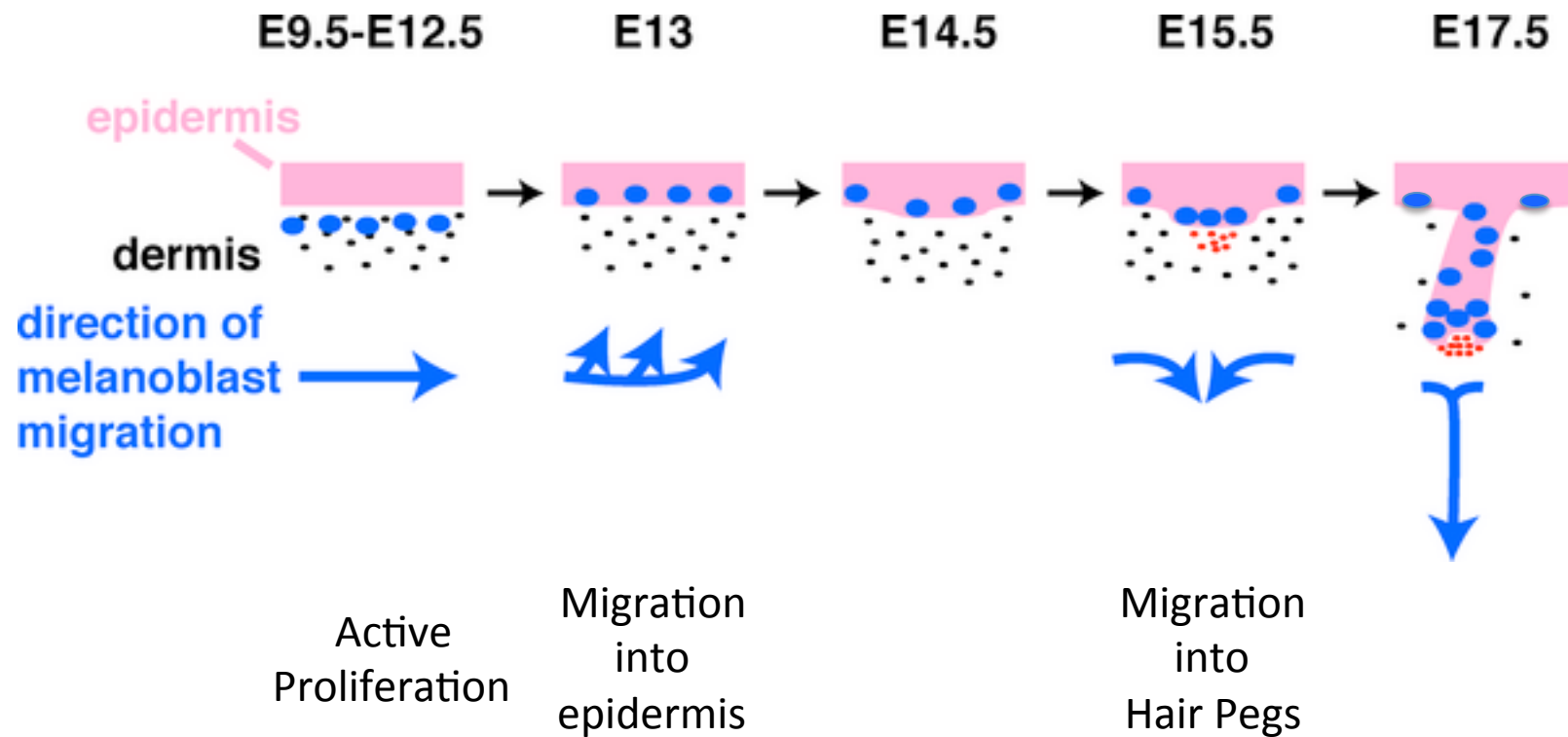
Neural crest



Ernfors, Exp Cell Res 2010

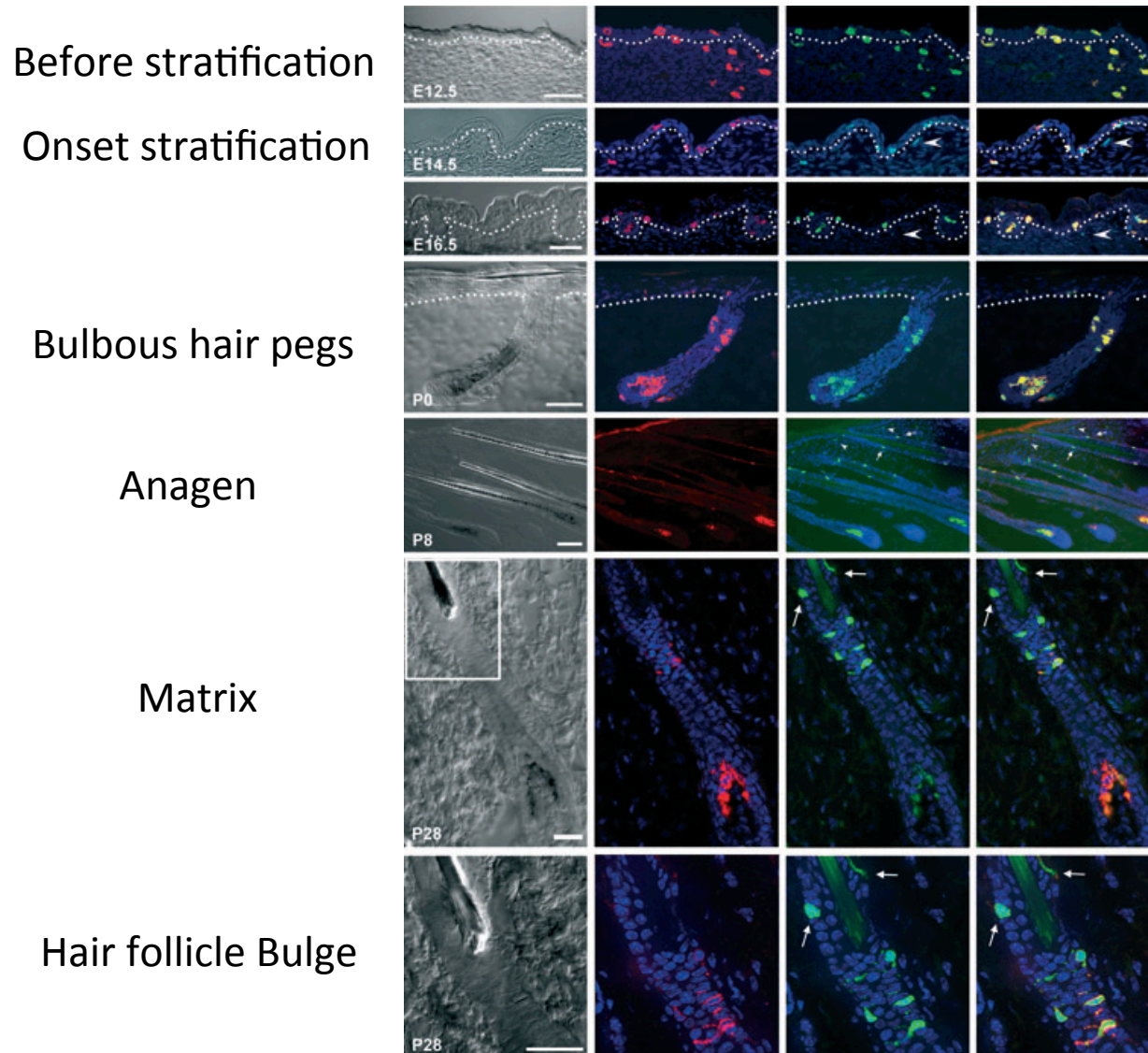
Melanocyte development

Neural crest



Melanocyte development

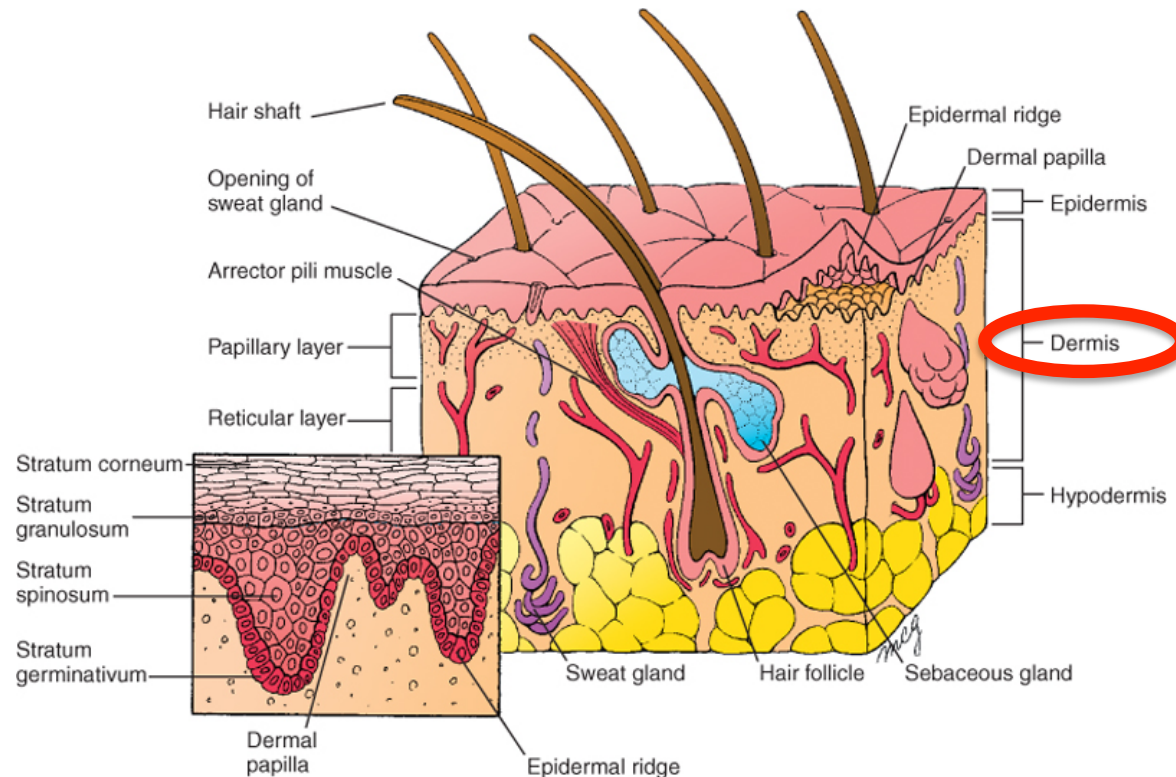
Neural crest



Djian-Zaouche,
Pigment Cell Melanoma Res 2012

Dermis

Connective tissue with:
Fibroblasts
Blood vessels
Nerve endings
Sensory receptors

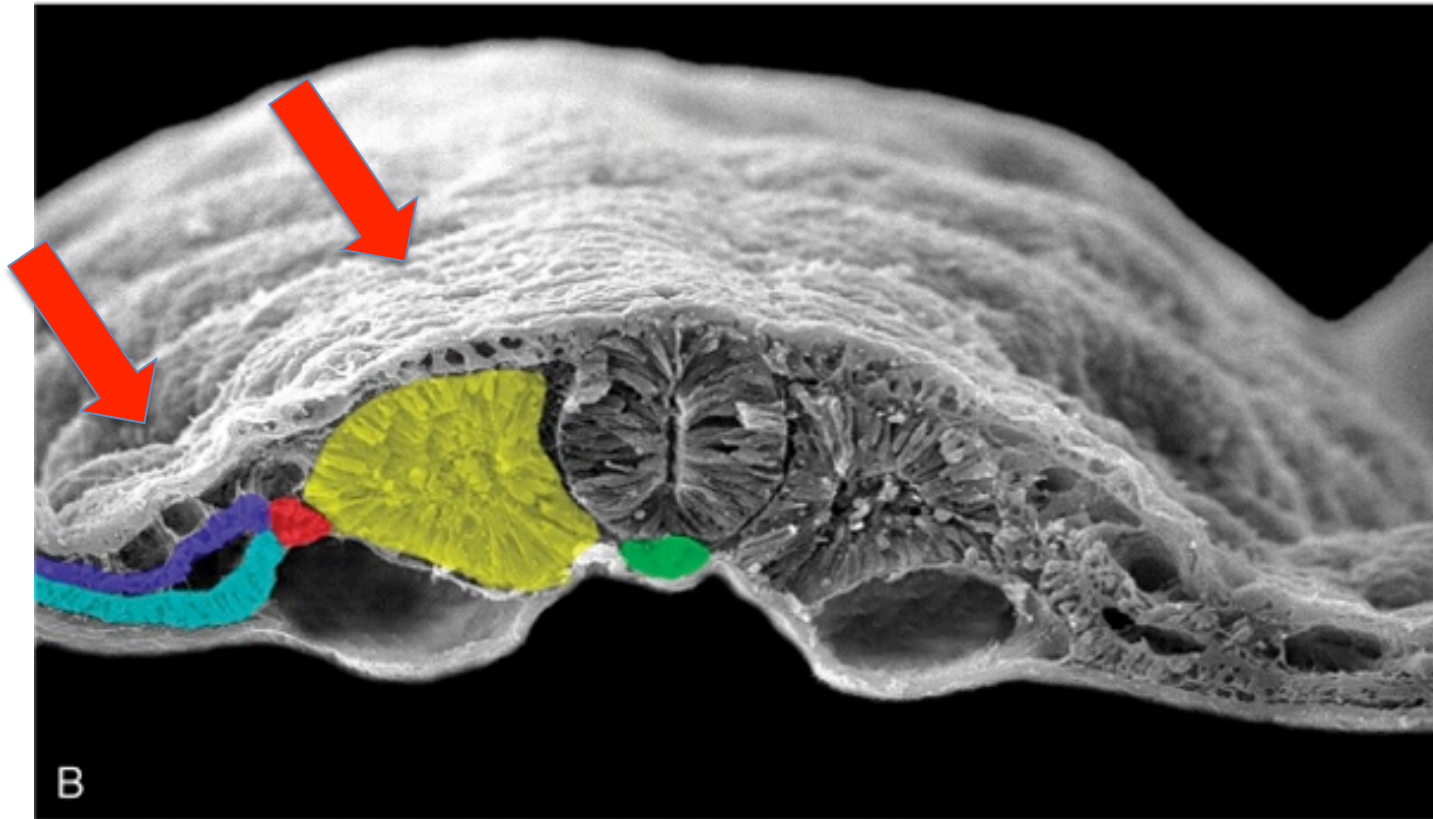


Dermis development

Somitic mesoderm

Somatic lateral plate mesoderm

Cranial neural crest derived mesenchyme

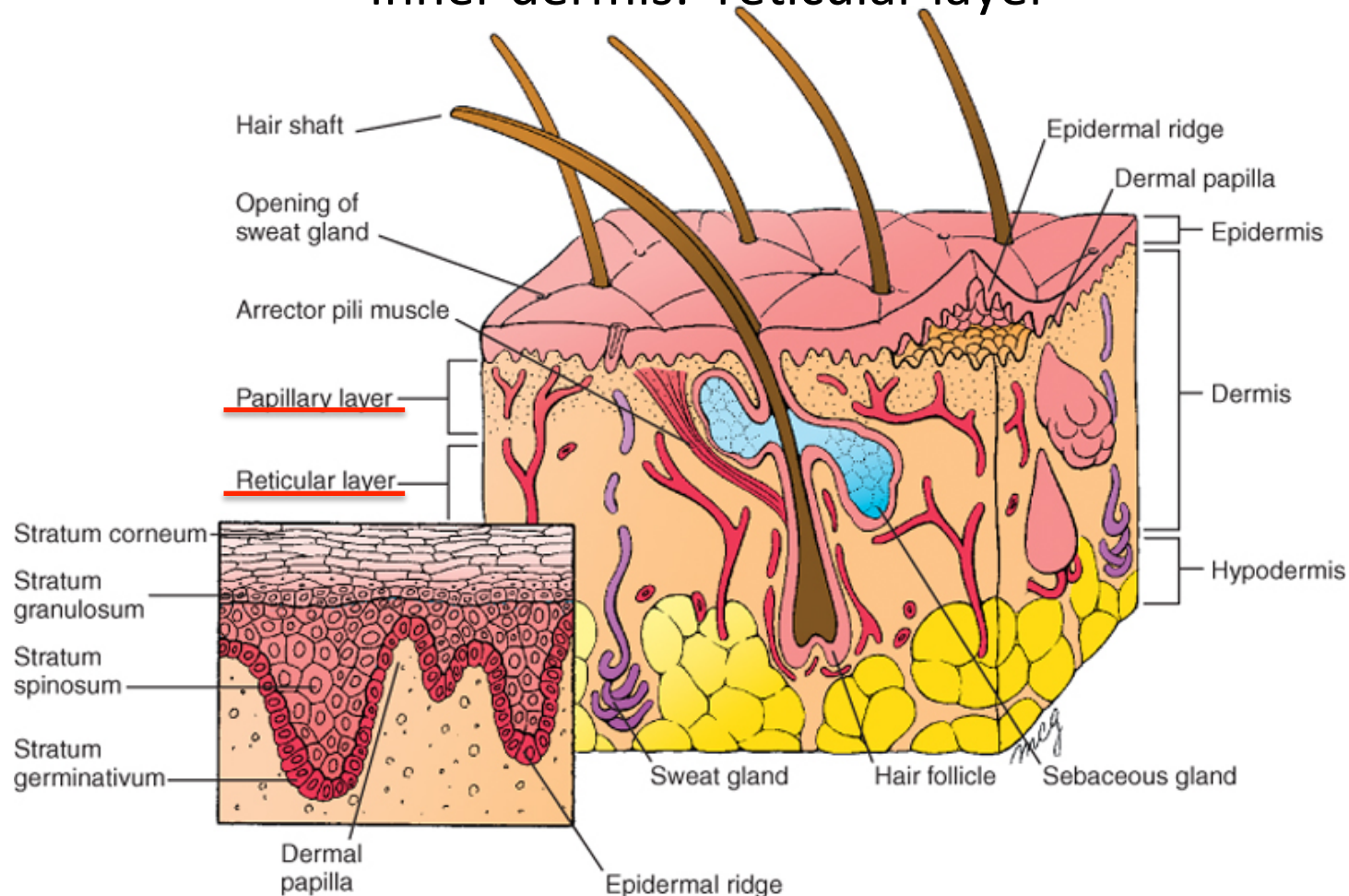


Schoenwolf et al: Larsen's Human Embryology, 4th Edition.
Copyright © 2008 by Churchill Livingstone, an imprint of Elsevier, Inc. All rights reserved

Dermis development

3 Months: formation of papillary layer
(dermal papillae and epidermal ridges)

Inner dermis: reticular layer



Schoenwolf et al: Larsen's Human Embryology, 4th Edition.

Copyright © 2008 by Churchill Livingstone, an imprint of Elsevier, Inc. All rights reserved

Lecture overview

Skin

Skin origins

Development of the overlying epidermis

Development of epidermal appendages:

Hair follicles

Glands

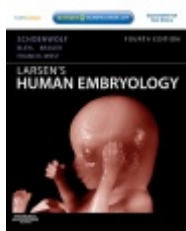
Mammary glands

Nails

Teeth

Development of Melanocytes

Development of the Dermis



Resources:
<http://php.med.unsw.edu.au/embryology/>
Larsen's Human Embryology
The Developing Human: Clinically Oriented Embryology



Dr Annemiek Beverdam – School of Medical Sciences, UNSW
Wallace Wurth Building Room 234 – A.Beverdam@unsw.edu.au