

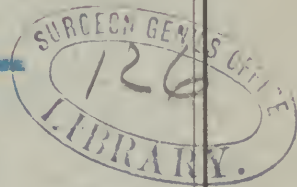
Schmidt (H. D.)

THE DEVELOPMENT OF THE NERVOUS TISSUES OF THE  
HUMAN EMBRYO.

BY

DR. H. D. SCHMIDT,

Member of the American Neurological Association.



---

*(Reprinted from the Journal of Nervous and Mental Disease, July, 1877.)*

---

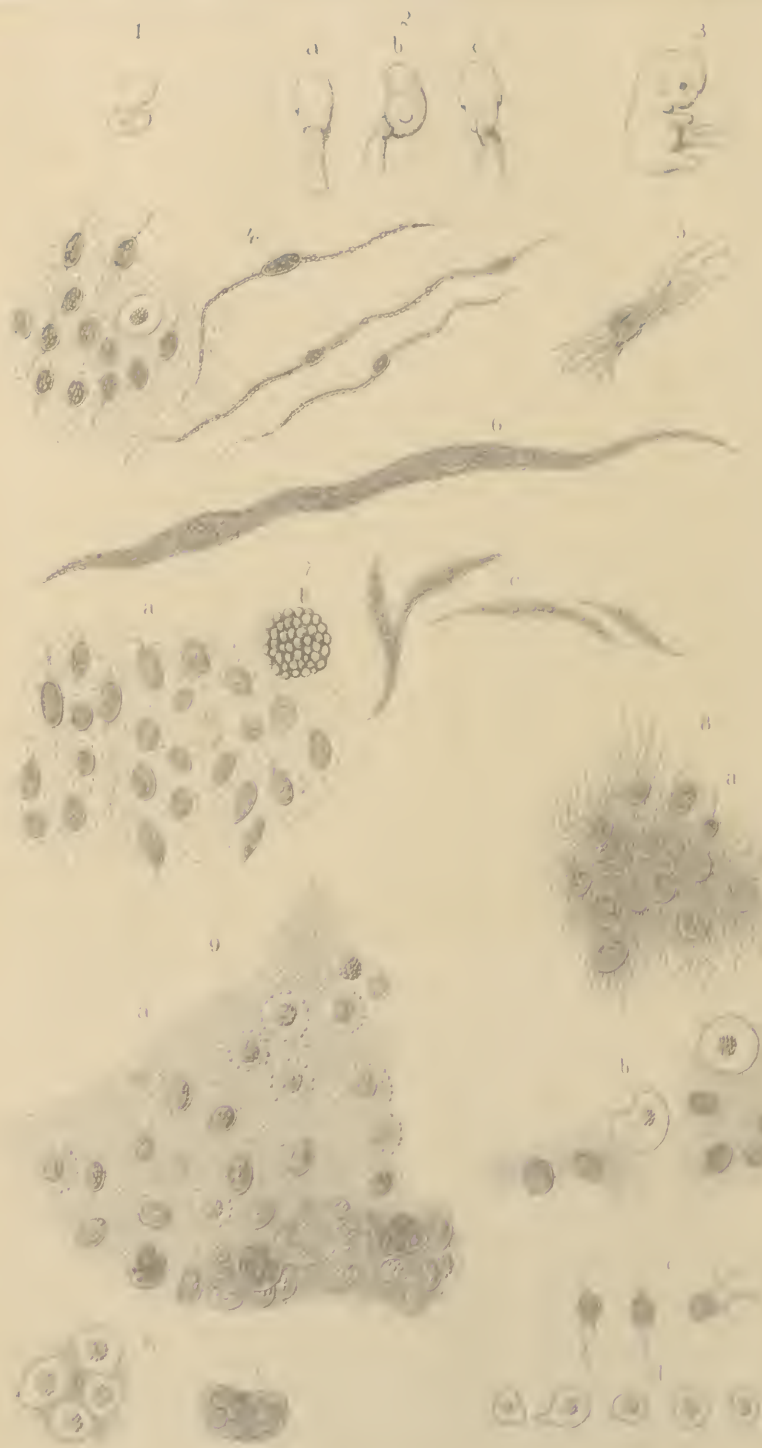
CHICAGO:

A. S. KISSELL & Co., PRINTERS.

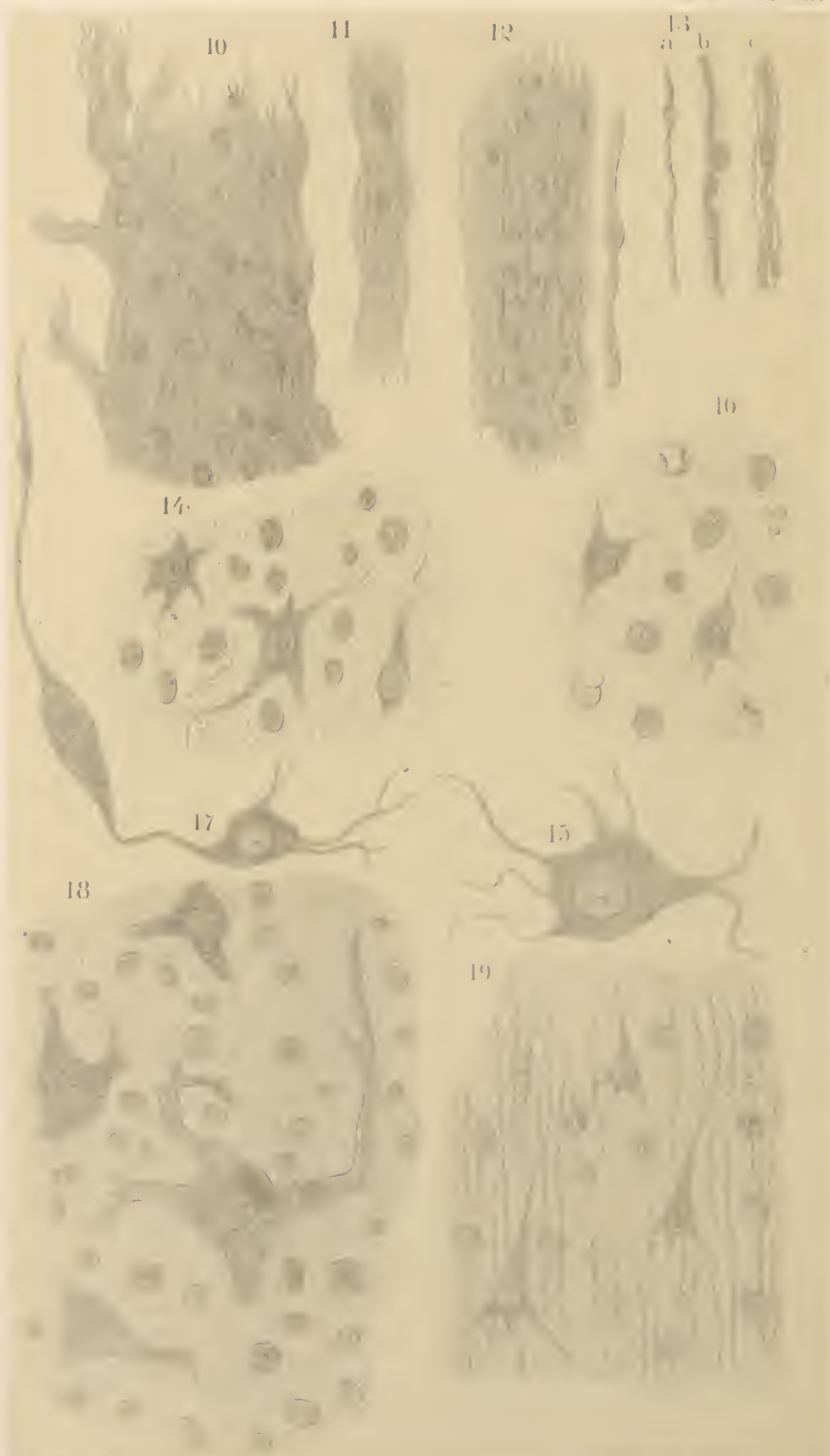1877.

















THE  
JOURNAL  
OF  
Nervous and Mental Disease

Vol. IV.

JULY, 1877.

No 3.

Original Articles, Selections and Translations.

ART. I.—THE DEVELOPMENT OF THE NERVOUS  
TISSUES OF THE HUMAN EMBRYO.

By DR. H. D. SCHMIDT, OF NEW ORLEANS.

MEMBER OF THE AMERICAN NEUROLOGICAL ASSOCIATION.

THE following pages embody the results of a series of researches into the development of the nervous tissues of the human embryo, which were commenced several years ago. More than four years, indeed, have elapsed, since they were finished, but not until now have circumstances allowed me to present them to the medical public in proper form, and illustrated with appropriate drawings. It is true, that some reference was made to these investigations in my article on "The Structure of the Nervous Tissues" etc., published in the Transactions of the year 1875, of the American Neurological Association; but only such a brief sketch was given, as the arrangement then in hand required.

I was fortunately able in these researches to command an abundant supply of good material. The greater portion of embryos employed—about eighteen in number—belonged chiefly to periods of pregnancy, anterior to the fifth month. In all, they ranged from one exceedingly small specimen, only

6. mm. in length, through all the intervening stages of fetal evolutions, up to the mature fetus born at full term.

The examinations were made, as circumstances required, both from fresh specimens and from others preserved and prepared in a weak solution of chromic acid.

Inasmuch as the nervous tissues are not developed from organic cells, in any true sense of the word, as has been so generally supposed, I have deemed it expedient to introduce the subject with some prefatory remarks in explanation of some terms, which I have employed.

Ever since the discovery of the organic cell in animal tissues, it has been a favored theory among histologists, that the primary form of all tissues was that of a cell. This theory still almost universally prevails, although in one instance, at least, in the so called "white fibrous" or connective tissue, it has been sufficiently shown, that it does not originate in a cellular form. But neither the striated muscular, nor the nervous tissues originate from cells, unless we look upon the nuclei, concerned in their origin and development as such. The idea of what constitutes an organic cell itself, has of late years undergone considerable modification, since it was discovered, that the only essential part of this body, was the protoplasm, and that in many cases the whole cell consisted only of a minute portion of this substance. Thus, the wall and the nucleus are now considered to be non-essential parts of a cell, both being products of the protoplasm. The wall, when present, must manifest itself by a double contour; a cell, presenting only a single contour, is said to possess no wall. And yet, it seems to me, that even in this instance, the density of the protoplasm must be greater at its surface, than in the interior of the mass; for, if there were no limiting elements, the protoplasm of contiguous cells would be liable to become fused. Such a layer may differ so slightly from the whole mass of protoplasm, of which it forms a part, and may be so extremely thin, as to manifest itself only by a delicate single contour, and nevertheless, its density may be sufficient, to prevent its fusion with a neighboring cell.

The nucleus, which, according to the older cell theory, was pre-existent to protoplasm, as well as to the wall, is now known

to originate from and within the protoplasm. There are, however, some exceptions to this rule.

According to what has been said above, a nucleus, surrounded by a portion of protoplasm, however minute or of whatever form, constitutes a perfect cell. But, now I may ask, whether the term "cell" may equally be applied to a body consisting of a more or less oblong nucleus with a minute portion of protoplasm, in the form of granular filaments or appendages, adhering to its opposite poles? Such bodies are met with in the developments of the striated muscular fibres (Fig. 4), and in that of the smaller blood vessels in the human embryo. To extend to these bodies, the term "cell" appears to me to overstretch the true meaning of the word. It was for this reason, that sometime ago, in connection with my researches of the development of the smaller blood vessels in the human embryo, I preferred to call these elements "spindle-shaped bodies," and I shall make use of this term in the following pages. It is true that in the development of the striated muscular fibres the nuclei of these elements become eventually entirely surrounded by the granular fibrillæ (Fig. 6), and the whole body might then be compared to an organic cell. But, as these bodies soon fuse with each other, in order to form another distinct tissue, and thus never perform the functions of a true organic cell, I shall still prefer to apply the above mentioned term to them, especially, as their fibrillæ may be easily separated after the fusion has taken place (Fig. 5). In the development of the nerve fibres, no such spindle-shaped bodies occur, for the nuclei are lying at first free between the granular fibrillæ, only later, when the axis cylinders begin to be formed, they become fused with fibrillæ.

The nervous tissues, during the earlier stages of development, are exceedingly delicate, of a jelly-like consistency, and to a certain degree transparent. It is this delicacy of structure which renders their histological investigation so difficult, as it frequently interferes with their successful removal from the body of the embryo. In very small embryos, therefore, it becomes often necessary to immerse them for a short time in a weak solution of chromic acid, in order to render them sufficiently consistent for dissection. If the solution is not

strong, and the material is only exposed a short time to its action, the changes taking place in the tissues by its action will be so slight, as not to interfere with the investigation. Nevertheless, in order to come to correct conclusions, the examinations made of specimens treated with a solution of chromic acid, should always be compared with such as are made from fresh unaltered material.

Another difficult point in the investigation of embryonic tissues, is to determine the exact age of a human embryo, especially when we obtain our material from unknown sources. To estimate the age of an embryo by its size is inadmissible, as embryos of the same age and stage of development may differ in size as well as adults do. To avoid errors, I shall therefore state in the following pages simply the length of embryos under discussion, measured from the top of the head to the point of the big toe, and allude to their ages only approximately.

The smallest embryo, which I ever had occasion to examine, measured 6 mm. in length, (Fig. 1.) The brain here, consisted only as far as I could ascertain, of the same embryonic elements as the dermal surface and other tissues; viz., of small embryonic nuclei, embedded in a soft, somewhat transparent material, the protoplasm. A differentiation of the nervous tissues, and those surrounding them, had as yet, not begun.

In examining the nervous matter of the brain of embryos of about 9 mm. in length (Fig. 2), we find it to consist of an amorphous matter of a gelatinous consistency, holding, besides innumerable minute granules, a very considerable number of nuclei (Fig. 7, *a*). The greater portion of these nuclei present an oval form, some of them are round, while others have assumed more or less the form of a spindle. They all present a distinct double contour, and contain a number of granules, frequently unequal in size. On some of the nuclei, small appendages in the form of granular filaments, were observed to adhere to their opposite poles. It is difficult to decide, whether these bodies were the primary representations of ganglionic bodies, or whether they were destined to take part in the formation of blood vessels. Besides these elements,

a small number of certain cells, filled with small nuclei were observed. The latter, measuring from about  $\frac{1}{600}$  to  $\frac{1}{300}$  mm. in diameter, were distinguished by a very dark and heavy contour and by a greenish lustre. In most instances, no cell membrane could be seen, the whole represented a minute ball of nuclei (Fig. 7. *b*). To these cells we shall refer again hereafter. Some other elementary forms, observed in the matter of the brain at this embryonic period, remain to be mentioned. These were a number of long, spindle-shaped opaque bodies, containing one or more rows of granules. Some of these bodies already adhered to each other (Fig. 7. *c*). They undoubtedly represented the first traces of the blood vessels, and judging by the resemblance they bore to those spindle-shaped nuclei, above mentioned, they were very likely identical with them. In my article "On the Development of the Smaller Blood-vessels in the Human Embryo," published in the January number of the *Monthly Microscopical Journal*, 1875. I have described one mode of the formation of blood vessels, taking place at a later period, by the formation of certain spindle-shaped bodies, consisting of granular fibrilla; the latter starting to be formed from the opposite poles of a pre-existing oval nucleus, by successive adhesion of granules, and similar to the formation of the striated muscular fibre. The observation of these spindle-shaped opaque bodies in the matter of the brain above described, however, seems to indicate that at this early period of embryonic life, blood vessels may also be developed directly from nuclei.

Although several embryos of this early period, either of the same size or slightly larger, fell into my hands, I never succeeded in isolating successfully the spinal marrow for the purpose of an exact examination. The tissues in general at this period are very soft, and their differentiations still too slight to admit of an easy separation. But judging from the examinations made of the spinal marrow of somewhat older embryos, to be described directly, I suppose, that it consists of the same elements as the brain.

In a perfectly fresh and normal embryo, of about 16 mm. in length (Fig. 3), I found the brain to consist of the same ele-

ments as above described, which, however, were now further advanced in development (Fig. 8, *a*). Thus, the minute granules were more numerous, so much so, as to form a granular mass or substance. A considerable portion of them had already been arranged into rows, forming granular fibrillæ. The nuclei were also more numerous, they all presented a distinct double contour, and contained a number of granules, the largest one of them representing the nucleolus. A few granular fibrillæ were observed to adhere to some of these nuclei (Fig. 8, *c*). Now, whether this adhesion took place accidentally, or whether we behold here the first traces of the formation of ganglionic bodies, I am not prepared to decide; especially as I did not observe the same phenomenon in the spinal marrow of this embryo.

Finally, a considerable number of clear cells, containing coarse granular nuclei, were met with in the matter of this brain (Fig. 8, *b* and *d*). The outlines of these cells represent a delicate, double contour, and being very clear, contain nothing else besides the nucleus, except in a few instances in which I observed a few single granules. The nucleus consists only of a collection of coarse and mostly irregular-shaped granules, possessing no enveloping layer or wall. In many instances, some of these granules were observed to separate from the general mass; while in others they were seen to escape through the ruptured wall of the cell. The diameter of the clear cells is not constant, for it ranges from  $\frac{5}{100}$  to  $\frac{7}{100}$  mm., the nucleus, however, whether enclosed by a large or small cell, varies but little in size, its diameter being about  $\frac{3}{100}$  mm. The form of the cell also varies, for, while some of them appear round or oval, others are irregular in shape (Fig. 8, *d*). These cells are not only found in the nervous tissue, but also in all other tissues during the earlier stages of their development. Considering their general occurrence and the separation of the granules of their nuclei, it almost appears as if they were playing some part in the multiplication of nuclei.

As regards the spinal marrow of this embryo, I succeeded in isolating a portion of it in the fresh condition. With some slight exceptions, it consisted of the same elements, as those of the brain just described. A portion of it still consisted of

free granules, though the arrangement of these minute granules into rows or fibrillæ had advanced much further than in the brain, the formation of fibrillæ was already so decided as to allow them to be separated into bundles in the white substance. Fig. 10 represents a small portion of the spinal marrow in the fresh condition, exhibiting the formation of fibrillæ. The bundle, lying across the general mass, represents most likely a spinal nerve. The nuclei were also more numerous; they usually contained one or two nucleoli among the granules packed in their interior. They were either distributed throughout the whole, as in the white substance, and unconnected with the fibrilla, or collected into masses as seen upon the pia mater in Fig. 9, *a*. Those clear cells with coarse granular nuclei were also met with here in very considerable numbers (Fig. 9, *b*). Besides these, however, a number of these mother cells, packed with small nuclei of a greenish lustre, alluded to before, were observed in their various stages of development. As stated before, some of them represented only a minute ball of nuclei, while in others a delicate single contour was observed; in these instances, the nuclei were quite small. But there were still others, further advanced in development (Fig. 9 *c*), which were distinguished by a double contour. In some of these, the nuclei had obtained a considerable size, and even showed a double contour. The development of the nuclei, however, seemed to bear no fixed relation to the size of the cells, neither did the contour of the cells. The whole character of these elements shows, that they are mother cells, engaged in the multiplication of nuclei. Like those clear cells, they are also met with in other tissues, at this early period, especially in the skin. In the spinal marrow, these cells were not observed between the fibrillæ of the white substance, but they were especially observed in the vicinity of the pia mater. It was in this locality also, where the nuclei were met with, collected in masses, which circumstance induced me to think, that the growth of the spinal marrow in thickness was most active near this membrane. In examining a small piece of pia mater (Fig. 9), it was found to consist of a delicate amorphous membrane, the inner surface of which was dotted with innumerable granules; a number of these were

arranged in the form of rows. Now, whether these rows of granules represent the first traces of the formation of the fibrillæ of the connective tissue of the membrane, such as I observed in other places, or whether they were fibrillæ of the nervous substance, adhering to the membrane, I must leave undecided.

In reviewing the results obtained from the examination of the nervous tissues of this early period of embryonic life, we can not fail to recognize the first traces of the future nerve fibre in the form of a row of minute granules, which, held together by an intermediate substance, are transformed into nervous fibrillæ, thus representing the fundamental anatomical elements of the axis cylinders. The first traces of the formation of ganglionic bodies, or so called "nerve cells" are seen in those short fibrillæ, adhering to some of the nuclei, as before described.

To satisfactorily demonstrate the development of the peripheral nerves at this early period, is very difficult, on account of the fact that the striated fibres of the muscles, by which the nerves are surrounded, still consist of granular fibrillæ, rendering it impossible to distinguish between the two tissues. But in examining the bundle of nervous matter, lying across the fragment of spinal marrow (Fig. 10), and which we may safely regard as a spinal nerve that during the manipulation was accidentally dragged across the preparation, we find the development of its composing fibrillæ as far advanced, as that of the fibrillæ of the white substance of the spinal marrow. No traces of the formation of blood vessels were discovered in the spinal marrow at this period.

A spinal ganglion, which I succeeded in separating in the embryo under discussion, I found to consist, like the brain and spinal marrow, of a great number of nuclei, imbedded in the mass of granules, of which a great number were already arranged in rows, representing granular fibrillæ; even some small bundles of them were observed.

Let us now direct our attention to embryos, about nine weeks old, measuring from  $5 \frac{1}{10}$  et.m. to  $5 \frac{1}{10}$  et.m., from the top of the head to the point of the toes, and of which I had occasion to examine some fine specimens thoroughly. In com-



paring the nervous system of this period with that of the small embryo last discussed, we find that during the intervening time, its morphological development has been proportionately greater than its histological. In embryos of this period the head is still large in proportion to the whole body. The eyes and nose are formed; the mouth is open, and its cavity quite well developed. The extremities are formed, but the fingers and toes are to a certain degree still connected with each other. The lungs, heart and larger blood vessels are distinctly formed, also the liver, spleen, intestines, etc. The farthest developed of all is the muscular system, for the muscles not only possess their individual sheaths, but they are, moreover, already provided with blood vessels. From the advanced development of the heart and the blood vessels, as well as from the quantity of mature colored blood corpuscles, it may be presumed, that the circulation of the blood is carried on pretty completely. In opening the cranium and spinal canal, the brain and the spinal marrow with their membranes are found to be morphologically much farther developed, than in the embryo last discussed. The membranes, though still passing through their phase of histological development, are nevertheless, formed in all their details. Thus, the pia mater, delicate and transparent as it still is, not only embraces the whole cerebro-spinal axis, as in later periods, but also extends in the form of the neurilemma over the peripheral nerves and their ramifications; and notwithstanding its delicacy of structure, it can now be separated under water from the nervous tissues without difficulty, offering the best opportunity for the study of the development of its connective tissue and blood vessels.

The ganglia of the sympathetic nerve are also distinctly formed. They are seen extending along each side of the spinal column, forming the gangliated cords. Their size, however, in comparing it with that of the perfectly developed ganglia in the adult, seems rather larger in proportion, for which reason they also appear to be closer to each other.

The nervous substance of the brain and spinal marrow of this period, presents a white semi-transparent appearance, similar to the "Milk glass" of certain lamp shades. It still consists principally of those primary anatomical elements, already de-

scribed. The histological development of these elements, has however not kept equal pace with the development in volume and form of the whole nervous apparatus. Not only has the brain and spinal marrow assumed a more decided form, but the peripheral nerves are also distinctly formed and may even be separated. In the spinal marrow, the gray substance is softer than the white. The formation of ganglionic bodies is still confined to a small number of nuclei, to which a few short granular fibrillæ are seen to adhere. The rest, being quite numerous, are distributed throughout the granular substance, the granules of the greater part of which are now arranged into regular rows. The first traces of the formation of blood vessels are now observed in the form of oval nuclei, with small granular appendages, adhering to their opposite poles, and giving to the whole body the form of a spindle. In the white substance also, the greater portion of the granules are found to be arranged into parallel rows, while the rest are distributed between these primitive fibrillæ, to furnish, in the course of the development, material for the formation of others. Those subdivisions of the white substance, as seen in the fully developed spinal marrow, into larger or smaller bundles, and effected by partition-like processes derived from the neuroglia, may be observed to commence in the embryonic spinal marrow of this period.

An interesting fact to be noticed here is, that while in the spinal marrow the granules are arranged, as before mentioned, into regular rows, which, however, may be easily deranged again by manipulation, in the peripheral nerves, as for instance in the brachial plexus, they are observed to be already fused with each other into perfect fibrillæ. This observation, with others to be stated hereafter, shows, that the development of the nervous tissue is farther advanced at the periphery, than in the centre.

In the brain the histological development has not advanced further than in the spinal marrow. On the contrary, the granular fibrillæ are not even so distinctly formed as in the latter. The formation of ganglionic bodies is still limited to those few nuclei with granular filaments adhering, as mentioned before.

The pia mater extends from the brain and spinal marrow,

over the peripheral nerves in the form of a single sheath. The whole nerve consists, therefore, like the nerve of an insect, only of a bundle of granular fibrillæ, which in pursuing a slightly wave-like course, are placed parallel to each other, and surrounded by their sheath, the neurilemma. A number of oval nuclei, varying in diameter, are distributed and imbedded between the fibrillæ. The blood vessels of the pia mater are very numerous and much further advanced in development than those of the nervous substance. When the pia mater is illuminated with oblique light, very fine fibrillæ, lying parallel to each other, may be observed. Its inner surface is dotted with numerous nuclei of different diameters, similar to those of the white substance of the spinal marrow, but there is also a small number of others, which are spindle-shaped and probably belong to the connective tissue.

It deserves to be mentioned here, that those large mother cells, packed with larger and smaller nuclei of a greenish lustre, and found, as described above, in the substance of the spinal marrow near the pia mater of a former period, are no longer met with. The multiplication of nuclei by the endogenous mode, has ceased; another mode, that by gemination or budding, will henceforth be observed.

In the sympathetic ganglia of this period, the formation of their peculiar ganglionic bodies has distinctly commenced. Although the greater portion of their nervous substance still consists of the same elementary forms, as found in the brain and spinal marrow, there are nevertheless a considerable number of nuclei now met with, surrounded by a mass of granules, from which the rudimentary processes are seen to proceed in the form of granular filaments. Now, whether these filaments have already been connected with the granular nervous fibrillæ, or whether this connection takes place subsequently, will be difficult to determine. I am inclined to think that it has existed from the beginning of the formation of the ganglionic body.

The sympathetic nerves still consist, like those of the cerebro-spinal axis, of bundles of granular fibrillæ, each surrounded by a sheath. A number of oval nuclei are imbedded between the fibrillæ. The sheath represents the neurilemma

and is derived from the membranous capsule, surrounding the whole sympathetic ganglion.

In the spinal ganglia of this period, the development of the ganglionic bodies has still farther advanced, for they not only present all the characteristics of those of the thoracic ganglia, above described, but they have besides already assumed a more definite round or oval form.

In reviewing the above observations, regarding the development of the nervous tissues, our attention cannot fail to be directed to quite an interesting fact, namely, that the development does not keep equal pace in all localities, but may be more advanced in one than in the other. Thus, while in the brain and spinal marrow we have so far only met traces of the formation of ganglionic bodies, we find them already formed in the sympathetic thoracic ganglia. And again we find the primary fibrillæ of the nerve fibres in the peripheral nerves farther advanced in development, than in the spinal marrow or the brain. We shall refer again to this fact.

After the embryonic period, thus far treated, in this paper, the nervous tissues commence to assume very gradually their later complicated structure, for which reason, we shall prefer to treat each tissue individually.

In commencing with the nerves of the cerebro-spinal axis, in embryos of  $15 \frac{2}{16}$  etm. to  $15 \frac{2}{16}$  etm. in length,—about three and a half months old,—we find that each of them no longer consists of only a single bundle of nervous fibrillæ, enclosed in the rudimentary neurilemma forming a single sheath; but that on the contrary, the fibrillæ have subdivided into a number of bundles, each of which is surrounded by its own individual sheath of delicate connective tissue, which is derived from the neurilemma surrounding the whole nerve. Besides this, the fibrillæ of each bundle have also commenced to separate themselves, either singly, or by twos, sometimes even by threes. The interspaces formed by this separation, are filled up with numerous nuclei of different diameters, and with granules. From the latter, new fibrillæ are formed during the course of the development of the nerve. The nuclei, of course, are identical with those already described, between the granular fibrillæ of a previous period.

Somewhat later, in embryos, about  $18 \frac{5}{16}$  etm. long, and

four months old, the fibrillæ forming the individual groups of two or three, have approached each other more closely and adhere to each other. This phenomenon signifies the first step to the formation of axis cylinders. The interspaces formed, in consequence of this mutual approach of the fibrillæ, have been rendered larger and more distinct. A number of these primitive axis cylinders, as already indicated before, consists of only one fibrilla. At the same time it is observed, that the smaller nuclei, lying in the interspaces, appear to become attached to the axis cylinders, in order to fuse with them, as we shall see directly. The rudimentary axis cylinders are difficult to separate from each other, which may be attributed to the absence of the sheath, by which they will somewhat later be surrounded; and also, because they are imbedded together with the nuclei and granules, in an amorphous matrix of protoplasm, which holds them together.

Again, somewhat later, in the foetus of four and a half months, about 20 to 22  $\mu_0$  et. m. in length, a number of primitive axis cylinders are observed to be surrounded each by a sheath of its own, which, when fully developed, is distinguishable by a delicate double contour (Fig. 12). We must, however, remember, that all the axis cylinders of one bundle, do not keep equal pace in their development; on the contrary, while some of them may be already surrounded by their sheath, others may still be seen to lie bare, or the formation of the sheath may only be indicated by a delicate single contour. The nuclei, previously adhering to the axis cylinders, have now begun to fuse with them; they are also observed in different degrees of fusion.

The next phenomenon in the development of the double contoured nerve fibre is the appearance of the nerve medulla, surrounding the axis cylinder, and manifesting itself by an extremely delicate single contour (Fig. 13, *b*). In some instances, however, traces of the formation of the tubular membrane, or external sheath of this nerve fibre, may also be observed in the appearance of a second delicate contour, inside of the first. A few single granules are observed in the interior of the nerve fibre (Fig. 13, *c*). The diameter of the axis cylinder of this stage of development is not the same at all

points. In the vicinity of the nuclei fusing with the axis cylinders, it is usually greatest. The larger nuclei, which were previously observed to remain lying free and unconnected with the axis cylinders, are now found to rest upon the tubular membrane of the nerve fibre.

Finally, about a month later, the double contoured nerve fibre is met with again, marked by all its peculiar characteristics. The tubular membrane, together with the fibrillar layer of the nerve medulla, manifest themselves now distinctly by their characteristic double contour. The delicate, smooth fibrillæ of the fibrillar layer of the nerve medulla may now be seen in their wave-like course, crossing each other in the interior of the nerve fibre, or protruding in the form of loops from its torn ends, such as I have formerly described them\* in the fully developed nerve fibre. The axis cylinder may also be seen in many instances protruding from the open end of the nerve fibre. It is only in the diameter, that the double contoured nerve fibre of this period of fetal life still differs from that of adult life, it being still smaller.

The first distinct traces of the formation of ganglionic bodies in the spinal marrow, I observed in embryos measuring from  $7\frac{5}{10}$  ct.m. to  $8\frac{1}{10}$  ct.m. in length, and about ten weeks old. The formation of these bodies takes place by a gradual accumulation of granules around one of the larger nuclei; from the granular mass fine processes are seen to arise, establishing a communication with the still granular nervous fibrillæ of the future axis cylinder. The nucleus has as yet undergone no visible change in its character, for it still represents a vesicle filled with granules, of which one or two of them, larger than the rest, may be regarded as nucleoli. By the continued attraction of fresh granules, the ganglionic body enlarges in circumference, and its processes in thickness and extension.

Finally, in the spinal marrow of the fetus, about four and a half months old, a number of ganglionic bodies are observed, bordered by a delicate single contour, which in some instances even extends over their processes, and indicates the formation of the delicate sheath, enveloping the whole body, and being

---

\*Monthly Microscop. Journal, May, 1874.

continuous with the sheath of the axis cylinders arising from the processes (Figs. 14, 15, and 17). At the same time, however, many of the ganglionic bodies have not yet passed the first stage of their development. But in the nucleus, also, a change has taken place. Its nucleolus, namely, having by this time gained considerably in its dimensions, shows a granule of a bright lustre in its centre.

Still a month later, in the fœtus of about five and a half to six months of age, the ganglionic bodies with their processes, besides having gained in volume, are now completely surrounded by their sheaths (Fig. 18). The interior of the nucleus is filled with small granules of the same nature as those of the mass of the ganglionic body; its nucleolus has enlarged, and is seen more distinctly; the granule in the centre has become brighter. Those accumulations of dark bordered pigment granules in the vicinity of the nucleus so characteristic of the ganglionic bodies of the nervous system of the adult, also have now made their appearance. Thus, all parts, characteristic of the ganglionic body, are now present, and, excepting its further development in volume, it appears but for one element to be near its completion. The missing part belongs to the nucleolus. In the fully developed ganglionic body of the spinal marrow, the nucleolus is distinguished by a distinct double contour; its interior, besides being filled by small granules, contains one or two clear bodies of a reddish lustre. One of these, being always present, is also distinguished by a double contour, and shows, besides this, a dark granule in its centre. The fully developed nucleolus of the ganglionic body, therefore, is quite a complex body, for which reason, on a former occasion, I assigned to it the character of a nucleus, and regarded the so-called nucleus as the true nerve cell. The nucleolus of the ganglionic bodies of the spinal marrow of the fœtus under discussion, on the contrary, shows only a single contour, and the sole object it contains is the bright granule, which, however, is not as yet distinguished by a double contour, nor does it contain a dark granule in its centre.

In consideration of the fact, therefore, that the nucleolus is that part of the ganglionic body, which, last of all others,

attains its perfection, we cannot but suspect, that its office in the function of the ganglionic body must be an important one.

The ganglionic bodies of the cortical layer of the brain appear to attain their full development somewhat later than those of the spinal marrow, or even those of the medulla oblongata, or the larger cerebral ganglia, the corpora striata, etc. In the earlier periods of embryonic life, we have met only their first traces in the form of a few nuclei, to which some short granular fibrillæ were adhering. The first distinct traces I observed in embryos, measuring about 15 or 17 $\frac{5}{10}$  centimetres in length. The brain, at this period, from the third to the fourth month, still consists, in its greater part, of the granular substance and those nuclei already described before. A considerable portion of the granules, of course, are now arranged into rows. The force, however, which binds them to each other is still very feeble, so that they become very easily deranged and disconnected, even under the most delicate manipulation. Amidst these elements, a small number of ganglionic bodies are observed in different stages of development. Though, in those specimens, furthest developed, the granular mass completely embraces the nucleus; the processes proceeding from it are still short; they are usually from three to four in number (Fig. 16). As has already been remarked, in connection with the spinal marrow, those mother-cells filled with nuclei of a greenish lustre, and found in the matter of the brain and spinal marrow of an earlier embryonic period (Figs. 7 and 9), and serving for the multiplication of nuclei, are seen no more. The multiplication of these bodies is now accomplished by another mode, namely, by the process of budding, or germination. Thus, instead of those large mother-cells, we observe a number of nuclei of a greenish tint, provided with small, clear vesicles, which become ultimately detached, in order to be transformed into nuclei themselves (Figs. 16 and 24). A number of nuclei are also observed bearing one or more spherical depressions, the remaining traces of former vesicles. This mode of multiplication of nuclei, I described some time ago, in connection with the development of the smaller blood vessels in the human embryo.\*

---

\* Monthly Microscop. Journal, January, 1875.



Let us pass over now to a period of fœtal life, when the brain has attained such a degree of development, as to possess sufficient consistency to allow, after having been hardened in a weak solution of chromic acid, of making transparent sections, the only mode of preparation, which admits of an exact examination. In examining such a section of the cortical layer of the cerebrum of a fœtus, seven months old, we find the nervous elements, composing this layer, already arranged in regular order (Fig. 19). The ganglionic bodies have now assumed their later pyramidal form, their long-pointed processes can be distinctly seen stretching toward the surface of brain, also their lateral and local processes, pursuing their course laterally or downward toward the white substance. In some instances, even, I have observed a primitive axis cylinder in the form of granular fibrillæ, arising from one of the latter processes. A considerable number of granular fibrillæ are seen running vertically from the surface toward the white substance. They represent the future double-contoured nerve fibres. Numerous free nuclei, distributed between the ganglionic bodies, are seen imbedded in the granular substance. But the most interesting of all these parts, composing the cortical layer, is the fine terminal network of nervous fibrillæ, distinctly seen to extend throughout this substance. We see, therefore, that although these anatomical elements of the cortical layer of the cerebrum are not fully developed, they are, nevertheless, already arranged in perfect order, and we must not be surprised to see a fœtus, born at the end of the seventh month, live without detriment to the development of his mental faculties.

In the newly-born child, finally, we find the mental apparatus almost fully developed (Fig. 20). The ganglionic bodies have nearly obtained their full growth and structure. In some of them, the characteristic collections of dark-bordered pigment granules have also made their appearance. The rudimentary axis cylinder, which, in the fœtal brain of seven months, we observed arising from the basal processes of the ganglionic bodies, and pursuing their course toward the white substance, have now been developed into double contoured nerve-fibres. Nevertheless, some of the granular fibrillæ are still noticed among these fully developed fibres; and

I doubt not, but that the development of new axis cylinders continues as long as new ganglionic bodies are formed. In fact, it would be an interesting question to solve, until what time of life this last process goes on. Among the free nuclei, embedded in the granular substance of the cortical layer of the brain under discussion, I have several times observed two nuclei, overlapping each other, suggesting the question, whether they do not owe their origin to the division of one nucleus. Finally, the terminal net work of nervous fibrillæ is now as distinctly seen as in the adult brain; and, moreover, the fine branches of the long pointed process are observed to lose themselves in its meshes.

We have now arrived at the most difficult part of our subject, the study of the development of the sympathetic ganglionic bodies. The structure of these bodies has always been one of the most obscure subjects in histology, and hence the discrepancies, which have arisen concerning it, in the views and statements of different investigators. The chief difficulty in the examination concerns the characteristic capsule, which incloses the ganglionic body of the sympathetic nervous system and its relation to, and its connection with this body. Therefore, before giving a description of their development, I deem it necessary to recall to mind the structure of the fully developed sympathetic ganglionic body, as I have described it. According to my investigation,\* the sympathetic ganglionic body, which is generally round in form, consists of a large nucleus, surrounded by a mass of granules. From this mass, a number of larger and smaller processes are seen to arise; the whole enclosed in that peculiar membranous capsule. The *larger* processes, from one to four in number, after arising from the body, pierce the capsule, and disappear in the form of naked axis cylinders, at a distance of about  $\frac{6}{100}$  mm. or more, among the neighboring bundles of sympathetic nerve fibres. What becomes of them is not certainly known, but I have reason to believe, that they are finally transformed into dark-bordered nerve fibres. The *smaller* processes, arising from the body, are more numerous than the former, and consist mostly of only two or even one fibrilla. After a short course alongside of the body, they enter the

---

\* Transactions of the American Neurol. Assoc'n, 1865, p. 107.

capsule at its inner surface, and form, by means of ramification and reciprocal connection, a *network* extending throughout this membrane; the interspaces of the network are filled up by small granules. The capsule of the sympathetic ganglionic body, therefore, represents a *complicated membriform, nervous structure*, derived from and connected with the body, which it encloses. On the surface of the capsule, formed in this manner, a number of fine fibrillae arise from the network, a part of which pass, in the form of a finely reticulated plexus, over into the capsules of neighboring ganglionic bodies, and thus establish a reciprocal communication; the rest surround the axis cylinders arising from the larger processes and having pierced the capsule, and running in the same direction with these, unite among themselves to form finally the so-called *sympathetic nerve fibres*. Scattered over the inner as well as the outer surface of the capsule, a considerable number of round or oval nuclei are observed. They are especially numerous in the reticulated fibrillous plexus, connecting the ganglionic bodies with each other, whence they extend, while assuming a more oblong form, between the sympathetic nerve fibres.

As we have already seen in the preceding pages, there exists no essential difference in the formation of the primary ganglionic bodies of the cerebro-spinal axis and those of the sympathetic ganglia. They are all formed by an aggregation of granules around a pre-existing nucleus; from this granular mass, the processes arise, to be subsequently connected with the primitive nervous fibrillae. While, however, the cerebro-spinal ganglionic bodies attain their full development in this manner, those of the sympathetic system, must deviate from it, in order to form their characteristic capsule.

In embryos of  $5 \frac{6}{16}$  to  $5 \frac{9}{16}$  cm. in length we find the ganglionic bodies of the thoracic ganglia, as already mentioned, to consist of a nucleus, only surrounded by one or two layers of granules from which a few filamentous processes are seen to arise. These primary ganglionic bodies are embedded in the general mass of granules and nuclei, of which at this time the greater part of the ganglion still consists. A considerable portion of the granules, however, are arranged into rows, representing primitive nervous fibrillae. In fact, this was already

the case to some extent, as will be remembered, in the spinal ganglion of an embryo, only 16 mm. in length. But the adhesion of the granules is still too feeble, to prevent them from being deranged by the most delicate manipulation. It is for this reason, that the filamentous processes are always found to be torn (Fig. 21). In the *spinal* ganglia of the same embryo, however, the development of their ganglionic bodies is found to be considerably in advance of those of the thoracic ganglia. Not only have these bodies assumed a more definite form and gained in size: but they are already attached to each other by filamentous processes, forming small groups, as later in life, when they are fully developed (Fig. 22). Other bundles of fibrillæ are seen to arrive from them, uniting to form the sympathetic nerve fibres. It will be noticed, however, that there are, as yet, no nuclei attached to any of the nervous fibrillæ. In my previous descriptions of the structure of the sympathetic ganglionic bodies, I said, that I suspected their larger axis cylinder processes would be ultimately transformed into a dark-bordered nerve fibre. But in taking into consideration the reciprocal connection of these bodies by their larger processes, as seen in Fig. 22, it may be possible also, that by means of these processes, the destination of which is still unknown, a reciprocal connection is established between the ganglionic bodies of one and the same group.

Now, in examining a small group of ganglionic bodies of the spinal ganglion of an embryo,  $10 \frac{9}{10}$  ctm. in length, and about eleven to twelve weeks old, we behold the first traces of the formation of the capsule. It will be noticed here (Fig. 23), that some of the filamentous processes have become attached to the nuclei, lying between the ganglionic bodies. In the preparation, a number of processes have been torn from the bodies by the manipulation.

A few weeks later, in the embryo of about four months, and  $17 \frac{5}{10}$  ctm. in length, the formation of the capsule is seen more distinctly. The fine filamentous branches arising from a number of the processes of the ganglionic bodies, have now commenced to unite with each other, in order to form the filamentous network of the capsule. At the same time, they are observed to adhere to the numerous nuclei, surrounding the ganglionic bodies.

Fig. 24, *a*, represents a ganglionic body of a thoracic ganglion of this embryo; it illustrates the formation of the capsule better, than it can be described, for it shows distinctly the ramifications of the processes, the communication of the filaments in forming the meshes of the network, and their attachment to the nuclei. In *b*, of the same figure, we behold some of the nuclei, entangled in the filamentous mass found between the ganglionic bodies.

In Fig. 25, which represents a ganglionic body of a spinal ganglion of the same embryo, the formation of the network of the capsule is still more distinctly seen.

In studying the formation of the capsules of the sympathetic ganglionic bodies on the preparations just described, it must be remembered that they have been made by separating the component anatomical parts of minute portions of a ganglion, with finely pointed needles, and that it is impossible to avoid tearing and displacing some of these parts. It is for this reason, that we do not see the anastomosing nervous filaments with their nuclei surrounding the ganglionic body while forming the rudimentary capsule, but observe them only attached to the processes of the body. In the fœtus of six and a half months of age, however, the first cervical sympathetic ganglion has attained a sufficient size to allow thin transparent sections to be made, after it has been hardened in a weak solution of chromic acid.

Such a section we find represented in Figs. 26 and 27. In examining Fig. 26, we observe three capsules, cut at one and the same level. The ganglionic bodies, being exposed by the section, are seen in the interior of the capsules. While in the fresh specimen, however, the ganglionic body nearly fills the interior of the capsule, we find in this instance the granular mass of the body considerably contracted by the action of the chromic acid. The processes which, in consequence of this contraction, have to a certain degree been put on the stretch, appear somewhat larger; they are subdividing, and the branches resulting from this subdivision are seen ramifying throughout the wall of the capsule, forming the network. From the outer surface of the different capsules, small bundles of nervous fibrillæ are seen to arise, joining with each other in their course in order to form larger nerve bundles. This preparation also

shows how the component anatomical elements of adjoining capsules run into each other. The nuclei are seen dispersed in the capsules and in the reticulated plexus, arising from these. In examining this preparation, it must be remembered, that a number of the smaller processes have been torn off by the knife in making the section, and furthermore, that the structure of the capsule has, as yet, not attained its perfection.

In Fig. 27, which was copied from the same section, we see the outer surface of a capsule. The network or plexus, formed by the nervous fibrillæ, derived from the ramifications of the smaller processes of the ganglionic body, is here very distinctly exhibited, and, moreover, small bundles of fibrillæ may be observed arising from it, to finally join a neighboring bundle of nerve fibres.

In making a final review of the facts elicited by these investigations into the development of the nervous tissues, described in the preceding pages, we first notice, that these tissues are not developed in the true sense of the word from pre-existing cells, as was formerly supposed, but, on the contrary, are developed by the aggregation of pre-existing minute granules, which either collect around a pre-existing nucleus, as in the formation of the ganglionic bodies; or arrange themselves into rows, as in the formation of the fibrillæ of the axis cylinders.

The principal anatomical elements, then, taking part in the formation of the nervous tissues, are a mass of pre-existing minute granules with a special material binding them to each other,—the intermediate substance, as I have occasionally called it,—and a large number of pre-existing nuclei. The granules, together with the intermediate substance, may be regarded as the protoplasm of these primitive formations.

Nevertheless, in more minutely comparing the development of an organic cell with that of the nervous tissues, we cannot fail to recognize a certain analogy between the two processes. This exists in the formation of the *wall* in the one instance, and the formation of the *sheath* of the axis cylinder, as well as that of the ganglionic body in the other instance. As the wall of the cell, namely, is formed by a condensation of the protoplasm, taking place at its surface, so, I believe, the sheath of the axis cylinder and that of the ganglionic body, are

formed by a condensation of the intermediate substance, which not only connects the individual granules of the nervous fibrillæ with each other, but also surrounds the fibrillæ themselves. Thus the ganglionic bodies of the nervous system may still be regarded in the light of organic cells, which, multipolar in form, would send the ramifications of their processes, in the form of nervous fibrillæ, to the various peripheral organs.

The view has been held, and perhaps still is, by some anatomists, that the great nerve centres, the brain and spinal marrow, were the first parts of the nervous system formed, and that the nerves, regarded as simple processes, or prolongations arising from these centres, were growing outwardly into the tissues, finally to arrive at the periphery. In the preceding pages it has been shown, that this is by no means the case, but, on the contrary, that the peripheral nerve fibres are sooner developed than those of the centre; and, furthermore, that the nerve fibres arrive at their full development sooner, than the ganglionic bodies. As regards the tissues of the different parts of the nervous system, we find that they attain their full development first in the sympathetic ganglia, especially in the spinal; next in the spinal marrow, and last in the brain. This order of development might be expected, for it truly corresponds with the different grades of functions, namely, the *vegetable, animal* and *mental*.

#### EXPLANATION OF PLATES.

FIG. 1.—Human embryo, 6 mm. in length; nat. size.

FIG. 2.—Human embryo, 9 mm. in length, nat. size; *a*, anterior, *b*, lateral and *c*, posterior view.

FIG. 3.—Human embryo of 16 mm. in length.

FIG. 4.—Elementary forms of striated muscular fibres, from the upper extremities of the embryo, represented in Fig. 3.

FIG. 5.—Primary muscular fibre from the tongue of the same embryo, with its fibrillæ separated from each other.

FIG. 6.—Spindle shaped bodies (cells) of the primary muscular fibre of the auricles of the heart of the same embryo.

FIG. 7.—Primary anatomical elements of the brain of embryo, Fig. 2; *a*, nuclei and granules; *b*, mother cells, containing a brood of nuclei; *c*, primary elements of blood vessels.

FIG. 8.—Nervous matter of the brain of embryo, Fig. 3; *a*, white substance; *b*, grey substance; *c*, nuclei with nervous filaments adhering to them; *d*, different forms of clear mother cells, described in the text.

FIG. 9.—*a*, minute portion of the pia mater of embryo, Fig. 3, with nervous matter adhering; *b*, groups of clear mother cells; *c* large mother cells, containing a brood of nuclei of a greenish lustre.

FIG. 10.—Minute portion of spinal marrow from embryo, Fig. 3, showing the formation of nervous fibrillæ.

FIG. 11.—Bundle of nervous fibrillæ from the brachial plexus of an embryo, about nine weeks old.

FIG. 12.—Nervous bundle from the root of a spinal nerve of an embryo, three and a half months old; it illustrates the formation of the axis cylinders.

FIG. 13.—Nerve fibres from the brachial plexus of the same embryo, showing the formation of the nerve medulla and the tubular membrane; *a*, primitive axis cylinder; *b*, nerve fibre with single contour; *c*, nerve fibre with double contour.

FIG. 14.—Minute portion of gray substance from the upper part of the spinal marrow of an embryo, three and a half months old, showing the formation of ganglionic bodies.

FIG. 15.—Ganglionic body from the dorsal region of the spinal marrow of the same embryo.

FIG. 16.—Nervous matter from the brain of a fœtus, four months old, showing the formation of ganglionic bodies, and the process of multiplication of nuclei by germination.

FIG. 17.—Communicating ganglionic bodies from the spinal marrow of the same fœtus.

FIG. 18.—Minute portion of spinal marrow of a fœtus four and a half months old.

FIG. 19.—Thin transparent section of the cortical layer of the cerebrum of a fœtus seven months old.

FIG. 20.—Thin section of the same layer of the cerebrum of a fœtus at full term.

FIG. 21.—Ganglionic bodies from a thoracic sympathetic ganglion of an embryo, about nine weeks old.

FIG. 22.—Group of sympathetic ganglionic bodies from a spinal ganglion of the same embryo.

FIG. 23.—Group of sympathetic ganglionic bodies from spinal ganglion of an embryo, from eleven to twelve weeks old.

FIG. 24.—*a*, sympathetic ganglionic body from the thoracic ganglion of an embryo of four months, showing the formation of its capsule; *b*, nuclei, entangled in nervous fibrillæ during the formation of the capsule.

FIG. 25.—Sympathetic ganglionic body from a spinal ganglion of the same embryo, also illustrating the formation of the capsule.

FIG. 26.—Thin transparent section of the first cervical sympathetic ganglion of a fœtus six and a half months old, showing the structure of the capsule.

FIG. 27.—External surface of a capsule, showing the network or plexus of nervous fibrillæ, also the bundles of fibrillæ arising from it, and joining a neighboring nerve bundle.

The above figures are magnified 420 diameters, with the exception of the first three.





