

10/9

109 G



22101689393

Med
K7799



VERTEBRATE
EMBRYOLOGY

COMPRISING
THE EARLY HISTORY OF THE EMBRYO AND
ITS FOETAL MEMBRANES

BY

J. W. JENKINSON, M.A., D.Sc.

LECTURER IN EMBRYOLOGY, OXFORD
FELLOW OF EXETER COLLEGE

OXFORD
AT THE CLARENDON PRESS

1913

45 921

HENRY FROWDE, M.A.
PUBLISHER TO THE UNIVERSITY OF OXFORD
LONDON, EDINBURGH, NEW YORK, TORONTO
MELBOURNE AND BOMBAY

WELLCOME INSTITUTE	
LONDON	
Coll.	WELLCOME
Class	
No.	QS



TO .

A. A. W. HUBRECHT

PREFACE

THE publication in 1885 of Francis Balfour's great treatise on *Comparative Embryology* marked the first attempt to establish on a scientific basis our knowledge of the development of the animal organism.

Since Balfour's day embryology has travelled far, and a multitude of new discoveries has thrown fresh light on the structure, origin, maturation, and fertilization of the germ-cells, on the mechanism of segmentation, on the significance of the germinal layers, as well as on the later organogeny in the several groups.

But while abroad all this material has found embodiment in such comprehensive manuals as those of Oskar Hertwig on Vertebrate, and of Korschelt and Heider on Invertebrate Embryology, hardly any serious endeavour has so far been made in this country to review the fresh data or to revise or enlarge the general conclusions drawn by Balfour.

It is true, of course, that several admirable text-books of Vertebrate embryology have been issued, among which those of Milnes Marshall, of Minot in America, and of Bryce are particularly worthy of mention, but these are all directed primarily to the needs of the medical student and are consequently somewhat limited in their scope.

It would seem, therefore, that the hour is ripe for a re-statement of the facts and a renewed examination of the problems that they raise, and the object of the present work is to supply this want, if only for one group of animals, the Vertebrata.

The Vertebrates have, however, provided the material for so many investigations that much may be learnt of the general questions alluded to from them alone.

But modern research has by no means been restricted to the inquiry into the first stages of development.

Thanks very largely to the splendid labours of Hubrecht on the structure and development of the foetal membranes and

placenta of the Mammals, a flood of light has been shed on much that was previously obscure in the early history of the human embryo.

The account of the general development of the embryo is therefore followed by a discussion of these embryonic organs, a discussion which I trust may be of genuine service to the medical man. No knowledge of human ontogeny can, however, be really sound which is not based upon and seen in the light of the broad facts of comparative embryology, and I hope that the earlier chapters will prove of value to the student of medicine as well as to the professed zoologist.

The detailed organogeny of the Vertebrates is outside my present aim, and must be reserved for a future volume.

The illustrations have been drawn especially for the book, with the exception of a few taken from my *Experimental Embryology*. Where the figure is a copy due acknowledgement is made.

At the end of each chapter a list will be found of the principal authorities cited; the student who desires further information may consult the complete bibliography to be found in Oskar Hertwig's *Handbuch der Entwicklungslehre der Wirbeltiere*.

It is a pleasant duty to express my obligations to the Delegates of the Clarendon Press, in particular to Sir William Osler, and to their Secretaries for the pains that have been expended in the production of this volume.

CONTENTS

	PAGE
CHAPTER I	
INTRODUCTION	9
CHAPTER II	
GROWTH	15
CHAPTER III	
THE GERM-CELLS, THEIR ORIGIN AND STRUCTURE	23
CHAPTER IV	
THE GERM-CELLS, THEIR MATURATION AND FERTILIZATION	62
CHAPTER V	
SEGMENTATION	95
CHAPTER VI	
THE GERMINAL LAYERS	110
CHAPTER VII	
THE EARLY STAGES IN THE DEVELOPMENT OF THE EMBRYO	153
CHAPTER VIII	
THE FOETAL MEMBRANES OF THE MAMMALIA	192
CHAPTER IX	
THE PLACENTA	215
INDEX OF SUBJECTS	259

CHAPTER I

INTRODUCTION

EMBRYOLOGY is the study of the development of the individual organism—that is to say, of that long and frequently complex series of changes whereby from a relatively simple germ there is produced a new individual which, within the limits of ordinary variation, is like the parents that give it birth. Development, in other words, is the production of the form characteristic of the species; it is the mechanism of inheritance. The starting-point of the process may be a single cell, which is either a fertilized ovum or at any rate the product of the union of two cells, as in all cases of sexual reproduction, or else an unfertilized egg-cell, as in parthenogenesis. Again, the ‘germ’ from which the new organism is to arise may be a multicellular body derived from one or more of the tissues of the parent, as in budding. Lastly, in regeneration, or the replacement of lost parts, where a new whole form is produced over again from a part of the original—whether that part is large or small—the process starts from a multicellular and a differentiated structure.

As a matter of common practice, however, the term ‘development’ is often restricted to the first of these processes, and in the Vertebrates with the greater justification in that reproduction by budding does not occur in the group, although regeneration does. Neither has natural parthenogenesis ever been observed. Reproduction, then, in Vertebrates means sexual reproduction, and the developing individual springs from the union of two germ-cells.

These germ-cells are the vehicles whereby the inheritable characters of the species are handed on from one generation to the next; they are the material basis of inheritance.

In the study of this process two methods are at our disposal. Either we may content ourselves with a description of the series of changes which the ovum passes through, or else we may add

experiment to observation in the attempt to discover the causes of each stage in the chain of events, and so of the whole. In the present treatise we shall limit ourselves to the former of these two inquiries.

In every development there are involved three kinds of activity—growth, cell-division, and differentiation.

Growth is increase of size, more properly of mass.

Cell-division, preceded always by karyokinetic division of the nucleus, is the first, or nearly the first, sign the fertilized ovum gives of its activity, and continues throughout the period of development, indeed throughout life itself, though at a diminishing rate.

But these are, relatively speaking, side issues. The problem about which interest really centres is the problem of differentiation, or increase of structure. The egg has indeed a structure, but that structure is not the structure of the parent that produced it, nor of the offspring to which it will give rise. It is more simple, and in development structure is increased, the simple gives way to the complex.

The process takes place in a series of stages which follow upon one another in regular order and with increasing complexity. When segmentation has been accomplished certain sets of cells, the germ-layers, become separated from one another. Each germ-layer contains within itself the material for the formation of a definite set of organs—the endoderm, for instance, contains the material for the alimentary tract and its derivatives—gill-slits, lungs, liver, bladder, and the like. The germ-layers are, therefore, not ultimate but elementary organs, and elementary organs of the first order.

In the next stage these elementary organs become subdivided into secondary organs—the ectoderm is portioned into epidermis, sense-organs, and nervous system—and in subsequent stages these again become successively broken up into organs of the third and fourth orders, and so on, until finally the ultimate organs and tissues are formed each with special histological characters of its own, as seen in the arrangement, shape, and size of the cells, structure of the nucleus, structure of the cytoplasm, and nature of the substances secreted by the latter,

whether internally, as, for example, the contractile substance of muscle fibres, or externally, as in the matrix of bone. This end is, however, not necessarily reached by all the tissues at the same time. Indeed, it is no uncommon thing for certain of them to attain their final structure while the others are yet in a rudimentary condition. Vacuolated notochordal tissue, for instance, is differentiated in the newly-hatched tadpole of the frog, and, speaking generally, larval characters are developed at a very early stage.

Regular sequence of events, then, is one of the features of ontogeny, or the development of the individual, and another is composition, since the organs of the body are by no means formed of single tissues—bone, epithelium, blood, and the rest—but are compounded, often of very many.

While, therefore, in the last resort all differentiation is histological, that final result, the assumption by the cells of their definitive form, is only achieved after many changes have taken place in the position of the parts relatively to one another while the organs are being compounded, and so its specific shape being conferred upon the whole body.

But manifold though the changes are that occur in the relative position of the parts, they may all be embraced in a comparatively few general expressions, relating to the movements of single cells, or of cell-aggregates.

I. MOVEMENTS OF SINGLE CELLS

Amongst movements of single cells are comprised :

1. The migration of free amoeboid cells, for example, the lower layer cells in the blastoderm of Elasmobranchs, and the wanderings of the germ-cells in early stages.

2. The aggregation of isolated cells :

a. Linear aggregates, as in the formation of capillaries.

b. Superficial aggregates, as in the formation of the yolk-sac of certain Mammals.

c. Massive aggregates, as in the spleen.

3. The attachment of isolated cells to another body, as in the union of tendon to bone, or the application of skeletal cells to the notochord.

4. Investment and penetration by isolated cells, as in the septa of the corpus luteum, the cells which secrete the vitreous humour in the eye.

5. Absorption by wandering cells, as in the phagocytosis of the tadpole's tail during metamorphosis.

6. To these we may add here the frequent movements involving merely change of shape, as when flat cells become columnar, or when a nerve fibre grows out from a nerve-cell.

II. MOVEMENTS OF CELL AGGREGATES

A. Linear Aggregates

1. Growth in length, as in the back growth of the segmental duct.

2. Splitting.

a. At the end, that is, branching, for example, of nerves, blood-vessels, kidney-tubules, glands.

b. Throughout the length ; for instance, the segmental duct of Elasmobranchs, the truncus arteriosus of Mammals.

3. Anastomoses, as of nerves in the formation of nerveplexuses, of capillaries, of the bile-capillaries of the liver.

4. Fusion with other organs : of a nerve, for instance, with its end organ, of the vasa efferentia with the tubules of the mesonephros.

B. Superficial Aggregates

1. Increase in area, of a curved or of a plane superficies, as in the growth of the Mammalian blastocyst, or in that of the auditory vesicle, or of the medullary tube, or of the blastoderm over the yolk.

When this growth is not equal in all parts of the surface the result is a local outgrowth or ingrowth—that is, an evagination, as in the outgrowth of the optic vesicles, or of the cerebral hemispheres, or an invagination, as in the formation of the medullary groove, or of the lens of the eye.

2. Alterations of thickness, by increase, as in the formation of the placenta from the trophoblast in Mammalia, or by decrease, as in the roof of the thalamencephalon and medulla, or in the outer wall of the lens.

3. Interruptions of continuity by the atrophy of part of a layer, as in the disappearance of Rauber's cells in certain Mammalian embryos, or in the perforation of the floor of the archenteron in Amniota, or by the detachment of a part of the layer, as when the notochord is lifted out of the archenteric roof in Urodela and *Petromyzon*.

4. Concrecence of layers, as in the union of the embryonic plate with the trophoblast in some Mammals, where the layers unite by their margins, or as in the union of the medullary folds, or of the stomodaeum with the gut, where the concrecence is by the surfaces. In the latter case the cavities on opposite sides of the adherent layers commonly open into one another, as when the stomodaeum opens into the gut, or the amnion folds unite; but not necessarily, as when the somatopleure fuses with the trophoblast, or the allantois with the somatopleure.

5. Splitting of a layer into two, for example, in the inner wall of the pineal vesicle in Lacertilia.

C. Massive Aggregates

1. Changes in volume and shape, as in the outgrowth of limb-buds.

2. Rearrangement of material, as in the formation of the concentric corpuscles of the thymus, or in the development of kidney tubules in the metanephric blastema of Amniota; or again, when internal cavities are formed, such as the segmentation cavity, lumina of ducts and blood-vessels, of the coelom; or, lastly, by the dispersion of the cell-elements of an aggregate, as in the liberation of the germ-cells.

3. Division of masses, as in the metameric segmentation of the mesoderm and neural crest, or the separation of the (solid) nervous system from the ectoderm in *Petromyzon*, and Teleostei.

4. Fusion of masses, as in the union of originally separate ganglia.

5. Attachment of one mass to another, as of sclerotome to notochord.

Differentiation then takes place by these various movements of cells and of cell aggregates, and by the final assumption by the cells of the histological characters appropriate to each tissue.

The cells all arise from the continued subdivision of one original cell, the fertilized ovum.

But while this process of division is apparently necessary for development, it must not be supposed that it is the division which brings about the differentiation, for the simple reason that some differentiation already exists in the ovum before segmentation begins. Indeed, as we shall see in the sequel, the ovum is no homogeneous mass, but a heterogeneous body, provided with a definite structure, and this initial structure is the real cause of the differentiations that subsequently arise. A scientific account of development must therefore begin with the structure of the germ-cells.

For convenience' sake, however, we may first discuss very briefly the chief features of the phenomenon of growth.

LITERATURE

C. B. DAVENPORT. Studies in morphogenesis: iv. A preliminary catalogue of the processes concerned in ontogeny. *Bull. Harvard Mus.* xxvii, 1896.

J. W. JENKINSON. *Experimental Embryology.* Oxford, 1909.

CHAPTER II

GROWTH

GROWTH may be defined as increase in size or volume. Since then growth is increase in all three dimensions of space, it is most accurately measured not by increase in some one dimension—such as stature—but by increase of mass or weight.

Growth depends upon the intake of food and the absorption of water, and exhibits itself in the form of increase of living matter or of secretions of watery or other substances, organic or inorganic, intra-cellular or extra-cellular, such as chondrin, fat, mucin, calcium phosphate, and the like.

That growth depends—in later stages at least—upon the intake of food is obvious. That it is due to the absorption of water has been demonstrated effectively for the tadpoles of Amphibia (*Amblystoma*, *Rana*, *Bufo*). The method employed was to weigh known numbers of the tadpoles at different ages, desiccate and weigh again. The results of the investigation are shown in the accompanying figure (Fig. 1), from which it will be seen that the percentage of water rises with remarkable rapidity—from 56% to 96%—during the first fortnight after hatching. After that point the amount of water present slightly but steadily declines.

In later development the proportion of water slowly falls, as may be seen more fully from the tables following, for the chick and for the human embryo.

TABLE I

Showing the percentage of water in chick embryos at various stages up to hatching. (From Davenport, after Potts.) The table also shows the hourly percentage increments of weight.

Hours of brooding.	Absolute weight in grammes.	Increase.	Hourly percentage increment.	Percentage of water.
48	0.06			83
54	0.20	0.14	38.3	90
58	0.33	0.13	16.0	88
91	1.20	0.87	7.9	83
96	1.30	0.10	1.7	68
124	2.03	0.73	2.0	69
264	6.72	4.69	1.6	59

TABLE II

Showing the percentage of water in the human embryo at various stages up to birth. (From Davenport, after Fehling.) The table also shows the weekly percentage increments of weight.

Age in weeks.	Absolute weight in grammes.	Increase.	Weekly percentage increment.	Percentage of water.
6	0.98			97.5
17	36.5	35.52	331.2	91.8
22	100.0	63.5	34.8	92.0
24	242.0	142.0	71.0	89.9
26	569.0	327.0	67.6	86.4
30	924.0	355.0	15.6	83.7
35	928.0	4.0	0.1	82.9
39	1640.0	512.0	13.8	74.2

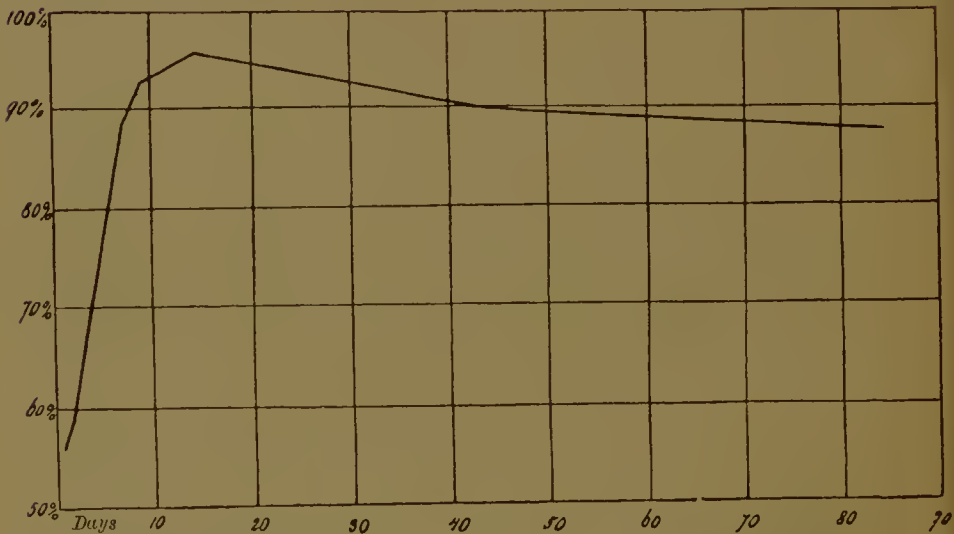


FIG. 1.—Curve showing change in percentage of water in frog tadpoles from the first to the eighty-fourth day after hatching. Abseissae, days; ordinates, percentages. (After Davenport, from Korschelt and Heider.)

There are other external factors by which growth may be affected—such as heat, light, and atmospheric pressure. We cannot consider these now. We may, however, profitably turn our attention for a moment to one feature which is characteristic of growth in general, of the growth of the animal organism under normal conditions, and that is the change that takes place during growth in the rate of growth itself.

The rate of growth may be measured by the percentage increments of weight (or of other measurements where weight

is not available) during a given interval of time ; that is to say, by expressing the increase in weight during a given period as a percentage of the weight at the beginning of that period. The change of rate, if any, is found by taking such percentage increments for successive equal increments of time.

As a first example let us consider the data furnished by Minot for the rate of growth, after birth, of guinea-pigs.

TABLE III

Showing the change of rate of growth in male and female guinea-pigs, as measured by daily percentage increments of weight. (From Minot.)

Age in days.	Mean daily percentage increments.		Age in months.	Mean daily percentage increments.	
	Males.	Females.		Males.	Females.
1-3	0.0	2.1	8	0.05	0.2
4-6	5.6	5.5	9	0.3	0.2
7-9	5.5	5.4	10	0.1	0.1
10-12	4.7	4.7	11	0.04	0.1
13-15	5.0	5.0	12	0.1	0.05
16-18	4.1	4.3	13	-0.2	0.3
19-21	3.9	3.5	14	0.5	-0.03
22-24	3.1	1.7	15	0.2	0.00
25-27	2.8	1.9	16	0.07	0.2
28-30	2.8	2.6	17	-0.1	-0.02
31-33	1.9	1.8	18	-0.05	-0.2
34-36	1.7	1.6	19-21	0.006	-0.1
37-39	1.9	1.8	22-24	0.02	-0.05
40-50	1.2	1.1			
55-65	1.3	1.3			
70-80	1.2	0.8			
85-95	0.9	0.9			
100-110	0.7	0.8			
115-125	0.6	0.5			
130-140	0.1	0.2			
145-155	0.4	-0.03			
160-170	0.3	0.5			
175-185	0.2	0.2			
190-200	0.2	0.2			

An inspection of the accompanying table and figure (Fig. 2) will show at once that there is in both sexes almost from the moment of birth a decline in the growth-rate. The decline is not, however, uniform.

The rate falls rapidly between about the fifth day (when it is from 5% to 6%) and the fiftieth, from the fiftieth day onwards more slowly, becoming eventually very small, zero or even negative.

The younger the animal, therefore, the faster it grows; the more developed it is the more slowly it grows. The rate of growth, in fact, diminishes as development proceeds.

This post-natal decline in the rate of growth is a continuation of a process which has been going on for some time, perhaps from the first movement at which growth began.

This may be gathered from the data given for the human embryo in Table II, and is graphically represented in the curve (Fig. 3).

For the study of the post-natal growth of man numerous data have been collected by various observers. Quetelet's measure-

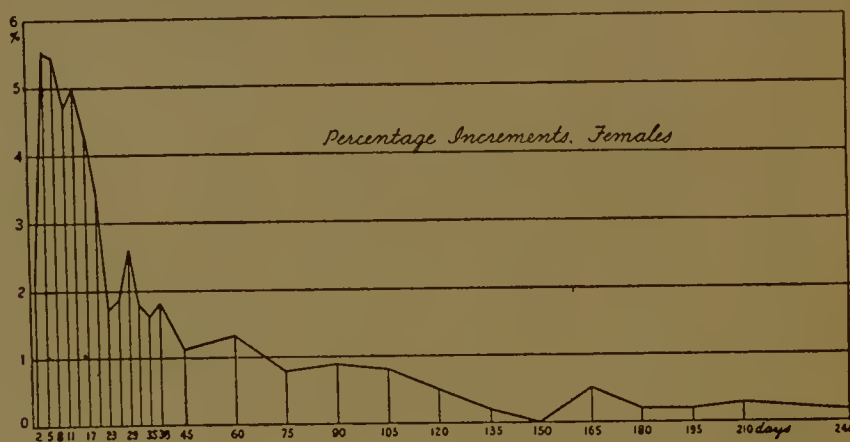


FIG. 2.—Curve showing the daily percentage increments in weight of female guinea-pigs. (From Minot, 1907.)

ments for boys are shown in the accompanying figure (Fig. 4). This shows that at the end of the first year after birth the percentage increment is as high as 200%, or nearly, but that then this increment drops to just over 20% at the end of the second year. From this point onwards the decline is slow but sure, until at the thirtieth year the annual percentage increase is only 0.1%. The change of rate of growth in females is practically the same as in males.

The monthly percentage increment immediately before birth is about 20%; according to the curve (Fig. 4) this represents an annual percentage increment of, say, 250%, and the annual increase at the end of the first year is about 200%. The post-natal is, therefore, a continuation of the pre-natal change.

There are, further, two points at which the rate diminishes with great rapidity: between the fourth and sixth months of

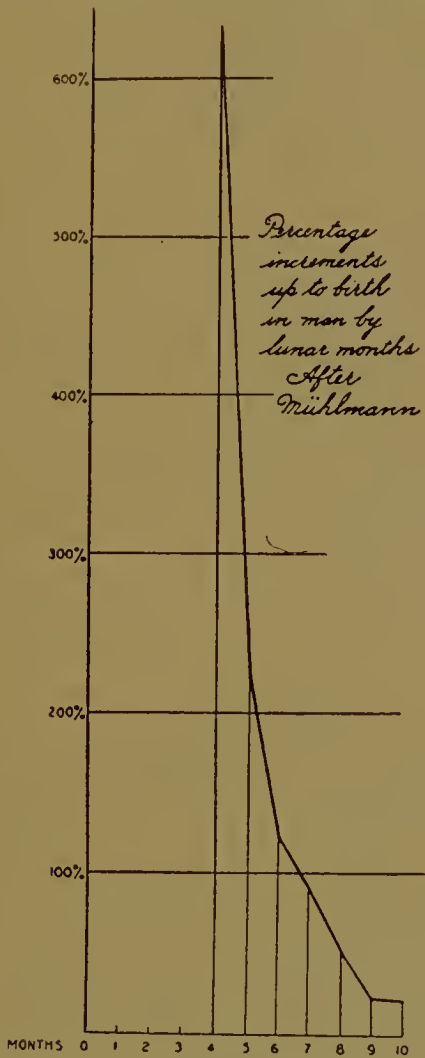


FIG. 3.—Curve showing monthly pre-natal percentage increments in man. (From Minot, 1907.)

pregnancy and between the first and second years after birth. Elsewhere the diminution is gradual.

A point of importance is that in both sexes there is a slight temporary rise in the growth-rate about the time of puberty (see the curve). This rise is always earlier in females than in males.

A comparison of the growth of these two mammals is interesting.

A guinea-pig reaches 775 grammes in 432 days.

A man „ 63,000 grammes in 9,428 days.

The average percentage increments are

Guinea-pig 0.47 grammes.

Man 0.02 „

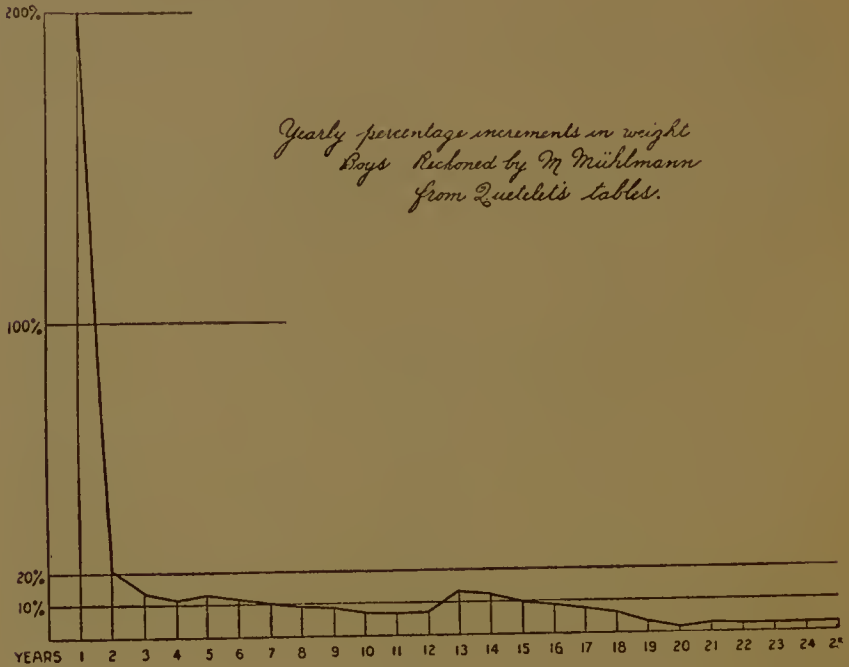


FIG. 4.—Curve showing the yearly percentage increments in weight of boys. (From Minot, 1907.)

In the human being, therefore, growth is much slower than in the guinea-pig, and man is only eventually the bigger of the two because he goes on growing for so much longer.

It is of course a commonplace of embryology that the growth of all the organs of the body does not proceed at the same rate. The parts, however, obey the same law of diminishing rate as does the whole. This may be seen in the figure (Fig. 5) in which the changes in the rate of increase of the human being in respect of stature, head-length, length of vertebral column, and length of leg are shown.

The progressive loss of growth power is spoken of by Minot as 'senescence'. The same author has brought forward some evidence to show that during differentiation there is an increase

in the amount of cytoplasm in the cell, a decrease in the size of the nucleus, and a decrease in the rate of nuclear and cell-division. It is suggested that differentiation and senescence alike depend on an increase in the cytoplasm. During segmentation,

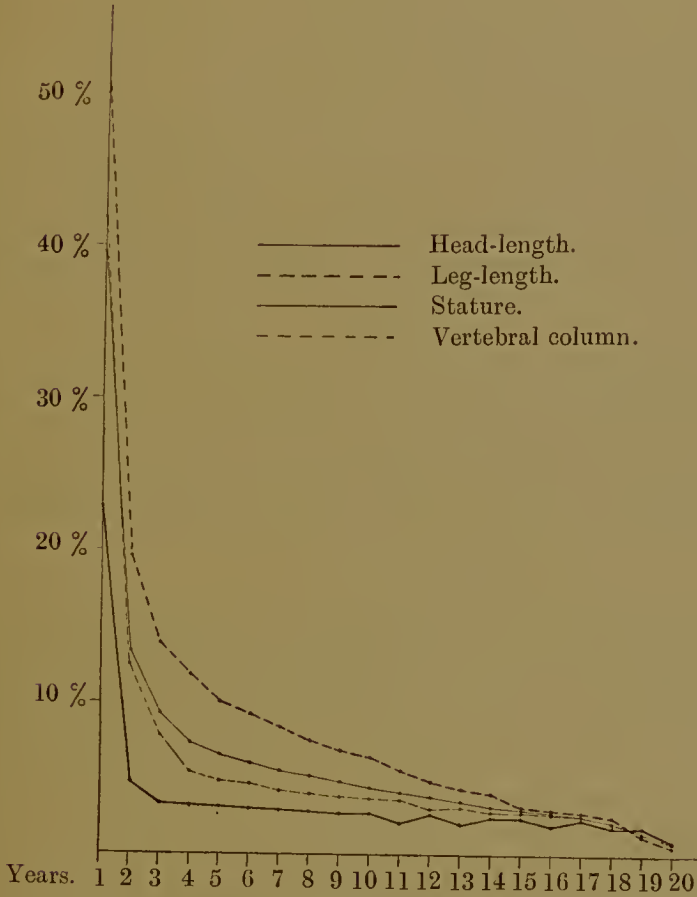


FIG. 5.—Curves showing the alteration during the first twenty years of life of the rate of growth of stature, length of head, length of vertebral column, and length of leg in the human being (males). (Constructed from Quetelet's data.) Ordinates, percentage increments; abscissae, years.

that is, the initial process of cleavage of the fertilized ovum, before differentiation begins, the reverse of this occurs, for, as we shall see later on, the essence of segmentation probably lies in a reduction of the cytoplasmic matter relatively to the nucleus until a definite ratio between the two is attained. Then differentiation sets in.

LITERATURE

F. BOAS. The growth of Toronto children. *U.S.A. Report of the Commissioner of Education*, ii, 1897.

C. B. DAVENPORT. The rôle of water in growth. *Proc. Boston Soc. Nat. Hist.* xxviii, 1899 (1).

J. W. JENKINSON. *Experimental Embryology*. Oxford, 1909.

C. S. MINOT. Senescence and rejuvenation. *Journ. Phys.* xii, 1891.

— The problem of age, growth, and death. *Pop. Sci. Monthly*, 1907.

A. QUETELET. *Anthropométrie*. Bruxelles, 1870.

NOTE.—Although in the foregoing account I have adhered to Minot's method of measuring the rate of growth by the percentage increment, I should point out that T. B. Robertson (*Arch. Ent. Mech.* xxv, xxvi, 1908) has proposed to measure the rate simply by the average increment per unit of time over a short interval of time. Thus if we call the magnitude measured, say the weight, at any moment x , and after a certain interval of time Δt suppose the weight to have increased to $x + \Delta x$, then $\frac{\Delta x}{\Delta t}$, the increment during this interval per unit of time, measures the rate. Minot's percentage increment is of course $\frac{\Delta x}{\Delta t} \times \frac{100}{x}$.

The graph of the growth-rate constructed by Minot's method, as in the figures given above, descends rapidly at first, more gradually later, and so presents a likeness to the graph of the rate of a unimolecular chemical reaction.

The graph of the growth-rate constructed by the other method is quite different, rising from a minimum to a maximum and descending to a minimum once more. (In the human being there are three or four cycles each with its maximum.) Now this graph resembles that of the rate of an autocatalytic unimolecular reaction, as Robertson has pointed out, a rate which, as the equation

$$\frac{dx}{dt} = k(x)(A-x)$$

states, depends at any moment on the change that has already occurred (x) and on that which has still to occur ($A-x$) before the end-point (A) of the reaction is reached.

Robertson suggests that growth is based on chemical reactions of this kind, and that its rate at any moment depends on x , the amount of growth already accomplished, and $A-x$, that which has still to take place before the whole growth (A) is completed.

It follows from the equation just cited that the velocity ($\frac{dx}{dt}$) is at a maximum when $x = \frac{A}{2}$, i. e. when the reaction is half over, and the theory that growth takes place in this way may be tested by finding whether the growth-rate really is at a maximum when growth is half completed. Other ways of testing the theory are by comparing the observed ($\frac{\Delta x}{\Delta t}$) with the theoretical ($\frac{dx}{dt}$) growth-rates, and the observed with the theoretical values of x at different times. Robertson has applied the test to the growth of the human being and some other organisms, and found the agreement between observed and calculated values to be fairly good.

Since the equation quoted above may be written approximately

$$\frac{\Delta x}{\Delta t} = k(x)(A-x)$$

or

$$\frac{\Delta k}{\Delta t} \times \frac{1}{x} = k(A-x),$$

it will be seen why Minot's growth-rate curve should be similar to that of a unimolecular reaction the equation for which is

$$\frac{dx}{dt} = k(A-x).$$

CHAPTER III

THE GERM-CELLS

THE male and female germ-cells—the spermatozoon and ovum—are highly specialized structures and as different from one another—except in their nuclei—as any two cells could well be, the former being a small, active body, the latter large and inert. But though so unlike in their completed form, they are derived from cells which are apparently identical in the two sexes, the primordial germ-cells.

During the development and growth of the body of the parent which encloses them, these primordial germ-cells pass through a series of changes, the final result of which is the formation of the ova and spermatozoa. The history of these changes is very similar in the male and in the female. In each case it may be divided into three periods, a period of multiplication, a period of rest and growth, and a period of maturation (Fig. 6).

In the male sex the primordial germ-cells divide to form small cells, the spermatogonia, which in their turn divide a large number of times. In all these divisions the nucleus divides by karyokinesis, and the number of chromosomes formed at each division is the same as that observed in all the tissue-cells of the body. This somatic number is constant for any given species of animal (or plant), and is (except in certain insects and some other forms) an even number. We shall speak of it as $2n$.

After a time, however, these spermatogonia cease dividing and enter upon the second period of rest, during which they grow. The growth is not very great, but quite well marked. During this time the nucleus undergoes intricate changes which are the prophases of the first maturation division. The male germ-cells are now known as primary spermatocytes.

At the end of the resting period the primary spermatocytes prepare once more to divide. Each is halved to form two secondary spermatocytes, the nuclear division being of an altogether peculiar

character, and the number of chromosomes reduced to one-half (n) of the normal number. Each secondary spermoeyte then divides again to give rise to two equal cells, the spermatids, the number of chromosomes being again one-half that observed in

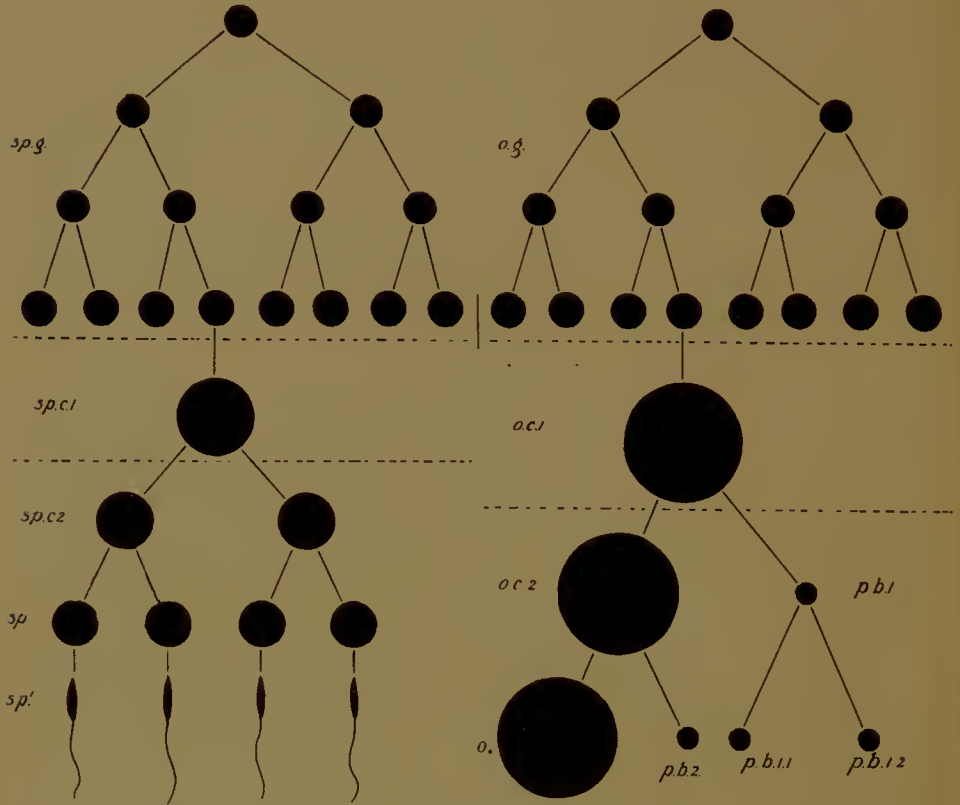


FIG. 6.—Diagram to illustrate the history of the germ-cells in the male (on the left) and the female (on the right).

I. Period of multiplication (many more divisions occur than are here represented).

II. Period of rest and growth.

III. Period of maturation. *Sp.g.*, spermatogonia; *sp.c.1*, primary, *sp.c.2*, secondary spermoeytes; *sp.*, spermatids; *sp.'*, spermatozoa; *o.g.*, oogonia; *o.c.1*, primary, *o.c.2*, secondary oocyte; *o.*, ovum; *p.b.1*, first polar body; *p.b.2*, second polar body; *p.b.1.1*, *p.b.1.2*, halves of first polar body. (After Wilson, after Boveri.)

the spermatogonia. Each spermatid becomes directly metamorphosed into a spermatozoon, there being no further division.

In the female the primordial germ-cells divide to produce oogonia, and these in their turn divide, the nucleus breaking up into the full number of chromosomes ($2n$). When the period

of multiplication has come to an end each oogonium rests while the nucleus passes through the prophase of the first maturation division. The whole cell then grows into a primary oocyte. This growth is much greater than in the male sex, since it is during this time that the yolk is deposited in the cytoplasm to the accompaniment of other and very complex nuclear changes. In the third or maturation period the ovum, like the spermatozoon, undergoes two divisions, and two only; but whereas in the male these two divisions are equal, giving four spermatids, eventually four spermatozoa of the same size, in the female they are markedly unequal. The primary oocyte divides unequally into a large cell—the secondary oocyte—and a small cell, the first polar body, the number of chromosomes being reduced to n . A second unequal division results in the production of one large cell—the mature ovum—and a small cell, the second polar body; meanwhile the first polar body has divided (usually) into two small cells of the same size. The number of chromosomes is again one-half the normal number.

The parallel between these processes in the two sexes is evident, since each primary spermocyte or oocyte by two divisions produces four cells, each one of which possesses only one-half the number of chromosomes seen in the spermatogonial and oogonial mitoses. While, however, in the male the four cells are all of the same size, in the female one, the ovum, is large, while the remainder are small.

The germ-cells are supported, invested, and nourished in the testis and ovary by certain elements known as follicle-cells. These, like the primordial germ-cells, appear at an early stage in the development of the parental body, and our first duty will be to inquire into the origin of both. We shall then be at liberty to discuss the structure and chemical composition of the mature sexual elements, the disposition of the protecting follicles, the nature of the membranes by which the ovum is enclosed, the intracellular and nuclear processes accompanying the deposition of the yolk, the nuclear phenomena involved in the reduction of the number of the chromosomes during the two maturation divisions, the metamorphosis of the spermatid into the spermatozoon, and finally the union of the two germ-cells in the act of fertilization.

I. THE ORIGIN OF THE GERM-CELLS AND OF THE FOLLICLE-CELLS

The gonads—testes and ovaries—first appear, at an early date in the development of the embryo, in the form of what are known as the genital ridges. The genital ridges are a pair of longitudinal bands of tissue in the abdominal region, each placed between the root of the mesentery of the gut on the inside and the Wolffian body or mesonephros on the outside, and each projecting downwards into the peritoneal cavity.

Each genital ridge is covered by the peritoneum or coelomic epithelium, which is here usually columnar. Under this epithelium are a number of small cells which are probably derived by proliferation from the epithelium itself, together with others which come from the retro-peritoneal tissue behind. In addition there are conspicuous certain large cells—usually with large nuclei unlike those of the surrounding cells and in many cases with yolk-granules in the cytoplasm, derived from the yolk of the egg from which the embryo itself has arisen. These large cells are placed some in, some below the epithelium. They are the primordial germ-cells, and their position in the columnar epithelium covering the genital ridge has very naturally given rise to the belief that they are formed by modification *in situ* of the cells of that epithelium, which has hence been termed the germinal epithelium. The researches of recent years have, however, brought forward very strong evidence to show that the first germ-cells are not formed in or from the germinal epithelium, but elsewhere in the body, and that they only reach what is to be their final resting-place by migrating there, the source from which they spring being in general the endoderm or splanchnopleure (mesoderm) of the gut or yolk-sac. Later on, however, it is generally admitted that germ-cells may arise from the germinal epithelium. This is also probably the source of the future follicle-cells, since these are derived from the small cells which are proliferated from that epithelium. The other small cells, retro-peritoneal, give rise to the thecae of the follicles and to the vascular connective tissue (stroma) of the ovary or testis. Let us consider a few cases.



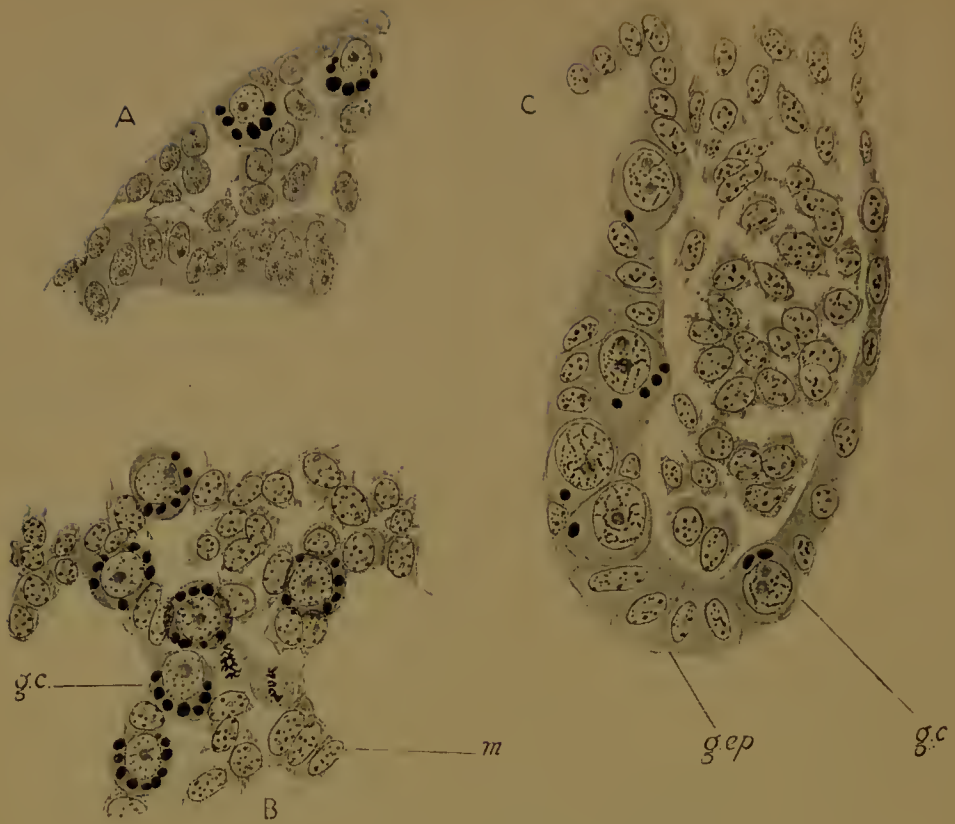


FIG. 7.—Primordial germ-cells in the dogfish (*Scyllium*).
 A, Germ-cells in the mesoderm surrounding the gut.
 B, Germ-cells (*g.c.*) creeping up the mesentery (*m.*).
 C, Germ-cells in the germinal epithelium (*g.ep.*) of the genital ridge.
 The yolk-granules are beginning to disappear.

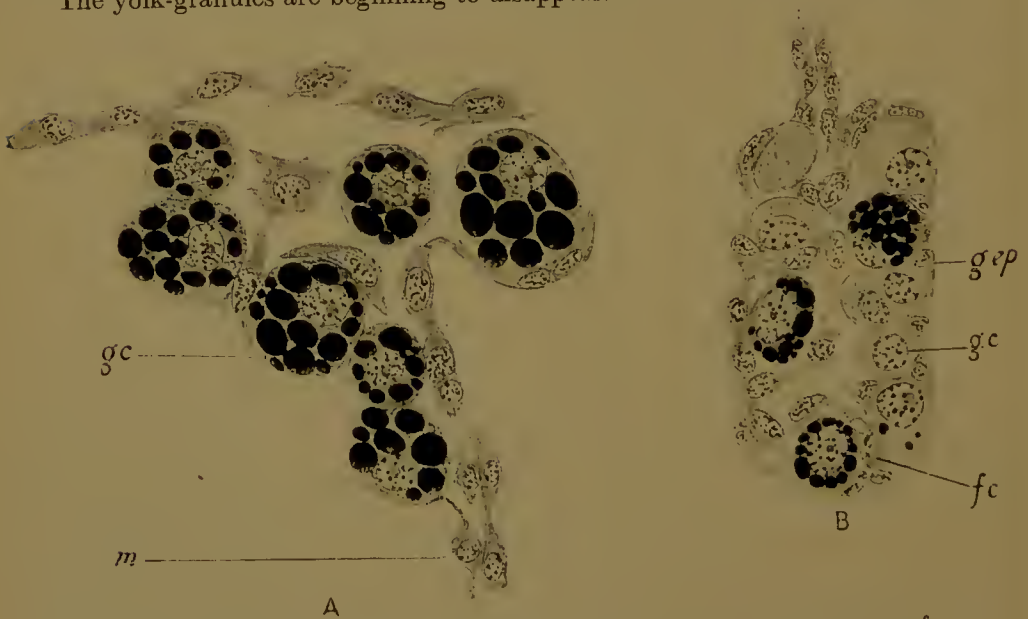


FIG. 8.—Primordial germ-cells (*g.c.*) in the tadpole of the common frog (*Rana temporaria*). A, In the mesentery (*m.*); B, In the genital ridge.
g.ep., germinal epithelium; *f.c.*, follicle-cell.

In the Elasmobranch fishes the germ-cells are first found in the extra-embryonic blastoderm, either between the yolk and the mesoderm, or under the ectoderm. Thence they migrate into the body of the embryo by way of the yolk-stalk (Fig. 7); passing up by the splanchnopleure surrounding the gut, sometimes in the gut epithelium itself, they reach the mesentery, and thence to right and left into the two genital ridges, where they make their way into the epithelium. The cells are large, the cytoplasm crowded with yolk-granules, which, however, are presently digested and disappear, the nucleus large, provided with a large nucleolus, its chromatin in the form of small granules. The accompanying table (from Woods) gives the number found in the unsegmented mesoderm or ventral to the mesentery, in the mesentery, and in the genital ridges, in successively older embryos of *Acanthias*, and clearly establishes the migration of these cells.

Length of embryo in mm.	Total number of germ-cells.	Number in unsegmented mesoderm or ventral to mesentery.	Number in mesentery.	Number in genital ridges.
2.75	98	98	—	—
3.5	230	230	—	—
6.0	256	222	—	34
8.0	296	154	73	69
11.5	408	78	137	193
34.0	710	—	—	710

More germ-cells are later on formed from the germinal epithelium.

In the lamprey (*Petromyzon*) the primordial germ-cells, similar in character to those of the Elasmobranchs, first appear in the lateral plate mesoderm, whence they migrate to their definitive position.

So also in the trout and salmon: in these there is also a later formation of germ-cells from the epithelium of the ridges.

In another bony fish (*Cymatogaster*) the sex-cells can be distinguished even in segmentation stages; later they are found at the posterior end of the body (where all the germ-layers are fused together), whence they move forwards into the mesoderm of the genital ridges.

Amongst the Amphibia the germ-cells of the frog appear at

an early stage, in the newly-hatched tadpole; they are derived from the large yolk-cells of the gut. Being separated off on the dorsal side they move up the mesentery (Fig. 8), and so, passing to the right and left, reach the genital ridges. The cells are at first crowded with yolk, but this soon disappears; the nuclei are not peculiar.

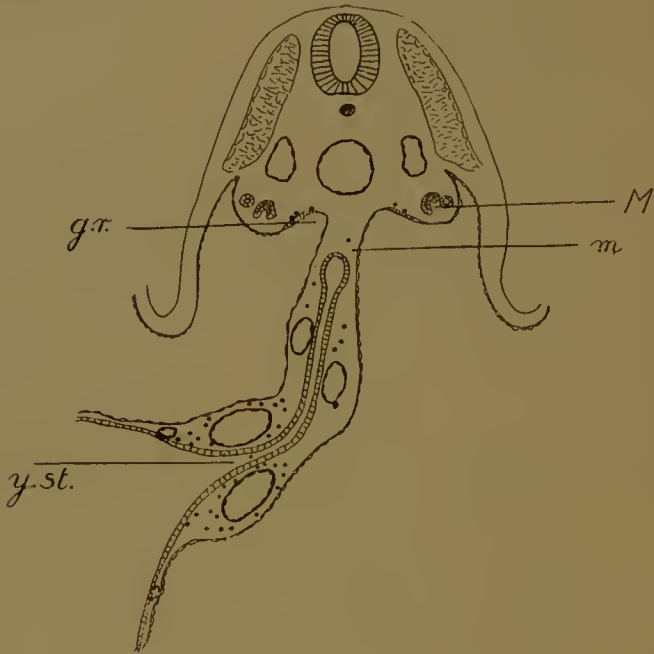


FIG. 9.—Section of a 12-day rabbit embryo, showing the migration of the primordial germ-cells (indicated by black dots). Most are in the yolk-stalk mesoderm, some in the mesentery (*m*), some in the genital ridge (*g.r.*) internal to the mesonephros (*M*). *y.st.*, opening of the yolk-stalk into the yolk-sac.

It is remarkable that, in the female at any rate, many of these young germ-cells are expelled from their follicles and disintegrate in the peritoneal cavity. There is an extensive formation of fresh ones by modification of cells of the germinal epithelium, which is also the source from which the follicle-cells are derived. The theca comes from retro-peritoneal tissue. (An account of the follicle and the theca will be found in a subsequent section.)

When we pass to the Reptiles we find the same migration taking place. In the tortoises (*Chrysemys*) the sex-cells arise in the endoderm of the yolk-sac posteriorly. Becoming amoeboid

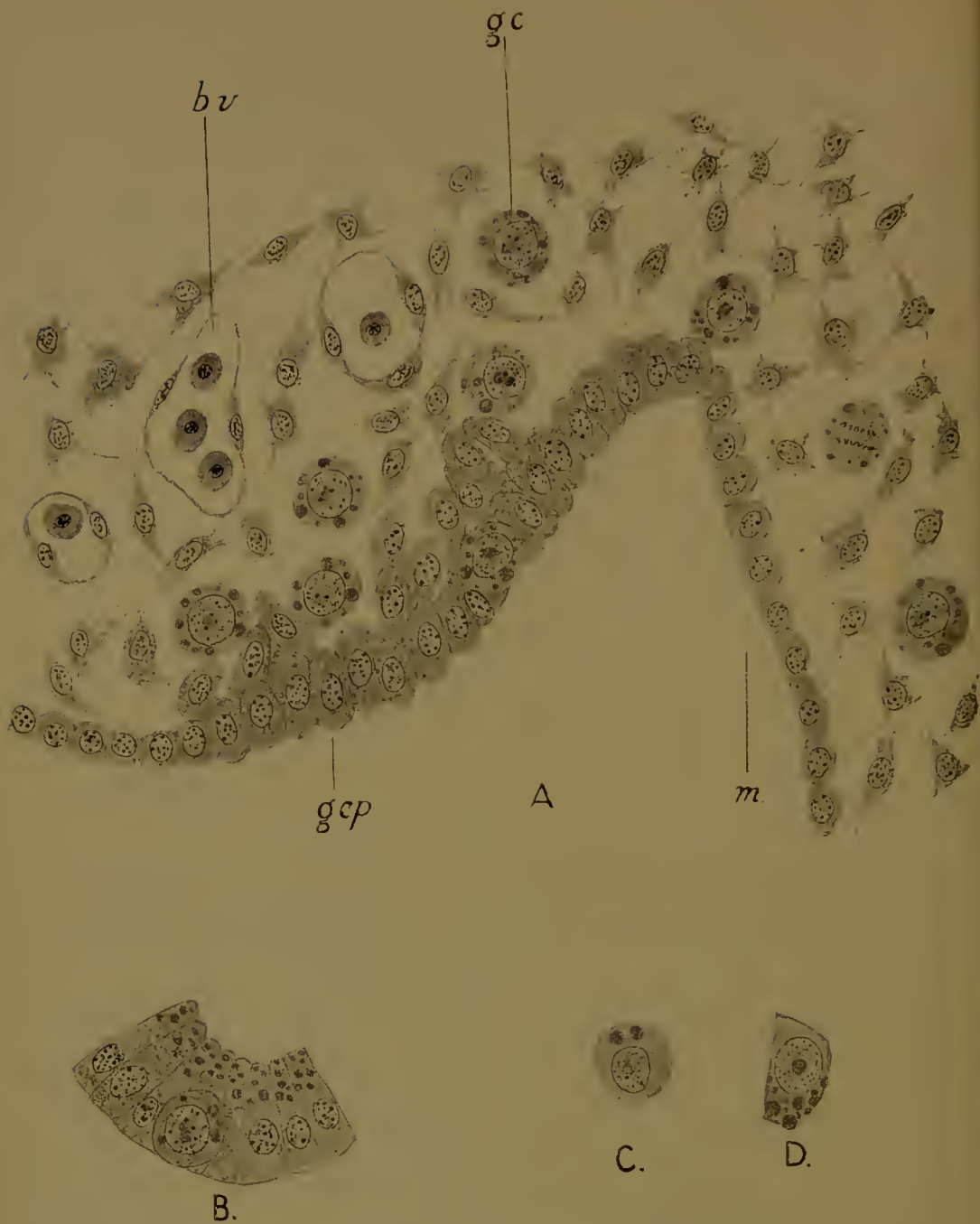


FIG. 10.—Primordial germ-cells (*g.c.*) in the rabbit.
 A, Early stage in the formation of the genital ridge, covered by the germinal epithelium (*g.ep.*). Below this are some germ-cells and connective tissue and blood-vessels (*b.v.*). Germ-cells are also seen in the mesentery (*m.*).
 B, A germ-cell in the epithelium of the gut.
 C, One from the yolk-stalk.
 D, An epithelial cell from the yolk-sac.

they migrate towards the middle line into the embryonic region. Passing out of the endoderm into the splanchnopleure (the mesoderm covering the gut), they travel up the mesentery into the ridges. Many, however, fail to reach their destination, and remain for some time in the epithelium of the gut. It is stated that in this animal no germ-cells are ever formed from any other source.

In the Birds, again, the germ-cells appear early, in a chick on the third day of incubation. They seem to originate from the splanchnopleure of the yolk-sac, and pass, in the way already described, to the genital ridges, and there into the germinal epithelium. By the fifth day the migration is complete and the cells begin once more to multiply.

In all these cases the identification of the primordial germ-cells is considerably facilitated by their retention of yolk-granules at a time when these bodies have disappeared from the surrounding cells.

In the (placental) Mammals, however, where there is practically no yolk, the distinction of these cells from the surrounding elements is a matter of some difficulty, and it has been, and is still contended, that the germinal epithelium is their only place of origin. Nevertheless, there is good reason for believing that the Mammalia are no exception to the general rule.

In a rabbit embryo of eleven or twelve days (Figs. 9, 10) there are to be found in the splanchnopleure of the yolk-stalk large numbers of rounded cells, distinguishable from the surrounding cells by their cytoplasm—which includes large oxyphile granules—and their nuclei, which are round and large, with a fine achromatic reticulum bearing small granules of chromatin. The nuclei consequently look pale. There is one, sometimes more, large nucleolus. In all these respects the cells bear a close resemblance to the large cells in the endodermal yolk-sac epithelium (Fig. 10 D). Precisely similar cells may be found in the body of the embryo—round the sides of the gut, and sometimes in the gut epithelium, in the mesentery, and finally below and in the columnar epithelium (germinal epithelium) internal to the mesonephros, which is the beginning of the genital ridge. In earlier stages the same cells are found in increasingly smaller numbers in the genital

ridges and mesentery, in increasingly larger numbers in the yolk-stalk and endoderm. It can hardly be doubted, therefore, that the same migration of these cells from the yolk-sac to the genital ridges is occurring here as we have already observed in other forms. There is equally little doubt that these cells, arrived at the genital ridges, become germ-cells.

In the rabbit embryo of twelve days the genital ridge (Fig. 10 A) is very slight, consisting of a band of columnar epithelium, below which are a few cells derived probably by immigration

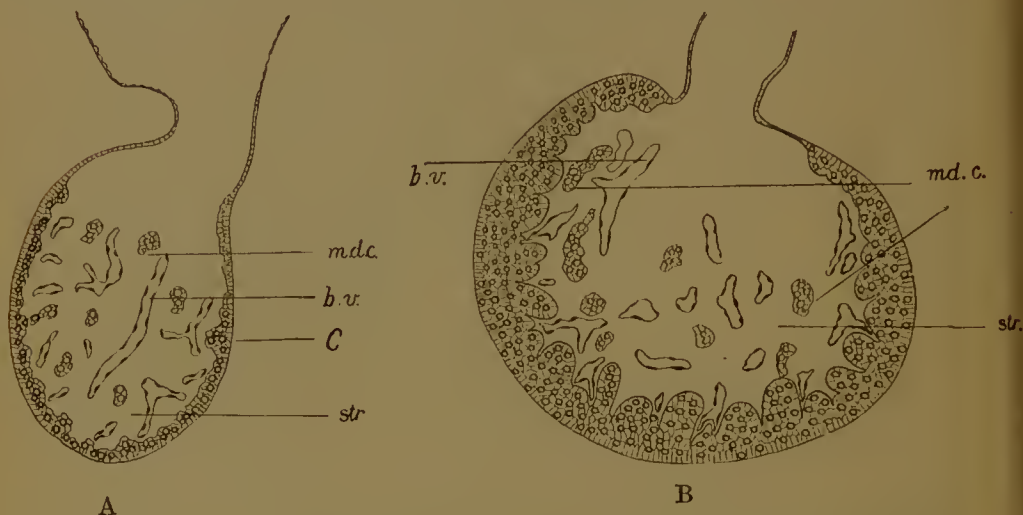


FIG. 11.—Ovary of rabbit from embryos of A, 18 days, and B, 21 days, showing formation of cortex (*C*) and medulla. *b.v.*, blood-vessels in stroma (*str.*) of medulla; *md.c.*, medullary cords.

from that epithelium. These cells differ from the germ-cells amongst which they lie in their nuclei—which are oval in shape, have more than one nucleolus, and a more open reticulum with coarser granules of chromatin, and are of smaller size—and in their cytoplasm—which includes no granules. Those which lie below the surface are destined to give rise to the follicle-cells, which will eventually be disposed in layers round the germ-cells. Deeper still are connective tissue-cells and blood-capillaries derived from the retro-peritoneal tissue; from these will come the thecae and the vascular stroma. Let us follow the development of this genital ridge into the sexual organ, and first into the ovary.

The whole genital ridge is enlarged and made to project into

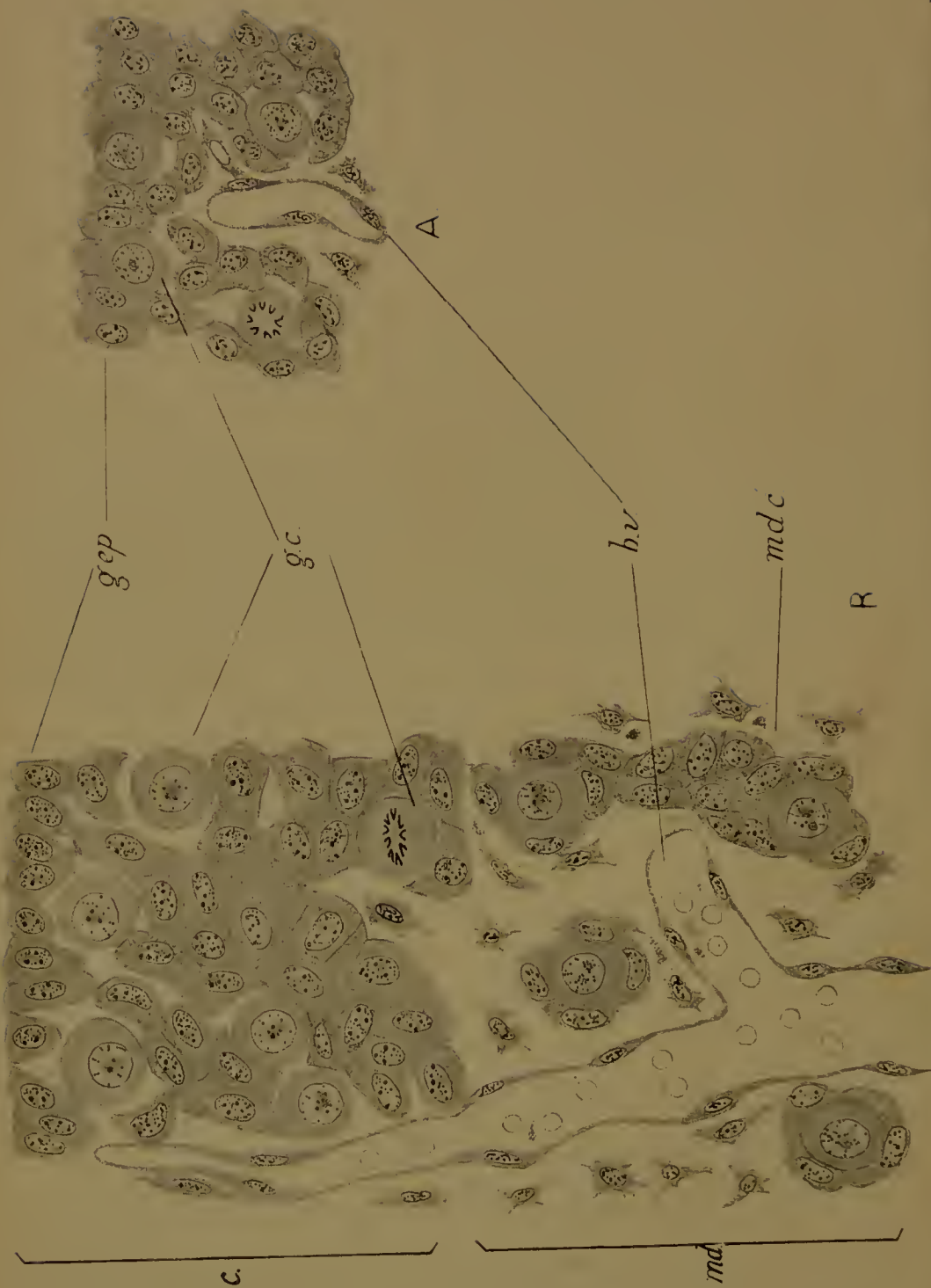

FIG. 12.—A, Ovary of 18-day embryo of rabbit; section through cortex. B, 21 days, part of the medulla is shown as well. *g.c.*, germ-cell; *g.ep.*, germinal epithelium; *e.*, cortex; *m.c.*, medulla; *m.c.*, medullary cord; *b.v.*, blood vessel.

the body-cavity by the increase of the connective tissue elements and blood-vessels, or stroma, which thus forms a central core or medulla to the whole organ. At the same time, by continued proliferation of the germinal epithelium at the surface, an external layer or cortex is formed. The germ-cells lie mainly in this cortex, but a few—those presumably which in migrating to the genital ridge have never reached the surface—lie in the stroma, where they are grouped in rows known as medullary cords (Figs. 11 A, 12 A). They seem to degenerate.

The cortex increases in thickness and becomes divided up into columns or blocks by the ingrowth of vascular connective tissue from the stroma. These columns—which were at one time believed to be produced by hollow invaginations of the germinal epithelium and known as the epithelial tubes of Pflüger—are the sex-cords (Figs. 11 B, 12 B). They consist of follicle-cells derived in all probability from the germinal epithelium, and of germ-cells which have migrated into their present position from their source, the yolk-sac. The germ-cells have been increasing in numbers: in the resting condition their nuclei present the same characters as before. The cytoplasm, however, loses the oxyphile granules. At about the twenty-second day the germ-cells cease to divide and enter on the period of rest: they are in fact primary oocytes, and their nuclei begin to undergo the changes characteristic of the prophases of the first maturation division.

This mode of origin of the germ-cells does not of course preclude the formation of others from the cells of the sex-cords, that is, from the germinal epithelium, and it is indeed quite possible that this occurs.

In the mouse and other Mammals (guinea-pig, mole, cat) the germ-cells appear to come from a similar source. In the mouse they are large cells with rounded bodies, dense, rather deeply-staining cytoplasm, and large nuclei, with a close reticulum, small, scattered chromatin granules and one or two large nucleoli (Fig. 13 A). They divide by mitosis for a time, but pass into the resting condition at a comparatively early date, about the fifteenth day (Fig. 13 B, C). They lie intermingled with a number of cells, the future follicle-cells, which may be regarded as of epithelial origin. The medulla of the ovary is formed late

(Fig. 13 E), when the nuclei of the germ-cells have already reached the pachytene¹ condition (see below), by ingrowth of connective tissue from the base; prior to this the whole thickness of the organ is composed of follicle-cells and germ-cells, with but a few capillary blood-vessels. The sex-cords ('tubes') of the cortex arise, therefore, not so much by downgrowths of epithelium as by rearrangement of the cortical, that is, follicle and germinal, and medullary, that is, stroma cells (Fig. 13*).

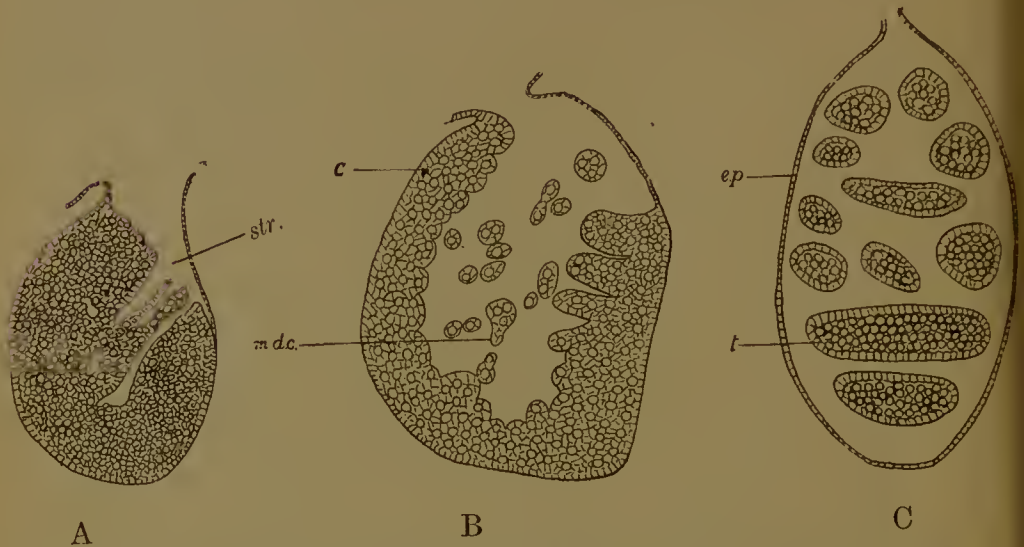


FIG. 13*.—A, B, Formation of medulla in ovary of mouse. *str.*, stroma of medulla; *m.d.c.*, medullary cords; *c*, cortex of germ-cells and follicle-cells.

C. Testis of embryo mouse. *ep.*, coelomic epithelium; *t.*, seminiferous tubules.

A few germ-cells are found in the medulla, but as in the rabbit, these probably never become mature. When the germ-cell nuclei have reached the diplotenic or dictyate stage (Fig. 13 F) (in the new-born animal) the formation of follicles begins, by the grouping of the follicle-cells round the oocytes, to form a single flat layer. At the same time the oocytes enlarge. These two processes always occur first at the deep end of the sex-cords. Later (Fig. 14) the cells of the follicle become cubical, and then increase in number till several layers are formed. Hence the

¹ A full explanation of this term will be found in the section of the next chapter dealing with maturation.

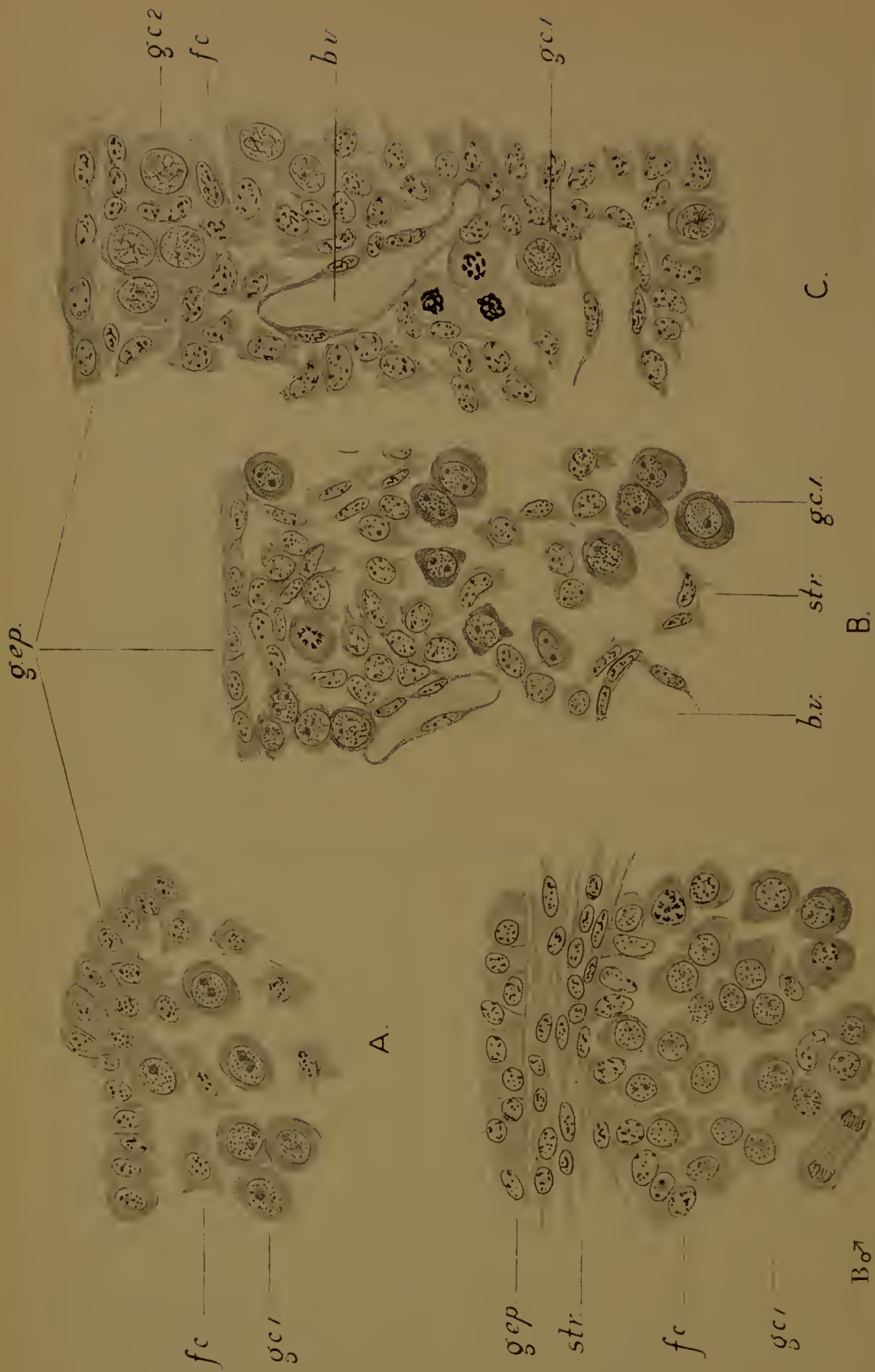


FIG. 13. A-C.—Primordial germ-cells and differentiation of the gonad in the mouse. A, Indifferent stage; B, C, Young ovary; B ♂, Young testis of the same age as B. f.c., follicle-cell; str., connective tissue-cells of stroma; b.v., blood-vessel; g.ep., germinal epithelium; g.c.i., primordial germ-cells with nuclei in the original condition; g.c.i., female germ-cells with leptotene nuclei.

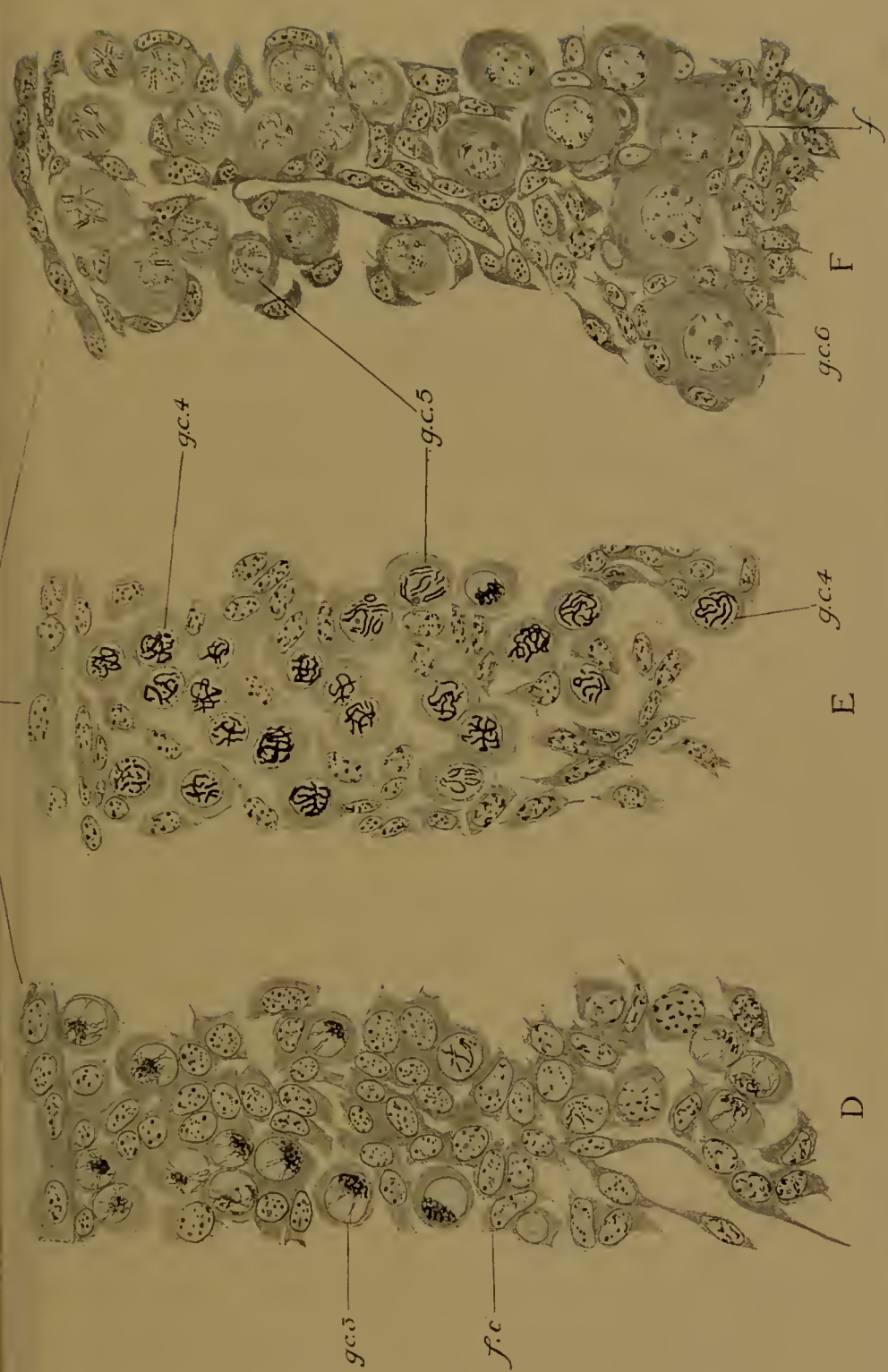


FIG. 13, D-F.—Further differentiation of the ovary in the mouse. *d.* Stage in which all the nuclei of the germ-cells are in the synaptonemal stage (*gc.3*). At this stage there is still no distinction between cortex and medulla, the whole ovary being occupied by germ-cells, follicle-cells (*fc.*), and a few stroma-cells and blood-vessels. *e.* Part of the cortex, the medulla having now been formed by ingrowth of connective tissue. The nuclei of the germ-cells are mostly in the pachytone condition (*gc.4*), but a few are diplotene (*gc.5*). *f.* Part of the cortex of the ovary of a now-born mouse. The oocytes in the deep part are beginning to enlarge and follicles of one cell-layer (*f*) are arranged round them; their nuclei are diplotene (*gc.6*). In the superficial part the oocytes are smaller, the nuclei diplotene (*gc.5*), and the follicles hardly formed.

cortex of the young ovary comes to comprise several layers of small oocytes, each surrounded by a single layer of flat cells under the surface, and larger oocytes, surrounded by cubical follicle-cells, disposed in the more advanced deeper down in

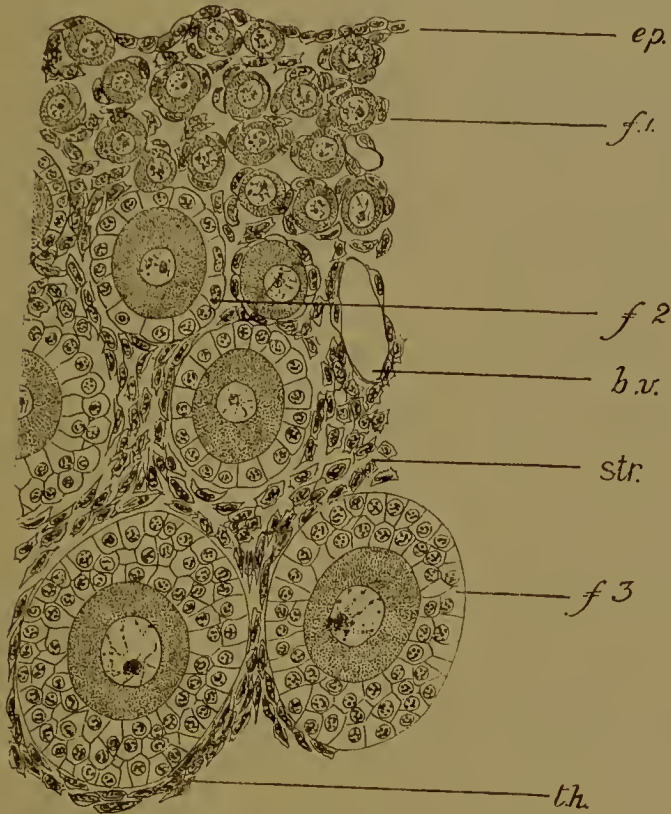


FIG. 14.—Part of cortex of ovary of young mouse (8 days). In the deeper parts the follicles (*f. 3*) consist of two- or three-cell layers, and the oocytes are large. In the middle layers the follicles (*f. 2*) are one-layered, but the cells are cubical, the oocytes smaller. Under the surface the oocytes are smaller still and the follicle-cell flat (*f. 1*). *ep.*, surface epithelium (germinal epithelium); *b.v.*, blood-vessel; *str.*, stroma; *th.*, theca.

many layers. It is not, therefore, that the follicles and oocytes enlarge as they pass in from their (supposed) origin at the surface, but that those which are inmost are the first to enlarge. The oocytes of the outermost layer often lie practically in the epithelium at this stage. Their nuclei, however, are not in the condition seen in newly-formed germ-cells (oogonia), but in the dictyate stage characteristic of oocytes.

In the male (Figs. 13 B♂, 13* c) the sex-cords become early shut off from the surface epithelium (peritoneum) by the formation of a sheet of connective tissue (*tunica albuginea*), and from one another in the same way. The sex-cords are the rudiments of the seminiferous tubules of the testis. Each consists of an outer layer of follicle-cells, and an inner mass of germ-cells, presenting the characters already described. These are spermatogonia and divide mitotically many times. Intermingled with them are a few of the follicle-cells. In this sex there seems to be no doubt that many of the first-formed germ-cells degenerate, and that in the adult fresh spermatogonia are differentiated from the basal follicle-cells.

The early segregation of the germ from the body or somatic cells, their first appearance in a part of the body remote from, and their gradual migration to their definitive position, are processes which find a parallel in many, if not in all, groups of the animal kingdom. Thus in the Hydroid Coelenterates, the germ-cells may originate in the manubrium of the medusa and migrate on to the radial canals, or, starting from the stem of the hydroid, they may move into the buds which become medusae or gonophores. In this migration they often pass forwards and backwards from one germ-layer to the other. In the round-worm *Ascaris* the parent cell of the germ-cells is distinguishable by certain nuclear peculiarities in the four-celled stage of the segmenting ovum. Similarly in the Crustacean *Cyclops*. In Cephalopod Mollusca and in Scorpions they become visible during the formation of the germinal layers, while in Insects they may be separated very early—prior to the appearance of the blastoderm—or rather later, but before the differentiation of the germ-layers, or later again from the hinder end of the mesoderm, and in all these cases they are obliged to migrate forwards into their definitive position in the walls of the coelom-sacs; lastly, they may be differentiated *in situ* from the germinal epithelium of the coelom. Here we have the closest parallel to the double origin which we have seen in the Vertebrates, either at an early date, independently of the mesoderm, with subsequent migration into the germinal epithelium, or at a later date, from the germinal epithelium itself. It is clear that no hard-and-fast

rule can be laid down. All the germ-cells may be precociously separated from the somatic cells and elsewhere than in the generative organ, or some may have such an origin, while others arise in the generative organ itself, or lastly, all may be developed by the second method, as appears to be the case in most Annelid worms and in Ascidians.

Nor need the conversion of what look like tissue-cells into cells endowed with the capacity of reproducing all the characters of the species cause any particular astonishment when the widespread capacity for regenerating lost parts possessed by the adult tissues, and the remarkable facts of bud-reproduction, are borne in mind. In these cases germ-plasm or reproductive substance must be present in the regenerating or budding tissues, and yet there is no obvious continuity between this germ-plasm and that of the germ-cell from which the regenerating or budding individual sprang; as little should we expect to find a demonstrable continuity in the case of sexual reproduction.

II. THE STRUCTURE OF THE MATURE GERM-CELLS

A. The Ovum

The egg-cell is large and inert: it is quite incapable of locomotion; only occasionally does it exhibit peristaltic contractile movements, as in the formation of the polar rings at the time of fertilization in Annelids, or slow changes of shape as in the protrusion of the animal ends of the blastomeres in *Petromyzon*, or the flattening at the animal pole of the frog's egg prior to segmentation.

In shape it is nearly always spherical: exceptionally, as in Myxinoids and *Amia*, ellipsoid or ovoid.

Size of the ovum. The ovum is always a large cell compared to other cells of the body, even where, as in Placental Mammals, it is actually very small, and it may be very large indeed, as in the large-yolked ova of most fishes, and of birds and reptiles. The size of the ovum is due to the contained reserve food material or yolk, the amount of which varies very greatly in the different groups.

A small-yolked (microlecithal) egg is found in the lamprey (*Petromyzon*) and in the Anurous and Urodclous Amphibia. In the frog the diameter of the ovum is about 1.6 mm. In the Gymnophiona, and most 'Ganoid' fishes (*Acipenser*, *Amia*, *Lepidosteus*), there is more yolk in the egg, while in the Myxinoid Cyclostomes, Elasmobranch and Teleostean Fishes, Reptiles, Birds, and Monotrematous Mammals, the egg is large-yolked (megalecithal). Finally, in the Placental Mammals—which are descended from large-yolked forms—the yolk has been reduced to a very small amount.

The following table brings out the contrast between the size of the eggs in the large-yolked Monotremes and the small-yolked other forms. It will be seen that amongst the latter the Marsupials have the largest ovum. In this respect, as in others, they are intermediate between the Monotremata and the Placentalia.

Monotremata :

<i>Echidna</i>	3-4 mm.
<i>Ornithorhynchus</i>	2.5 mm.

Marsupialia :

<i>Dasyurus</i>	0.28 mm.
<i>Didelphys</i>	0.13 mm.

Placentalia :

<i>Canis</i>	0.18 mm.
<i>Homo</i>	0.17 mm.
<i>Lepus</i>	0.15 mm.
<i>Ovis</i>	0.15 mm.
<i>Talpa</i>	0.09 mm.
<i>Cavia</i>	0.08 mm.
<i>Erinaceus</i>	0.06 mm.
<i>Mus</i>	0.06 mm.

The yolk. The yolk is frequently termed deutoplasm, in distinction from the living substance or protoplasm in which it lies. It is deposited in the cytoplasm of the ovum during the period of growth, in the form of small bodies spoken of as granules, globules, or platelets (Fig. 15). The size, shape, and structure

of these vary. In the lamprey, frogs and toads, newts and salamanders, the granules are oval or ellipsoid bodies, sometimes vacuolated. In the Elasmobranch fishes they are oval plates, sometimes spherical and vacuolated. In the Teleostean fishes the separate yolk-globules run together at an early stage to form one continuous yolk-mass. In the Birds there is white yolk and yellow yolk, the former consisting of small globules enclosing still smaller ones of varying size, while the latter is made up of




FIG. 15.—Yolk-granules. A, Dogfish. B, Axolotl, the smaller from the animal, the larger from the vegetative hemisphere. C, White yolk, D, yellow yolk, from the Hen's egg.

larger spheres, each including a multitude of minute droplets. In both kinds of yolk the smaller bodies are often set free by the rupture of the larger enclosing envelopes. In the Placental Mammals the yolk-granules are usually globular (Fig. 18, B). All the granules which have been mentioned are protein in nature, but in addition to these fat globules are not uncommon. Fat is present in the hen's egg, in some Mammalia (guinea-pig) (Fig. 18, c), while in the Teleostei a single large oil-drop is characteristically present (Fig. 72).

The chemical composition of the yolk of a hen's egg is as follows. The yolk—that is, the ovum—weighs from 12 to 18

grammes ; 47.2 % of this is water ; the remaining solids include

Protein	15.63 %
Salts	0.964 %
Fats	22.84 %
Lecithin	10.7 %
Cholesterin	1.75 %
	<hr/>
	51.884 %

The proteins include ovo-vitellin (for the greater part) and some albumin.

The former is not a globulin but a nucleo-proteid ; on digestion with pepsin it yields an iron-containing body, a pseudo-nuclein known as haematogen, since it is supposed that it is the source of the haemoglobin of the embryonic blood corpuscles. With the ovo-vitellin the lecithin of the egg is closely associated. The fats are oleates, palmitates, and stearates. With them must be included certain phosphatides.

The salts are chlorides of sodium, potassium, magnesium, and calcium.

The reaction of the yolk is alkaline. The colouring is due to lutein, a lipochrome.

Other ova have not been so fully investigated, but it is known that the ichthulin of certain fish eggs (carp, cod) is a nucleo-proteid, and lecithin (6 %) and nucleo-proteid (94 %) can be demonstrated in the yolk of the frog's egg. The significance of the presence of nucleo-proteids will be more evident when we consider later on the part played by the nucleus during the deposition of the yolk.

The yolk of the Monotreme egg is of a yellow colour. In the lamprey it is a faint yellow, in the dogfish greenish, in the Ganoid fish *Amia* brown. In Placental Mammals the yolk is colourless.

The yolk is not scattered irregularly through the cytoplasm, but arranged in a very definite fashion, known as the telolecithal ; that is to say, while the cytoplasm (or protoplasm) is concentrated on one side of the egg, the yolk (or deutoplasm) is concentrated on the opposite side. This does not imply, of course, that all

the yolk is on one side, all the protoplasm on the other side, but that most of the cytoplasm is on the one, with fewer and smaller yolk-granules, while on the other the yolk-granules are more abundant and larger, with less cytoplasm in between them. The transition from one extreme to the other in a small-yolked egg such as that of an Amphibian is quite gradual (Fig. 16): there is a graded diminution in the concentration of cytoplasm,




FIG. 16.—Diagram of a meridional section through a full-grown oocyte of the frog. The yolk-granules are represented by stippling, the pigment by the thin black line. The arrow marks the egg-axis, its head the animal pole.

an increase in the concentration of the yolk in passing from one side to the other.

As the yolk increases the distinction between protoplasmic and deutoplasmic portions becomes more and more marked, until the limit is reached in the megalecithal type. Here the amount of yolk is so enormous that the cytoplasm is reduced to a small cap or disc—the blastodisc—at one side, the bulk of the ovum being occupied by the yolk (Fig. 17). Yet even here small yolk-granules are found in the blastodisc, and the transition from blastodisc to yolk is not absolutely abrupt.

In the Placental Mammals the telolecithal arrangement of the yolk can still be seen, in spite of the small amount, at least when

the nucleus, with some cytoplasm, goes to the surface just before maturation (Fig. 18).

In the ovum of the Marsupial *Dasyurus* (Fig. 18, A) the yolk-globules run together at this time to form a single rounded mass—the yolk-body—placed on the opposite side to the nucleus.

In the ova of Birds (Fig. 17) the white yolk is disposed in the form of a central plug—the latebra—under the blastodisc. This is surrounded by successive layers of yellow and white yolk, alternately. The same feature is observable in the ova of Reptiles, Gymnophiona, Amphibia, and Elasmobranch fishes, where sheets of coarse and fine granules alternate.

The telolecithal disposition of the yolk confers upon the Vertebrate ovum a very definite structure and symmetry. In most cases the ovum is a sphere, and it is evident that a line may be drawn passing through the centre of the protoplasmic portion, at the surface, the centre of the egg, and the centre of the deutoplasmic portion at the opposite surface. This line is the egg-axis, and it is clear that its two ends, or poles, are unlike. The former, the protoplasmic, is known as the animal pole, the latter as the vegetative pole. These terms took their origin in the observation that in such an egg as that of the hen the chick or animal is developed from the blastodisc, at the side opposite to the inert or vegetative yolk.

From what has already been said it further follows that the yolk and protoplasm are distributed about this axis in such a way that the egg would be divided into precisely similar halves by any section which included the axis, but by none other. Hence the egg is said to possess a polarity and a radial symmetry about the axis. In any one plane at right angles to the egg-axis all radii are alike. The plane at right angles to the axis and including the centre of the egg is equatorial.

In cases where the egg is ovoid or ellipsoid (Myxinoids, *Amia*) the egg-axis is the major axis.

Yolk is heavier than protoplasm. Hence the Amphibian egg which, after fertilization, is free to rotate inside its jelly membranes, always turns over till its axis is vertical with the white, vegetative pole below. The full-grown ovarian egg—whether alive or dead—behaves in the same way when floated in a fluid

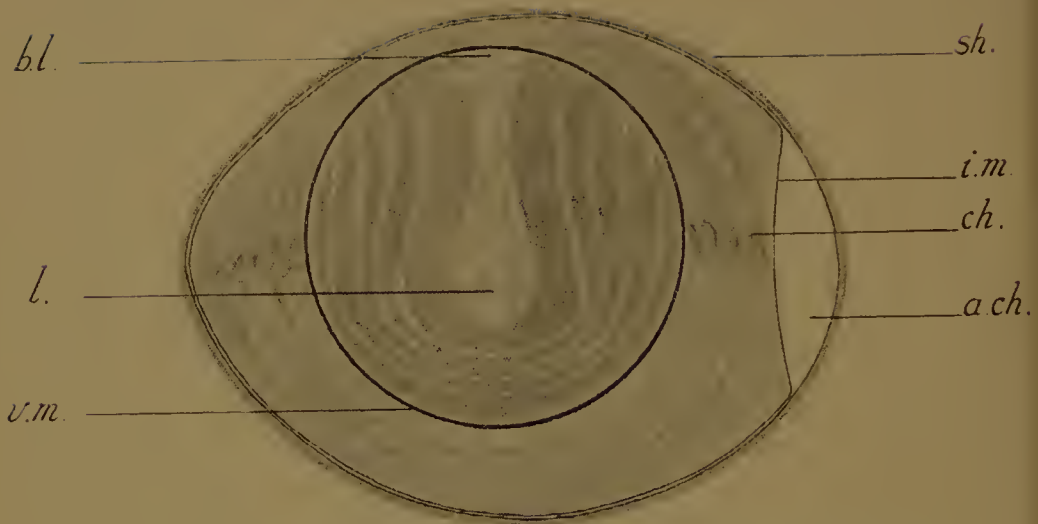


FIG. 17.—Hen's egg longitudinally bisected. (After Balfour, modified.) The section includes the axis of the ovum, the animal pole being to the upper side of the figure. *sh.*, shell, underneath it the external shell-membrane; *i.m.*, internal shell-membrane; *a.ch.*, air chamber; *ch.*, chalaza; *bl.*, blastodisc; *l.*, latebra of white yolk; *v.m.*, vitelline membrane.

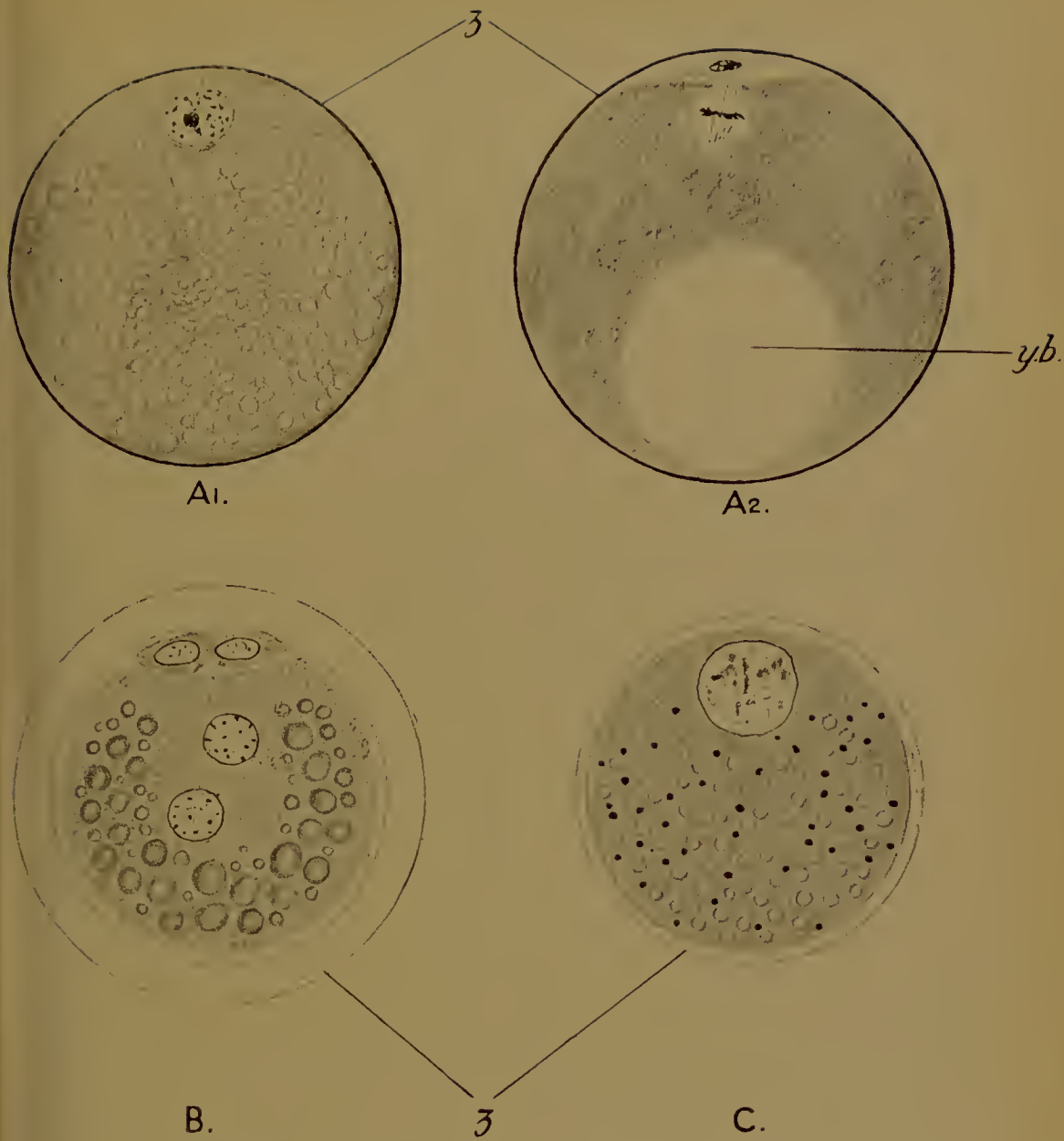


FIG. 18.—Mammalian ova.

A, *Dasyurus* (a Marsupial). 1, The ovarian egg (oocyte); the nucleus is near the surface at the animal pole; the cytoplasm contains spherules of yolk. 2, The second maturation division. The first polar body has been extruded, and the second polar spindle is seen. The yolk-spherules have run together to form the yolk-body (*y.b.*) placed at the vegetative pole. (After Hill.)

B, A bat (*Vespertilio*). Both polar bodies have been extruded and fertilization is taking place. The two pronuclei are seen. In the cytoplasm are numerous globules of yolk (protein). (After Van Beneden.)

C, The guinea-pig (*Cavia*). Full-grown oocyte. In the cytoplasm are mitochondria (chromatic bodies) and fat globules (the former are black, the latter clear in the figure). (After Lams and Doorne.) z., zona pellucida.

of the same specific gravity as itself. Similarly the ovum (yolk) of the hen's egg always turns over inside the shell till the blastodisc is uppermost. So in Elasmobranchs.

Pigment. The polarity and radial symmetry thus conferred upon the egg by distribution of the yolk may be further emphasized by the disposition of the pigment where that is present apart from the colouring matter of the yolk itself. In many Amphibia (Anura and Urodela), in *Ceratodus* and *Acipenser*, pigment is present in the egg. The dark brown, almost black pigment of the frog's egg will be familiar. Chemically it is a melanin. In other cases (*Siredon*, for example, and the edible frog) it is of a much lighter colour.

The pigment lies (Fig. 16), in the form of minute droplets, in a dense superficial layer in the animal hemisphere of the egg, extending a greater or less distance into the vegetative hemisphere. There is left round the vegetative pole as a centre a circular unpigmented area. The symmetry of the egg, as determined by the position of the yolk, coincides with that due to the distribution of the pigment. There is also a less dense mass internally in the animal hemisphere.

The Nucleus. The nucleus—germinal vesicle—of the full-grown oocyte is characterized by the presence of one (Placental Mammals) or more nucleoli, usually chromatic. The history of these nucleoli and of other parts of the nucleus will be dealt with later. What interests us at the moment is the position of the nucleus. This is always in the axis of the egg, but excentric (Fig. 16), and always nearer the animal than the vegetative pole. In a microlecithal egg the nucleus lies in the protoplasmic portion, in a megalecithal egg in the blastodisc (Fig. 17). It is placed, therefore, in what is termed, in Oskar Hertwig's first rule, the centre of its field of activity. The importance of this will be appreciated when we come to the study of the phenomena of segmentation.

Structure and symmetry of the ovum. It will be obvious from the foregoing that the egg is no homogeneous body, but heterogeneous with a definite polar structure—radially symmetrical about an axis determined conjointly by the disposition of the yolk, the distribution of the pigment, when that is present, and

the position of the nucleus. The first two characters are purely cytoplasmic. The significance of this initial structure of the

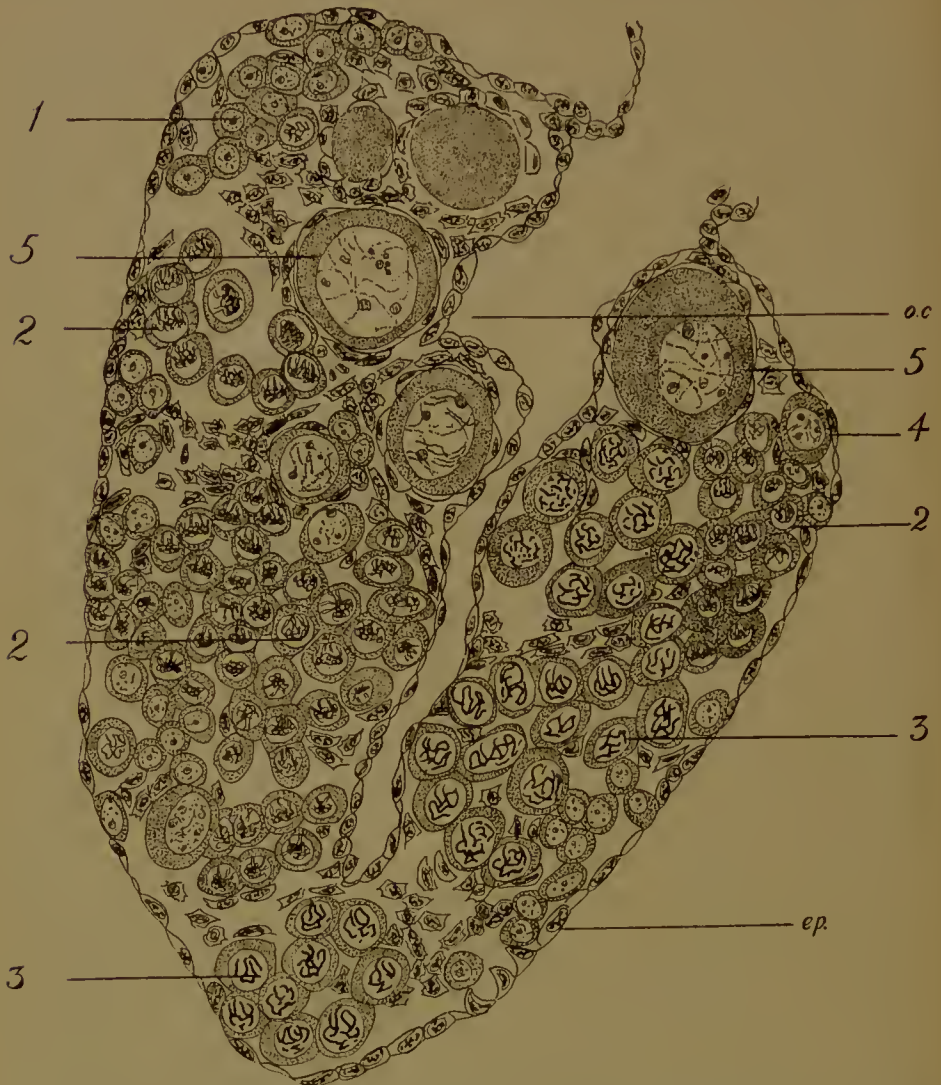


FIG. 19.—Ovary of the tadpole, showing development of the ovarian cavity (*o.c.*) and numerous germ-cells in different stages of growth, and with the nuclei in different conditions. 1, Earliest stage; 2, Synaptene; 3 Pachytene; 4, Diplotene; 5, Formation of nucleoli. The largest oocytes are surrounded by follicles. *ep.*, coelomic epithelium (germinal epithelium).

egg cytoplasm in development cannot be over-estimated, for it is related in a perfectly definite way to the structure of the embryo which will come from it. Thus, to take one example,

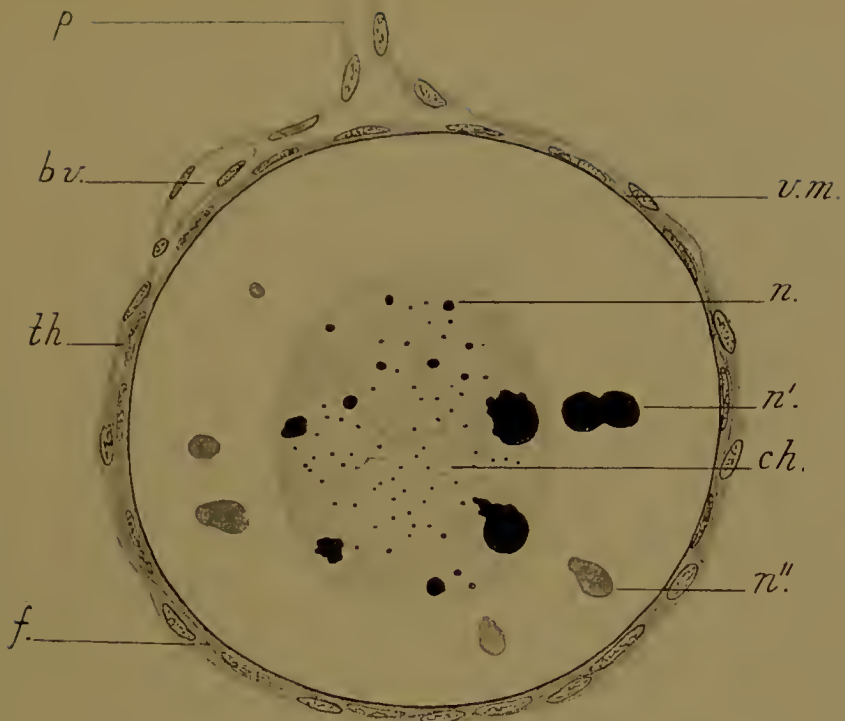


FIG. 20.—Small ovarian egg of the frog surrounded by its follicle (*f.*) and theca (*th.*), which is continued into the pedicle (*p.*). *b.v.*, a blood-vessel between follicle and theca; *v.m.*, vitelline membrane; *ch.*, chromatin filaments, now achromatic; *n.*, chromatic nucleoli, ejected from the nucleus (*n'.*) and becoming achromatic (*n''.*).

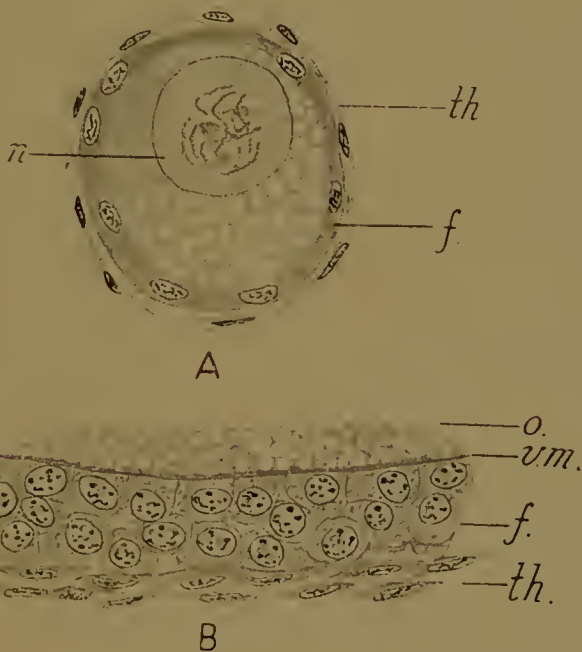


FIG. 21.—A, young, and B, older oocytes from the pigeon's ovary. *n.*, nucleus; *o.*, cytoplasm of the oocyte; *v.m.*, vitelline membrane; *f.*, follicle; *th.*, theca.

the anterior end of the embryo is developed always near the animal pole of the frog's egg, the egg-axis making a certain constant angle with the longitudinal axis of the embryo; or, in other words, the anterior and posterior regions of the embryo are predetermined in the structure of the egg.

That the relation is a necessary and causal one is shown by those experiments—performed on the eggs of various animals—in which, some one part of the cytoplasm being removed, some definite organ of the embryo or larva is lacking. The different portions of the egg cytoplasm are therefore so many organ-forming substances, and since the organs are part of the sum total of the inheritable characters of the species, the cytoplasmic substances, on which their development depends, are factors determinant of inheritance.

The egg-follicle. In the ovary the egg-cell is invested by one or more layers of follicle-cells, the function of which is not only to protect, but also to nourish, the growing oocyte. These are derived, as we have seen, from the germinal epithelium of the genital ridge. The follicle in its turn is surrounded by a theca of flattened connective tissue-cells.

In the Amphibia there is but one layer of cells in the follicle; they are flat. The ovary is hollow (Fig. 19), and the theca cells are continued into the stalk by which each ovum is suspended to the wall of the ovarian cavity (Fig. 20). Between theca and follicle there are blood-vessels.

In the Elasmobranchs and Birds (Fig. 21) there is but one cell-layer in the young follicle, but the number is subsequently increased to two or more. The cells are cubical or polyhedral in shape.

In the Monotremata the number of cell-layers is only one or two, but in all other Mammals (Fig. 22) it is greatly increased, and a cavity filled with an albuminous fluid—the liquor folliculi—is developed in between the cells, thus leading to the development of the characteristic hollow Graafian follicle. The cavity appears first on one side of the ovum as a narrow crescentic slit; soon this enlarges and extends round the ovum, which is then attached to the wall of the cavity only by a short stalk—the so-called discus proligerus. On its free side a few layers of follicle-cells

remain adherent to it, the cumulus proligerus. Finally, by the further extension of the cavity, the stalk is ruptured and the ovum, with its corona of cells, floats freely in the follicular cavity. The ripe follicle, which has now returned from the deep parts to the surface of the ovary, bursts, and the ovum, with its corona, is expelled and passes into the mouth of the oviduct (Fig. 43) to be fertilized.

The expulsion of the ovum is known as ovulation. In multi-parous Mammals several are, of course, expelled at the same time and from both ovaries.

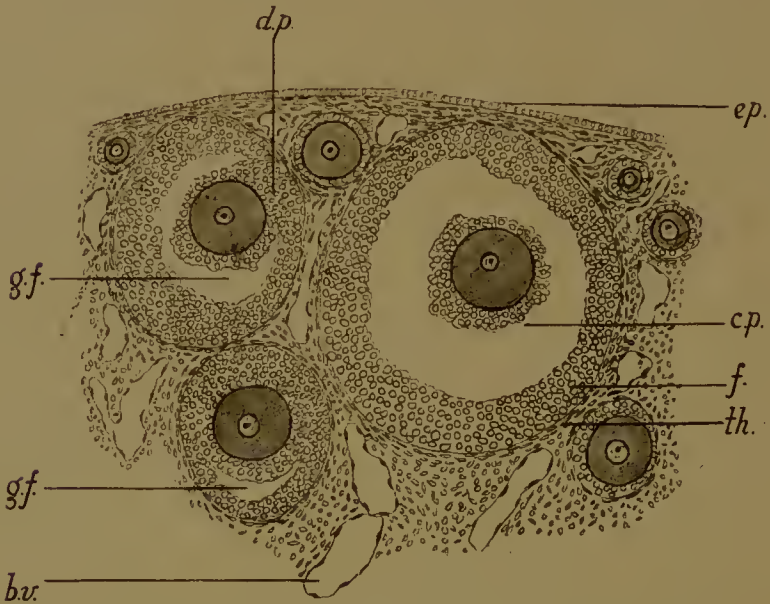


FIG. 22.—Part of the cortex of an adult mouse ovary. *g.f.*, cavity of the Graafian follicle; *f.*, follicle cells; *d.p.*, discus proligerus; *c.p.*, cumulus proligerus; *ep.*, surface (coelomic) epithelium; *th.*, theca; *b.v.*, blood-vessel.

After ovulation the follicle collapses, but it does not immediately degenerate. It becomes altered into a corpus luteum. The follicle-cells divide for some little time, and then, ceasing to do so, hypertrophy (Fig. 23). They secrete fat and lutein (to which the corpus luteum owes its yellow colour). Amongst these enlarged follicle-cells grow vascular strands from the innermost layer of the theca. The theca cells, which increase in numbers by division, are fusiform, and, lying obliquely, or

tangentially, or radially, in the follicle, divide up the luteal tissue into irregular blocks. The larger strands contain blood-vessels. There is a central cavity filled with stellate cells and extravasated blood corpuscles.

It has been shown that the corpus luteum secretes a substance which passes into the blood, and by that channel reaches the wall of the uterus, where it appears to be necessary for the proper attachment of the embryo by means of the placenta.

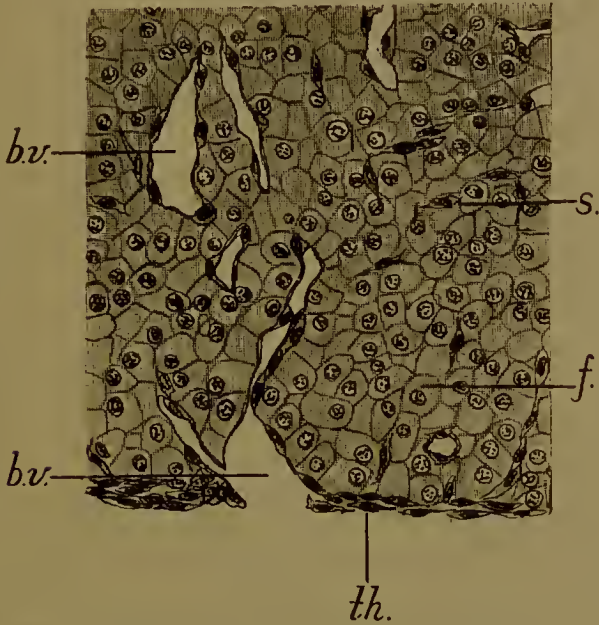


FIG. 23.—Marginal portion of a section through the corpus luteum of a mouse 14 days after parturition (i. e. after ovulation). *f.*, hypertrophied follicle-cells; *s.*, septa of connective-tissue cells; *th.*, theca; *b.v.*, blood-vessels.

The membranes of the ovum. These may be of three kinds, primary, secondary, and tertiary. A primary membrane is one secreted by the cytoplasm of the egg itself; a secondary, one secreted by the follicle-cells and often termed 'chorion'; while tertiary membranes (albumen, shell) are secreted by the epithelium of the oviduct as the egg passes to the exterior.

The ovum of Vertebrates is always immediately surrounded by a vitelline membrane, frequently termed a zona pellucida (Figs. 16, 17, 18, 20, 21). This membrane may be traversed by

fine radial pores, by means of which nutrient material passes from the follicle-cells to the ovum: it is then spoken of as a zona radiata.

It is a matter of great difficulty in most cases to determine whether the vitelline membrane is primary or secondary, but it is stated that there is a membrane secreted by the ovum itself, inside another secreted by the follicle-cells, in most forms (Elasmobranch fishes, Amphibia, Reptiles, Birds). The radial striations of the inner primary membrane disappear before the ovum is full grown. The vitelline membrane of the ripe egg is possibly the result of the fusion of both the primary and secondary membranes of an early stage.

The so-called 'chorion' of Teleostei and the Ganoid *Lepidosteus*, a very thick membrane, is apparently primary. In it the radial striations are persistent. The Myxinoids, however, possess a true chorion which is provided, at the animal pole, with a number of hooks, by which the egg is attached. In *Petromyzon*, Teleostei, and *Lepidosteus*, the vitelline membrane is perforated by a passage at the animal pole through which the spermatozoon enters. This is the micropyle.

In Mammals (Marsupialia and Placentalia) there is much uncertainty as to the origin of the vitelline membrane. It varies a good deal in thickness, and is not generally radiate unless thick. It is a zona radiata in the rabbit (Fig. 60), mole, pig, and sheep.

Chemically the vitelline membrane (of Birds) is an albuminoid allied to keratin.

The tertiary membranes are secreted by the oviduct. The innermost of these is the albumen, white of egg, or jelly. This is found in Elasmobranch fishes, Amphibia, Tortoises, and Crocodiles, but not Snakes and Lizards, Birds (Fig. 17), Monotremata, Marsupials (Fig. 58), and sometimes in Placental Mammals (rabbit).

The white of the hen's egg is wound round the ovum in layers, spirally arranged. The layers are separated from one another by a thin but tough membrane, the albumen in between successive membranes being fluid. Owing to the rotation of the egg as it passes down the oviduct these layers are spirally twisted up into cords (the chalazae) on two opposite sides. The chalazae




FIG. 23*.—Section through the shell of the egg of the ostrich (after Waldeyer, after Königsborn). *c.*, cuticle; *sp.*, spongy layer of stratified substance pierced by canals, which open internally between the bases of the conical processes of the mammillary layer (*m.*); *sh. m.*, shell-membrane.

are always placed in the equator of the ovum so that the blastodisc is midway between them, and they lie in the long axis of the egg-shell.

The white of the egg, which has an alkaline reaction, contains

85-88 %	water
10-13 %	protein
0.7 %	salts
0.5 %	dextrose

and traces of fats, soaps, lecithin, cholesterin, and lutein (to which the faint yellow colour is due).

The proteins are ovo-globulin (6.7 %), ovo-albumin (a mixture of at least two proteins), and ovo-mucoid.

The salts are sodium and potassium chloride, phosphates, and salts of calcium, magnesium, and iron.

In some birds (Insessores) the egg-white does not become opaque on boiling, but gives a transparent jelly, similar to alkali albuminate.

In Fishes and Amphibia the egg-white is a jelly, composed of mucin.

A shell is present, outside the egg-white, in Elasmobranch fishes, Birds (Fig. 17) and Reptiles, Monotremata, and some Marsupials (Fig. 58).

In the fishes referred to the shell is horny and attached by tendril-like strings to some foreign body. It is composed of keratin.

In Birds and most Reptiles the outer layer of the shell is calcified, the inner layer being then known as the shell-membrane. Calcification, however, does not occur in some cases (*Lacerta vivipara*). The shell-membrane is made up of a network of fibrillae of keratin.

The calcareous layer consists—in a Bird's egg—of three sheets (Fig. 23*): an outer delicate porous cuticle, a middle spongy sheet, and an inner mammillary sheet of columns whose conical ends impinge upon the shell-membrane.

The shell contains 3-7 % of organic matter (keratin), 90 % of calcium carbonate, and small quantities of magnesium carbonate and earthy phosphates.

The colour of the shell is due to bile-pigments. In the hen's egg the shell-membrane is separable into two sheets: between these two air collects at the blunt end of the shell after the beginning of incubation, so forming the air-chamber. This air is for the chick to breathe just before hatching (Figs. 17, 121).

The Monotremes possess a shell which in *Ornithorhynchus* is calcified.

Amongst Marsupials a horny shell is present in *Dasyurus* and *Phascolarctos*. In Placentalia the shell is invariably absent.

B. The Spermatozoon

In striking contrast to the large inert egg-cell, the spermatozoon is a small, actively-moving body, capable of swimming towards and entering the ovum in fertilization.

While there is great variety in the form of the animal spermatozoon, two principal types may be recognized, the flagellate or tailed, and the tailless.

The Vertebrate spermatozoon is flagellate. It consists typically of two parts, a head and a tail (Fig. 24).

In the head there is at the anterior end the acrosome or perforatorium, used in perforating the surface of the ovum, and behind this the nucleus. The nucleus is always dense and homogeneous, and highly chromatic.

The tail consists of an axial filament and a cytoplasmic envelope. Centrosomes are always present in it. Three portions may be recognized: an anterior part including the centrosomes; this is the *pars conjunctionis*; a middle part, *pars principalis*, as far as the end of the cytoplasmic envelope of the tail; and a *pars terminalis*, in which the axial filament is naked.

The axial filament (probably the seat of the contractility of the tail) runs throughout the length of the tail. Anteriorly it terminates in the most anterior centrosome—referred to sometimes as the end-knob—placed immediately behind, or even embedded in, the nucleus. Behind this are one or more other centrosomes.

The cytoplasmic envelope of the tail extends from the front end of the first to the hind end of the second region. In the third region only the axial filament is present.

The small part interposed between the head and the tail, that is, between the hind end of the nucleus and the front end of the axial filament, and containing only the anterior centrosome, is sometimes spoken of as the neck, or middle piece. This usage cannot be justified in all cases, as the axial filament may pass right through the anterior centrosome to the nucleus (as in the Amphibian *Discoglossus*). The term should therefore be dropped, or applied to the anterior region of the tail, including all the centrosomes.

Though always of the flagellate type, the form of the Vertebrate spermatozoon is variable. Thus, to take a few illustrations (Figs. 25, 26), the acrosome may be large and flattened (spoon-shaped) as in the guinea-pig, or, as is more usual, narrow and pointed (some Amphibia, Reptiles, and Elasmobranch fishes), or much reduced (*Phalangista*), or apparently absent (Teleostean fishes, possibly Birds). Whether it is really absent or not can, however, only be stated when the origin of the spermatozoon from the spermatid has been studied in these forms. In Birds there is often a remarkable spirally-coiled membrane round the head.

The nucleus may be short and rounded (Teleostei), or short and flat (guinea-pig), or cuneiform (*Phalangista*), or oval (*Tropidonotus*), or pointed and elongated, sometimes exces-

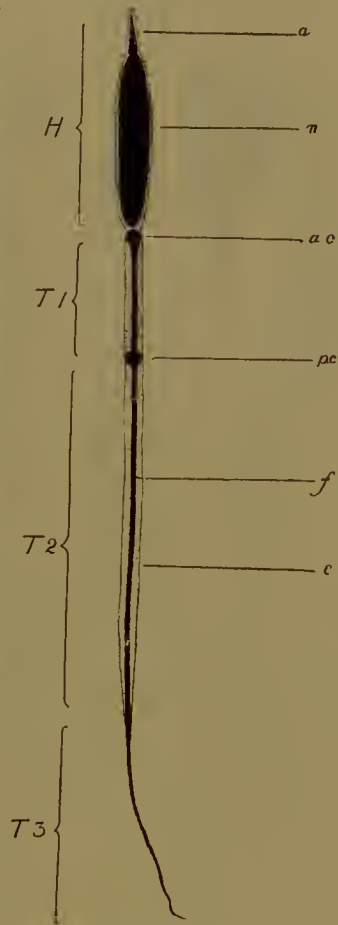


FIG. 24.—Diagram of a typical vertebrate spermatozoon. H., head; a., acrosome; n., nucleus; T, tail; T.1, pars conjunctionis; T.2, pars principalis; T.3, pars terminalis; a.c., anterior centrosome; p.c., posterior centrosome; f, axial filament; c., cytoplasm; e., envelope.

sively (Urodela). The anterior centrosome may be a small end-knob, single (Fig. 25, 2, 3, 4, Fig. 26) or multiple (Fig. 25, 1), or much enlarged, as in Urodeles especially. In *Bom-*

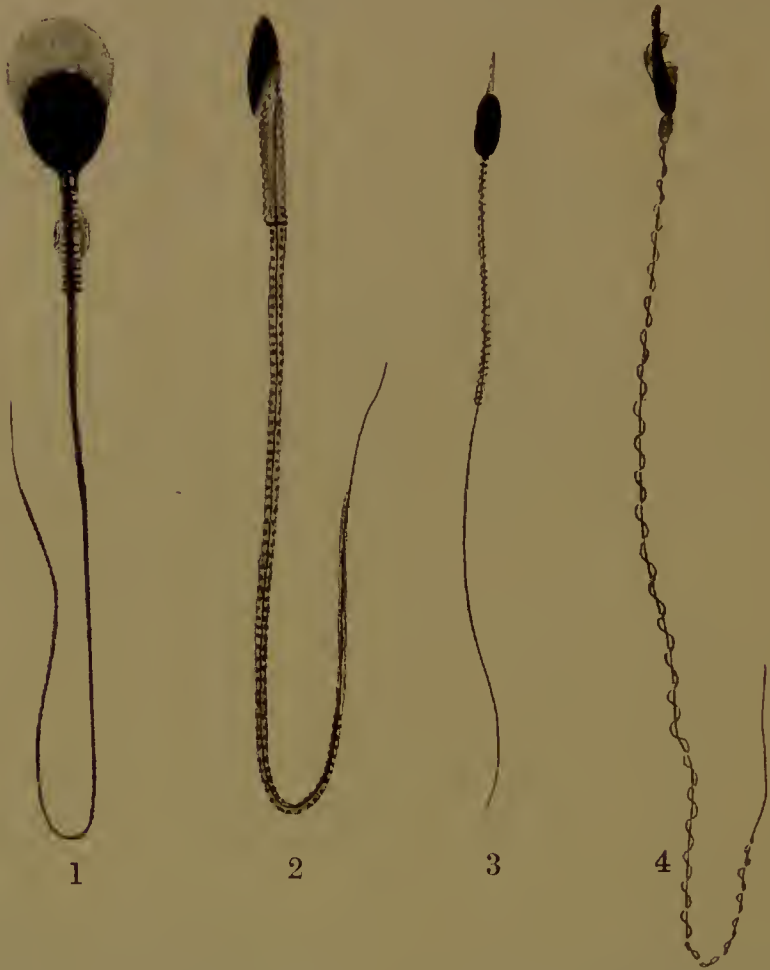


FIG. 25.—Various spermatozoa. 1. Guinea-pig (*Cavia*) (after Meves). 2. *Phalangista* (a Marsupial) (after von Korff). 3. *Tropidonotus* (a snake). 4. *Fringilla* (the chaffinch). (3 and 4 after Ballowitz.)

binator (a toad) its position near the anterior end of the nucleus is remarkable. The tail filament is inserted, therefore, near the front end of the head in this form. There may be (*Phalangista*) one or more intermediate centrosomes. The posterior one, at the end of the first portion of the tail, and therefore some way back, is frequently ring- or disc-

shaped. In Urodeles it lies very far back indeed. The cytoplasm of the anterior region often presents transverse or spiral

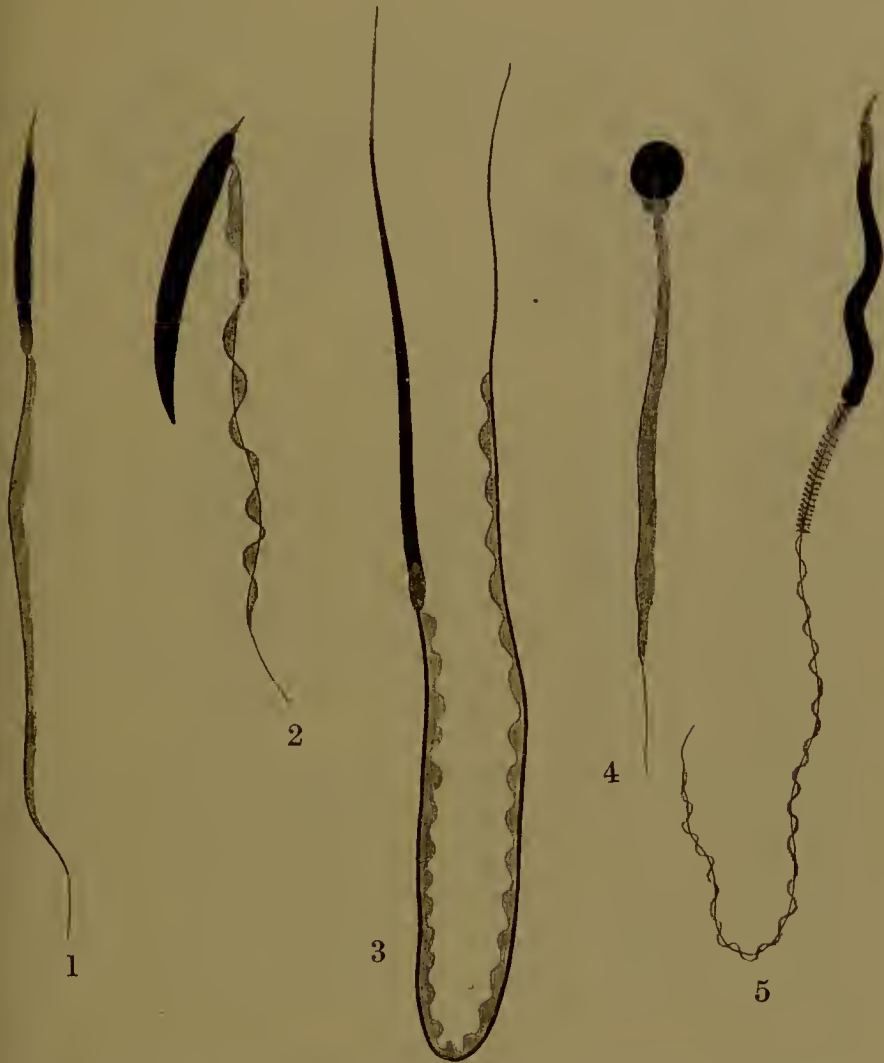

FIG. 26.—Various spermatozoa. 1. *Bufo* (the toad) (after King). 2. *Bombinator* (a toad) (after Broman). 3. *Siredon* (the Axolotl). 4. *Perca* (perch). 5. *Raia* (skate). (4 and 5 after Ballowitz.)

markings. In the anterior and middle regions (or in the middle region only) the cytoplasm is frequently in the form of a fin, which may have a thickened undulating border, or be spirally coiled round the axial filament.

Spermatozoa also vary very greatly in length, as the following

table will show. The lengths are given in thousandths of a millimetre.

<i>Crocodylus</i>	20-27
<i>Esox</i>	43
<i>Homo</i>	52-62
<i>Bos</i>	65
<i>Bufo</i>	62-91
<i>Erinaceus</i>	85
<i>Cavia</i>	93
<i>Mus</i>	107
<i>Raia</i>	215
<i>Siredon</i>	360-430
<i>Discoglossus</i>	2250

The gigantic spermatozoa of the Amphibian which comes last in the list are not, it is hardly necessary to say, proportionately broad. It may be added that even this length is exceeded by the spermatozoa of an Ostracod Crustacean, *Pontocypris monstrosa*, which are 5-7 millimetres long.

The Chemistry of the Spermatozoon. The most accurate determinations of the chemical composition of the spermatozoon are those carried out on fish sperms.

In the salmon the head (nucleus) of the sperm consists of fat and nuclein and other substances. The nuclein is itself a compound of nucleic acid ($C_{40}H_{56}N_{14}P_4O_{26}$) with a protamine known as salmin ($C_{30}H_{57}N_{17}O_6$), the proportions being roughly 60 % and 35 % respectively of the head, after removal of the fat. The remaining 5 % consists of inorganic matter ($Ca_3(PO_4)_2$, $CaSO_4$) 2.5 %, and an iron-containing organic material (the remainder).

In the herring the protamine known as clupein is apparently the same; scombrin (mackerel) and sturin (sturgeon) are other protamines obtained from the sperm-heads of fishes.

The tail, in the salmon, contains heat coagulable proteids to the extent of 42 %, and fatty substances, 58 %. The latter include lecithin (50 %), fat (30 %), and cholesterin (20 %).

The metamorphosis of the spermatid into the spermatozoon. As has already been stated, four small cells, the spermatids, are

produced from each primary spermatocyte by the two maturation divisions. Each spermatid is then directly metamorphosed into a spermatozoon.

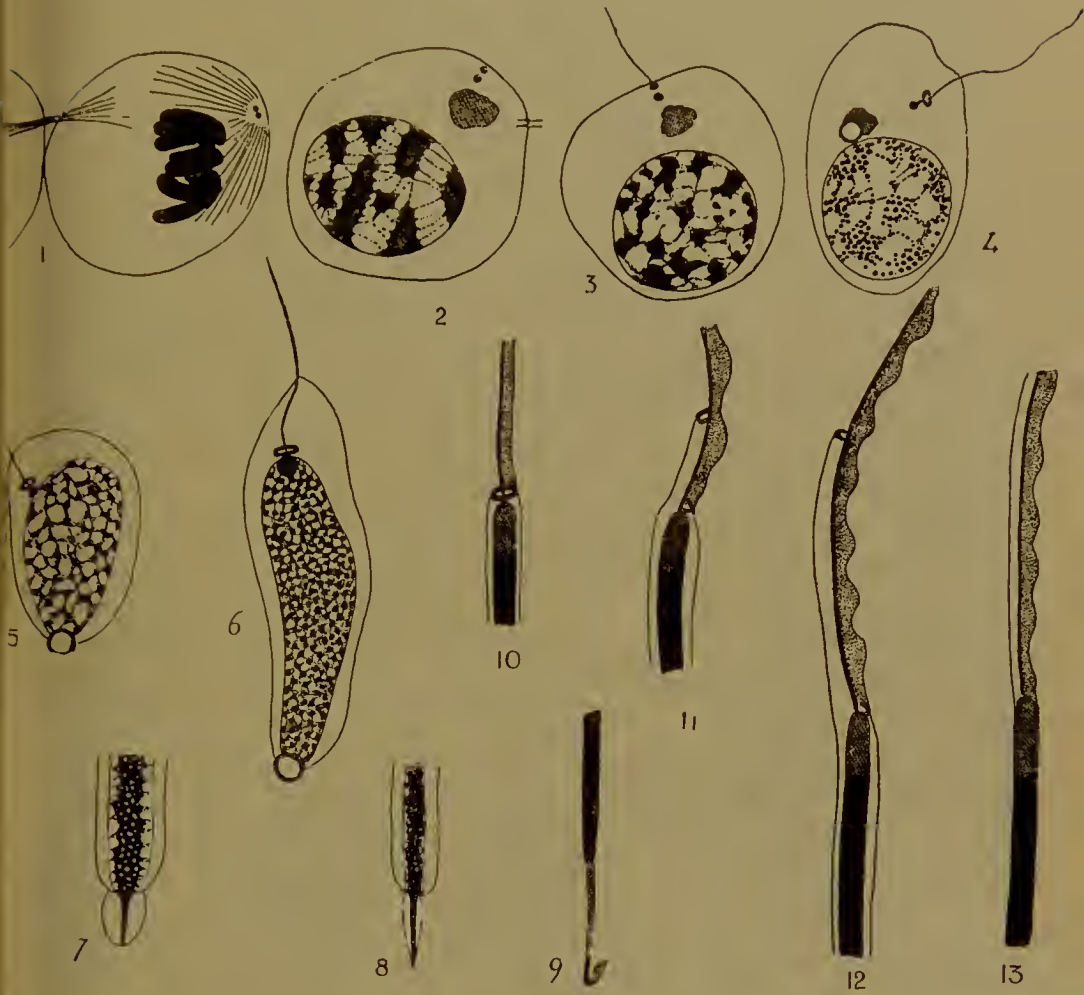

FIG. 27.—Metamorphosis of the spermatid into the spermatozoon in the salamander (after Meves). 1-6, the whole cell; 7-9, the anterior end; 10-13, the posterior end of the head. (For explanation see text.)

The investigation of this process in many forms, including several Vertebrates, has shown that there is a remarkable constancy in the changes that take place. One or two examples will suffice.

As a first, let us take the salamander (Fig. 27). The spermatid, emerging from the second maturation division, is a rounded cell,

in which the chromosomes are clumped together while the centrosome, lying in the middle of the centrosphere or sphere of attraction (Idiozom), has divided into two, placed tangentially with regard to the surface of the cell (Fig. 27, 1). While the nuclear membrane is being formed round the chromosomes, the centrosomes detach themselves from the sphere (Fig. 27, 2) and adopt a radial position. When the chromosomes break up into granules, a fine filament—the axial filament of the tail—grows out from the centrosome nearest the surface (Fig. 27, 3). This is the posterior centrosome, and it soon becomes first discoidal, then ring-shaped, the axial filament passing through the ring to attach itself to the other or anterior centrosome (Fig. 27, 4). Meanwhile the sphere—in which a spherical vacuole has been developed—moves away from the centrosomes to the opposite side of the nucleus, which is of course the anterior end (Fig. 27, 4-6). Here it becomes gradually changed into the acrosome or perforatorium. It becomes oval and an axial rod is formed in it. It is protruded from the cell, becomes pointed, and finally much elongated and barbed at its extremity, while the vacuole disappears (Fig. 27, 7-9). At the other, the posterior end of the cell, further changes are taking place. The anterior centrosome first attaches itself to the hinder end of the nucleus (Fig. 27, 5)—now elongated and finely granular—then enlarges and embeds itself in the nucleus (Fig. 27, 6), finally lengthening to form a long ellipsoid body. The axial filament has remained inserted into it (Fig. 27, 10). In the meantime, an outgrowth of cytoplasm has occurred on one side (dorsal) of the tail filament to form the fin (Fig. 27, 10). When the fin is well developed, the posterior ring-shaped centrosome breaks into two halves. One half travels down the other (ventral) side of the tail, carrying some cytoplasm with it, and eventually reaches a point near the end of the middle region (*pars principalis*). The other half remains behind and is fused with the anterior centrosome (Fig. 27, 11-13). The nucleus continues to elongate to form the sperm-head, finally becomes homogeneous, and is divested of its cytoplasmic covering.

The history of the sperm in other types, the guinea-pig for instance, is almost the same (Fig. 28).

In the spermatid can be seen the sphere—including some dark granules—the chromatoid accessory body, and the two centrosomes (Fig. 28, 1). These are dumb-bell-shaped, the outer or

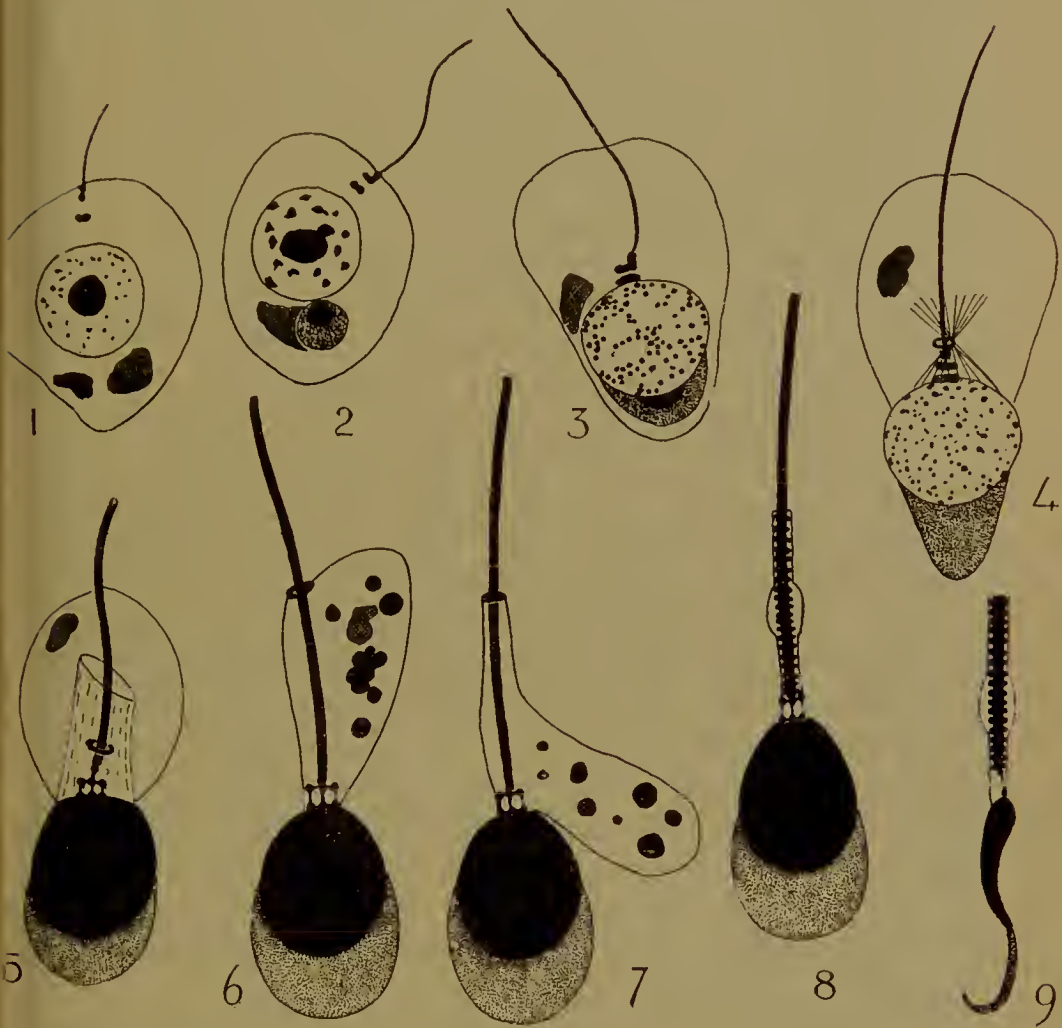


FIG. 28.—Metamorphosis of the spermatid into the spermatozoon in the guinea-pig (after Meves). 1-4 show the whole cell; 5-9 the head and the front part of the tail; 9 is seen in profile. In 1 the accessory chromatoid body is rendered in black. In this and the following figures the sphere is shaded or (aerosome) stippled. In 6 and 7 the granules of von Ebner are shown in black. (A full explanation will be found in the text.)

posterior is placed radially and bears the axial filament, the inner tangentially.

The chromatoid body disappears. The sphere moves round to what will be the anterior end; in it two portions are

distinguishable. A spherical body with a dense central spherule, this is derived from the dark granules of the previous stage, and an irregular body applied to the first, derived from the outer portion of the original sphere. This irregular body presently moves back to the hind end and disappears, but the spherical part becomes transformed into the acrosome (Fig. 28, 2-4). It is applied to the front end of the nucleus, and becomes lenticular (concavo-convex) (Fig. 28, 5). The central dense body then vanishes, the whole projects from the front end of the cell, being attached to the front and sides of the nucleus. Finally it becomes thin and curved (spoon-shaped) (Fig. 28, 9). The nucleus meanwhile having become homogeneous is also flattened and curved, its curvature being opposite to that of the acrosome.

The centrosomes have all this time been passing through complicated changes. The anterior one becomes flattened against the nucleus, the posterior hook-shaped, one limb of the hook—directed outwards—bears the tail filament, while the other, or anterior limb, is at right angles to it (Fig. 28, 2).

The hinder limb of the posterior centrosome now becomes divided into a ring behind and a knob in front (Fig. 28, 4). The tail filament passes through the ring, on to the knob, and then on to the middle of the anterior limb. The anterior centrosome and the anterior limb of the posterior centrosome then become divided, each into three knobs (Fig. 28, 5). The arrangement is therefore as follows. A row of three knobs united by filaments next the nucleus; each of these knobs being similarly united to one of the three knobs of the next row, also united together. The middle knob of the second row is united to another knob, and into this is inserted the axial filament of the tail which passes through the ring. Later the ring passes backwards some little way; it marks the end of the first region of the tail (Fig. 28, 6-8). The tail filament thickens, the posterior knob being fused with it.

A curious, quite transitory, structure is the 'tail-sleeve' (Fig. 28, 4, 5). This is a felt-work of fibrillae developed round the front end of the filament to form a sort of tube. Its existence is short. Most of the cytoplasm—which has by this time passed away from the nucleus to the middle-piece—is peeled off (Fig. 28,



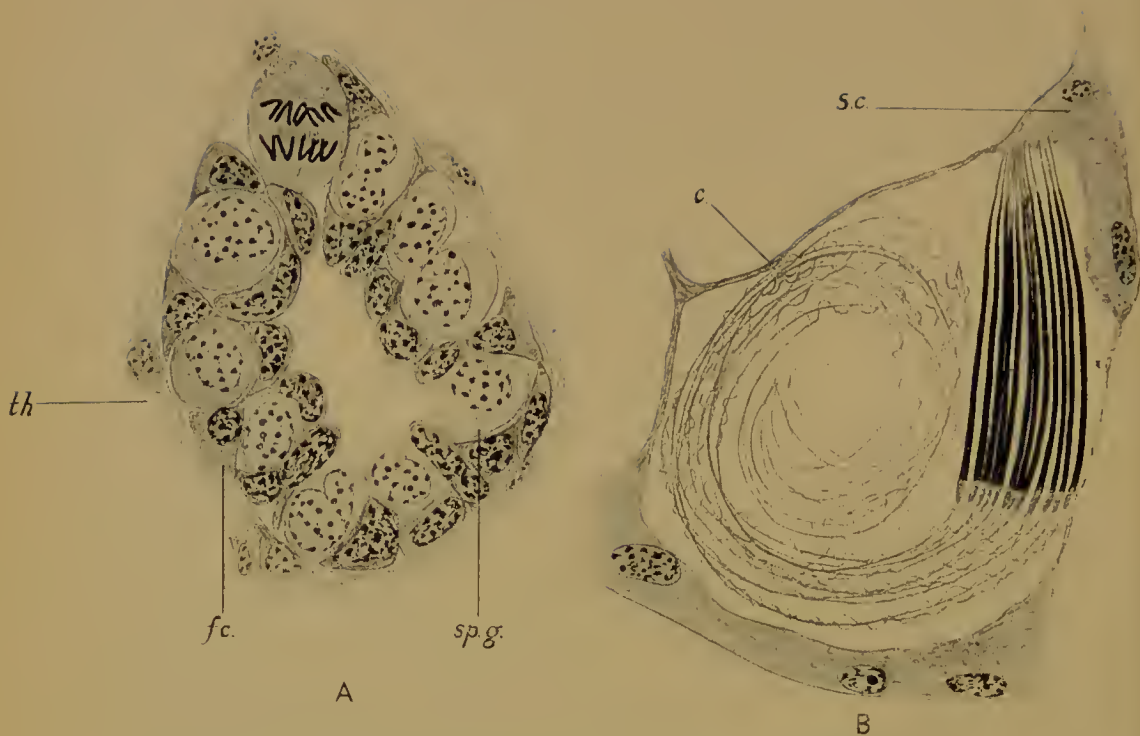


FIG. 29.—Sperm-cells of Amphibia in their cysts or follicles.

A, Section of a single seminiferous tubule from the immature part of the testis of a newt (in winter). The spermatogonia (*sp.g.*) are enclosed in follicles (*f.c.*); the theca surrounding the tubule.

B, Bundle of ripe spermatozoa inside a cyst (*c.*), from the testis of the Axolotl. *S.c.*, Sertoli-cell in which the acrosomes of the spermatozoa are embedded.

6, 7), with the remains of the sphere and a number of stainable bodies—the granules of von Ebner—which always appear at this time. The remains of the cytoplasm form a sheath round the middle-piece (pars conjunctionis), and apparently a thin investment for the principal part of the tail. In the middle-piece the characteristic transverse (? annular) striations appear (Fig. 28, 8, 9).

These examples are typical of spermatogenesis in general. The acrosome is formed from the sphere, the tail filament grows out from the centrosome; and even where (as in many Crustacea) the tail is absent, the two centrosomes are still present, and the posterior one becomes transformed into a ring.

The close relation between the locomotory organ of the cell and the centrosome is not peculiar to spermatozoa. In certain Protozoa there is a central corpuscle which not only acts as an organ of cell-division, but also serves as a base of insertion for the flagella or for the axial filaments of the pseudopodia (*Dimorpha*, *Acanthocystis*).

The centrosome of the spermatozoon and the sphere—which becomes the acrosome—are both parts of the original division apparatus. They have, however, distinct functions to perform in fertilization, for while the latter is the perforatorium, employed for ensuring the penetration of the sperm below the surface of the egg, the former is the centre round which the primary sperm-sphere is formed. We shall see, nevertheless, that these distinct processes probably depend upon a property which is common to both bodies, and may be due to their community of origin.

The follicle-cells of the testis. Like the ova, the male cells are associated with certain nutrient cells in the testis, known also as follicle-cells, though they do not always form a covering for the germ-cells. Their origin from the germinal epithelium has already been referred to.

In the lower Vertebrates the germ-cells commonly occur in bundles, each of which is enclosed in a wrapping of follicle-cells, a cyst, or follicle. The cysts are arranged round the walls of the seminiferous tubules. In the immature tubules of the testis the cysts will be found to be small, each containing only one or two spermogonia (Fig. 29 A). But the number of the latter is

soon increased by division, and quantities of germ-cells are subsequently found in each single cyst. In each cyst all the germ-cells are usually in the same stage—whether spermatogonia, spermatocytes, spermatids, or spermatozoa, complete or incomplete—but in the different cysts in the same tubule different stages are found, though they are not usually very widely different in adjacent cysts (Fig. 30).

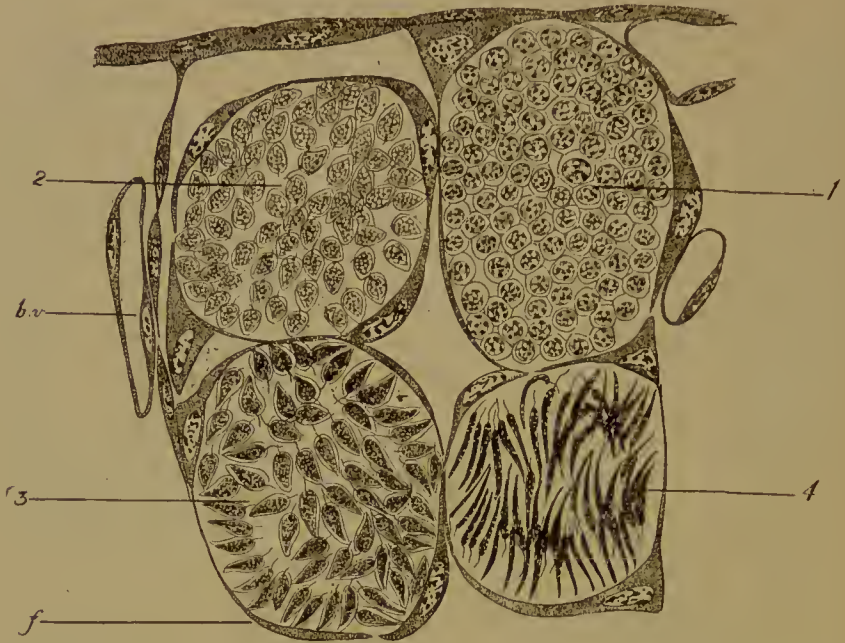

FIG. 30.—Four cysts or follicles from the same seminiferous tubule of the testis of the Axolotl. 1, contains spermatids; 2, 3 and 4, three successive stages of the metamorphosis of the spermatid into the spermatozoon. *f.*, follicle; *b.v.*, blood-vessel outside the tubule.

The mature spermatozoa become arranged in bundles, and inserted, in each bundle, by their acrosomes into a single basal cell of the cyst (Fig. 29 B), facing the wall of the tubule. The cyst, which has been much distended, then gives way, and the tails of the sperms project freely into the lumen of the tubule.

The basal cells in which the heads of the spermatozoa are embedded are apparently nutrient as well as supporting. They are known as the cells of Sertoli, a term first applied to the corresponding cells of the Mammalian testis.

In the Mammalia the germ-cells are also grouped in bundles,

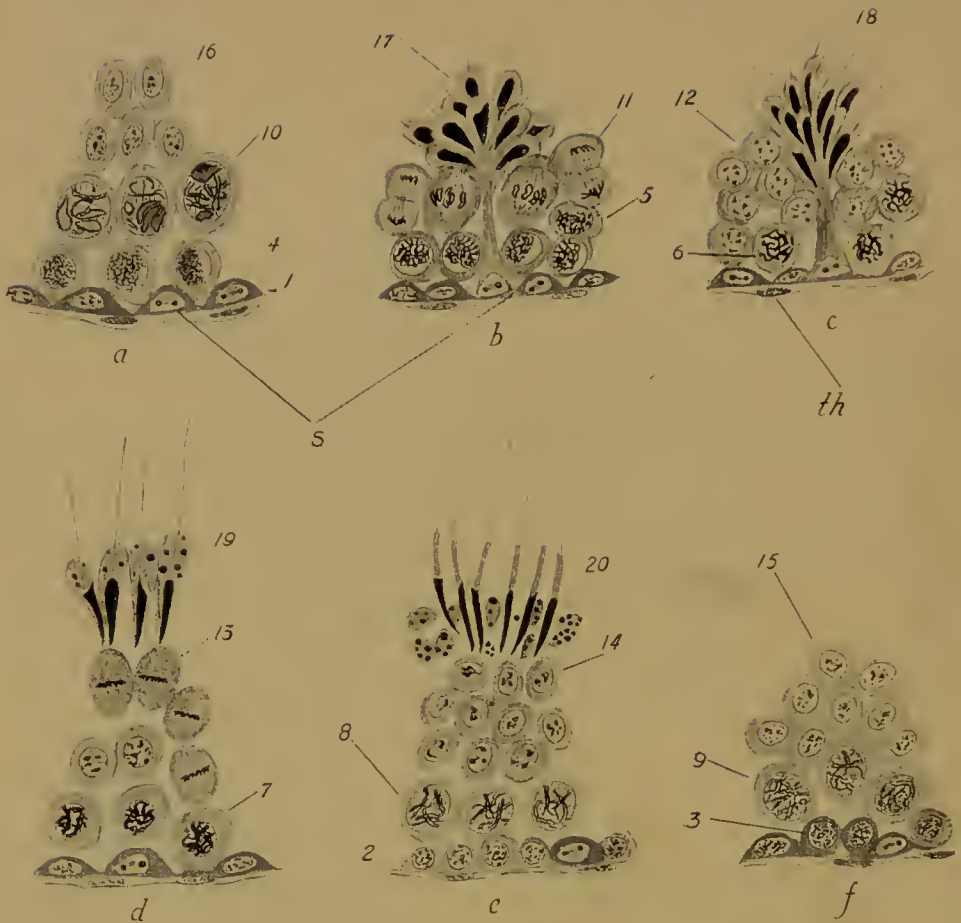

FIG. 31.—Testis of mouse. A small part of a section through a seminiferous tubule in six different conditions (*a-f*). 1-20, stages in spermatogenesis (for further explanation see text). *S.*, Sertoli-cell; *th.*, theca.

but are not enclosed in cysts ; further, they are disposed in several layers, and different stages in development are found in the several layers at one and the same point in a seminiferous tubule (Fig. 31).

The basal layer contains the supporting cells or cells of Sertoli, which (in the mouse) are recognizable by the presence in the nuclei of one large nucleolus and two large spherules of chromatin. In addition to these there are the spermatogonia (indifferent cells), which are derived either from the central cells of the young testis (see Fig. 13) or from the surrounding follicle-cells, or from both.

Internal to this basal layer are about three others, in each of which the germ-cells are in a different stage. For the sake of illustration the whole spermatogenesis may be divided into twenty stages, as follows :

1. Indifferent cell or spermatogonium.
2. Transition to spermatocyte.
3. Primary spermatocyte : leptotene stage.
4. Transition to synaptene stage.
5. Advanced synaptene.
6. Pachytene.
7. Pachytene to diplotene.
8. Later diplotene.
9. Commencement of ring-formation.
10. Ring-shaped (heterotypic) chromosomes formed.
11. First maturation division.
12. Secondary spermatocytes.
13. Second maturation division.
14. Spermatids.
15. Later spermatids.
16. „ „
17. Commencing metamorphosis, with short tail filament.
18. Later stage.
19. Appearance of von Ebner's granules.
20. Peeling off of cytoplasm ; spermatozoon complete.

Beginning with, for example, a stage in which the spermatogonia of the basal layer are in stage 1, the cells of the second layer in the fourth, those of the third layer in the tenth, and those of the fourth layer in the sixteenth stage, the progress of development

in each layer may be readily watched. As layer II passes into stage 5, layer III shows first maturation spindles, while the spermatids of the fourth layer begin to be metamorphosed into spermatozoa, and so on. By the time that the spermatozoa of the fourth (inmost) layer are ripe and ready to drop into the tubule, the cells of the third layer have reached the spermatid stage; those of the second are in a late prophase of the first maturation division, while the somewhat flattened spermogonia of the basal layer are becoming cubical and preparing to grow into spermocytes. By the time the ripe sperms have been thrown off, the young spermocytes have detached themselves from the basal layer and lie in a distinct second layer below the third and fourth layers, which are respectively in the ninth and fifteenth stages, and so the starting-point is reached once more.

The germ-cells, therefore, originating in the basal layer, are brought nearer and nearer the lumen of the tubule as the ripe sperms of the inner layer are cast off and fresh layers formed from below. As the spermatids undergo their metamorphosis, they become grouped into bundles; and, in each bundle, the spermatozoa are inserted by their acrosomes into the extremity of an elongated Sertoli cell, which is retracted once more when the spermatozoa have been set free. The tails, therefore, float out into the seminiferous tubule.

The ovum and the spermatozoon are obviously different from one another in almost every respect. The former is large, inert, and, when fully ripe, as we are shortly to see, without a centrosome. It is rich in cytoplasm, contains reserve food material, and has a structure, related in a very definite way to the structure of the embryo which is to be developed from it.

The spermatozoon, on the other hand, is motile and small, has little cytoplasm (except in the tail, which is of no importance in fertilization, since it may be left outside the egg) but is provided with one or more centrosomes, as well as with an apparatus for entering the ovum.

We have still to examine the structure of the nuclei of the germ-cells, a structure which is the result of the peculiar nuclear changes involved in maturation. This examination will show us that in their nuclei the germ-cells are alike.

LITERATURE

- B. M. ALLEN. The origin of the sex-cells of *Chrysemys*. *Anat. Anz.* xxix, 1906.
- E. BALLOWITZ. Untersuchungen über die Struktur der Spermatozoen. I. *Arch. mikr. Anat.* xxxii, 1888. III. *Arch. mikr. Anat.* xxxvi, 1890.
- E. BALLOWITZ. Die merkwürdigen, $2\frac{1}{4}$ Millimeter langen Spermien des Batrachiers *Discoglossus pictus*. *Arch. mikr. Anat.* lxiii, 1904.
- J. BEARD. The germ-cells. *Journ. Anat. and Phys.* xxxviii, 1904.
- E. VAN BENEDEN et C. JULIN. Observations sur la maturation de l'œuf chez les Chiroptères. *Arch. de Biol.* i, 1880.
- U. BÖHM. Beiträge zur Entwicklungsgeschichte der Leibeshöhle und der Genitalanlage bei den Salmoniden. *Morph. Jahrb.* xxxii, 1904.
- I. BROMAN. Ueber Bau und Entwicklung der Spermien von *Bombinator igneus*. *Anat. Anz.* xvii, 1900.
- R. BURLIAN. Chemie der Spermatozoen. *Ergebn. Physiol.* v, 1906.
- C. A. EIGENMANN. On the precocious segregation of the sex-cells in *Micrometrus aggregatus*. *Journ. Morph.* v, 1891.
- O. HAMMARSTEN. Text-book of Physiological Chemistry, trans. by J. A. Mandel. New York, 1911.
- H. D. KING. The egg of *Bufo lentiginosus*. *Journ. Morph.* xvii.
- K. VON KORFF. Zur Histogenese der Spermien von *Phalangista vulpina*. *Arch. mikr. Anat.* lx, 1902.
- E. KORSCHULT u. K. HEIDER. Vergleichende Entwicklungsgeschichte der wirbellosen Thiere. *Allg. Th.*, Lief. I. ii, Jena, 1902.
- H. LAMS et J. DOORME. Nouvelles recherches sur la maturation et la fécondation de l'œuf des Mammifères. *Arch. de Biol.* xxiii, 1908.
- F. McCLENDON. On the nucleo-albumin in the yolk-platelets of the frog's egg. *Amer. Journ. Phys.* xxv, 1909.
- F. MEVES. Ueber Struktur und Histogenese der Samenfäden von *Salamandra*. *Arch. mikr. Anat.* l, 1897.
- F. MEVES. Ueber Struktur und Histogenese der Samenfäden des Meer-schweinchens. *Arch. mikr. Anat.* liv, 1899.
- W. RUBASCHKIN. Ueber das erste Auftreten und Migration der Keimzellen bei Vögelmbrioncn. *Anat. Hefte*, 1^{te} Abt., xxxv, 1908.
- W. RUBASCHKIN. Ueber die Urgeschlechtzellen bei Säugetieren. *Anat. Hefte*, 1^{te} Abt., xxxix, 1909.
- J. SOBOTTA. Ueber die Entstehung des Corpus luteum der Säugethiere. *Anat. Hefte*, 2^{te} Abt., viii, 1899.
- O. VAN DER STRICHT. La structure de l'œuf des Mammifères. *Arch. de Biol.* xxi, 1905.
- W. WALDEYER. Die Geschlechtzellen, in O. Hertwig, *Handbuch der Entwicklungslehre der Wirbeltiere*. Jena, 1906.
- E. B. WILSON. The cell in development and inheritance. New York, 1902.
- H. VON WINIWARTER. Recherches sur l'ovogenèse et l'organogenèse de l'ovaire des Mammifères. *Arch. de Biol.* xvii, 1901.
- F. A. WOODS. Origin and migration of the germ-cells in *Acanthias*. *Amer. Journ. Anat.* i, 1902.

CHAPTER IV

THE GERM-CELLS (*continued*)

III. THE MATURATION OF THE GERM-CELLS

A. In the male.

THE Urodelous Amphibia have always been a favourite object for the study of these changes, and may conveniently be taken by us as a type.

It will be recalled that during the spermatogonial divisions the full somatic number of chromosomes is seen. The mitosis is of the ordinary character (Fig. 32). The granules of chromatin increase, run together in the form of beaded rows, which become the V-shaped chromosomes. The nuclear membrane has in the meantime broken down, the centrosome has divided, and around each daughter centrosome an aster is appearing. The chromosomes then undergo longitudinal fission and, so split, are placed on the equator of the spindle now developed between the two centrosomes. The daughter chromosomes are then pulled apart by the spindle-fibres attached to them to the opposite spindle poles, and there passing through the same series of changes in the reverse order become the daughter nuclei. Meanwhile a cell-division has occurred in the equatorial plane of the spindle, in which process the intermediate bodies—thickenings of the spindle fibres—play an important part.

All the features of an ordinary mitosis are here : the chromatin is the only part of the nucleus to be divided ; for that purpose it is thrown into the form of chromosomes, which split lengthways independently of any external agency ; a division apparatus—asters and spindle—is constituted between the centrosomes and probably by them, the function of which is to pull apart the halves of the already divided chromosomes and to ensure the division of the cell. When the spermatogonia have ceased dividing they enter upon a resting stage ; during this time the nucleus passes through complex changes, which are in

reality the prophases of the first of the two maturation divisions. This first division is of a very different character to an ordinary mitosis. There ensues the second division. This, with one important exception, resembles the mitoses of the spermatogonia.



FIG. 32.—Stages in the karyokinetic division of the spermatogonia of the newt.

The first maturation division (Figs. 33, 34). In the nucleus of a spermatogonium the chromatin is in the form of fairly coarse lumps uniformly distributed over a wide achromatic reticulum. As the growth of the cell and its nucleus begin the chromatin becomes subdivided into finer granules, which soon arrange themselves in rows or filaments; in each row the granules are

connected by threads of the achromatic reticulum, while similar threads pass from one filament to another. This is the narrow thread or *leptotene*¹ stage. As the nucleus enlarges still more

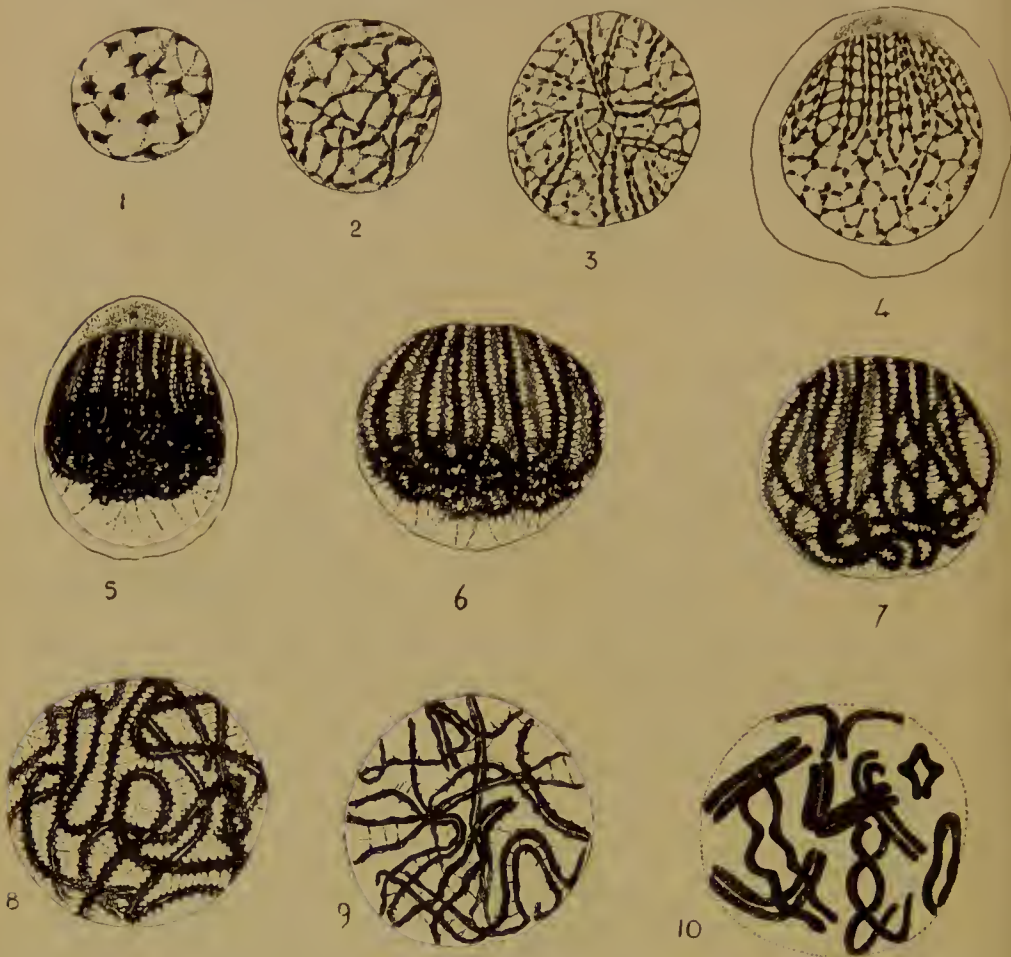


FIG. 33.—Prophases of the heterotype division in the male Axolotl. 1, Nucleus of spermatogonium or young spermocyte; 2, Early leptotene; 3, Transition to synaptene; 4, Synaptene with the double filaments converging towards the centrosome; 5, Contraction figure; 6, 7, Pachytene; 8, Early, 9, Later diplotene; 10, The heterotypic double chromosomes; the nuclear membrane is disappearing.

it is seen that on one side some of the filaments are arranged in pairs, and converge towards one point, the point where the centrosome in its centrosphere is placed. On the other side of

¹ These and the following terms were first proposed by von Winiwarter in his classical work on the oogenesis of the rabbit.

the nucleus the filaments pass into the general network. This is the paired thread or *synaptene* stage.

By coalescence of the component granules the filaments become shorter and thicker : at the same time in each pair the filaments approach one another so closely that only a narrow slit is left between them. On one side the pairs of filaments still converge towards the centrosome, but on the other are inextricably coiled




FIG. 34.—First maturation division in the male. 2, Salamander, the remainder Axolotl. 1, 2, The heterotypic chromosomes on the spindle (metaphase); 3, Anaphase; 4, 5, Telophase; 6, Resting nuclei; 4-6, Cell-division into two secondary spermyocytes.

and tangled together into a bunch which is withdrawn some little way from the nuclear membrane. The pairing of the filaments can, however, be seen in the tangle. The several pairs are still united by achromatic threads, the filaments being toothed at each point of insertion of such a thread. A few threads stretch across the empty space between the tangle and the membrane. This is the *contraction figure*.

The members of each pair of filaments now unite throughout their length, so that the longitudinal slit disappears. The thick filaments still converge towards the centrosome side, where

apparently they end against the nuclear membrane. There is, therefore, not one continuous filament or spireme, but several.

The other ends of the filaments pass into the tangle, which is still retracted from the nuclear membrane, but becoming looser as the nucleus enlarges. The coil is soon still more unravelled and occupies the whole of its side of the nucleus. This is the *pachytene* stage.

The several filaments now separate from one another, so that the polar convergence is lost, and coil in various directions through the nucleus. At the same time the longitudinal slit reappears in each, and the filaments are once more paired, so reaching the *diplotene* condition. Their surfaces are still toothed where the connecting achromatic threads are inserted. Soon, however, these cross threads disappear and the filaments become smooth. At the same time the members of the several pairs begin to separate a little from one another, in places if not throughout their length.

The nuclear membrane now breaks down and disappears, the pairs of filaments shorten and thicken, and assume the most various shapes and sizes. A pair may be in the form of two straight parallel rods, or two curved parallel rods, either V-shaped, or C-shaped, or two rods parallel at one, divergent at the other extremity, and so Υ -shaped; or the slit between them may be expanded in two or more places, and then the two may be twisted over one another into a figure of ∞ or ∞ , or by expansion of the whole slit, while the rods are united at the ends, may be ring-shaped, while finally the ring may be pushed in in four places and assume the form of a cross, \oplus . These bizarre double bodies are the chromosomes of the first maturation division. It seems clear that they are derived from the separate paired filaments of the diplotene stage, these from the thick filaments of the pachytene stage, and these again from the paired filaments of the synaptene nucleus. The origin of these we shall have to discuss later on.

The number of the double chromosomes, and therefore of the several double filaments in the earlier diplotene, pachytene, and synaptene stages, is one-half that seen in the spermatogonia. The reduction from the somatic number ($2n$) to the germ-

number (n) has already taken place. It seems that this half number must be established in the synaptene nucleus.

The actual division now occurs (Fig. 34). A spindle is formed in the ordinary way, and the double chromosomes are thrown upon its equator in such a way that the two ends of each member of a pair lie in the equatorial plane. This is easily seen where the pair retains the original form of two closely-parallel rods separated by a longitudinal slit, and can often be made out in the ring- and cross-shaped and other chromosomes.

The members of the pairs now come apart and travel to opposite spindle poles, where they coalesce and pass into the condition of resting nuclei. The cell, meanwhile, has divided and the two secondary spermatocytes have been formed. The nucleus of each of these, it is clear, contains only one-half of the ordinary number of chromosomes.

The division which we have just witnessed is unlike an ordinary mitosis in at least two respects. First, the number of chromosomes is reduced from the somatic to the germ number, and second, the chromosomes are double and frequently of extraordinary shape. For these reasons the division is spoken of as heterotypic, or unlike the usual type. The term meiotic or reducing, also applied to it, refers to the numerical lessening of the chromosomes.

We have now to inquire whether this division is or is not like an ordinary mitosis in another respect, the manner in which the chromosomes are divided. Ordinarily, as we know, the chromosomes are longitudinally divided; but on this occasion it is held by many observers that the division, albeit in appearance longitudinal, is in reality transverse.

The interpretation of the nuclear changes is a matter of considerable difficulty, and very diverse opinions are entertained (1) as to the origin of the double filaments seen in the synaptene and later stages of the prophase, and (2) as to the mode of formation of the ring-shaped chromosomes seen in the actual mitosis; different combination of these diverse opinions has led to the formulation of three principal views.

I. It is held that (1) the double filaments of the synaptene stage arise by longitudinal fission of the filament, that the

longitudinal split disappears, but reappears (2) to form the cavity of the rings. Hence the actual division is longitudinal (Meves). This is illustrated in the accompanying diagram (Fig. 35, I).

For the sake of simplicity we will suppose that the full number of chromosomes is four, the reduced number two. We will further

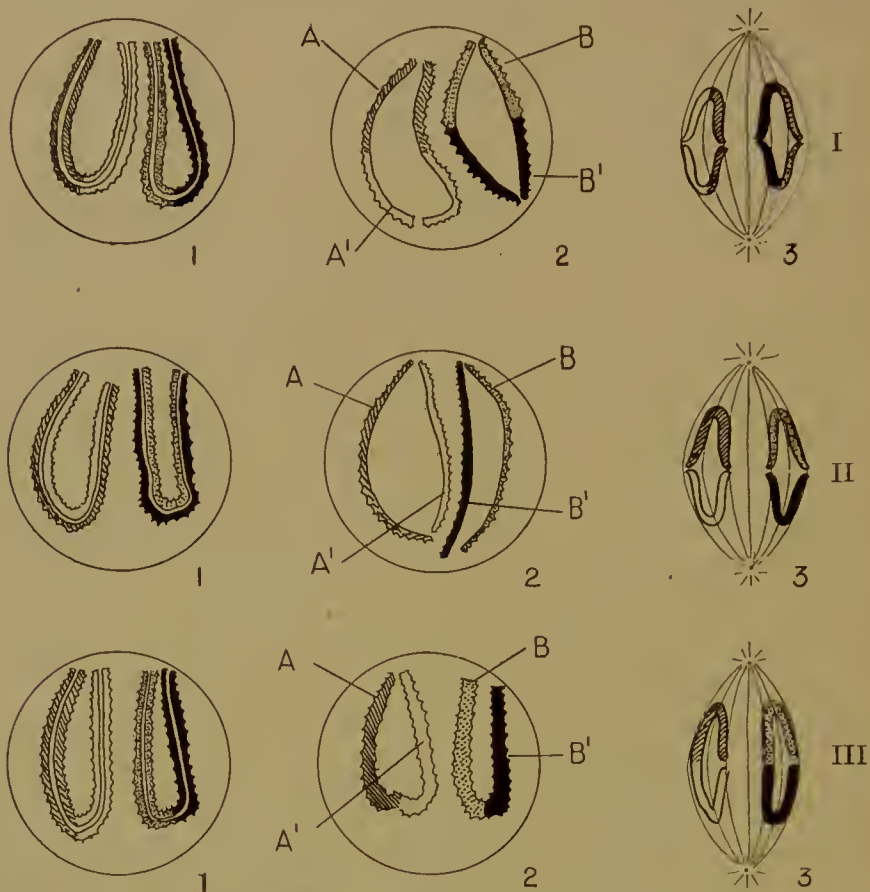


FIG. 35.—Diagram to illustrate three interpretations of the first maturation division (I, II, III); 1, 2, 3, successive stages; A, A', B, B', chromosomes. A is shaded, A' white, B stippled, and B' black. (For explanation see text.)

suppose that these four chromosomes are really different from one another though apparently identical. Let us call them A, A', B, and B'. In the prophase of the mitosis two instead of four filaments appear. We may suppose that each of these consists of two ordinary chromosomes united end to end, say A to A', and B to B'. Each filament becomes then split lengthways (I, 1), the slit widens out until each filament assumes

a ring shape (I, 2), and the rings are then so placed on the equator of the spindle that the ends of the chromosomes lie in the equator (I, 3). Hence, since each half ring consists of an *A* and an *A'*, or of a *B* and a *B'*, when the halves are separated and travel towards the spindle poles, each daughter nucleus of a secondary spermocyte will receive a chromosome of each kind, *A*, *A'*, *B*, and *B'*.

II. On the second view (von Winiwarter, Schreiner, Agar), (1) while the paired filaments of the synaptene stage are believed to arise, not by longitudinal fission of the leptotene, but by apposition of distinct chromatin filaments (that is, chromosomes), the formation (2) of the rings from these double filaments is in accordance with the first view.

The diagram (Fig. 35, II, 1) shows the four chromosomes united in pairs by their entire length, though presenting every appearance of longitudinally split rods: *A* is paired with *A'*, and *B* with *B'*. The chromosomes of each pair then separate to form rings, remaining united only by their ends, and then are placed on the spindle in such a way that these ends lie in the equator. It follows that *A* and *B* face towards one, *A'* and *B'* towards the opposite pole, and hence that each nucleus of a secondary spermocyte receives not all four chromosomes, but only two, say *A* and *B*, or *A'* and *B'*.

The division, therefore, is not really but only apparently longitudinal: the result is the same as though *A* and *A'* (and *B* and *B'*) had been united end to end, and then separated by a transverse division of the double chromosome so formed.

III. On the third view (Farmer, Montgomery), (1) the double thread of the synaptene and pachytene is formed by the longitudinal splitting of the chromatin filament; but (2) the rings do not arise by the opening out of the split. The longitudinal division disappears, and the filament is first gathered up into half as many loops as there are chromosomes in the spermatogonia, and these loops then separate as the *n* ring-shaped chromosomes. The rings are therefore open at one end only, and the cavity of the ring arises, not by the opening out of the longitudinal split (for that has disappeared), but by the bending of the two halves, united end to end, of each double chromosome

upon one another (Fig. 35, III). That is, the filament, consisting of A , A' , B , and B' , is first gathered up into two loops, A being bent on A' , and B on B' , and then the loops separate. In the mitosis (III, 3) the rings are so placed on the spindle that A becomes separated from A' and B from B' , so that one secondary spermatocyte receives A and B , the other A' and B' (or, of course, A and B' , A' and B).

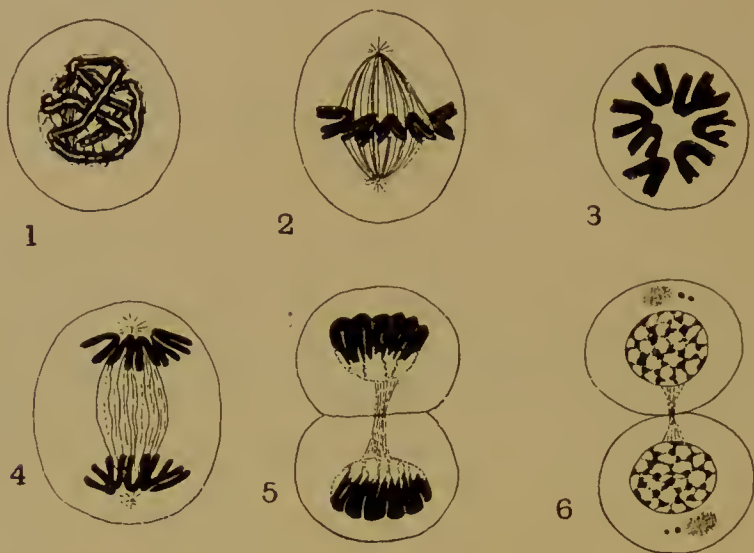


FIG. 36.—Second maturation division in the male (Axolotl). 1, Prophase (split spireme); 2, The homoeotypic split chromosomes on the spindle; 3, Polar view of the same; 4, Anaphase; 5, Telophase; 6, Resting nuclei and completion of cell-division; in each spermatid the centrosome has divided, and the sphere has become detached.

The result is therefore the same as on the second hypothesis.

Considering the diversity of opinion, it would be rash to dogmatize, but it may be pointed out that the evidence on the whole is against the mode of formation of the rings adopted by the third view. It does seem as though the rings were made by the opening out of the double filaments. We are left, therefore, with the choice between the first and second hypotheses. We can only say that the way in which the members of the pairs of filaments diverge into the general network in the fourth stage (Fig. 33, 4) suggests apposition rather than fission, and this involves ultimately a transverse division of double chromo-

somes, and that the phenomena of maturation observed in a number of Invertebrate forms corroborate this view.

Before discussing the theoretical significance of this mode of division, we shall describe *the second maturation division* (Fig. 36).

The nucleus of the secondary spermocyte soon emerges from the resting condition, and a chromatic filament appears. This filament becomes longitudinally split and then divided into a number of V-shaped chromosomes, themselves therefore split lengthways. The number of chromosomes is the half somatic, n . A spindle is developed, the split chromosomes are placed on its equator, and division takes its ordinary course, resulting in two spermatids, the nucleus of each of which therefore possesses n chromosomes. In the V-shape of the chromosomes, as well as in their longitudinal division, this second mitosis is of the ordinary type. Hence it is called homoeotypic. Each spermatid becomes metamorphosed into a spermatozoon in the fashion already described.

The phenomena of maturation in the male are, as far as is known, similar in other forms (*Myxine*, Elasmobranchs, Mammalia). Each ripe male cell, therefore, is provided with only half the number of chromosomes seen in the spermogonia and in the tissue cells of the body. Whether the n chromosomes in all the spermatozoa are or are not alike depends upon the interpretation placed on the first maturation division, as well as upon our views of the nature of the chromosomes.

B. In the female

While in the male the first or heterotypic division follows immediately upon the prophases, in the female the two episodes—prophase and division—are separated by an interval, sometimes of great length, a year or more—during which the yolk is deposited in the cytoplasm to the accompaniment of complex nuclear changes.

Prophases of the heterotypic division. The oogonial divisions come to an end at a fairly early period, and growth of the oocyte begins almost at once. The prophases of the heterotype are therefore usually found only in very young animals—in the tadpole of the frog, or the new-born or embryonic Mammal.

These two afford good examples. The nuclear changes which are readily seen in the tadpole's ovary (Fig. 37) are obviously closely parallel to what we have observed in the other sex.

A stage in which the chromatin is in the form of scattered granules is followed by one in which the granules run together to form the leptotene filament. Then comes the synaptene, with parallel filaments, followed by the contraction figure. The paired filaments emerge from the tangle to converge to one pole, the tangle itself being withdrawn from the other side of the nucleus. The pachytene and diplotene follow in due course. A remarkable change now occurs in the straining capacity of the chromatin filaments. Up to the diplotene stage they behave in the usual way, showing great affinity for chromatin stains (carmine, haematoxylin, and basic aniline dyes); but from now onwards they lose this faculty and stain only with the acid plasma dyes. Meanwhile, the number of nucleoli (these also stain in acid dyes) is increasing, and presently it is seen that granules of chromatin (that is, granules which are coloured by the ordinary chromatin dyes) begin to settle upon (? be precipitated round) the nucleoli. By what appears to be a continuation of this process the nucleoli become converted into highly chromatic bodies.

The filaments (chromosomes) persist for a while, but will eventually disappear.

Precisely similar phenomena are seen in the young Mammalian ovary (Fig. 38), and only one or two points require to be mentioned. There is a very obvious centrosphere with included centrosome on one side of the nucleus (this usually goes by the name of the *yolk-body of Balbiani*), towards which the filaments of the synaptene and pachytene converge. In the early stage of contraction the paired filaments are seen to emerge from the rather open tangle on this side, while on the other a few filaments, also paired, stretch out to the nuclear membrane. In the later contraction figure the latter are retracted and the tangle, much closer, lies wholly on the side of the centrosphere.

After the diplotene stage the ring-shaped figures of eight and other forms of double chromosomes are seen, but then the chromosomes break up into their constituent granules and range themselves along the achromatic threads which make a network




FIG. 37.—Prophases of the heterotypic division in the female (ovary of tadpole). 1, Nucleus of oogonium; 2, Leptotene; 3, Synaptene; 4, 5, Contraction figures; 6, Pachytene; 7, Later pachytene, multiplication of nucleoli; 8, 9, Diplotene: the chromatin filaments are becoming achromatic; granules of chromatin are being deposited on the nucleoli.

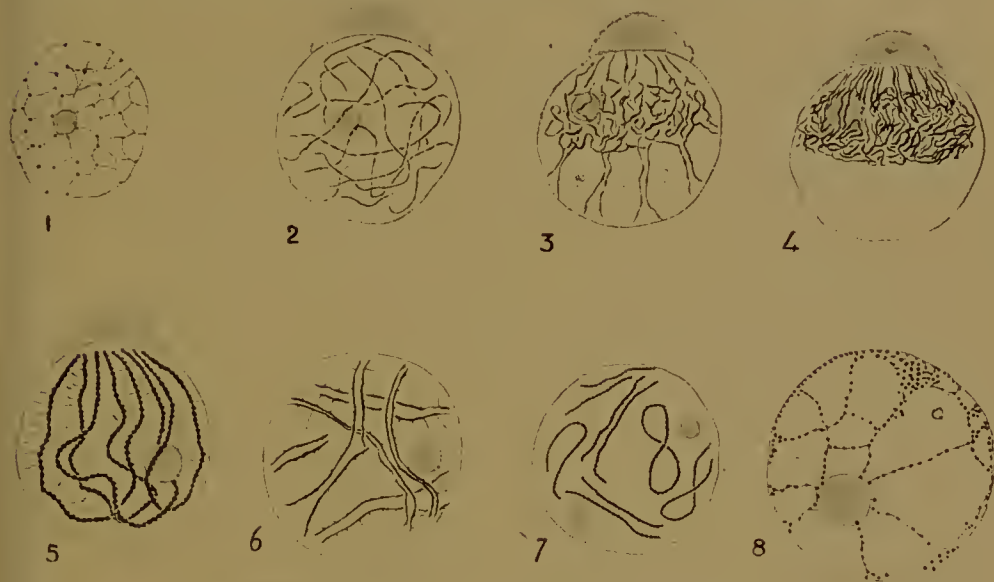

FIG. 38.—Prophases of the heterotypic division in the female (Mammals). 1-6, Kitten three days old; 7, Mouse embryo shortly before birth; 8, Mouse eight days old.

1, Nucleus of oogonium or young oocyte; 2, Leptotene; 3, Synaptene; 4, Contraction figure; 5, Pachytene; 6, Diplotene; 7, Heterotypic chromosomes; 8, Diplotene.

In 2-5 the centrosphere and centrosome (yolk-body of Balbiani) are shown with the chromatic filaments of the nucleus converging towards them.

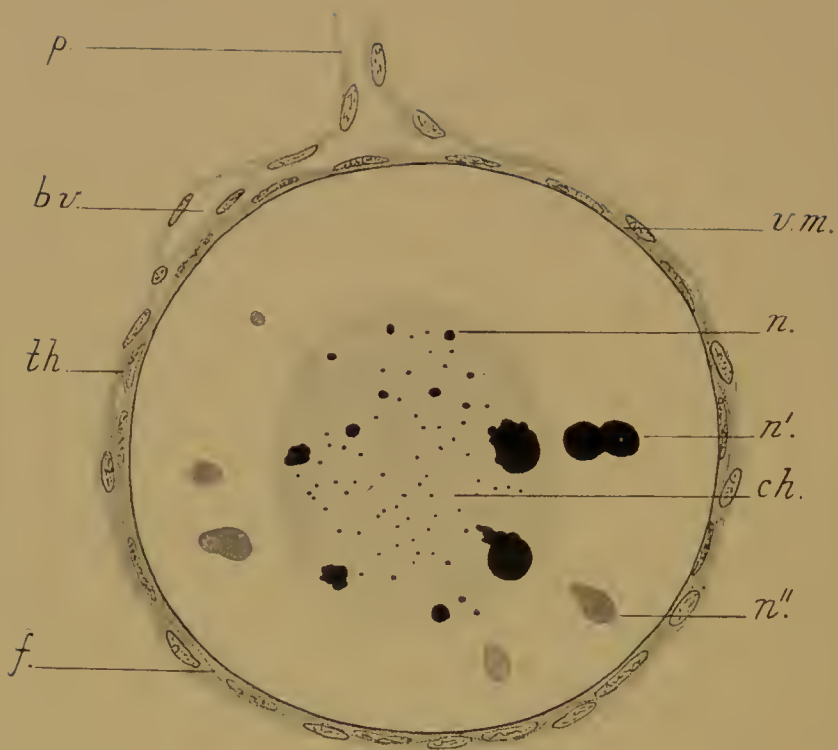


FIG. 38*.—Small ovarian egg of the frog surrounded by its follicle (*f.*) and theca (*th.*), which is continued into the pedicle (*p.*). *b.v.*, a blood-vessel between follicle and theca; *v.m.*, vitelline membrane; *ch.*, chromatin filaments, now achromatic; *n.*, chromatic nucleoli, ejected from the nucleus (*n'*.) and becoming achromatic (*n''*.).

through the nucleus. This is the *dictyate* condition, and in this the nucleus remains through the growth period until the moment of maturation arrives.

The period of growth and deposition of yolk. The nuclear changes accompanying the deposition of the yolk in the oocyte have only been studied in the Amphibia, to which we must now accordingly return (Fig. 38*).

We have seen that after the prophases the chromatin filaments become achromatic, while the nucleoli increase in number and become chromatic. The filaments gradually break up into a number of small granules, which disappear, or at least become indistinguishable from the general ground substance—or magma—of the nucleus.

The nucleoli become more numerous, larger, and more chromatic. They pass into the cytoplasm in one of two ways: either they are bodily ejected from the nucleus, lose their staining capacity and break up into small fragments, or else they disintegrate inside the nucleus, the products of their disintegration then passing out—either in the form of small particles or in solution—through the nuclear membrane into the cytoplasm. The nucleoli consist of nucleo-protein, and the result of their transference to the cytoplasm is that the latter first acquires an affinity for the chromatin stains, and then begins to secrete yolk-granules. There is thus a direct connexion between the nucleo-protein of the nucleoli and that which, as we have seen, is demonstrable in the yolk.

It appears that this cycle of changes is repeated many times during the growth of the oocyte, fresh nucleoli being formed, moving to the centre of the nucleus, and there disintegrating.

This passage of material from the nucleus to the cytoplasm of the egg-cell during the time of growth and yolk-formation is of constant occurrence in animals. The material may be solid and bodily ejected or liquid and diffusible, it may be chromatic or achromatic, but it is always given off and is always concerned in yolk-secretion. The chemical changes are, unfortunately, not fully understood.

The material is known generally as 'yolk-nucleus'. It has sometimes been confounded with another quite distinct struc-

ture, the sphere and centrosome. In Mammalian ova the sphere has indeed long been known as the yolk-body of Balbiani (Fig. 39). In the Mammals the sphere usually divides into two or more bodies, which persist for some time, but disappear (in the bat) when there are two or three cell-layers in the follicle.

In some Mammals (*Cavia*, *Vespertilio*) chromatoid bodies are found in the cytoplasm. These may be of nuclear origin and correspond to the yolk-nucleus of Amphibia.


The yolk-nucleus is a very important contribution made by the nucleus to the structure of the cytoplasm: a second contribution has still to be made.

With the growth of the oocyte the nucleus has been enlarging *pari passu*, and by the time growth is completed is of considerable size. It lies in the axis, but excentrically, near the surface in the animal half of the egg. The oocyte is now ready for the first maturation division.

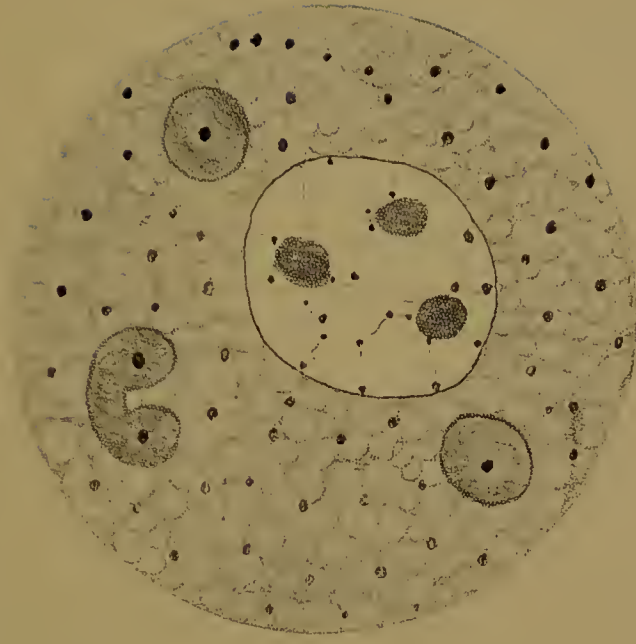
Maturation. The nuclear membrane breaks down and disappears. From a very small part of the achromatic substance of the nucleus a spindle—the first polar spindle—is formed (Fig. 41), and on this are placed the heterotypic chromosomes, of which we shall speak in a moment. The whole of the rest of the contents of the nucleus—chromatic nucleoli and achromatic granular ‘magma’—are cast into the cytoplasm. This is the second contribution made by the nucleus to the cytoplasmic structure, and it is of considerable importance, since on it in part depends the difference between animal and vegetative hemispheres.

As we have already had occasion to observe, there is a definite relation between the polar structure and symmetry of the egg and the structure of the embryo which is to come out of it, inasmuch as the anterior end is always developed near the animal, the posterior end near the vegetative pole. The structure of the embryo is at this moment being predetermined in the egg, by the dispersal of the contents of the nucleus.

This is a fact of universal occurrence. When the germinal vesicle breaks down, only a small part of it is utilized in the formation of the chromosomes which take part in the maturation mitosis. The remainder is given to the cytoplasm, of which it



A.



B.

FIG. 39.—A, Oocyte of the kitten with pachytene nucleus; in the cytoplasm the sphere and centrosome (yolk-body of Balbiani).
 B, Oocyte of guinea-pig. (After Lams and Doorne.) The sphere is divided into three or four pieces. In the cytoplasm are
 numerous chromatic bodies, the mitochondria.

forms henceforward a definite and integral part. Experiment has shown that that part is causally related to the development of certain organs, is therefore a vehicle of inheritance. It will be noticed that this process is without parallel in the male sex.

We return to the first polar spindle and its chromosomes.

The chromosomes appear first, as beaded filaments of heterotypic form—rings, crosses, figures of eight, curved rods, and so on (Fig. 40). Their number is the half-somatic or germ-number n . It has been disputed whether these chromosomes are identical with those which were formed at the end of the prophases, in the young oocyte.

It must be remembered, in discussing this question, that the hypothesis of the individuality of the chromatin does not necessarily involve that of the individuality of the chromosomes. We have seen elsewhere that there is reason for believing that the




FIG. 40.—Heterotypic chromosomes from the nucleus of the oocyte of the Axolotl (*Siredon*) just before the membrane breaks down.

chromatin of the nucleus comprises a number of qualitatively unlike bodies—not merely that the chromosomes are different, but that they are composed of individually different granules. It is also probable, to say the least, that chromosome formation is a matter of precipitation from solution, for there is certainly much more chromatin in a dividing than in a resting nucleus, and the chromatin often disappears from view in the latter condition. But a body endowed with certain properties will retain those properties in solution and emerge from solution with the same, and in a mixture of unlike bodies each will retain its own properties in solution and exhibit them afresh when reprecipitated. The chromatin granules are such bodies, and we may well suppose that they do retain their properties in spite of their disappearance. It does not follow, however, that the granules are associated always in the same order to form chromosomes, though that may be so. Hence the chromatin granules may well retain their individuality while the chromosomes do not.

The chromatin, therefore, of these heterotypic chromosomes that now appear may, on this view, be regarded as identical with the chromatin of the prophases.

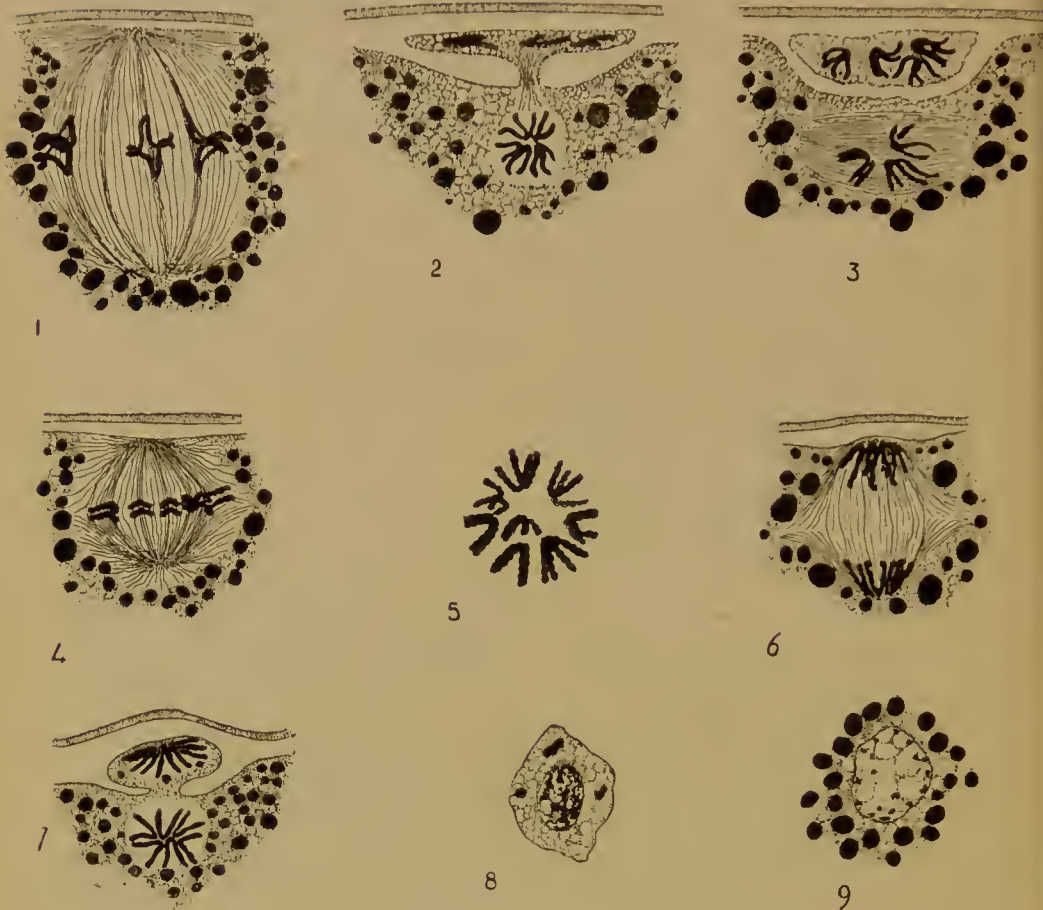

FIG. 42.—The maturation divisions in the female (Axolotl). 1, First polar spindle with heterotypic chromosomes; 2, Extrusion of first polar body; 3, Appearance of second polar spindle; longitudinal division of chromosomes in egg and in first polar body; 4, Second polar spindle radial; homoetypic chromosomes on equator (metaphase); 5, Polar view of the same; 6, Anaphase; 7, Extrusion of second polar body; 8, Second polar body with resting nucleus; 9, Female pronucleus in resting condition, closely surrounded by yolk-granules.

When the spindle is formed the chromosomes are placed on it and shorten and thicken (Fig. 41). The spindle then moves to the surface at the animal pole, where it takes up a radial position, closely surrounded by yolk-granules. The actual maturation divisions now occur.

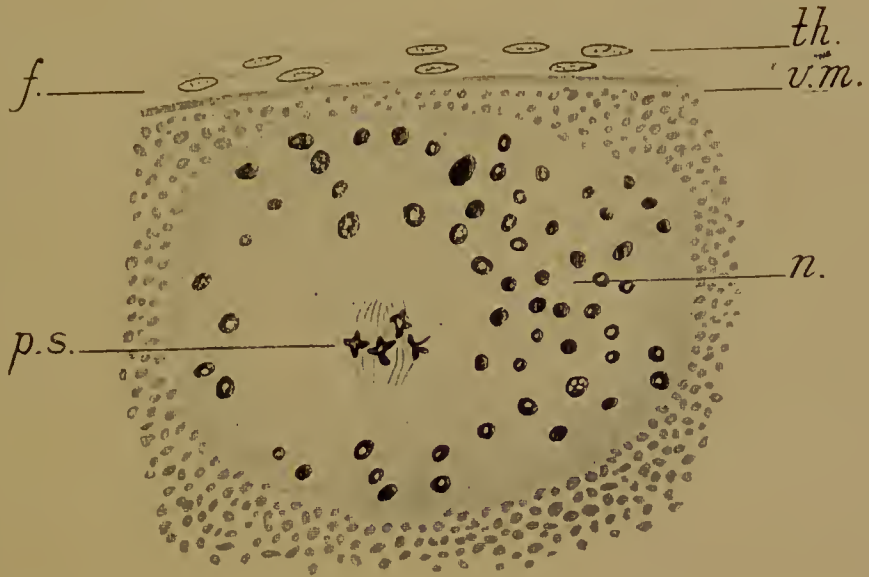


FIG. 41.—Germinal vesicle of the oocyte of the frog just before maturation (after Carnoy). The nuclear membrane has disappeared. The first polar spindle, bearing the heterotypic chromosomes, is seen in the middle of the nucleus (*p.s.*). *n.*, nucleoli; *v.m.*, vitelline membrane; *f.*, follicle; *th.*, theca.



FIG. 43.—Oocyte of mouse with heterotypic spindle from the Fallopian tube. The oocyte is still surrounded by the cumulus of follicle-cells.

The first maturation division (Fig. 42, 1, 2). The heterotypic chromosomes are placed upon the spindle in the same way as in the male—that is, with the extremities of the half-rings in the equators. The half-rings break away from one another and pass to the spindle poles. Cell-division now occurs. This is extremely unequal. The outer group of chromosomes, with a small quantity of cytoplasm, is cut off as the first polar body from the egg; it lies in a depression at the surface. The inner group of chromosomes remain in a clear area in the egg, now the secondary oocyte.

The first polar spindle is found (in *Siredon*, and generally in Amphibia, also in Birds) in the egg as it passes into the oviduct. In Mammalia—where it is also known to be heterotypic (Fig. 43)—it may be formed while the egg is in the ovary, or after it has passed into the Fallopian tube.

The first maturation division in the female evidently involves similar changes to those seen in the male: the prophases, the number and form of the chromosomes are all exactly the same. The interpretation of the manner of division of the chromosomes—whether longitudinal or transverse—which is adopted for the one, may therefore be applied to the other.

The second maturation division (Fig. 42, 3–9). Without passing into a resting condition the V-shaped chromosomes in the egg undergo longitudinal fission, as also do those in the first polar body. A number of parallel fibres, tangentially placed, now appear—the second polar spindle. The spindle is soon rotated into a radial position and the V-shaped chromosomes, already split, are thrown upon its equator with their apices towards the spindle axis, as in the male. Their number is, of course, n . The halves of the chromosomes then separate and pass to the spindle poles. Another unequal cell-division now occurs. The outer group of chromosomes, together with a little cytoplasm and one or two yolk-granules, is extruded as the second polar body, while the inner group remain in the now mature ovum as the female nucleus, or rather pronucleus, to employ the more usual term.

In both the second polar body and the ovum the chromosomes break up, a membrane is formed round them, and the nucleus passes into the resting condition.

Since the chromosomes are V-shaped, are longitudinally divided, and are present in half the normal number, this division is evidently homoeotypic, as in the male.

The second polar spindle is formed as the egg passes down the glandular region of the oviduct (in *Siredon* and most other Amphibia). In the uterus the polar spindles are in metaphase (with the chromosomes in the equator). The division is not completed until after the egg has been fertilized (which is just after the egg is laid).

Where fertilization is internal (Elasmobranchs, Birds, Reptiles, Mammals) the second polar body is extended while the egg is in the oviduct.

Although the chromosomes of the first polar body have divided, cell-division (in *Siredon*) does not usually follow. In other cases the first polar body does divide.

A centrosphere—if not an actual centrosome—is present at the poles of both the first and second spindles. In the mature ovum there is, however, no trace of it. The female pronucleus is immediately surrounded by yolk-granules (Fig. 42, 9).

Nature of the reducing division. We have already assumed for the purposes of illustration that the several chromosomes of a nucleus are genuinely different from one another. We may now add that there is experimental evidence (which we cannot discuss here) in support of this ; it is further probable that the granules of which each chromosome is composed are again of different values. Secondly, there are cases where the chromosomes are of different sizes (certain Insects), and in these cases they are found in pairs (in tissue- and in young germ-cells), the two members of a pair being of the same size. In the heterotypic division of maturation the members of the pairs get separated from one another, so that each secondary spermatocyte (and consequently each spermatid after the second homoeotypic division) receives a similar set of different-sized chromosomes.

Attention has already been called to the difference in size of the ring-shaped chromosomes in *Siredon*.

Now when a row of granules (or chromosome) is divided lengthways each half contains its due portion of each granule, and hence each daughter nucleus receiving half of each chromo-

some receives *ipso facto* a specimen of each different granule. The two daughter nuclei are therefore alike and a longitudinal division of the chromosomes is merely quantitative.

If, on the other hand, the row of granules (or chromosome) is transversely divided, or, what is the same thing, if two different chromosomes are separated from one another, each daughter nucleus will not receive a specimen of each different granule or chromosome, but only one-half, the remainder passing to the other nucleus, and the division is qualitative.

The first condition may be represented by some such formula as this (where *a-h* are the qualitatively different granules in a chromosome, *A, A', B, B', &c.*, whole chromosomes):

$$\frac{a b c d e f g h}{a b c d e f g h'} \quad \frac{A A' B B' C C' D D'}{A A' B B' C C' D D'}$$

the line being the division, while the second condition will be represented by

$$\frac{a b c d}{e f g h} \quad \text{or} \quad \frac{A B C D}{A' B' C' D'}$$

Ordinary somatic mitoses are therefore quantitative, and so is the second homoeotypic maturation division. If, however, we adopt the view that in the heterotypic mitosis a transverse division of the chromosomes is involved, then we must further believe that the division is qualitative, and consequently that the secondary spermatocytes, and eventually the spermatozoa, receive chromosomes of different kinds. Of every four spermatozoa produced from a single primary spermatocyte, therefore, two will be alike of one kind (containing, say, *A, B, &c.*), while two will be alike of another kind (containing *A', B', &c.*).

But it is evident from the foregoing that identical nuclear changes occur during maturation in the two sexes. The prophases of the first division—with the leptotene, synaptene, pachytene, and diplotene stages—are the same, and whatever view is taken of these phenomena must hold good for both sexes. In the female the growth period intervenes between the prophases and the actual division, but when this division occurs it is of the same form as in the male, heterotypic. The second division is homoeotypic in both sexes.

While, however, the cell-divisions are equal in the male—

resulting in four spermatozoa—in the female they are unequal—giving one large ovum which receives practically the whole of the cytoplasm and the yolk, and three small polar bodies. The similarity of the nuclei shows that in spite of their small size these polar bodies are in reality potential ova, and there are cases where they are large—as large as the ovum—and can be fertilized and develop.

Like the spermatozoa, the ovum (and polar bodies) receives only one-half the somatic number of chromosomes. As we shall see more fully in the next section, these chromosomes form a complete set, as do those of the male. If—as is probably the case—there are varietal differences between individual spermatozoa in respect of these chromosomes, the same will be true of the ova.¹

But what the further significance of these differences is, if they exist, we do not know. The chromosomes of the spermatozoon and ovum are certainly vehicles of inheritance—that is, concerned in the transmission of at least some of the inheritable characters of the species from one generation to the next. But since every spermatozoon or ovum can perform this function as well as every other, we are driven to conclude that each one possesses a complete set of the necessary specific chromosomes; but that in different spermatozoa or ova the chromosomes may be of different varieties—that is, be concerned in the transmission of different varieties of the same inheritable character.

This may be expressed by the following scheme.

$A, B, C, D, \&c.$, are the n different specific chromosomes.

In the tissue-cells and young germ-cells there are $2n$, each kind being represented by two slightly different varieties, namely,

A and A' , B and B' , C and C' , &c.

In the prophases of the heterotype division A and A' unite,² and so B and B' , C and C' .

In the actual heterotype division A and A' , B and B' , C and C' are separated from one another, so that each secondary spermocyte or oocyte has A or A' , B or B' , and so on.

¹ Provided of course that primary oocytes differ *inter se* in the arrangement and distribution of the heterotypic chromosomes.

² If the union is by parallel apposition it is further possible to suppose that the individual granules of which A and A' are composed pair off each with each, namely a with a' , b with b' , and so on.

The homoeotypic division is quantitative, hence each spermatozoon or ovum obtains A or A' , B or B' , and so on; that is, a complete set of the various kinds of chromosomes.

In only one respect are there chromosomal differences between the two sexes. In certain forms (*Insecta*), and possibly in others also, there is an accessory chromosome or heterochromosome (often paired), which not only differs in size and behaviour from the ordinary chromosomes, but is not the same in spermatozoon and ovum. The variations in the behaviour of this body or bodies are too complex to be discussed here, but those who have investigated it believe it to be concerned in the determination of sex. Apart from the heterochromosomes and the varietal differences of the ordinary chromosomes, the germ-nuclei are exactly alike.

We have now to see how the two nuclei—each containing one-half the somatic number of chromosomes—are brought together when the germ-cells unite in the act of fertilization.

IV. FERTILIZATION

The Axolotl—*Siredon*—will serve as a type (Fig. 44). The spermatozoon—which is of the same form as that of the newt and salamander—after passing through the mucin jelly surrounding the egg, reaches the surface of the latter. It approaches the egg with its anterior end—acrosome—and always in the pigmented animal hemisphere, sometimes near the equator, but more usually near the animal pole.

The acrosome pierces the surface-layer of the egg-cytoplasm, and immediately the egg reacts in a remarkable manner. From all sides there begins to flow towards the acrosome what appears to be a watery albuminous fluid: it is hyaline, but coagulable. This becomes concentrated round the acrosome in the form of a conical plug, the base of which projects at the surface, the apex towards the interior of the ovum (Fig. 44, A). This plug is the entrance-funnel, its base being known as the entrance-cone ('cone of attraction' is an erroneous expression, as it is not formed prior to the contact of the sperm with the egg). The entrance-funnel enlarges and extends more and more into

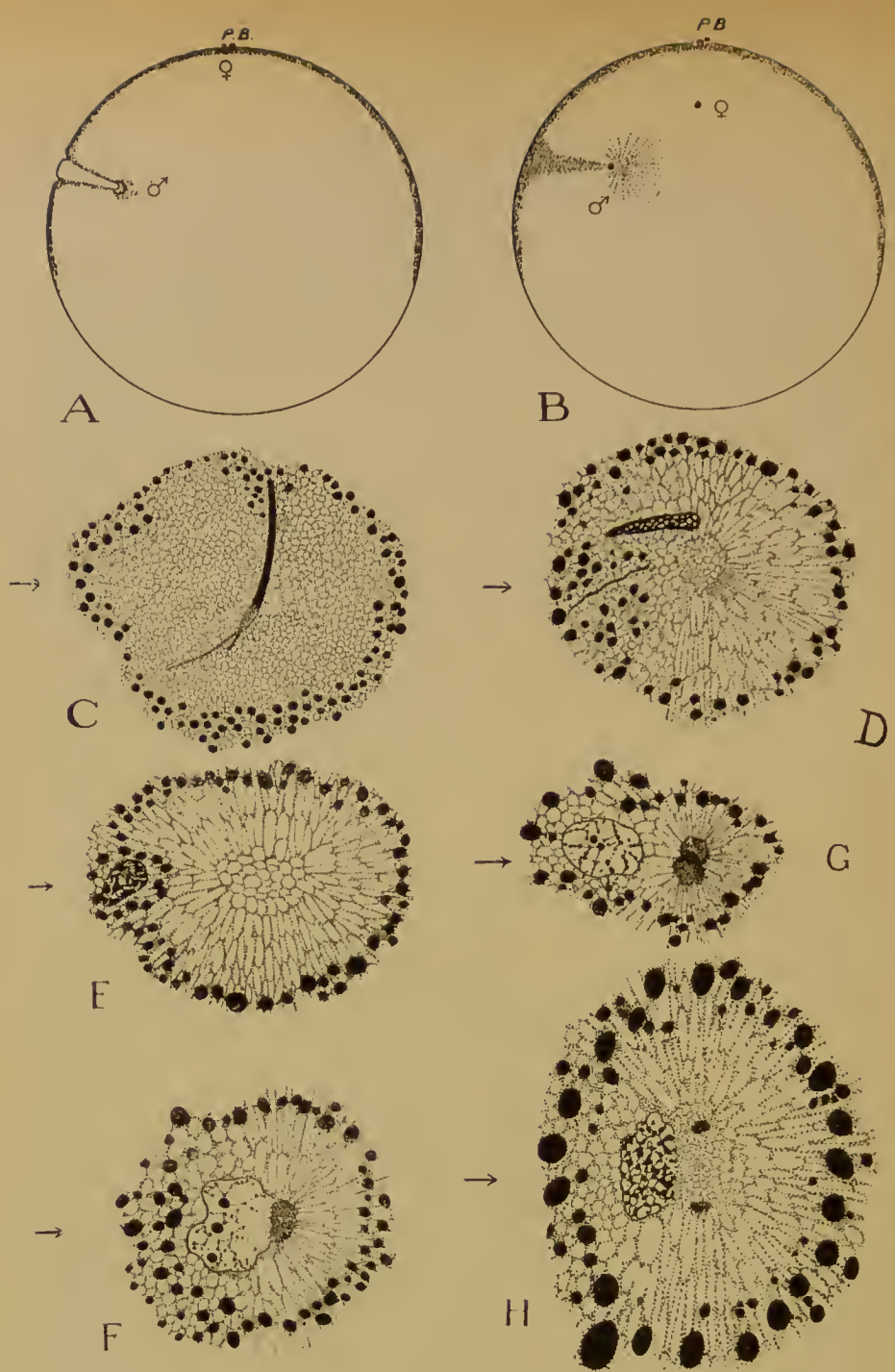


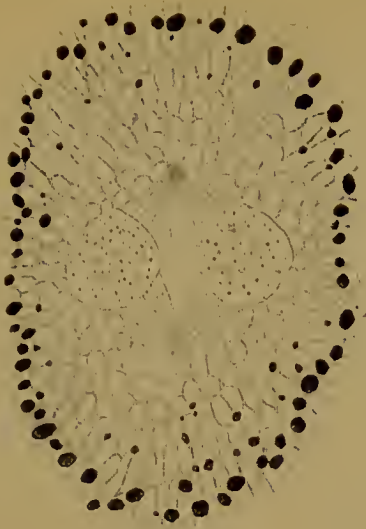
FIG. 44.—Fertilization in the Axolotl.

A and B, Meridional sections of the whole egg. A, Formation of entrance-funnel (first part of sperm-path). B, Formation of sperm-sphere and aster; ♂ male pronucleus; ♀ female pronucleus; *p.b.*, the two polar bodies.

C, Formation of the sperm-sphere round the middle piece (anterior centrosome); parts only of the head (black) and tail are shown.

D, Formation of the sperm-aster. The centrosome has disappeared; the head, beginning to be vacuolated, is separated from the tail.

E, Further shortening and vacuolation of the sperm-nucleus. There is still no centrosome.



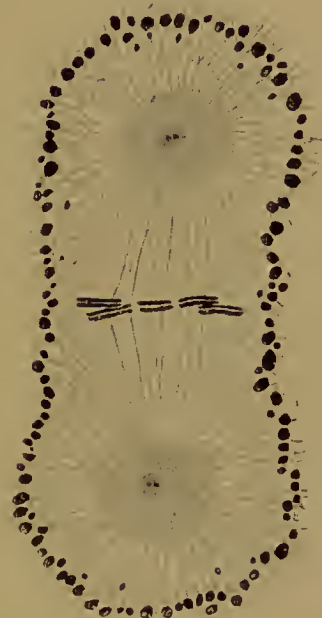I



J



K



L

F, Appearance of the definitive centrosome. G, H, Division of the centrosome.

(In C-H the arrow marks the direction of entrance of the spermatozoon.)

I, Approach of the two pronuclei. Formation of spindle-fibres.

J, Formation of asters, elongation of spindle, further enlargement of pronuclei, and appearance of chromosomes.

K, Further elongation of spindle, and formation of a centrosphere round each centrosome. The pronuclear membranes are breaking down and the spindle-fibres passing in.

L, The fully-formed fertilization spindle. In the equator are the chromosomes, now longitudinally split, and attached to large spindle-fibres. In each centrosome the centriole has divided.

the interior of the ovum, being directed usually towards the axis: it carries in with it a number of the superficial pigment granules and the spermatozoon. The latter, therefore, after moving actively up to the surface of the ovum and penetrating it with its acrosome, is passively carried in by the inflow of the entrance-funnel; this movement is apparently due to a difference in surface tension between the entrance-funnel and the surrounding cytoplasm. The acrosome presently gets caught in the side of the entrance-funnel, but the substance of the latter, still moving on, carries the head and tail of the sperm with it. The result is that the anterior end of the head now faces outwards, while the posterior end lies at the bottom of the funnel, where the head is bent on the tail, and the whole sperm-head has been rotated through 180° . Between the head and the tail—and therefore now at the inner end of the funnel—is the large anterior centrosome (Fig. 44, c.).

The entrance-funnel soon disappears, but the pigment carried in by it remains for some time as a streak, usually known as the first part of the sperm-path (Fig. 44, B).

A clear, yolk-free area now appears round the centrosome; this is the sperm-sphere (Fig. 44, c). Very soon radial fibres or processes of some kind begin to pass out from the sphere amongst the yolk-granules; this is the sperm-aster (Fig. 44, D). Meanwhile the head or sperm-nucleus has become detached from the tail, and the centrosome which was between them has totally disappeared. It seems that the formation of the sperm-sphere and aster—like that of the entrance-funnel—is due to the extraction of water from the cytoplasm, in the case of the entrance-funnel by the acrosome, in the present case by the centrosome; and that the centrosome is completely used up, in fact dissolved, in the process.

The tail of the spermatozoon will not concern us: it degenerates and vanishes. The head of course remains to become the sperm-nucleus or male pronucleus. It shortens and thickens: as it does so it becomes vacuolated. By further shortening and vacuolation it becomes transformed into an ordinary nucleus (Fig. 44, E). It lies on the outside of the sperm-aster.

It is at this moment that the definitive centrosome makes its

appearance (Fig. 44, F). On the side towards the sperm-aster the nuclear membrane breaks down, and through the aperture something comes out of the nucleus which appears, when outside, as a rounded granular body. This is the definitive centrosome. It is not preformed in the sperm-nucleus and then ejected, but, probably, is due to a precipitation of the albumins of the cytoplasm by the nucleic acid of the sperm-nucleus. But, whatever interpretation be put upon the process, the centrosome is of male origin.

The male pronucleus, preceded by its centrosome and aster, now advances to meet the female pronucleus which has already left its position at the animal pole and is returning towards the centre of the egg. The line in which the male pronucleus is now moving is known as the second part of the sperm-path. This does not necessarily lie in the same straight line, nor even in the same meridional plane as the first or entrance part of the path. This depends in part on the position of the female pronucleus (Fig. 46).

The first or entrance part of the path is usually directed towards some point in the egg axis, that is, it lies in a meridional plane of the egg. If, as also is usual, the female pronucleus lies in the axis, it is evident that the second part of the sperm-path or line of union of the two pronuclei will lie in the same plane. In that case it may be in the same straight line with the first part, or, more usually, make an angle with it, since the point in the axis at which the pronuclei meet is at a fairly constant distance from the animal pole, while the point of entrance of the spermatozoon in the animal hemisphere is variable. If, however, while the first part of the path is in a meridional plane the female pronucleus is not in the axis, then the sperm-nucleus must turn out of its meridional plane to meet the female pronucleus at some point which is not in the axis. The converse of this is seen when the entrance-path is not in a meridional plane while the female pronucleus is in the axis; in this case also the sperm must turn aside. Thirdly, both sperm-entrance path and female pronucleus may be out of their normal direction and position.

In other words, the meridional plane which includes or is

parallel to the entrance-path does not necessarily coincide with the meridional plane which includes or is parallel to the line of union of the pronuclei.

During the advance of the sperm-nucleus the centrosome divides (Fig. 44, G, H) at right angles to the direction in which the sperm-nucleus is travelling, that is, to the second part of the sperm-path, and also to the meridional plane in which the path lies. The daughter centrosomes therefore lie in a plane parallel to the equator of the egg. Hence, when the pronuclei have met, they lie together between the daughter centrosomes, which lie in a plane parallel to the equator of the egg.

The two pronuclei are now closely apposed, but not fused, inside the sperm-sphere and aster. Next, the centrosomes send out fine fibres in all directions (Fig. 44, I, J). On the one hand these impinge upon the pronuclear membranes—these are the beginning of the fertilization spindle; on the other hand they radiate out until they pass into the radiations of the original aster inside which they lie.

The pronuclei enlarge, and presently in each granules of chromatin appear and run together in rows to form chromosomes (Fig. 44, J). The number of these in each pronucleus is the same as that which entered into it at the close of maturation, namely n , the germ-number. Meanwhile the asters round each centrosome have been growing larger, the spindle-fibres longer, and the latter now break through the pronuclear membranes to meet their fellows from the opposite pole (Fig. 44, K). The membranes, achromatic network, and nuclei are now all dispersed, and the two sets of chromosomes, paternal and maternal, are placed side by side on the equator of the fertilization spindle, where they undergo longitudinal fission as in ordinary mitosis (Fig. 44, L). Hence, when the daughter chromosomes pass to the spindle poles, each daughter nucleus will receive a complete set of paternal, and a complete set of maternal chromosomes. The full somatic number, $2n$, is now restored, and with each repetition of nuclear and cell-division each cell in the body comes to possess $2n$ chromosomes, one-half of which are derived from the father, one-half from the mother.

With the apposition of the two sets of chromosomes in the

equator of the division apparatus—asters and spindle—the act of fertilization may be said to be complete.

The whole falls into two periods. In the first the spermatozoon is carried into the egg by means of the entrance-funnel, which in turn is due to a stimulus of some kind imparted to the egg cytoplasm by the acrosome; the acrosome is the modified centrosphere. In the second the definitive centrosome is formed from the male pronucleus and the division apparatus made between its two halves while the pronuclei meet. The mechanisms involved in both periods are therefore centrosomal.

The details of fertilization have been studied in many animals, including several Vertebrates. In Vertebrates it is a rule for the sperm to enter during the second maturation division of the ovum, as in the Axolotl (*Petromyzon*, *Salmo*, *Triton*, *Mus*), but in other cases it may enter at an earlier or later period. The tail may be left outside (*Mus*), but is more often taken in: it always degenerates.

The pronuclei may fuse to form a segmentation nucleus, from which $2n$ chromosomes arise (*Pristiurus*, *Salmo*, *Petromyzon*); but the newt and the mouse resemble the Axolotl in the separate formation of the chromosomes in each pronucleus.

It is certain that in all cases the female centrosome disappears. Whether the definitive cleavage centrosome is identical with the centrosome seen in the spermatozoon, that is, in the spermatid, or is, as in the Axolotl, a new formation from the sperm-nucleus, is not certainly known, but there is little doubt that it is invariably a male centrosome.

As a rule only one spermatozoon enters the egg, and the presence of more than one leads to serious derangements of development (pathological polyspermy).¹ In what is known as physiological polyspermy, however, two or more, sometimes a great number, normally get in, as in some Amphibia (including the Axolotl), Reptiles, Birds, and Elasmobranch fishes, in which last they are very numerous and known as 'merocytes' (Rückert). In these cases only one of the sperm-nuclei fuses

¹ As in the sea-urchin, where the several nuclei fuse and their chromosomes become irregularly distributed. Where, however, as in the frog, the several nuclei remain apart the polyspermy need not cause abnormal development (M. Herlant, *Arch. de Biol.* xxvi, 1911), although the superfluous sperm-nuclei do take part in the edification of the embryo.

with the egg-nucleus. The remainder lie about in the yolk, each develops its own centrosome and aster, and may divide (with n chromosomes) many times. Ultimately the accessory sperm-nuclei degenerate without contributing to any embryonic structure.

It remains for us to discuss the significance of fertilization.

It has commonly been supposed that its essence is to be found in the union of the pronuclei of the germ-cells, both nuclei being held to be necessary for the development of a normal individual. This view is based partly on the phenomena of conjugation in certain Infusoria, but also very largely on the assumption that the nuclei of the germ-cells are the sole vehicles for the transmission of inheritable characters; this again rests upon the fact that it is only in their nuclei that the germ-cells are alike, while in every other respect they differ, and upon the supposition that the paternal and maternal contributions to the total inheritance are equal.

Now, whatever view we may take of the parts played by nucleus and cytoplasm respectively in the handing on of the characters of the species, it is most assuredly certain that for the production of a normal individual both pronuclei are not a necessity. In the first place, there is the phenomenon of parthenogenesis, natural and artificial. In the former the ovum develops without fertilization by the sperm and without artificial assistance (as in Aphidae and some other Insects, and in certain Crustacea). In the latter the stimulus usually given by the sperm is replaced experimentally by some physical or chemical agent. Thus the ovum of a sea-urchin or Mollusc may be stimulated by treatment with hypertonic sea-water, or butyric acid or other substance, or by mechanical shock, or a lowering of the temperature; in the case of the frog it is sufficient to pierce the egg with a fine needle. In all these instances some physical or chemical alteration (or both) is produced in the egg, as a result of which it begins to segment and develop. The process, if care is taken, may be perfectly normal, and the individual reach the adult condition. A sexually mature (male) sea-urchin has been reared in this way.

In all cases of parthenogenesis only the female pronucleus is present.

The converse is seen in what is called merogony, where the egg (of a sea-urchin, Worm, or Mollusc) is divided into two halves, only

one of which contains the nucleus. Both halves can be fertilized, the nucleate and the enucleate, and will develop into normal larvae. In the latter case only the male pronucleus is present.

On the other hand, a nucleus must of course be present, and actual experiment has shown that what is really necessary for normal development is the presence in the ovum, and ultimately in every cell of the body developed from it, of a complete set of the n unlike chromosomes characteristic of the species.

Hence, both male and female pronuclei are not necessary, and we must look elsewhere for the significance of fertilization.

As we know already, the germ-cells of both sexes pass through two maturation divisions, and two only, after which their capacity for reproducing themselves is lost. The first effect, or almost the first effect, of their union is that their product, the fertilized ovum, begins to segment and continues to do so. In other words, the power of reproduction by cell-division which was previously lost is in fertilization restored. It is mutually restored.

That the ovum regains the power of nuclear and cell-division is obvious: we see the maternal chromosomes undergo longitudinal fission, as they lie on the spindle, and subsequently we see the egg cytoplasm divide. In the case of the male we see the male chromosomes divide in ordinary fertilization as they lie alongside the female; in the fertilization of enucleate egg-fragments the stimulus imparted by the female cytoplasm to the male chromosomes is still more evident.

A study of fertilization reveals the mechanism by which this stimulation is effected. For ordinary nuclear and cell-division an apparatus is necessary, the spindle with its asters; this apparatus is made by the centrosomes in the cytoplasm, the two centrosomes proceeding from the division of one, and its function is first to pull apart the halves of the divided chromosomes, and second, to ensure cell-division by the cell-plate or intermediate bodies developed in the equator.

The mature ovum possesses no centrosome: the mature spermatozoon possesses little cytoplasm, and that only in the tail. In fertilization the centrosome is either introduced by the male cell or made by it after entering the egg: the necessary cytoplasm in which this centrosome can divide and make the

asters and spindle is provided by the female. The wholly different structures of the two germ-cells are therefore mutually complementary in the stimulation by which the lost power of cell-division is restored, and this is the significance of fertilization.

The experiments on artificial parthenogenesis suggest that a physico-chemical expression may be found for this stimulus.

This is not, however, its only effect. A very common, if not universal, result of the approach of the sperm is the exudation by the ovum of a perivitelline fluid. In some cases (for instance, the sea-urchin) a membrane which prevents the entry of more spermatozoa is secreted at the same time and pushed out by the perivitelline fluid. In the frog it remains as a thin fluid layer between the ovum and the jelly; it is the exudation of this fluid which enables the egg previously adherent to the mucin jelly to turn over till its axis is vertical and the white pole below: this occurs shortly after insemination.

Of greater importance than this is the change in the cytoplasmic structure of the egg brought about at this time.

A few hours after insemination there appears in the frog's egg a crescentic grey patch on one side along the border of the pigmented area (Fig. 45). The grey crescent is due to the immigration of pigment from the surface into the interior, and this in turn is caused by the entrance of the spermatozoon. The grey crescent always appears on the side of the egg opposite to that on which the sperm has entered. We know that a watery fluid flows towards the sperm from the cytoplasm (the entrance-funnel first, and later the sperm-sphere, are due to this), and we may suppose that this streaming movement drags the pigment granules away from the surface on the opposite side, whence the grey crescent.

The grey crescent is actually opposite to—that is, in the same meridional plane as—the first or entrance part of the sperm-path (Fig. 46). Hence it does not necessarily lie in the same meridional plane as that which includes the line of union of the pronuclei.

We shall see in the next chapter that the meridional plane of the first division always includes the line of union of the pronuclei, and hence does not always coincide with the meridional plane of the grey crescent.

It is clear that, whereas the unfertilized egg was radially symmetrical about its axis, it can now be divided into similar halves by only one plane, that which includes the axis and the middle point of the grey crescent. About this plane it is bi-laterally symmetrical. The greatest interest attaches to this alteration of symmetry, since the side of the grey crescent will become the dorsal side of the embryo, the side on which the sperm

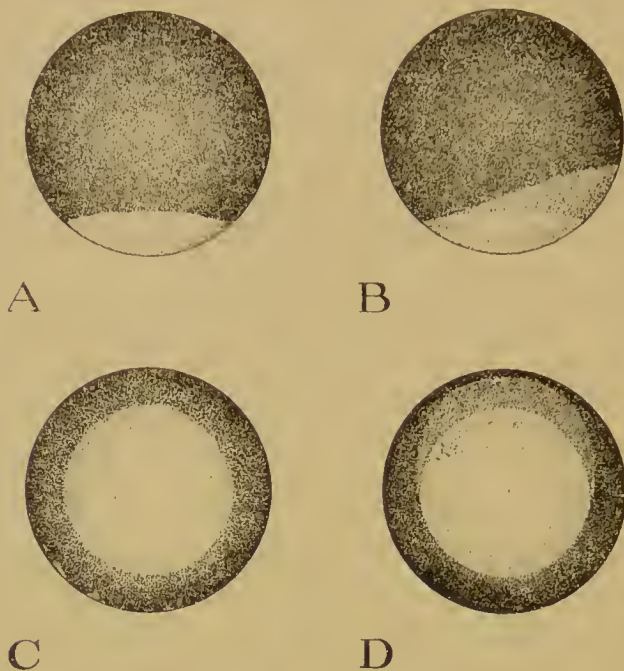


FIG. 45.—Formation of the grey crescent in the frog's egg (*R. temporaria*). A, B from the side; C, D from the vegetative pole. In A, C there is no crescent, in B, D a part of the border of the pigmented area has become grey.

entered its ventral side. Since the animal and vegetative poles mark respectively the future anterior and posterior ends (approximately), it follows that the plane of symmetry of the fertilized but unsegmented egg coincides with the median longitudinal or sagittal plane of the future embryo. The whole bilateral symmetry of the embryo is now predetermined in the cytoplasmic structure of the egg.

That the blastodisc has a bilateral structure in Birds and Elasmobranch fishes also seems to follow from the fact that the

cells in both these cases are larger at one end of the blastoderm than at the other. Further, this structure is definitely related to that of the embryo since the large-celled end becomes anterior.

Whether the change from the original radial to the definitive bilateral symmetry is in these cases also brought about by the spermatozoon, future researches must show.

In the Teleostei the concentration of the superficial cytoplasm (periblast) to form the blastodisc is an effect of fertilization.

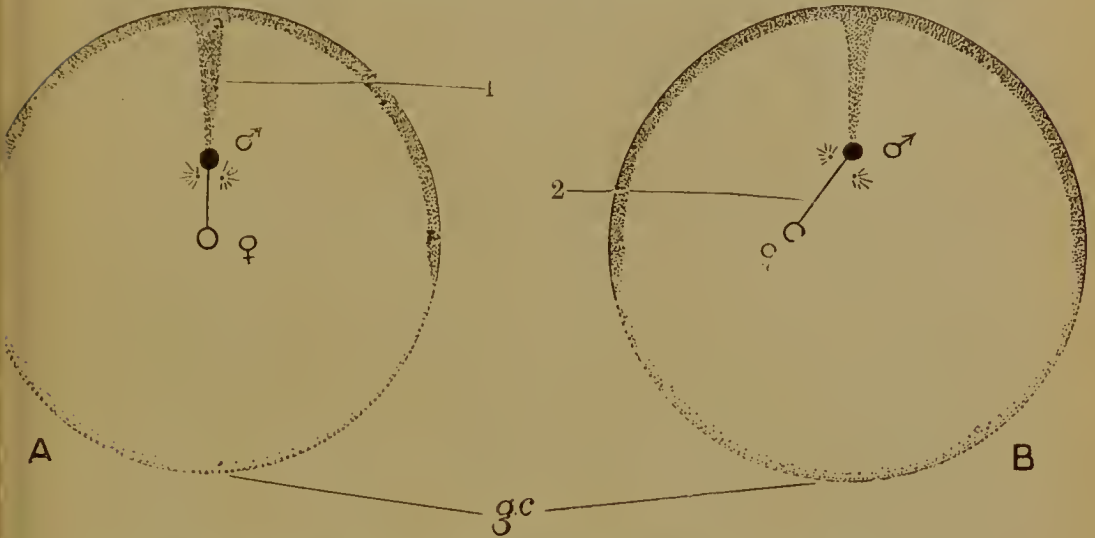


FIG. 46.—Diagrams to show the relation between the first and second parts of the sperm-paths. The paths are projected on a plane perpendicular to the axis. In A the two parts are in the same meridional plane, in B in different meridional planes. 1, First part of the sperm-path; 2, Second part; ♂, male pronucleus; ♀, female pronucleus; *g.c.*, grey crescent: on the opposite side (side of entrance of the sperm) the superficial pigment is dark. The centrosome has divided in a plane perpendicular to the axis, at right angles to the second part of the path.

In conclusion we may attempt to estimate the parts played by the cytoplasm and the nucleus of the germ-cells in inheritance.

That some at least of all the inheritable characters of the species—and not only specific but varietal and individual characters as well—can be inherited from the father as readily as from the mother is obvious. Since the nucleus, beside the centrosome, which is merely an organ of cell-division, and the aerosome, which merely provides for the entrance, is the only part of the male cell which is always incorporated in the fertilized ovum, for the tail may be left outside, we are obliged to regard the

nucleus, that is, the chromosomes, as the vehicles by which these characters are transmitted.

The chromosomes of the nuclei of the germ-cells—which, as we have already pointed out, are different from one another—are in some sense the determinants of inheritance in the offspring: on their presence depends the ultimate appearance in the offspring of certain characters, and, in respect of their capacity for transmitting these characters, the two germ-cells are similar: each possesses a full set of the necessary chromosomes. In ordinary sexual reproduction the offspring receives two such sets, but one will suffice, as in parthenogenesis and merogony.

It does not, however, follow that the determinants for the whole of the inheritance are located in the nucleus.

As we have just seen, the material for the different parts of the body of the embryo is present in the cytoplasm of the fertilized but unsegmented egg; to that structure the spermatozoon has contributed nothing, beyond the rearrangement of material, the substitution of a bilateral for a radial symmetry. Experiment teaches us that the various parts of this structure are so many organ-forming substances, causally related to the development of certain organs, and therefore determinants of a part of the whole inheritance; and recent researches on heterogeneous hybridization show clearly what this part is. The ovum of a sea-urchin, if the proper precautions are taken, may be fertilized by the sperm of a starfish, a feather-star (both of which of course are, like the urchin, Echinoderms), or even of a Mollusc or Worm. The result is always the same. A typical sea-urchin larva is developed. Even an enucleate egg-fragment will develop a little way when so fertilized, and exhibits the maternal characters alone. The spermatozoon employed does nothing but convey to the egg a stimulus, which sets the process in action; its chromosomes sometimes persist, sometimes do not.

Hence the characters, the determinants of which reside in the cytoplasm, are the large characters which put the animal in its proper phylum, class and order, which make it an Echinoderm and not a Mollusc, a Sea-urchin and not a Starfish; and these large characters are transmitted through the cytoplasm and

therefore through the female alone. The smaller characters—generic, specific, varietal, individual—are equally transmissible by both germ-cells, and the determinants of these are in the chromosomes of their nuclei.

And yet the cytoplasm of the egg-cell is indebted very largely for its structure to the activity of the nucleus. As we have seen, the nucleus makes two contributions to the cytoplasm, first, the so-called 'yolk-nucleus', the substances concerned in the deposition of the yolk, and second, the contents of the germinal vesicles dispersed when the latter breaks down at maturation. These processes are perhaps independent of the chromosomes. Further, they find no parallel in the male sex.

Even if, therefore, the cytoplasmic determinants are ultimately to be assigned to the nucleus, the share taken by the female in the transmission of the whole heritage is greater than the part played by the male.

LITERATURE

W. E. AGAR. The spermatogenesis of *Lepidosiren paradoxa*. *Quart. Journ. Micr. Sci.* lviii, 1911.

G. BEHRENS. Die Reifung und Befruchtung des Forelleneies. *Anat. Hefte*, x, 1898.

J. B. CARNOY et H. LEBRUN. La vésicule germinative et les globules polaires chez les Batraciens. *La Cellule*, xii, xiv, 1897, 1898.

J. B. FARMER and J. E. S. MOORE. On the meiotic phase in animals and plants. *Quart. Journ. Micr. Sci.* xlvi, 1905.

K. HERFORT. Die Reifung und Befruchtung des Eies von *Petromyzon fluviatilis*. *Arch. mikr. Anat.* lvii, 1901.

J. W. JENKINSON. Observations on the maturation and fertilization of the egg of the Axolotl. *Quart. Journ. Micr. Sci.* xlvi, 1904.

E. KORSCHULT u. K. HEIDER. Vergleichende Entwicklungsgeschichte der wirbellosen Tiere. *Allg. Th.*, Lief. 2, Jena, 1903.

F. MEVES. Ueber die Entwicklung der männlichen Geschlechtszellen von *Salamandra maculosa*. *Arch. mikr. Anat.* xlvi, 1896.

F. MEVES. Es gibt keine parallele Conjugation der Chromosomen! *Arch. Zellforsch.* i, 1908.

T. A. MONTGOMERY. The heterotypic maturation mitosis in Amphibia and its general significance. *Biol. Bull.* iv, 1903.

A. OPPEL. Die Befruchtung des Reptilieneies. *Arch. mikr. Anat.* xxxix, 1892.

J. RÜCKERT. Zur Befruchtung des Selachiereies. *Anat. Anz.* vi, 1891.

A. u. K. E. SCHREINER. Die Reifung der männlichen Geschlechtszellen von *Salamandra maculosa*, *Spinax niger* und *Myxine glutinosa*. *Arch. de Biol.* xxii, 1906.

J. SOBOTTA. Die Befruchtung und Furchung des Eies der Maus. *Arch. mikr. Anat.* xlv, 1895.

E. B. WILSON. The cell in development and inheritance. New York, 1902.

H. VON WINIWARTER. Recherches sur l'ovogenèse et l'organogenèse de l'ovaire des Mammifères. *Arch. de Biol.* xvii, 1901.

CHAPTER V

SEGMENTATION

APART from the exudation of the circum-vitelline fluid, and, in some cases at least, the assumption of a definite bilateral symmetry, the first sign that the fertilized ovum gives of its activity is cleavage or segmentation. In this process the material of the egg-cell, which, as we have seen, has a certain structure, is cut up by successive nuclear and cell-divisions into an increasingly greater number of increasingly smaller elements. The division of the nuclei is always by karyokinesis.

These cleavages pass through the egg substances in a perfectly definite way, which may be readily described by reference to the structure and symmetry of the egg, its axis, poles, and equator.

As a type we may consider the cleavage of such an egg as that of the common frog (*Rana temporaria*). The egg is of the small-yolked or microlecithal type, and its cleavage is total or holoblastic, that is to say, the whole substance of the germ is divided (Fig. 47).

The first cleavage is a meridional one, that is, is in a plane which includes the axis of the egg. The cleavage begins at the animal pole, and is seen externally as a fairly wide furrow. The division is extended inwards, and at the surface of the egg gradually round to the vegetative pole. At the very beginning, therefore, it may be seen that the protoplasm is divided more readily than the yolk. Prior to the division the surface of the egg at the animal pole is markedly flattened. At the sides of the furrow are a number of small wrinklings in the superficial skin or membrane of the cytoplasm (not the vitelline membrane, but the surface layer of the egg itself). These wrinklings, which are at right angles to the furrow at the animal pole and directed away from the animal pole at either end, are quite transitory

effects of the internal forces to which cleavage is due. As soon as it is completed the furrow becomes narrowed.

By a meridional furrow the egg is necessarily divided into equal parts or blastomeres. The cleavage may, however, be parallel to a meridian and therefore unequal. This is not, however, in any way prejudicial to a perfectly normal development.

The two blastomeres soon prepare for the simultaneous divisions of the second phase. As before, the division is preceded by a flattening of the egg at the animal pole, and the same transverse wrinklings are seen. In each blastomere the furrow begins at the animal pole, proceeds internally and round to the vegetative pole.

Usually the two divisions of this phase are again meridional and intersect the first furrow at right angles. In that case there are four surfaces of contact between blastomeres intersecting in one line, the egg-axis. This is cleavage of the pure radial type. But it may happen, owing to slight inequality of division in either one or both of the two blastomeres, that the second furrows fail to meet, either at the animal or at the vegetative pole, or at both. There is then intercepted between them a small portion of the first furrow, known as the cross- or polar-furrow. By shifting of the blastomeres the polar-furrow soon comes to make an angle with the remaining portions, that is the ends, of the first furrow, these two ends being parallel to one another. There are now five surfaces of contact between blastomeres, surfaces which intersect approximately at angles of 120° , and cleavage is no longer radial.

There are now four blastomeres, each of which has a similar portion of the animal, pigmented, and vegetative, unpigmented, regions of the egg. The simultaneous divisions of the third phase separate these regions, for the cleavage is latitudinal, or parallel to the equator and nearer the animal than the vegetative pole. The divisions intersect the first two cleavages at right angles. The result is four small animal, four large vegetative blastomeres, the former wholly, the latter partly pigmented. During the progress of the division the transitory superficial wrinklings may again be seen.

In the fourth phase of cleavage division begins rather earlier in the animal than in the vegetative cells. In direction it is on

FIG. 47.—Segmentation of the egg of the frog (*Rana temporaria*) except G (*Rana esculenta*). (E, H, from Morgan, after Schulze; G, after Roux.)

A. First furrow, from the side of the grey crescent. The furrow is in the plane of symmetry, that is, in the middle of the grey crescent. The furrow has not quite reached the vegetative pole.

B. First furrow from the animal pole. The division is not quite meridional in this case; the two cells are therefore unequal.

C. From the vegetative pole. First furrow completed, and now closing up. Second division with a wide furrow coming round from the animal side. The first furrow has cut the grey crescent obliquely (the grey crescent is at the top of the figure).

D. Beginning of the second division, from the animal pole.

E. Second division in which the furrows do not intersect the first furrow at the same point; the part of the first furrow intercepted between them is a polar furrow, and the first furrow is bent twice.

F. Typical division of the fourth phase, seen from the side opposite the grey crescent. The third latitudinal division is completed; the fourth is completed in the animal, but not yet in the vegetative cells.

G. The bilateral fourth division in the egg of *Rana esculenta*, from the animal pole. The first division runs up and down the page, the second from side to side. The third is in the plane of the page. The upper side of the figure is the side of the grey crescent (dorsal). The second division has been unequal, the two dorsal cells being smaller. On this side the furrows of the fourth phase run into the second furrows, while on the opposite ventral side these divisions run into the first.

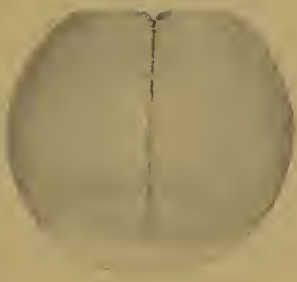
H. Fourth division. Abnormal case in which the furrows are parallel to the first. (From the animal pole.)

I. Fourth division. Usual appearance from the animal pole. The furrows do not meet exactly, but pass into the first or second near the animal pole.

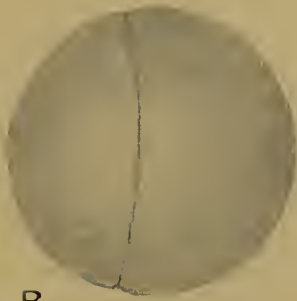
J. Side view of the fifth (latitudinal) division.

K. Later stage, seen from the left side, the grey crescent being on the right of the figure.

L. End of segmentation from the same point of view as the last. The grey crescent has become white and the original white area so enlarged.




A



B



C



D



E



F



G



H



I



J



K



L

the whole meridional, and at angles of 45° to the first two cleavages, and therefore of the radial type ; but there are many departures from this rule. Thus, instead of intersecting at the animal pole, the furrows may run into the first or second, and in a variety of ways ; in one variety the resulting arrangement is isobilateral (with two planes of symmetry), in another it is bilateral (with only one plane of symmetry), and the latter is stated to be the normal method of the fourth cleavage in the edible frog (*Rana esculenta*). But though liable to much variation the divisions are always parallel to a meridional plane, or only slightly oblique ; they are never parallel to the equator. As has been already pointed out, these irregularities of cleavage do not involve any abnormality in development.

In the fifth phase the furrows are once more latitudinal, and result in the production of four tiers of eight cells each. In the animal cells the division is approximately equal, in the vegetative unequal, four smaller pigmented blastomeres being separated from four larger, partly unpigmented. In this phase, again, division begins first in the animal cells. Departures from accurately latitudinal division are of frequent occurrence.

Up to this moment segmentation has been fairly regular, and synchronous in each phase, at least in cells belonging to the same region of the egg ; but from now onwards there is little regularity in direction, or simultaneity in time of division. The only rule that is rigidly adhered to is seen in the more rapid division of the small, pigmented, protoplasmic animal cells, the less rapid cleavage of the larger, yolky, unpigmented vegetative cells.

Further, while up to now all the furrows have been perpendicular to the surface, tangential divisions, separating the outer from the inner portion of a cell, now occur, and the segmentation cavity or blastocoel is formed (Fig. 48). The first sign of this may indeed be detected in the eight-cell stage, as a small space between the cells, in the axis of the egg, but nearer the animal than the vegetative pole. The cavity is soon enlarged, partly by the secretion of albuminous material, partly by the absorption of water from outside, and becomes eventually an extensive, hemispherical cavity in the animal portion of the egg.

As a result of all these processes—continued division, more rapid in the animal cells, and tangential as well as perpendicular to the surface, and enlargement of the segmentation cavity—the frog's egg, now known as a blastula, presents at the end of cleavage the following appearance (Fig. 48*): the roof of the segmentation cavity is formed of about four layers of small animal cells. The cells of the outermost layer are deeply pigmented, and arranged in a cubical, or shortly columnar epithelium; in the next two layers the cells are rounded, or by mutual pressure polyhedral; in the innermost layer they are

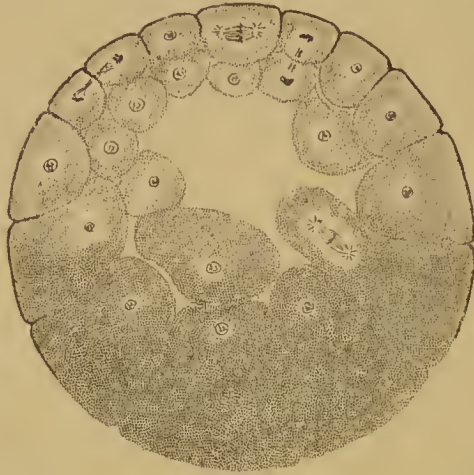


FIG. 48.—Meridional section through the egg of the frog in an early stage of segmentation, showing the segmentation cavity.

again in the form of a cubical epithelium. These animal cells contain only small yolk-granules. The floor of the segmentation cavity is occupied by about twenty layers (in the greatest thickness, that is, in the axis) of large cells heavily laden with large granules of yolk, while the intermediate region, round about the equator of the egg, is occupied by cells which in size, amount of yolk, and size of the yolk-granules, are intermediate between the above two kinds. The superficial pigment extends beyond the equator into the vegetative region, but on one side, that on which the grey crescent was formed and the unpigmented area consequently enlarged, it is less extensive than on the other. The segmentation cavity is symmetrically placed about the egg-axis, but lies wholly in the animal hemisphere.

It is evident that by the process of cleavage the unlike material of the egg has been cut up into a number of cells, the characters of which are derived directly from the characters of that region of the egg-substance from which they come. There is thus, during segmentation, no differentiation—beyond the formation of the blastocoel—no new structure formed, and the significance of the act is probably to be sought in the reduction of the cytoplasm relatively to the nucleus. Initially, the cytoplasm is too large, by cleavage it is reduced, and when a definite numerical nucleo-plasma ratio has been reached segmentation as such comes to an end and new events—of differentiation—begin.

But while cleavage is thus not a process of differentiation, it is yet true that the particular pattern adopted in cleavage—in our own case the radial pattern—is very definitely related to the initial structure of the ovum. That structure, as we have seen, is a polar one, with a radial symmetry about the axis, and the first three furrows are very definitely related to this axis,

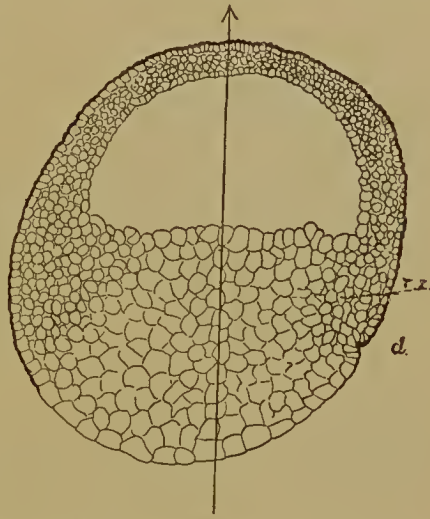


FIG. 48*. Sagittal section through the frog's egg at the beginning of the formation of the blastopore. *d.l.*, dorsal lip; *i.z.*, intermediate zone.

being successively meridional, meridional, and latitudinal. The direction taken by these and subsequent divisions may very probably be particular cases of the rules known by the names of Balfour and Hertwig.

According to Balfour's rule yolk impedes nuclear and cell-division, and that, as we have seen already, and shall see again when we deal with large-yolked eggs, is certainly the case in the Vertebrates. According to Hertwig's first rule the nucleus places itself in the centre of its sphere of activity, and this in a telolecithal egg is in the axis but excentrically, and nearer the animal than the vegetative pole. According to the second rule of

Hertwig, the dividing nucleus—or mitotic spindle—elongates in the direction of greatest protoplasmic mass (Fig. 49), or as Pflüger phrased it, the direction of least resistance, the resistance being offered by the yolk, and by the surface of the egg. Hence the first spindle has its equator in the axis in the animal portion of the egg, and elongates in a plane perpendicular to the axis, as the disposition of the yolk about the axis makes this a direction of least resistance; the resulting division is therefore meridional. Similarly in each of the first two blastomeres the greatest protoplasmic mass or least resistance is again in a plane perpendicular to the axis, and, in this plane, in a direction parallel to the first furrow. In this direction the spindle elongates, and once more the division is meridional, and at right angles to the first.

In the third phase, however, the greatest protoplasmic mass in each cell is in a direction parallel to the axis; at the same time, in each cell the nucleus lies in the protoplasmic portion, near the animal end: hence the latitudinal division. The direction of division in subsequent stages, as far as it can be followed, may be similarly explained.

Attention has already been called to the effect of the yolk on the rate of division and on the size of the cells.

We have still, however, to inquire into the cause which determines the particular meridian occupied by the first furrow out of the infinite number possible.

As we have seen, prior to segmentation the egg assumes a bilateral symmetry, owing to the formation of the grey crescent on the side opposite the entrance of the spermatozoon. The plane of the grey crescent or plane of symmetry of the egg is of course a meridional plane, and it might be imagined that it is this which determines the meridian to be occupied by the first furrow. But this is not so. There is no definite or necessary relation between the two. The first furrow may pass through the centre of the grey crescent (Fig. 47, A), or be oblique (Fig. 47, c), or at right angles to the plane in which it lies. The reason for this divergence of the plane of the first furrow from the plane of symmetry lies in the fact that the latter is determined by the first, the former by the second part of

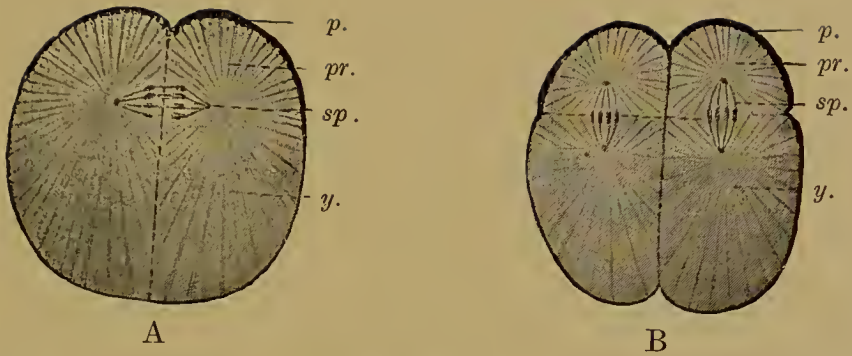


FIG. 49.—Diagram of the segmentation of the frog's egg. (After O. Hertwig, from Korschelt and Heider.) A, First (meridional), B, Third (latitudinal) phase of segmentation; *p.*, superficial pigment of animal hemisphere; *pr.*, protoplasm; *y.*, yolk; *sp.*, spindle.

the path taken by the spermatozoon in the egg, and that the two parts do not necessarily lie in the same meridional plane (Fig. 46).

The sperm enters the egg and immediately passes inwards; this is the first part of its path, and opposite this the grey crescent is formed. The sperm then turns to meet the female pronucleus,

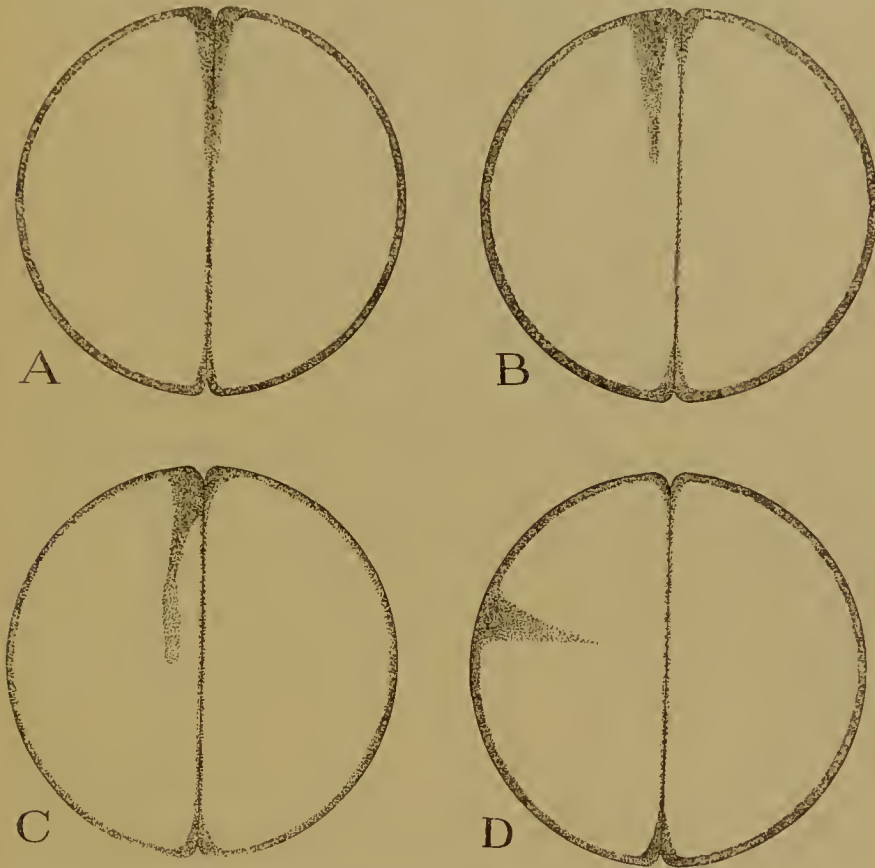


FIG. 50.—Diagrams illustrating the various relations between the first part of the sperm-path and the first furrow of segmentation. In A the furrow includes the sperm-path, in B it is parallel to it, in C it is slightly oblique to it, in D nearly at right angles. The furrow always includes or is parallel to the second part of the path (shown in C).

and this is the second part of its path. The centrosome divides at right angles to the meridional plane which includes the line of union of the pronuclei, the spindle is formed between the two centrosomes, and the division falls in the equator of the spindle, that is, in the second part of the path (Fig. 50). The two parts of the path may, but need not, lie in the same meridional plane;

hence the first furrow may, but need not, lie in the plane of the grey crescent.

While, therefore, as far as it is meridional, the direction of the first furrow is definitely related to the original polar egg-structure, the particular meridian it occupies is not so related to the bilateral structure imposed on the egg at the time of fertilization. That structure, on the other hand, as we are soon to see, is the actual forerunner of the bilateral symmetry of the embryo.

It is clear, then, that the factors which determine differentiation are distinct from those to which the pattern of segmentation is to be attributed. The former, for reasons which cannot be more fully set forth now, are to be looked for in certain cytoplasmic organ-forming substances, the latter in the relation between the nuclei, with their centrosomes, and the cytoplasm.

We may now turn to the cleavage of other Vertebrate eggs.

Petromyzon, *Ceratodus*, and the Urodelous Amphibia have small-yolked holoblastic ova. The course of segmentation is very similar to that in the frog, and, as a result, a similar blastula stage is reached with segmentation cavity in the animal hemisphere. In *Petromyzon*, however, the roof of the segmentation cavity consists of but one layer of cells. In *Ceratodus* the third furrows are stated to be meridional, the fourth and fifth latitudinal.

In the so-called Ganoid fishes *Lepidosteus*, *Amia*, *Acipenser*, as well as in *Lepidosiren* and in the Gymnophiona, the egg is intermediate between the small-yolked and large-yolked types. The additional amount of yolk exerts an influence upon the cleavage, and the vegetative portion of the egg is divided but slowly. Indeed, nuclear division here outruns cell-division, and at the end of segmentation there is produced a larger or smaller cap of small animal cells resting on an incompletely divided but multinucleate yolk-mass. The segmentation cavity is small (Fig. 51, B).

The direction of the furrows of the first few phases differs in the different cases, although the first two are always meridional and at right angles to one another. In *Acipenser* the third furrows

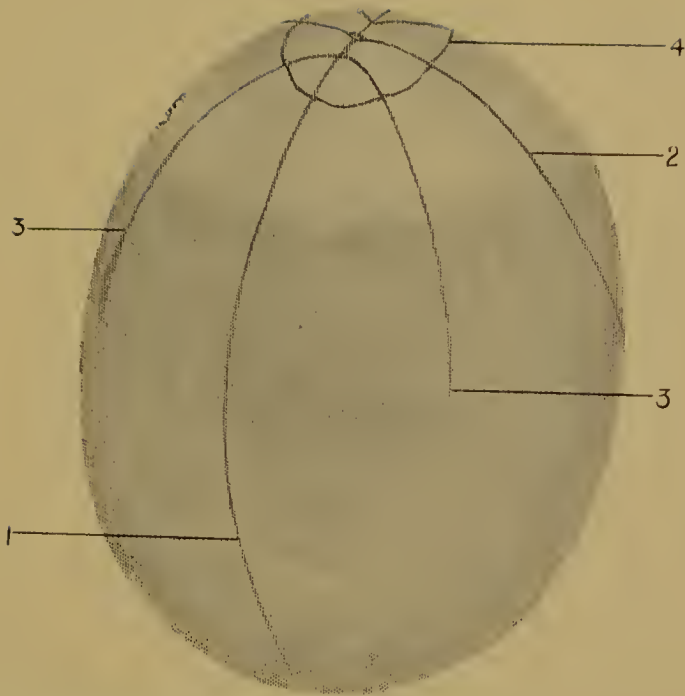


FIG. 51 A.—Segmenting egg of *Amia*. (After Whitman and Eycleshymer.)
 1, 2, 3, 4, successive divisions.

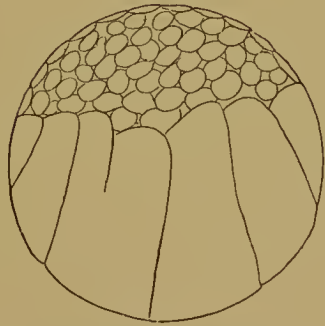


FIG. 51 B.—Fully segmented egg of *Amia*. (After Sobotta.)



A.



B.



C.

FIG. 52.—Surface views of segmentation of the blastodisc in Elasmobranchs. (After Rückert.)

A, 7-8-celled stage (*Torpedo*).

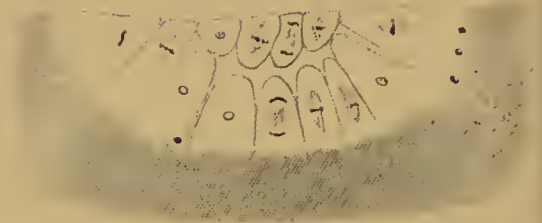
B, 8-16-celled stage (*Torpedo*).

C, Blastoderm (*Scyllium*).

In all the figures the upper is the anterior end. Note the larger cells at this end in c.



B.



C.




FIG. 53.—Sections through the segmenting blastodisc of Elasmobranchs. (After Rückert.) A, B, C, Successive stages A and B, *Torpedo*; c, *Pristiurus*. In c the left side is the anterior end. f, fine, c, coarse, yolk; m., merocytes.

are again meridional or parallel to the first, in *Lepidosteus* the furrows of the third phase are parallel to the first, those of the fourth phase parallel to the second (as in Teleostei). In *Amia* the third are meridional, the fourth latitudinal and quite close to the animal pole, the fifth tangential in the animal, meridional in the vegetative blastomeres (Fig. 51, A).

In the Myxinoids, Elasmobranchs, Teleostei, Reptiles, Birds, and Monotrematous Mammals the egg is very large-yolked and segmentation is meroblastic or partial—that is to say, is confined to the blastodisc or cap of cytoplasm which lies at the animal pole upon the voluminous yolk. As a result of segmentation the blastodisc is cut up into cells and becomes the blastoderm, resting upon an unsegmented yolk. The yolk may, however, contain nuclei, and these may continue to divide for a considerable time.

In all these cases the first two divisions are meridional and at right angles to one another. In Myxinoids the furrows of the third phase are again meridional. Cleavage then becomes irregular. When it is ended the blastoderm consists of a columnar upper layer, some lower layer rounded cells, and a third layer closely applied to the yolk. In the yolk are nuclei without cell-divisions. In Elasmobranchs (Figs. 52, 53) the third division is in some cases meridional, in others latitudinal, but so near the animal pole as to have the appearance of a circular furrow. Divisions perpendicular to the surface continue, and tangential divisions soon begin to occur.

At one end—the future anterior—of the blastoderm the marginal cells are distinctly larger than at the opposite end. The first furrow, however (Fig. 52, A), bears no definite relation to the antero-posterior axis.

The tangential divisions separate cells lying at the surface from cells which are still continuous with the yolk below. More tangential divisions increase the number of layers of cells, but the lowermost layer is always continuous with the yolk. In the same way at the margin of the blastoderm divisions perpendicular to the surface separate cells at the edge which are continuous with the yolk from cells inside. The marginal cells and the cells of the lowest layer feed upon the yolk, grow, divide

again, and so the whole blastoderm increases in diameter and in thickness.

Segmentation therefore leads to the formation of a many-layered blastoderm. The cells of the uppermost layer are arranged in a columnar epithelium. Those below are rounded elements, aggregated especially at the (future) anterior end; they are known as the lower layer cells, and between them and the yolk is a segmentation cavity, more spacious at the posterior end. In the yolk are numerous nuclei, some of which are derived from the fertilization nucleus, while others, as we have seen, are due to accessory spermatozoa (merocytes).

The nuclei in the yolk divide for some time by mitosis, but eventually abandon this method of multiplication. They enlarge, become highly and coarsely chromatic, irregular in shape, probably amoeboid, and divide amitotically. Their function is now to break up the yolk, possibly by some fermentative action, and render it suitable for absorption by the embryo. Eventually, when this duty has been performed, they disintegrate and disappear without participating in the development of any embryonic tissue.

In the Teleostei (Fig. 54) the second division is parallel to the first, the fourth parallel to the second. In the next phase the division is radial (with regard to the centre of the blastoderm) in the corner cells, parallel to the edge in the remaining marginal cells, and tangential in the four central cells. Further divisions result in the completed blastoderm, a compact discoidal mass of cells resting upon, but not continuous with, the yolk. The upper layer of the blastoderm is epithelial: in the lower layers the cells are polyhedral. The Teleostean segmentation is often described as 'discoidal'.

The detachment of the blastoderm from the yolk is effected at a fairly early stage, but not before a very important process has taken place, the separation of the yolk-nuclei. At a certain stage the marginal cells with their nuclei sink back into the periblast—or hyaline layer surrounding the yolk. Cell-divisions disappear and there is left a ring of nuclei round the margin of the rest of the blastoderm. The latter becomes now completely separated from the periblast around it and below it.

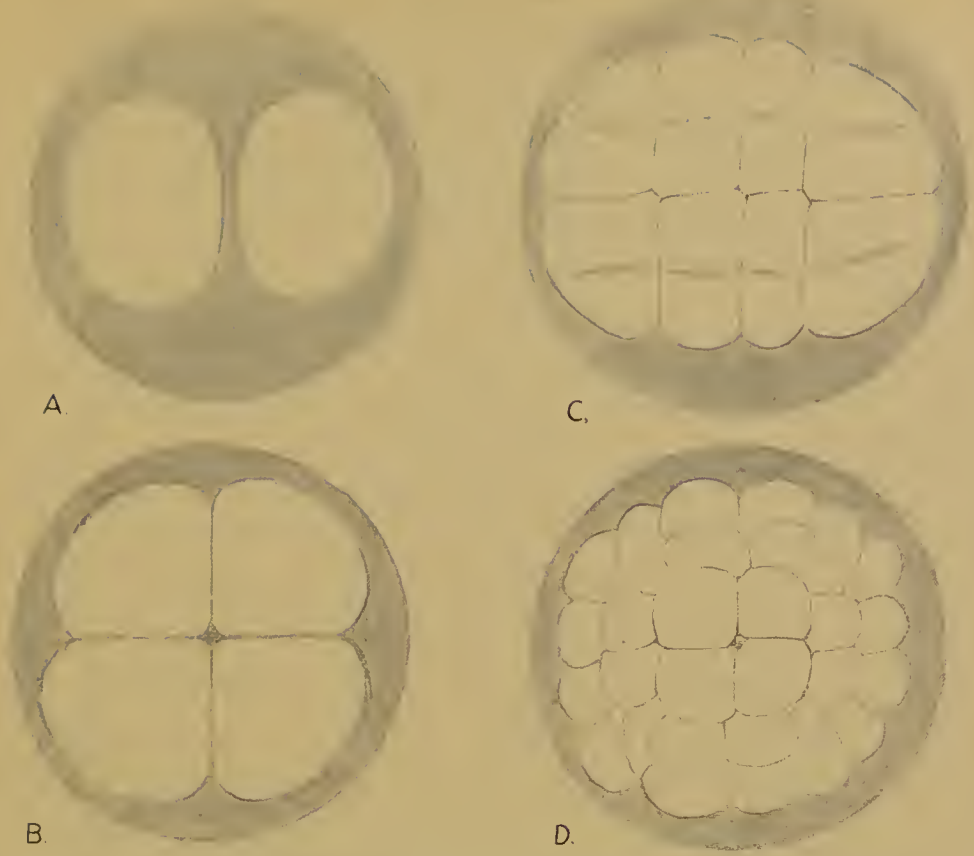


FIG. 54.—Segmentation of the egg of the plaice. A, 2 cells; B, 4 cells; C, The third division, parallel to the first (all the figures are so placed that the first division runs up and down the page), is completed, the furrows of the fourth phase are appearing; D, Fifth division.

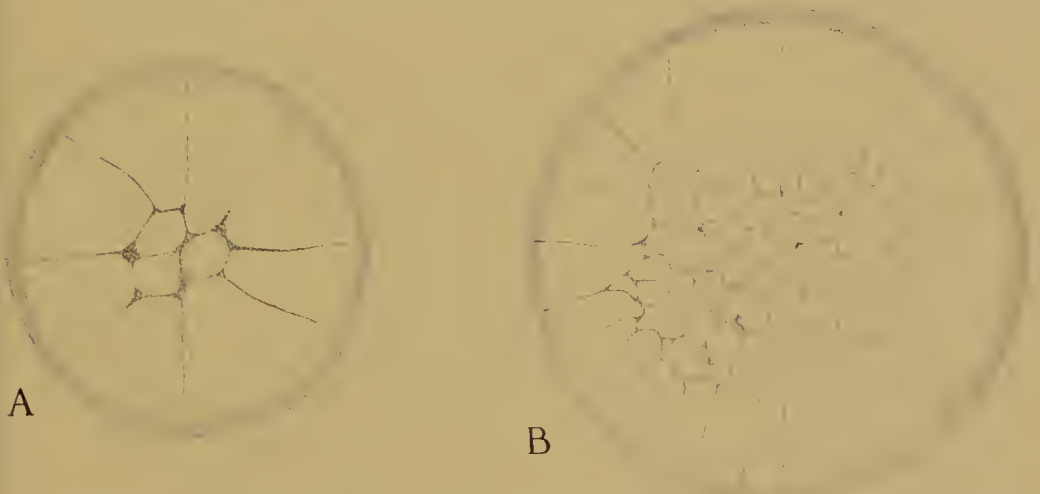


FIG. 55.—Two stages in the segmentation of the hen's egg (from oviducal eggs).

A, Three meridional divisions have occurred; the fourth (latitudinal) is in progress.

B, Later stage: the marginal cells are larger at the anterior end (upper side of the figure), and the centre of the small-celled area is towards the posterior end.

The yolk-nuclei then migrate into the layer of periblast underneath the blastoderm. There they cease to divide mitotically, swell up, become vacuolated, irregular, and very chromatic. As in the Elasmobranchs they are concerned with the liquefaction and elaboration of the yolk, and eventually disintegrate and disappear (Fig. 54*).

In some cases (Salmonidae and others) the periblast or yolk-nuclei are formed not only at the margin but also at the under surface of the blastoderm.

In the Reptiles and Birds (Fig. 55) segmentation quickly becomes irregular after the first two or three meridional divisions. Tangential divisions soon occur, and a blastoderm is

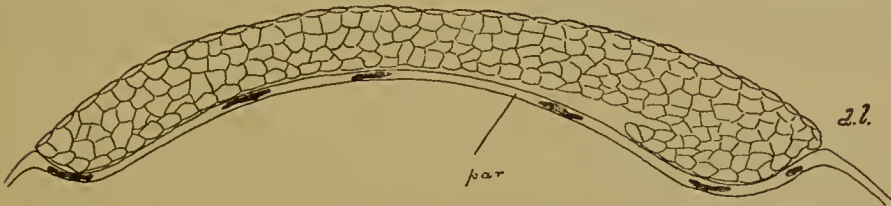


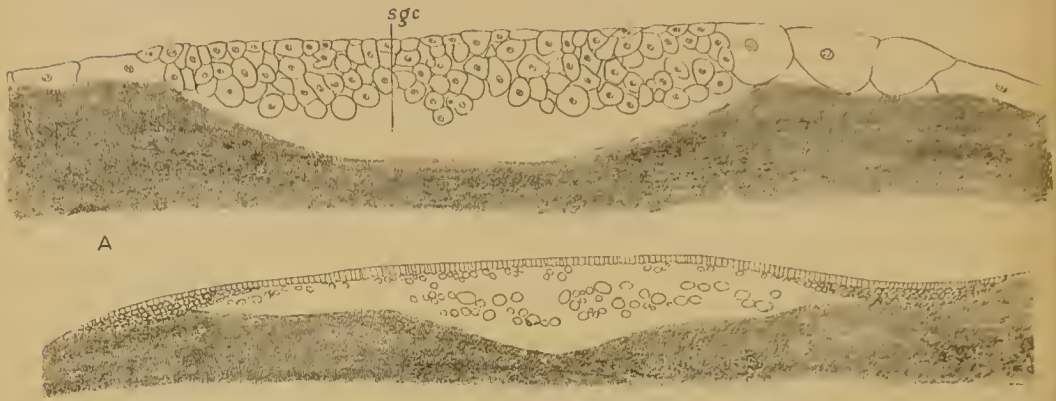FIG. 54*.—Sagittal section through the blastoderm of *Serranus* during the formation of the germinal layers (after Wilson); showing beginning of overgrowth at dorsal lip (*d.l.*). *par.* parablast (periblast).

formed composed of two layers only, an upper and a lower. In the hen's egg the cells at what will be the anterior end of the blastoderm are larger than at the posterior end. At the margin the two layers are united with one another and continuous with the yolk, as in other cases (Fig. 56). In Reptiles, though not so easily in Birds, there may be distinguished in the upper layer two regions, an oval area in the centre composed of columnar cells (this is the embryonic shield), and a surrounding extra-embryonic area of flattened cells. The lower layer consists of scattered rounded cells, many of which are, in the Reptiles, still continuous with the subjacent yolk. The lower layer cells unite together finally to form a flat epithelium, the lower layer or paraderm (Fig. 57) (endoderm of most authors, but the term should be avoided at this stage).

In the Reptiles the upper and lower layers remain continuous at one point up to the time when the germ layers begin to be formed. This point is at what will be the hinder margin of the

embryonic shield, and is known as the primitive plate. It is here that the blastopore will be formed (see Fig. 83).

In the Monotremata amongst the Mammals segmentation is also meroblastic, and it is known that the first two



A

B

FIG. 56.—A, Longitudinal section through the segmented blastoderm of the hen's egg; *s.g.c.*, subgerminal cavity. The anterior end with the larger cells is on the right.

B, Section through the blastoderm of the unincubated hen's egg. In the centre of the blastoderm the lower layer cells lie scattered in the subgerminal cavity; at the edges the lower layer cells are closely packed and rest on the yolk.

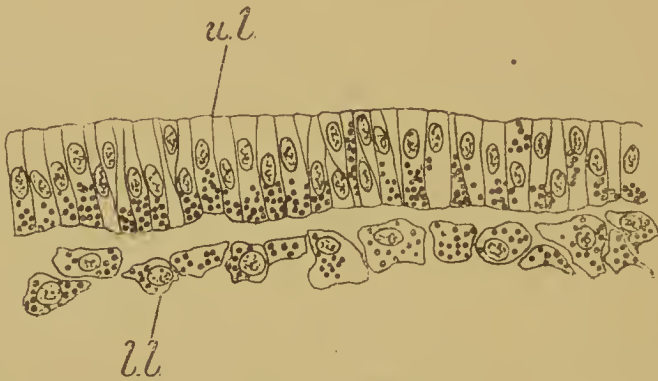


FIG. 57.—Part of a section of the blastoderm of the chick after six hours' incubation. *u.l.*, upper layer; *l.l.*, lower layer.

furrows are meridional, the third parallel to the first and at right angles to the second. At the end of segmentation there are two layers.

In all these Amniota the blastoderm originates by cleavage in precisely the same way as in the large-yolked eggs amongst

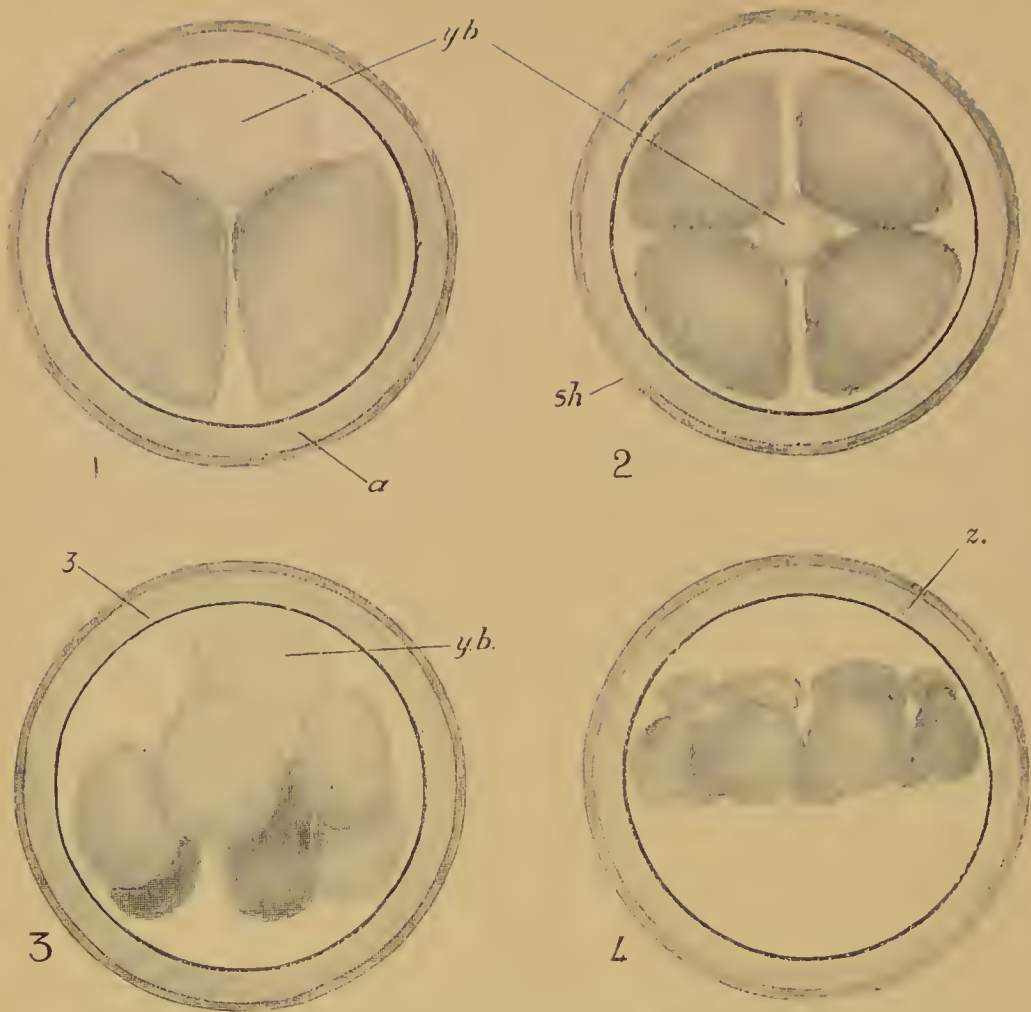


FIG. 58.—Segmentation of the ovum of the Marsupial *Dasyurus*. (After Hill.) 1, 2 cells; 2, 4 cells; 3, 6 cells; 4, 16 cells. *sh.*, shell; *a.*, albumen; *z.*, zona pellucida; *y.b.*, yolk-body.

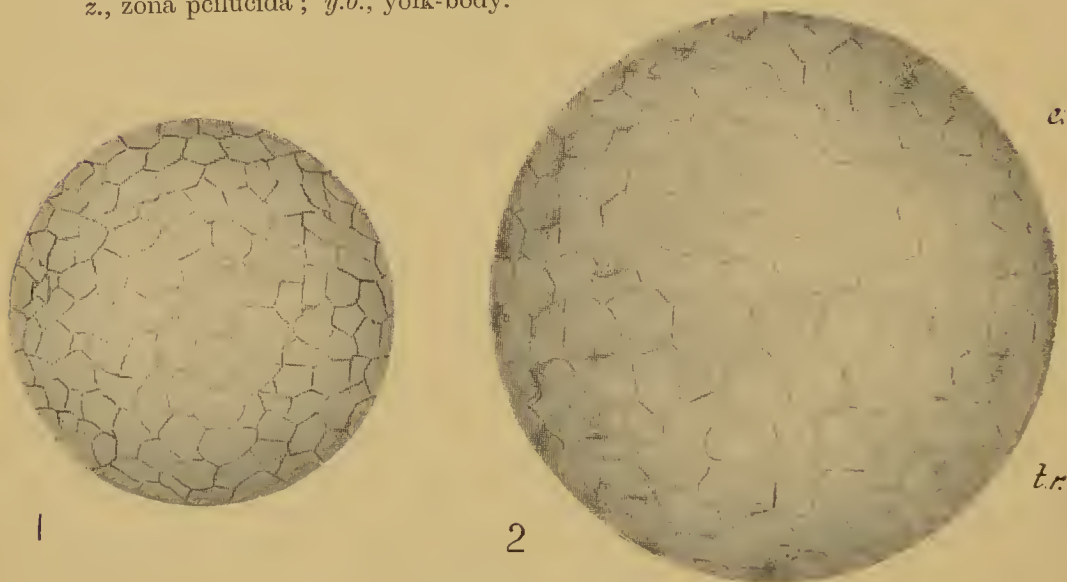
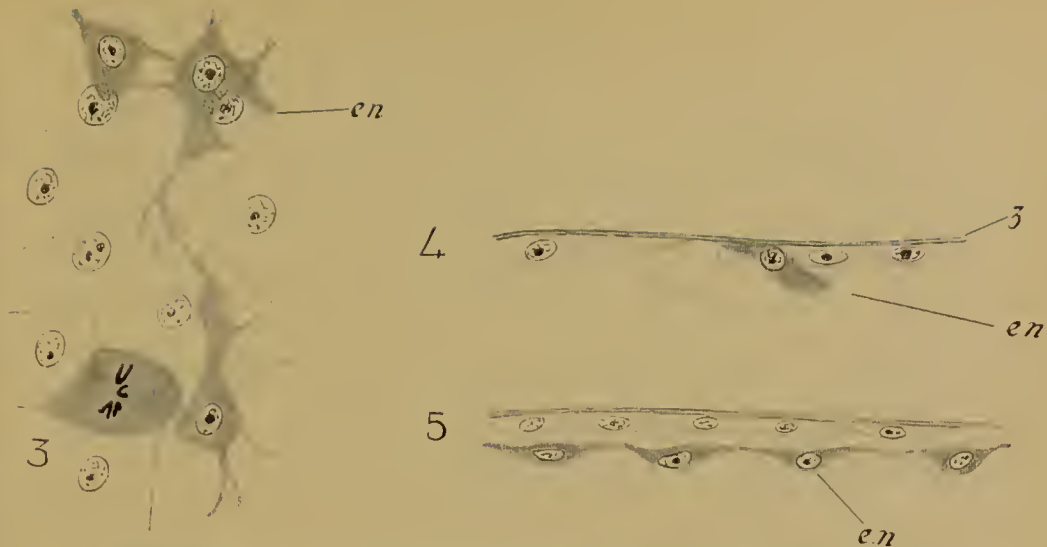


FIG. 59.—Formation of the blastocyst in *Dasyurus*. (After Hill.)
 1, Blastocyst in which all the cells are alike.
 2, Older blastocyst, one half (*e.*) of which is the embryonic, the other (*tr.*) the trophoblastic area.



3, Formation of the endoderm (*en.*) by immigration of amocoid cells of the embryonic area ; seen from the inner surface.
 4, 5, The same in transverse section.

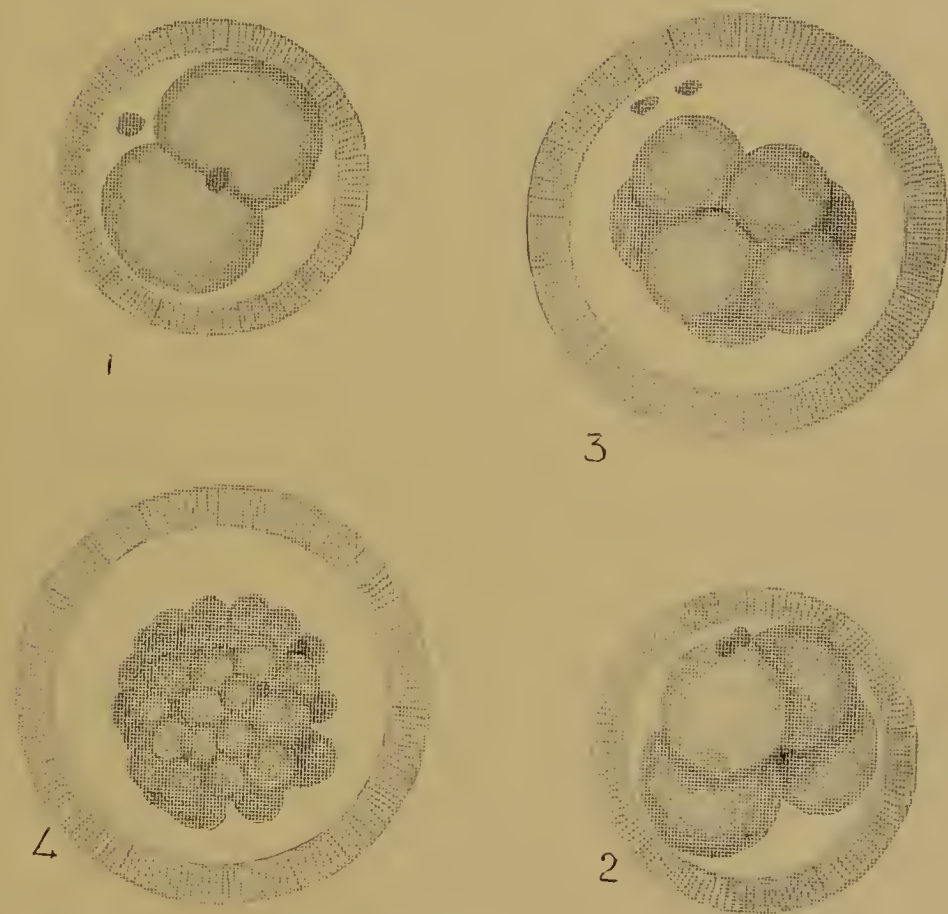

FIG. 60.—Segmentation of the ovum of the rabbit. (After Assheton.)
 1, 2 cells ; 2, 4 cells ; 3, 8 cells ; 4, 'morula' stage.

the Anamnia. In the next stage of development, however, their behaviour is different, for in the latter group the blastopore is formed at the edge of the blastoderm, while in the others it always arises inside the blastoderm at the edge of the embryonic shield, so that it is the latter structure which in its future conduct is comparable to the Anamniian blastoderm.

In the Amniota the growth of the blastoderm over the yolk goes on independently of the development of the blastopore and of the embryo; only at a comparatively late period is the yolk finally enclosed at the vegetative pole. In the Monotremata, however, this enclosure is effected with great rapidity, and as the edges meet there is produced a spot where yolk, upper layer, and lower layer are all continuous with one another. This (accepting Assheton's interpretation) is the proper explanation of what Wilson and Hill have identified erroneously with the primitive plate of Reptiles (see Fig. 92).

In the remaining Mammalia the egg, as we have seen, is small by loss of yolk, and its cleavage is holoblastic.

In the Marsupial *Dasyurus* (Fig. 58) a curious phenomenon occurs before cleavage, the extrusion of the yolk-body at the vegetative pole. The first two divisions are meridional and at right angles to one another, the third again meridional. The eight cells lying in a ring round the centre of the zona pellucida now divide unequally, the smaller cells lying on that side on which the yolk-body is situate. Further divisions, perpendicular to the surface of the zona pellucida, lead to the formation of a hollow sphere, the blastocyst, in which two regions become later distinguishable (Fig. 59, 1, 2). In one hemisphere the cells are small, in the other large. The former is the embryonic and derived (according to Hill) from the small cells of the sixteen-celled stage, and therefore from the vegetative hemisphere, since it is on this side that the yolk-body was extruded. The latter hemisphere is the trophoblastic, and derived from the larger cells (of the animal region of the egg) in the sixteen-celled stage. In the embryonic hemisphere individual cells become amoeboid, migrate below the surface, and there unite to form a lower layer or 'endoderm' (Fig. 59, 3-5), which presently grows round the inside of the blastocyst and forms a completely closed sac,

the yolk-sac or umbilical vesicle. The remaining cells of the embryonic hemisphere become cubical or columnar, and are thus sharply marked off from the flat elements of the trophoblast.

In the Placental Mammals the first division is meridional (Fig. 60). After this segmentation is irregular, and results in a spherical mass of cells, in which an outer layer of cubical soon becomes differentiated from an inner mass of rounded elements. By the absorption of fluid a cavity is then formed

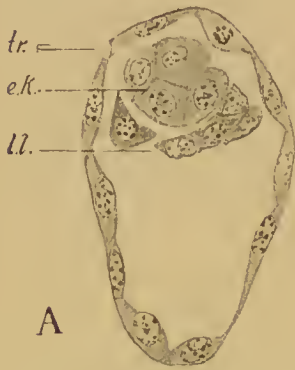

FIG. 60*.—Blastocyst of the mouse. The inner mass has been differentiated into embryonic knob (*e.k.*) and lower layer (*l.l.*). *tr.*, trophoblast.

between these two groups of cells except at one point, the future embryonic pole, where the inner mass remains adherent to the outer layer. Thus the blastocyst stage is reached. The cells of the outer layer or trophoblast (which will give rise to the ectoderm of the false amnion) now become flattened, while the inner mass is differentiated into a round embryonic knob of closely packed cells (this contains the material for the embryo and the ectoderm of the true amnion) and a lower layer of flattened cells (Fig. 60*). The latter quickly grow round the inside of the trophoblast and form the closed yolk-sac. Rarely (in the guinea-pig) the distal, lower or anti-embryonic wall of the yolk-sac is never developed. The lower layer gives rise to the gut, the yolk-sac epithelium, and the allantois.

At the stage we have reached, therefore, the material for the embryo, true amnion, yolk-sac, and allantois is shut up in a completely closed sac, the trophoblast or false amnion. All Placental Mammals pass through such a stage, however the amnion may ultimately be formed, and in this respect differ strikingly from the Marsupials, where the embryonic area is at the surface of the blastocyst, and the trophoblast confined to one hemisphere of the latter.

It will be noticed that in the Placental Mammals it is not possible to state what relation exists, if any, between the axis

of the blastocyst—the line drawn from embryonic to anti-embryonic pole—and the original axis of the ovum. In the Marsupials, if Hill's interpretation is correct, these axes coincide, but the vegetative becomes the embryonic pole.

LITERATURE

R. ASSHETON. A re-investigation into the early stages of the development of the rabbit. *Quart. Journ. Micr. Sci.* xxxvii, 1894.

R. ASSHETON. The segmentation of the ovum of the sheep. *Quart. Journ. Micr. Sci.* xli, 1898.

R. ASSHETON. The development of the pig during the first ten days. *Quart. Journ. Micr. Sci.* xli, 1898.

E. VAN BENEDEN. Recherches sur l'embryologie du lapin. *Arch. de Biol.* i, 1880.

W. HEAPE. The development of the mole. *Quart. Journ. Micr. Sci.* xxvi, 1886.

O. HERTWIG. Die Zelle und die Gewebe. Jena, 1893.

J. P. HILL. The early development of the Marsupialia, with special reference to the native cat (*Dasyurus viverrimus*). *Quart. Journ. Micr. Sci.* lvi, 1910.

F. R. LILLIE. The development of the chick. New York, 1908.

W. ROUX. Ueber die Zeit der Bestimmung der Hauptrichtungen des Froschembryo. *Ges. Abh.* xvi, Leipzig, 1883.

J. RÜCKERT. Die erste Entwicklung des Eies der Elasmobranchier. *Festschr. f. C. von Kupffer*, Jena, 1899.

R. SEMON. Die Furchung und Entwicklung der Keimblätter bei *Ceratodus forsteri*. *Zool. Forschungsreise in Australien*, 1901.

R. SEMON. Zur Entwicklungsgeschichte der Monotremen. *Zool. Forschungsreise in Australien*, ii, 1, 1894.

L. WILL. Beiträge zur Entwicklungsgeschichte der Reptilien. *Zool. Jahrb.* vi, 1893.

CHAPTER VI

THE GERMINAL LAYERS

By the germ-layers we understand certain groups of cells which contain in themselves the materials for certain definite groups of organs and tissues. These groups of cells are definitely separated from one another at an early period of development, and the process of their separation is spoken of as the formation of the germinal layers.

The germinal layers in a Vertebrate are three in number, the ectoderm, the endoderm, and the mesoderm. The ectoderm is that group of cells which contains within itself the material for the formation of the epidermis and epidermal derivatives like hair, feather, skin-glands, the enamel of the teeth, the nervous system both central and peripheral, and the sense organs, and further the stomodaeum and proctodaeum, or entrances to the mouth and anus; the endoderm contains the material for the lining epithelium of the alimentary canal and its outgrowths, such as gill-slits, thyroid, thymus, lungs, liver, pancreas, bladder; while from the mesoderm—with which we include the notochord—skeleton and connective tissues, muscles, blood and vascular system, coelom and urogenital organs will be derived.

The germ-layers are thus definable by their fate in development. They may also be defined with reference to their position in the embryonic body when they have been definitely segregated from one another, for then the ectoderm is the outside layer, the endoderm the inside layer, while the mesoderm with the notochord is in between. Prior to that moment, however, it is difficult, if not impossible, to give generally valid definitions of these sets of cells by their position, since the method of their origin from the different cells into which the substance of the ovum is divided by cleavage varies in the several groups.

In a Vertebrate the germinal layers are segregated during a process which is known as the formation and closure of the

blastopore, or in an older terminology 'gastrulation', the 'gastrula' being the name bestowed on this stage in which a new cavity, the 'archenteron' or primitive gut, is formed and is in communication with the exterior by an aperture, the blastopore.

This opening, and with it the germinal layers, is from the first bilaterally symmetrical. This is true of all Vertebrates, but in the method of its origin the phylum must be divided into two great groups, those in which the blastopore arises at the edge of the blastoderm—the Anamnia—and those in which it appears inside the blastoderm—the Amniota. By the help of the Gymnophiona, however, the gap between the two may be bridged.

ANAMNIA

We shall begin with the Anamnia, in which the conditions are much simpler.

As a type we shall take the common English frog (*Rana temporaria*).

The first sign of the formation of the germ-layers is given as soon as segmentation is at an end by the appearance of the structure known as the dorsal lip of the blastopore (Fig. 61). This is a short, deeply-pigmented rim bounding a groove, placed parallel to the equator, and a little below it (about 25°) at that point in the boundary between the pigmented and unpigmented regions of the egg where the latter area is most extensive. This is the side on which the grey crescent was formed and the original unpigmented area so increased. The plane which includes the egg-axis and the dorsal lip will shortly become the median longitudinal or sagittal plane of the embryo; it coincides evidently with the plane of symmetry of the unsegmented ovum.

The egg is still in the position into which it turned at the time of insemination with its axis vertical, and the heavy white pole below. The changes that now take place as seen from this vegetative pole are as follows. The rim of the groove begins to travel downwards over the surface of the egg towards the vegetative pole, the area over which it passes becoming covered by cells which are as deeply pigmented as those of the animal portion of the egg. At the same time the rim elongates, becoming crescentic; in other words, the processes of rim formation and

overgrowth are extended to the right and left along the margin of the pigmented area, and the lateral lips of the blastopore come

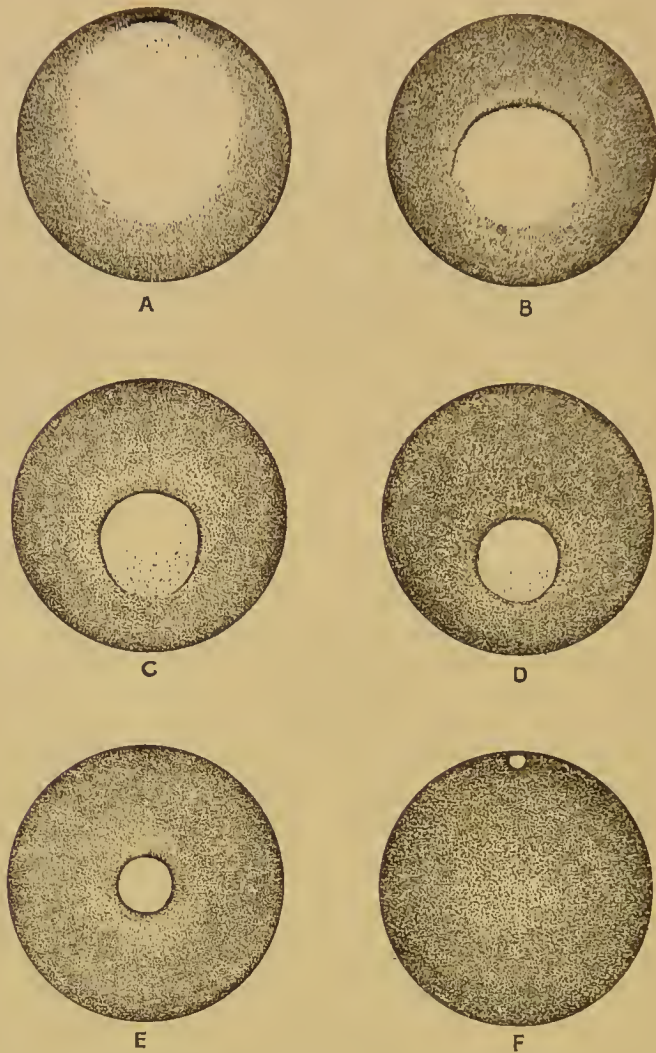


FIG. 61.—Diagrams of the closure of the blastopore in the egg of the common frog (*R. temporaria*). In A-D the egg is viewed from the vegetative pole, in E, F from below. The dorsal lip is at the top of the figures. In D the ventral lip has just been formed and the blastopore is circular. In E the rotation of the whole egg has begun, and in F is complete.

into being. As the dorsal lip (the middle region of the rim) continues on its course towards the vegetative pole, and as continually fresh parts are drawn into the process at the sides, the blastopore lip becomes first semicircular, and then three

parts of a circle, until finally, when that part which is diametrically opposite to the dorsal lip, namely the ventral lip, also begins to grow down, it attains the form of a circle enclosing the still uncovered portion of the vegetative hemisphere, the yolk-plug. The dorsal lip has now moved down to or a little beyond the vegetative pole.

At this moment the whole egg begins to rotate about a horizontal axis in the opposite direction to that in which the dorsal lip moved ; and this rotation continues—the circle of the blastopore becoming smaller all the time—until the dorsal lip has returned, rather beyond the point from which it started, to the new equator, or horizontal plane through the centre of the egg. The end now occupied by the blastopore is posterior. The angle subtended by the arc traversed by the dorsal lip—both before and during the rotation—is 75° , and the angle through which the whole egg rotates is 100° . It follows that the vertical line now drawn through the centre of the egg, which will be the dorso-ventral line of the embryo, makes the same angle of 100° with the original egg-axis ; that the animal pole is situated below what will be the anterior end of the embryo (Fig. 62, F), since the blastopore is posterior ; and that the antero-ventral half of the embryo is developed over the animal, the postero-dorsal half over the vegetative hemisphere of the egg. The dorsal and ventral lips are now actually dorsal and ventral.

It is clear that the lip of the blastopore which is thus formed and closed arises along the whole of the boundary between small pigmented and large yolk-cells, and that the process is bilateral, taking place, as it does, first and most rapidly at the dorsal lip, last and least rapidly at the ventral lip, and at an intermediate rate at the lateral lips in between.

The examination of sections (Fig. 62) will now show us that the closure involves (1) a movement of the yolk-cells into the segmentation cavity together with (2) an overgrowth and ingrowth of cells at the blastoporic lip, resulting in the formation of a new cavity, the ' archenteron ' ; and that during the process the material for the germinal layers is brought into position and laid down.

A sagittal section of the egg passing through the dorsal lip

at its first appearance shows the groove placed about 25° below the equator in the zone of intermediate cells. The radial disposition of the cells immediately about the groove marks the beginning of a process of overgrowth and ingrowth which becomes more obvious a little later, when it is seen that a fold of small cells has grown over a certain area of yolk-cells. This fold consists naturally of two sheets, an outer and an inner. The cells of the outer sheet resemble closely the small pigmented cells of the animal hemisphere into which they are uninterruptedly continued; like the latter, they are arranged in about four layers, the outermost of which is epithelial. At the lip of the blastopore the outer passes into the inner sheet, the cells in the outermost layer of the former being gradually turned over into the innermost layer of the latter. This inner sheet also consists of several layers of cells, the innermost of which is pigmented and epithelial, the remainder being more irregularly disposed. The inner sheet forms the outer, or, as it will be when the egg has rotated, the upper wall of the slit-like cavity between itself and the yolk-surface now covered up. This cavity is the archenteron and the inner sheet of the fold is its roof; the original vegetative surface of the egg forms its floor.

This overgrowth and ingrowth of cells, with consequent formation of an archenteric cavity, takes place in an exactly similar fashion at the lateral (Fig. 63, A) and ventral lips. By the time the latter has appeared the archenteric cavity is much enlarged, first by its being extended in an anterior direction into the yolk-cells that have meanwhile been pushed up into the segmentation cavity on the dorsal side, and secondly in a lateral and finally a ventral direction by a movement of the mass of yolk-cells towards these regions of the egg also. The segmentation cavity is thus first reduced to a small space upon the ventral side and then obliterated altogether. In a small percentage of cases, however, the segmentation cavity communicates with the front end of the archenteron, is surrounded by yolk-cells, and incorporated in the front end of the gut.

It is the shifting of the heavy yolk-cells to the ventral side that alters the centre of gravity and so causes the rotation of the egg until equilibrium is regained.

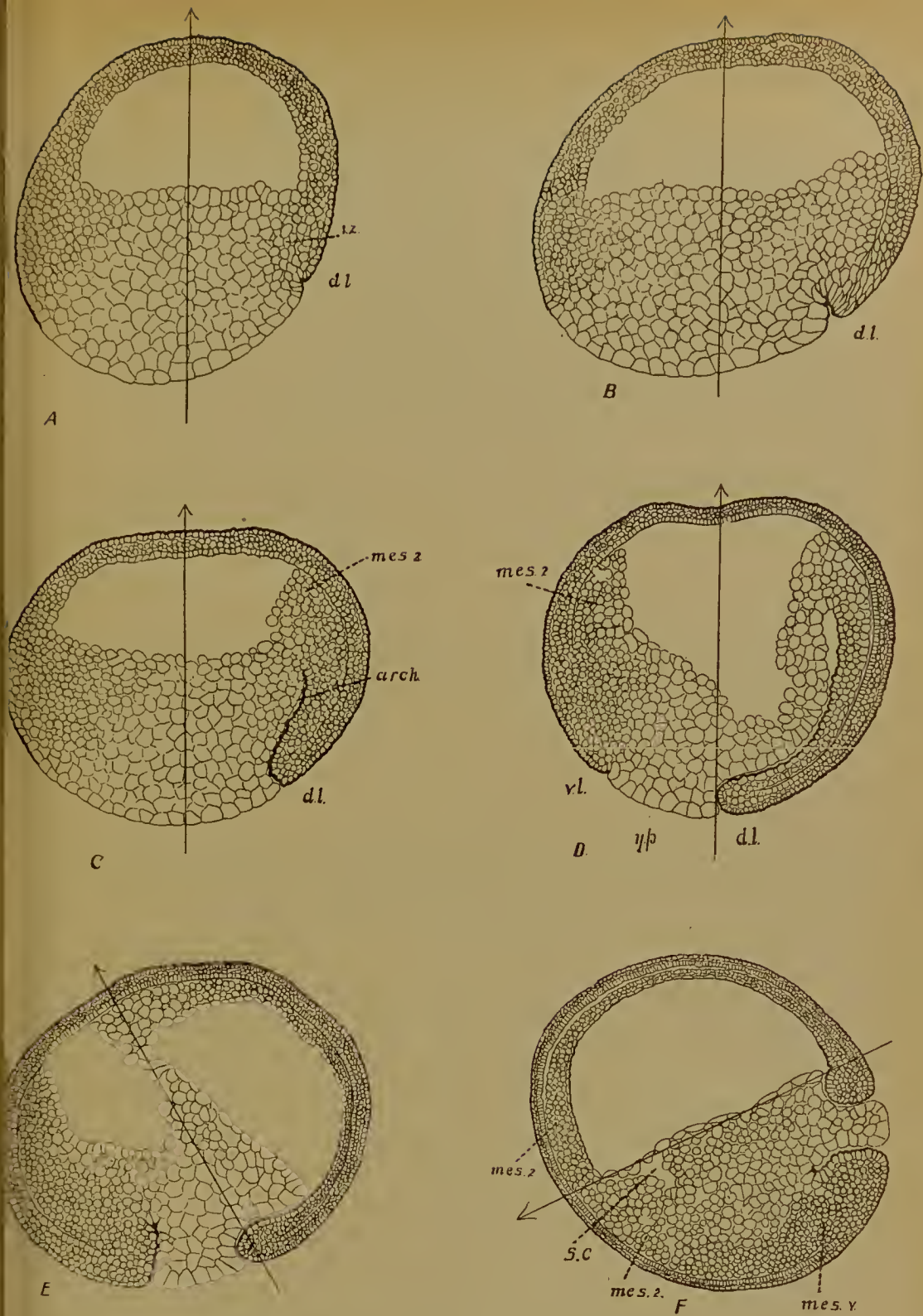


FIG. 62.—Sagittal sections through the frog's egg during the formation and closure of the blastopore. A-D, Before rotation; E, During rotation; F, After rotation.

The arrow marks the egg-axis, its head the animal pole. *d.l.*, dorsal lip; *v.l.*, ventral lip of the blastopore; *s.c.*, segmentation cavity; *arch.*, archenteron; *y.p.*, yolk-plug; *i.z.*, intermediate zone: *mes.v.*, mesoderm formed below the ventral lip; *mes.2*, mesoderm formed from the yolk-cells pushed into the segmentation cavity.

With the exception of the yolk-plug the outer surface of the egg is now covered by a sheet of small cells, disposed in about four layers, the outermost of which is epithelial and pigmented. This sheet is the ectoderm. In part it comes from the original animal cells which formed the roof of the segmentation cavity; but part of it is derived from the outer sheet of the blastopore fold.

The notochord and the dorsal mesoderm are differentiated out of the roof of the archenteron (Figs. 63 B, 64). The latter sheet of cells becomes split into (1) a thin layer next the cavity (this

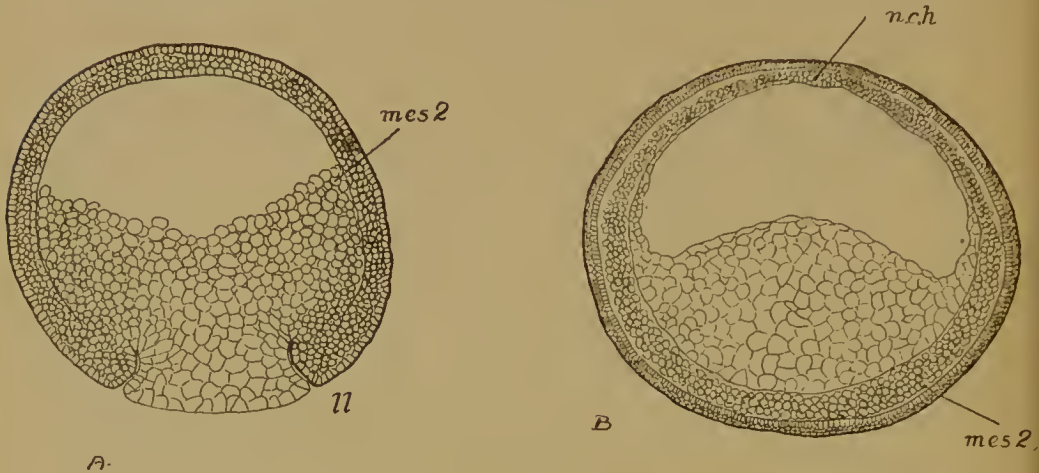


FIG. 63.—Transverse sections of the frog's egg. A, During the closure of the blastopore; B, After. *mes. 2*, mesoderm differentiated from the yolk-cells pushed into the segmentation cavity (in B these are seen to be ventral); *ll.*, lateral lip of the blastopore; *n.ch.*, notochord.

will be the roof of the alimentary canal) and (2) a layer next the outside. This outer layer is divided into (a) a median strip or rod, which is the notochord, and (b) two lateral sheets, the dorsal mesoderm. The notochord is not separated until after the sheets of mesoderm have been detached. The separation of both notochord and mesoderm begins at the anterior end and proceeds backwards. At the lip of the blastopore there is thus for a time an undifferentiated mass of tissue in which ectoderm, notochord, mesoderm, and roof of the alimentary canal are all continuous (Fig. 62, E). It will be remembered that the front end of the archenteron arises by an extension of that cavity into the yolk-cells; here, therefore, yolk-cells form the roof, and it is from them that the anterior portions of notochord and

dorsal mesoderm are formed. The posterior portions, however, arise in that part of the archenteric roof which comes into position as the inner sheet of the blastoporic fold.

The ventral mesoderm (Fig. 63, B) has a similar double origin. In front the floor of the archenteron is formed of the yolk-cells pushed into the segmentation cavity; the cells next the ecto-

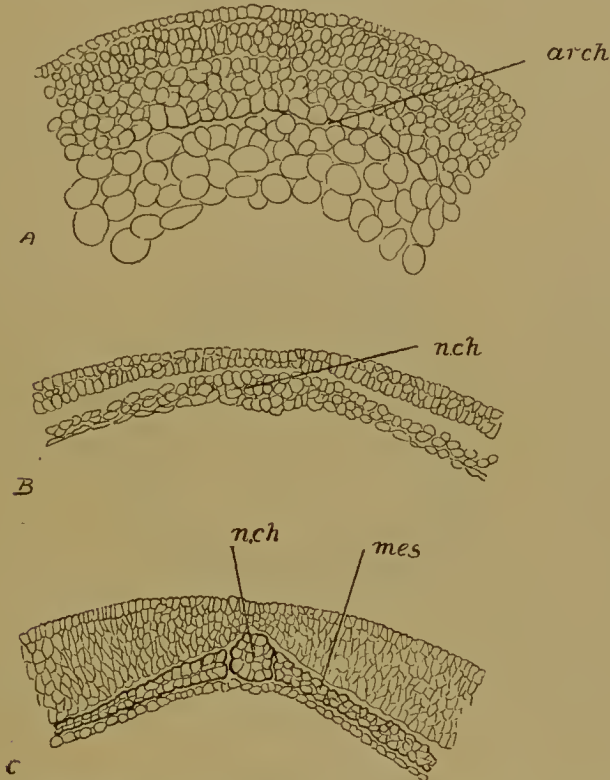


FIG. 64.—Three stages in the differentiation of the roof of the archenteron in the frog. *arch*, archenteron; *n.ch.*, notochord; *mes.*, dorsal mesoderm.

derm subdivide and become mesoderm. Behind mesoderm arises from the inner sheet of the fold at the ventral lip. At the sides of the embryo dorsal and ventral mesoderm pass continually into one another. The middle layer, therefore, taken as a whole, arises anteriorly and ventrally from the yolk-cells, posteriorly and dorsally from the blastoporic overgrowth; the former is in the original animal, the latter in the original vegetative hemisphere.

Since mesoderm is formed also at the lateral lips, the two sheets of this tissue which flank the notochord are necessarily

continuous, around the blastopore (Fig. 64*), with the mesoderm at the ventral lip (Fig. 62, *e*); only at the dorsal lip, where the notochord is formed, is there an interruption in the middle layer. The endoderm or lining of the gut cavity is what is left of the roof and floor of the archenteron, the roof of the gut being the thin layer left when the notochord and mesoderm have been detached, the floor the bulky mass of yolk-cells after the separation of the ventral mesoderm.

It must be remembered that though the differentiation of these germ-layers is only completed when the blastopore has closed, it has in reality been in progress during the earlier stages.

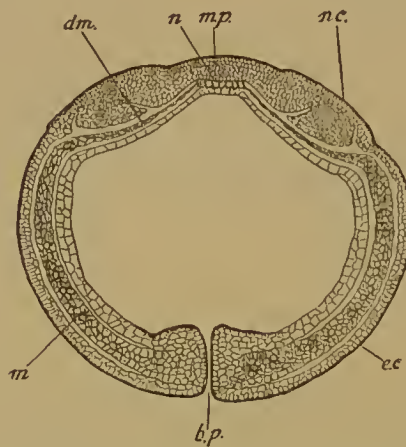


FIG. 64*.—Horizontal section of an older stage showing the sheets of mesoderm passing back into the lateral lips of the blastopore (*b.p.*).

It still remains for us to discuss very briefly the origin of the cells from which the blastoporic fold is derived, that is, the origin of parts of each of the three germ-layers. The inner layer of the fold is certainly derived neither wholly from the small cells of the animal hemisphere, nor wholly from the large cells of the vegetative hemisphere, but from the region about the egg-equator, in which the cells are of a character intermediate between these two (Fig. 62, *i, z.*). The outer layer of the fold comes from the same source, and from an extension of the roof of the segmentation cavity. These intermediate cells divide rapidly and give rise to the fold, which, as we have seen, contains ectodermal, endodermal, and mesodermal elements.

To sum up, the ectoderm of the frog comes partly from the cells of the animal hemisphere, partly from the intermediate cells; the endoderm in part from the latter, in part from the yolk-cells, while the mesoderm and notochord have a similar double origin; and the materials for these layers are brought into their definitive positions during the bilateral closure of the blastopore, which arises all along the line separating animal from vegetative cells.

We shall see that a similar statement may be made for the remaining Anamnia.

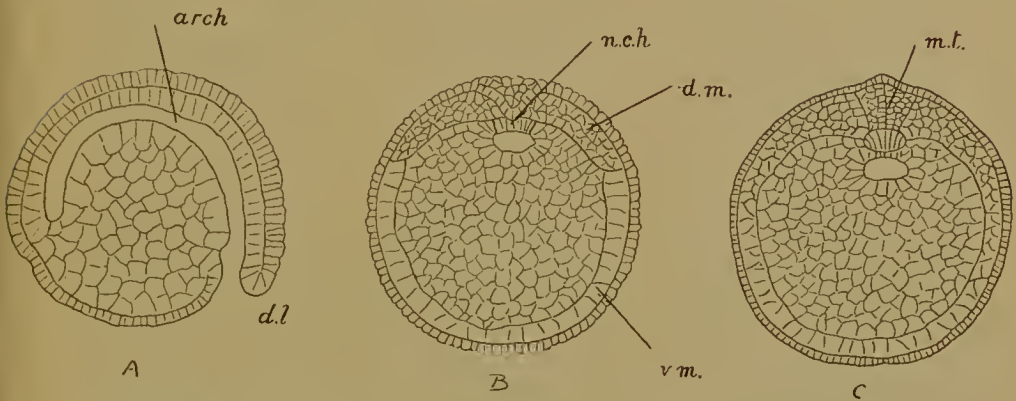


FIG. 65.—Formation of the germ-layers in *Petromyzon*. (After Scott.) A, Sagittal section; B, C, Transverse sections of two stages; *arch.*, archenteron; *d.l.*, dorsal lip of the blastopore; *n.ch.*, notochord; *d.m.*, dorsal mesoderm; *v.m.*, ventral mesoderm; *m.t.*, medullary tube (here a solid wedge of cells).

CYCLOSTOMATA

In *Petromyzon* (Fig. 65) the formation and closure of the blastopore, the origin and extension of the archenteron, resemble the same processes in the frog, with the exception that a ventral lip is never developed. The ventral mesoderm is differentiated from the yolk-cells pushed into the segmentation cavity, as in the frog, and these latter cells form the floor of the gut. They give rise, however, to much more than that, since the roof of the archenteron is converted wholly into the notochord and the gut is then completed by the upgrowth of yolk-cells from the sides and underneath the notochord. The dorsal mesoderm arises in connexion with the overgrowth at the lip of the blastopore.

In the Myxinoids (Fig. 66) segmentation produces a blastoderm at one end of the ellipsoid egg. At one point in the edge of this blastoderm a dorsal blastoporic lip appears, and the material for the germ-layers of the embryo is laid down during the bilateral overgrowth and ingrowth of cells in this region. The yolk is not wholly covered by this process, but as soon as

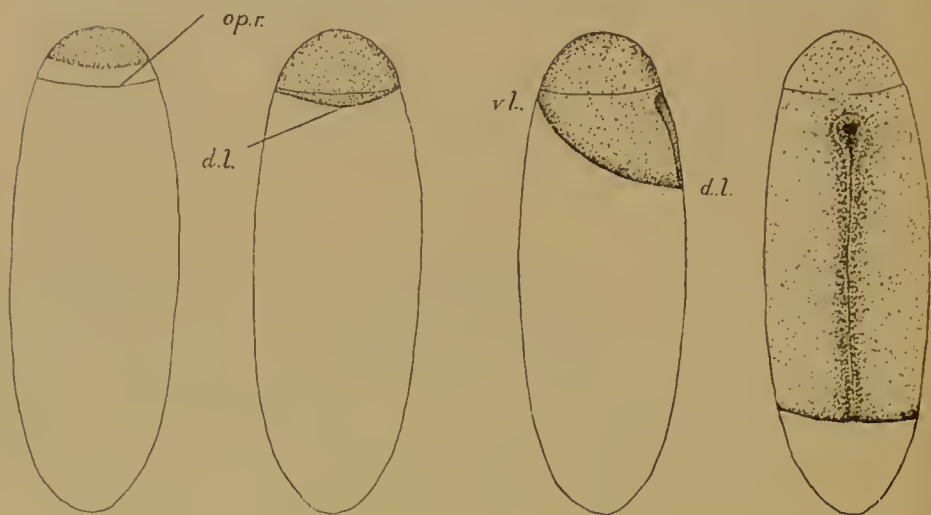


FIG. 66.—*Bdellostoma*. Overgrowth of the posterior edge or dorsal lip of the blastoderm over the yolk. *d.l.*, dorsal lip (posterior edge); *v.l.*, ventral lip (anterior edge); *op.r.*, opereulum of the shell. (After Bashford Dean.)

the body of the embryo is formed all parts of the edge of the blastoderm grow down and the blastopore eventually closes at the vegetative pole.

ELASMOBRANCHII

Germ-layer formation begins with the appearance at one point in the edge of the blastoderm of a fold or overturning of cells of the superficial layer. This point is, as will appear, in the middle line and at the posterior end. The fold, the rim of which is the dorsal lip of the blastopore, is slightly raised and covers over a space—the beginning of the archenteron—between itself and the yolk (Figs. 67, 68). By the continued backward growth of the fold and by the ingrowth of its under layer the archenteron attains a considerable length. The floor of the archenteron is

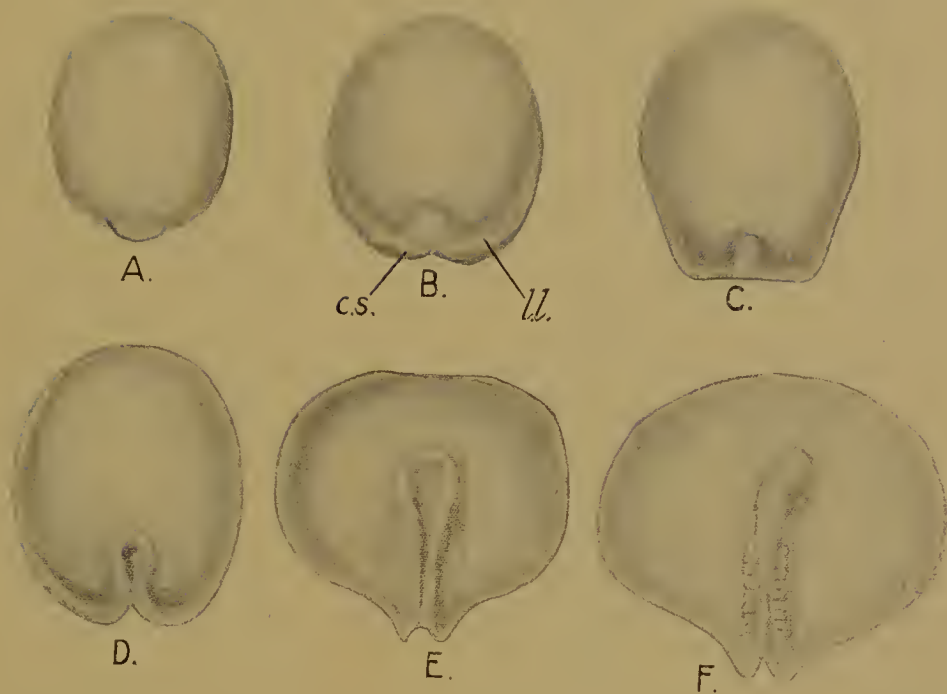


FIG. 67.—Overgrowth of the lip of the blastopore and formation of the embryo in Elasmobranchs. (A-C after Rückert, D-F after Ziegler.) *c.s.*, caudal swelling; *ll.*, lateral lip. In F the formation of a lip has extended almost to the anterior edge. In D, E, the medullary folds are still open, in F they are closed.

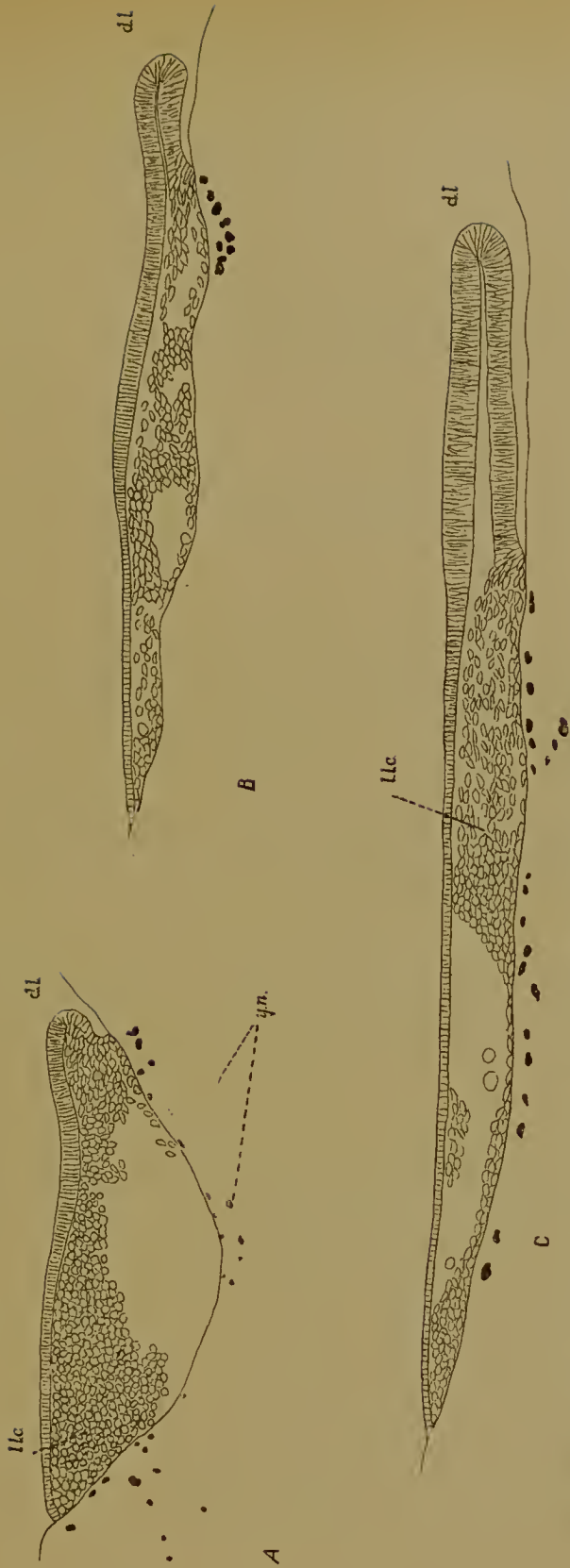


FIG. 68.—Successive stages in the growth of the dorsal lip, *d.l.* (posterior edge of the blastoderm), over the yolk in the dog-fish (*Scyllium*). *l.l.c.*, lower layer cells; *y.n.*, yolk-nuclei.

formed of yolk, into which yolk-nuclei subsequently make their way; its roof consists of a columnar epithelium derived in part from the overturning of cells at the lip of the blastopore, in part possibly from the posterior marginal cells of the lower layer.

But while this process is taking place at the dorsal lip, that is, at the median posterior margin of the blastoderm's edge, it is also being extended, though in a far less degree, to the neighbouring regions, the lateral lips, on the right and on the left. The archenteron thus comes to assume a crescentic shape, with a median anterior prolongation; the latter underlies the embryonic portion of the blastoderm, while the crescentic part is wholly extra-embryonic, and remains very shallow, though it is subsequently prolonged to the right and left round the edges of the blastoderm until a slight overgrowth is formed even at the anterior margin.

With the overgrowth at the lips of the blastopore the material for the germinal layers is laid down (Fig. 69). The superficial layer is now the ectoderm. The mesoderm consists of two parts: (1) two sheets of cells lying one on each side of the middle line over the embryonic portion of the archenteron; posteriorly these sheets pass into the caudal swellings—two thickenings at the edge of the blastoderm, one on each side of the middle line—where they are continuous with the roof of the archenteron, out of which they have been differentiated; (2) the formation of mesoderm is, however, not limited to the parts immediately adjacent to the dorsal lip, but is carried on at the lateral lips, and, as these extend forwards round the whole edge of the blastoderm, at the anterior edge as well. This extra-embryonic mesoderm is naturally continuous in the caudal swellings with the embryonic mesoderm first described; it takes part only in the formation of the area vasculosa.

The notochord is formed from a median strip of cells which is cut out of the roof of the archenteron; the process, like the differentiation of the mesoderm, takes place from before backwards. With the separation of the notochord and mesoderm the remainder of the archenteric roof is endoderm, and gives rise to the alimentary canal, the front end and sides bending down

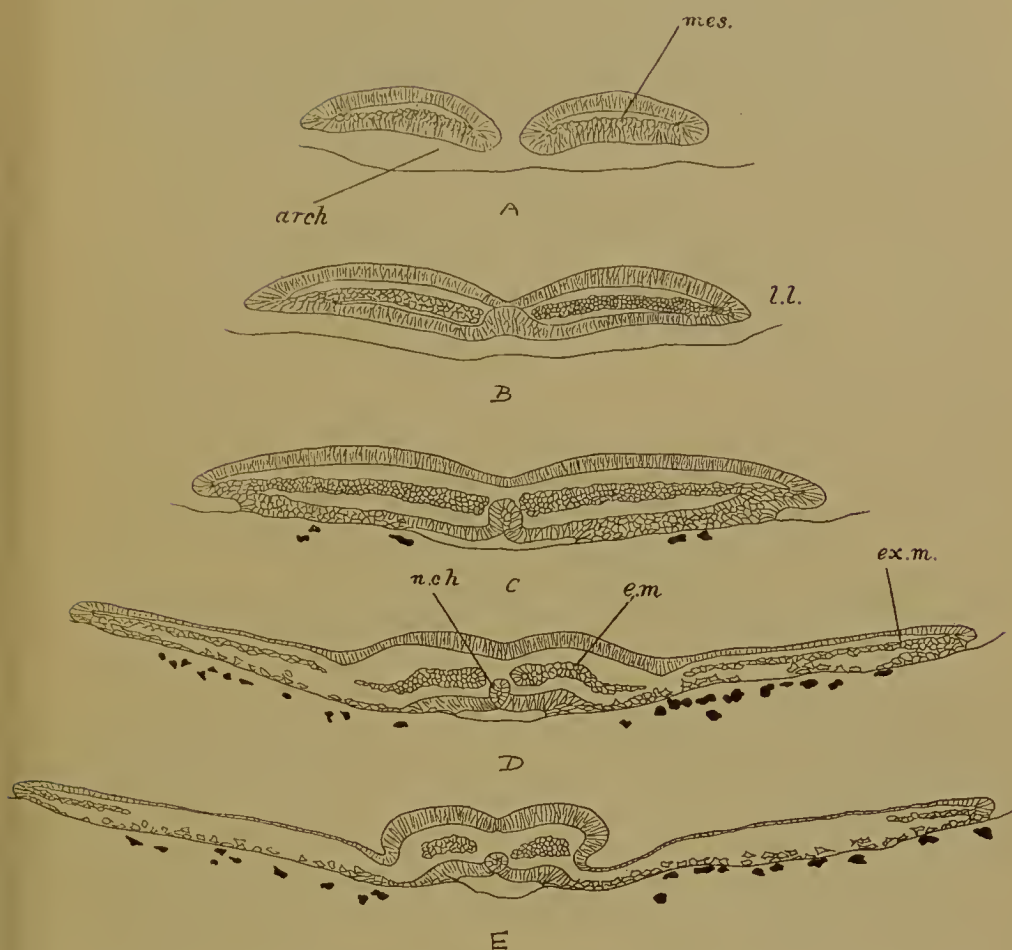


FIG. 69.—Five successive transverse sections through the hinder (embryonic) portion of the blastoderm of the dog-fish during the formation of the germinal layers. A is posterior, cutting the two caudal swellings; E, Anterior through the head of the embryo. *arch.*, archenteron; *mes.*, mesoderm; *e.m.*, embryonic mesoderm; *ex.m.*, extra-embryonic mesoderm; *n.ch.*, notochord; *l.l.*, lateral lip of the blastopore.

and meeting to form the ventral wall. The yolk in the floor of the archenteron plays no part in this process (Fig. 70).

Up to the present it is the posterior edge or dorsal lip which has been principally active, but now the anterior and lateral margins of the blastoderm become exceedingly vigorous and begin to grow over the yolk, the overgrowth being accompanied, as stated above, by a slight marginal invagination; and eventu-

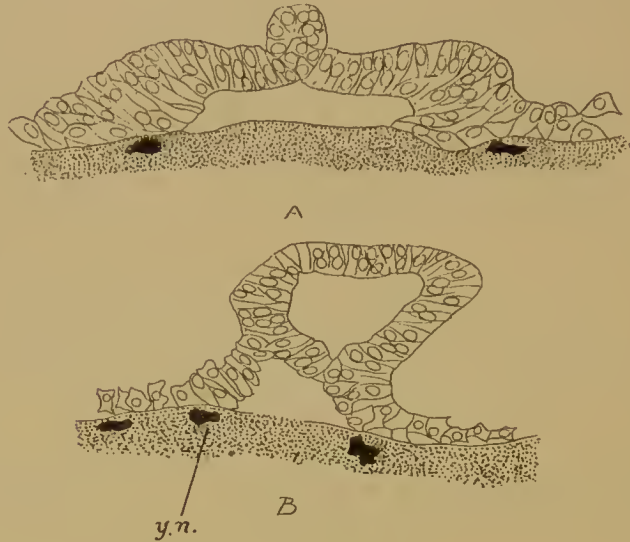


FIG. 70.—Two stages in the formation of the gut of the dog-fish by the bending down and fusion of the edges of the roof of the archenteron. *y.n.*, yolk-nuclei.

ally the anterior edge makes the whole circuit of the yolk, passing round the vegetative pole and reappearing behind the embryo as the ventral lip of the small 'yolk-blastopore' (Fig. 71). At the dorsal lip backgrowth of the caudal swellings is responsible for the posterior elongation of the body of the embryo alone, the body being raised above the surface of the yolk. Where the body passes into the hinder edge of the blastoderm growth of the latter ceases, but the lateral edges immediately adjacent to this point swing backwards until they bound a narrow median strip of yolk by which alone the aperture at the dorsal lip now communicates with the rest of the blastopore.




FIG. 71.—Extension of the blastoderm over the yolk after formation and folding off of the embryo in an Elasmobranch. A, The lateral lips have swung back parallel to one another behind the dorsal lip, so enclosing a narrow strip of yolk. B, Side view of the same. C, The anterior edge (*a.e.*) has passed beyond the vegetative pole, and in D it appears behind the embryo as the ventral lip (*v.l.*); *y.b.*, yolk-blastopore.

TELEOSTEI

The processes are essentially the same as in the Elasmobranchs. Blastopore formation begins at the posterior edge, where the

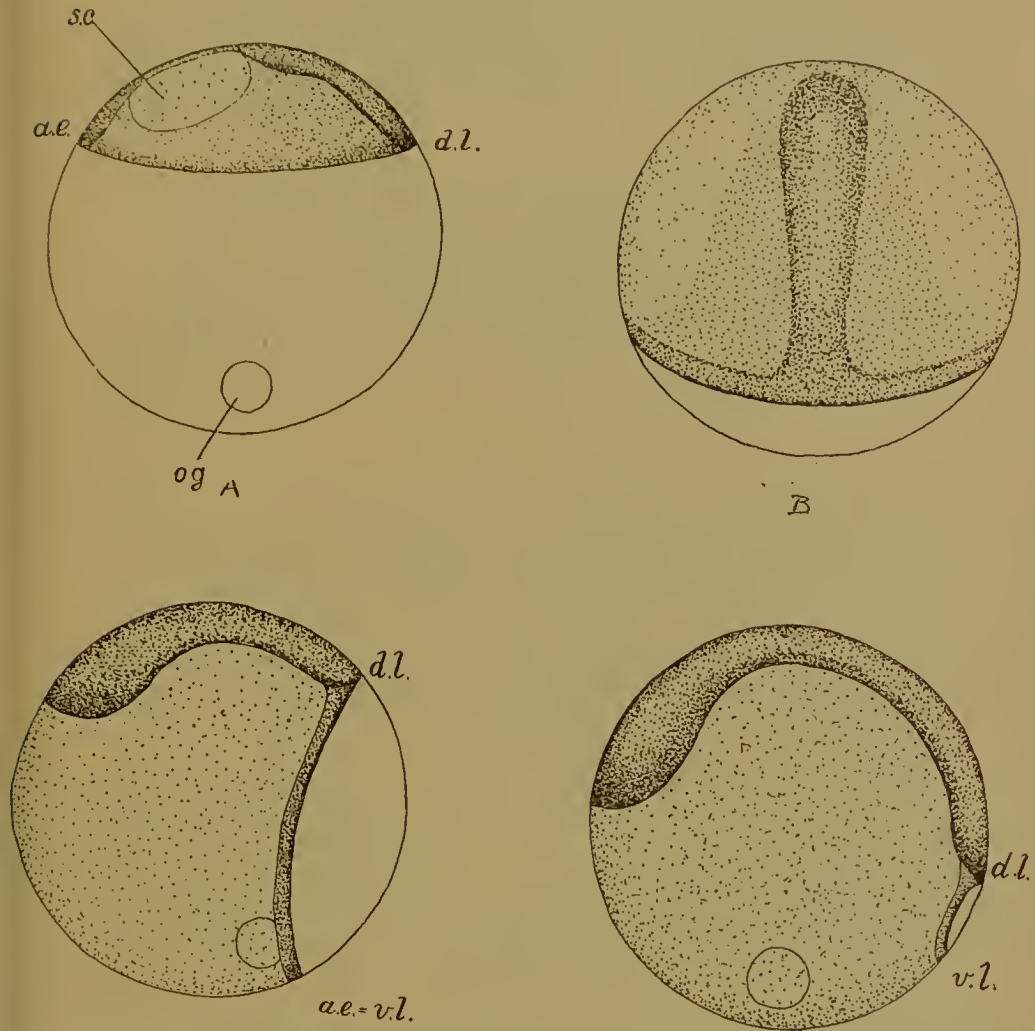


FIG. 72.—Growth of the blastoderm over the yolk after the formation of the material for the embryo in the Teleostean fish *Serranus*. (After Wilson.) *d.l.*, dorsal lip of the blastopore (posterior edge of the blastoderm); *a.e.*, anterior edge of the blastoderm or ventral lip (*v.l.*) of the blastopore; *s.c.*, segmentation cavity; *o.g.*, oil globule.

backward growth of the dorsal lip with concomitant development of an archenteric cavity gives rise to the body of the embryo, but the process is extended to the lateral and anterior edges, where there is a slight invagination. By the growth of

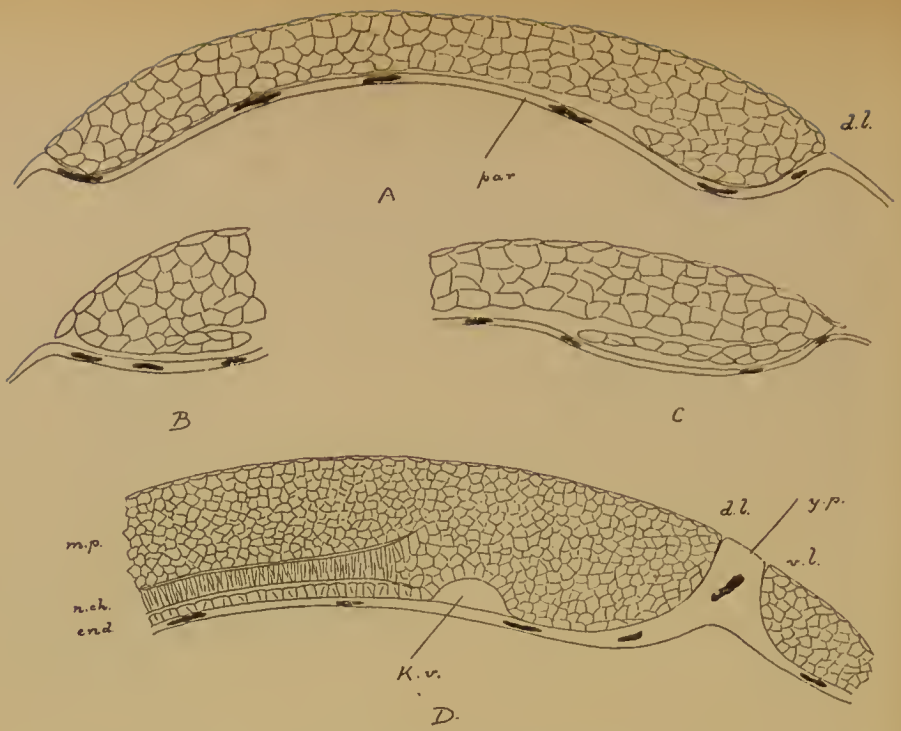


FIG. 73.—Sagittal sections through the blastoderm of *Serranus* during the formation of the germinal layers. (After Wilson.)

- A, Beginning of overgrowth at dorsal lip (*d.l.*).
 B, Overgrowth at anterior edge.
 C, Later stage of posterior edge.
 D, The anterior edge has become the ventral lip (*v.l.*); *n.ch.*, notochord; *end.*, endoderm; *m.p.*, medullary plate; *par.*, parablast (periblast); *y.p.*, yolk-plug; *K.v.*, Kuppfer's vesicle.

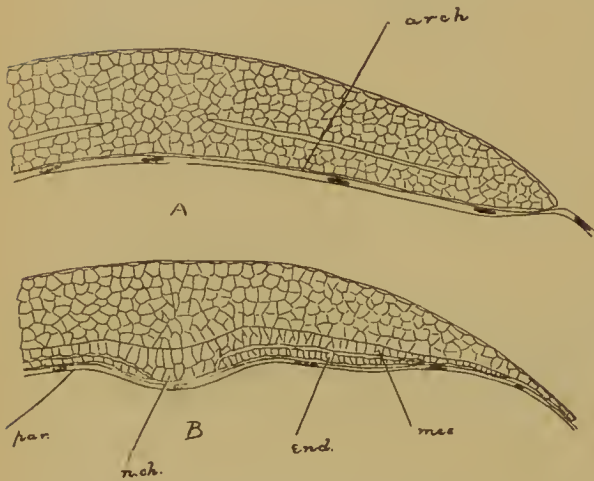


FIG. 74.—*Serranus*. Transverse sections showing differentiation of the roof of the archenteron into notochord (*n.ch.*), mesoderm (*mes.*), and endoderm (*end.*); *par.*, parablast (periblast). (After Wilson.)

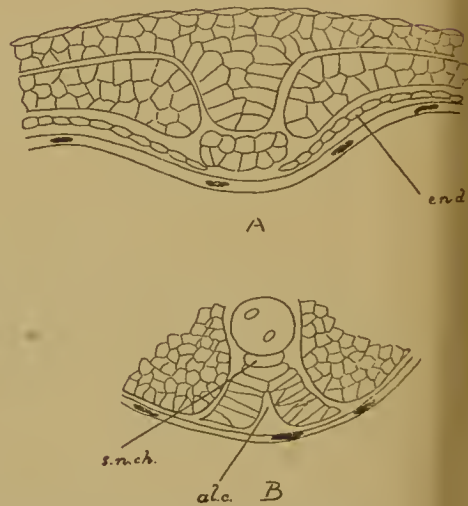


FIG. 75.—*Serranus*. Formation of the gut (*al.c.*) by the bending down of the sides of the roof of the archenteron. *s.n.ch.*, sub-notochordal rod; *end.*, endoderm. (After Wilson.)

these extra-embryonic edges the yolk is finally enclosed and the anterior margin is then the ventral lip (Fig. 72). Notochord and mesoderm are differentiated in the roof of the embryonic part of the archenteron, the rest of this layer giving rise to the alimentary canal, as in Elasmobranchs. Extra-embryonic mesoderm arises at the remaining edges of the blastoderm (Figs. 73-75).

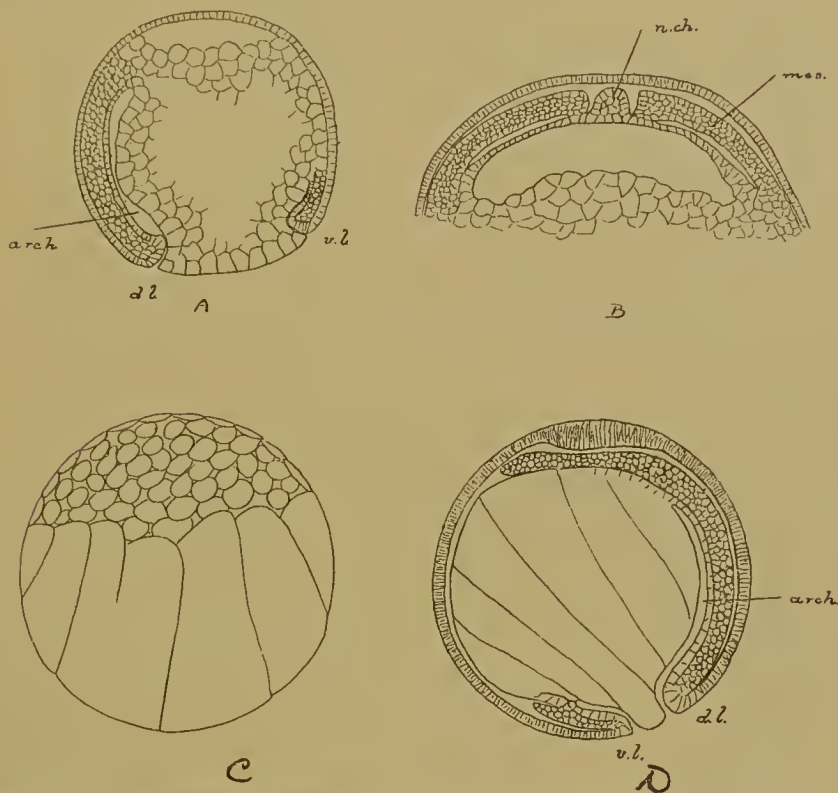


FIG. 76.—Formation of the germ-layers in Ganoid fishes. A, B, in the Sturgeon (*Acipenser*) (after Bashford Dean); C, D, in *Amia* (after Sobotta); *arch.*, archenteron; *d.l.*, dorsal lip; *v.l.*, ventral lip; *n.ch.*, notochord; *mes.*, mesoderm.

GANOIDEI

Our knowledge of the differentiation of the germinal layers is very slight, but it is known that the closure of the blastopore is bilateral, and that mesoderm is formed at its lips, the notochord in the middle dorsal line (Fig. 76).

DIPNOI

The holoblastic egg of *Ceratodus* resembles that of the frog very closely in the development of its archenteron. The roof

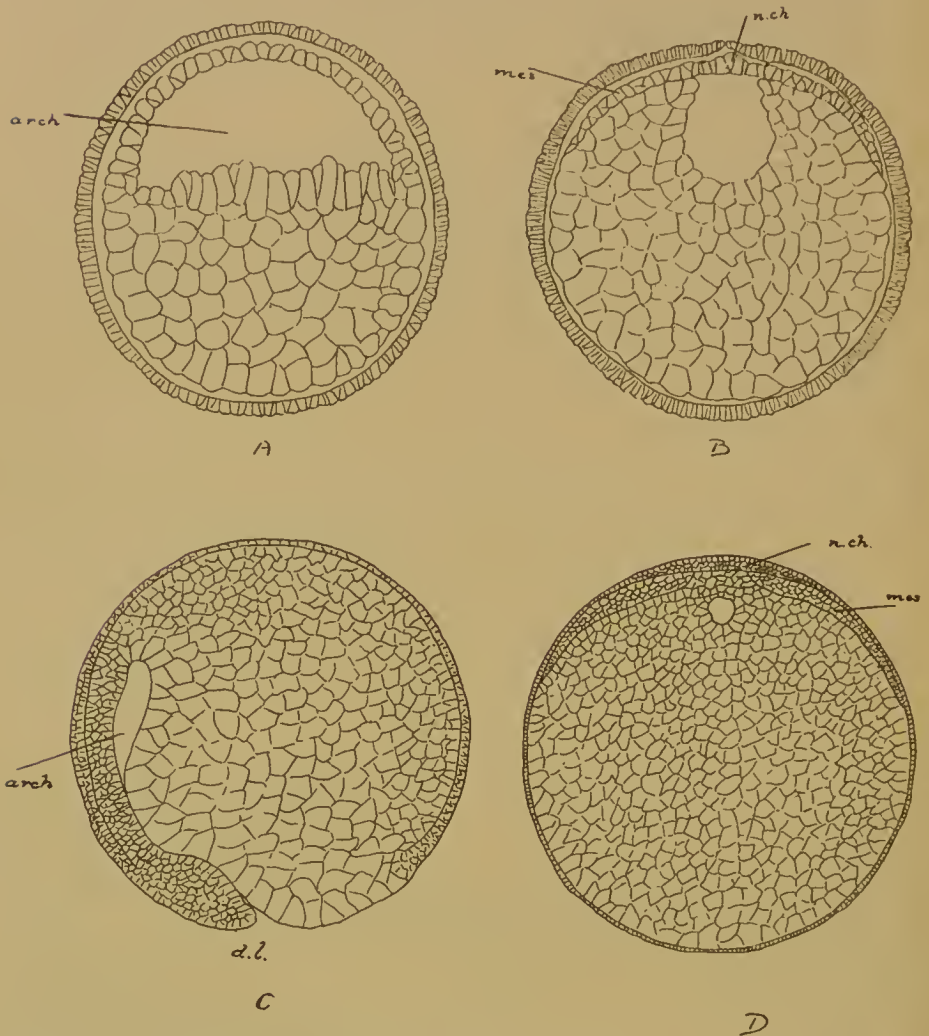


FIG. 77.—Formation of the germ-layers in Dipnoi. A, B, in *Ceratodus* (after Semon); C, D, in *Lepidosiren* (after Graham Kerr). *arch.*, archenteron; *d.l.*, dorsal lip; *n.ch.*, notochord; *mes.*, dorsal mesoderm.

of this cavity, however, takes no part in the formation of the gut, but is differentiated simply into median notochord and lateral plates of mesoderm. The yolk-cells then grow up to complete the dorsal wall of the alimentary canal (Fig. 77, A, B).

Lepidosiren resembles the frog in all respects, except that the yolk is more voluminous and that a ventral lip is never developed (Fig. 77, C, D).

URODELOUS AMPHIBIA

The method of germ-layer separation is here practically identical with that which is observed in the frog, except in one important respect. In the bilateral closure of the blastopore, the presence of a ventral as well as of a dorsal lip (Fig. 78, A) and the formation of the mesoderm from a double source, the two groups closely resemble one another; but while in the frog the under layer of the roof of the archenteron persists as the dorsal lining of the alimentary tract, in the Urodeles the roof of the archenteron becomes wholly converted into the notochord, as in *Petromyzon*, and the gut must be completed dorsally by an ingrowth of yolk-cells from the sides (Fig. 78, B, C).

The Anurous Amphibia, such as the toad, generally resemble the frog in this matter, but in one case the notochord is described as being formed from the middle streak of the whole thickness of the roof, and even in the frog such a procedure may be experimentally instigated by subjecting the embryos to the influence of cane sugar and other substances.

A comparison of these processes in the small-yolked and the large-yolked types shows that :

1. The blastoderm of the large-yolked corresponds to the animal region of the small-yolked egg, the yolk to the vegetative part, and that the edge of the blastoderm in the former is equivalent to the boundary between animal and yolk cells in the latter.

2. In both this bounding line becomes in its entirety the lip of the blastopore (except where the ventral lip is absent), the posterior point of the edge in the large-yolked being equivalent to the dorsal lip of the small-yolked, the anterior point to the ventral lip.

3. In both the germinal layers are laid down during the bilateral closure of this blastopore, the notochord stretching in front of the dorsal lip, the mesoderm springing from the lateral lips in two sheets which are continuous with one another behind the ventral lip.

4. The principal points of difference are two. First, the closure of the blastopore in Elasmobranchs, Myxinoids, and Teleostei, is effected in two periods; during the first the overgrowth is almost confined to the dorsal lip and produces the material for

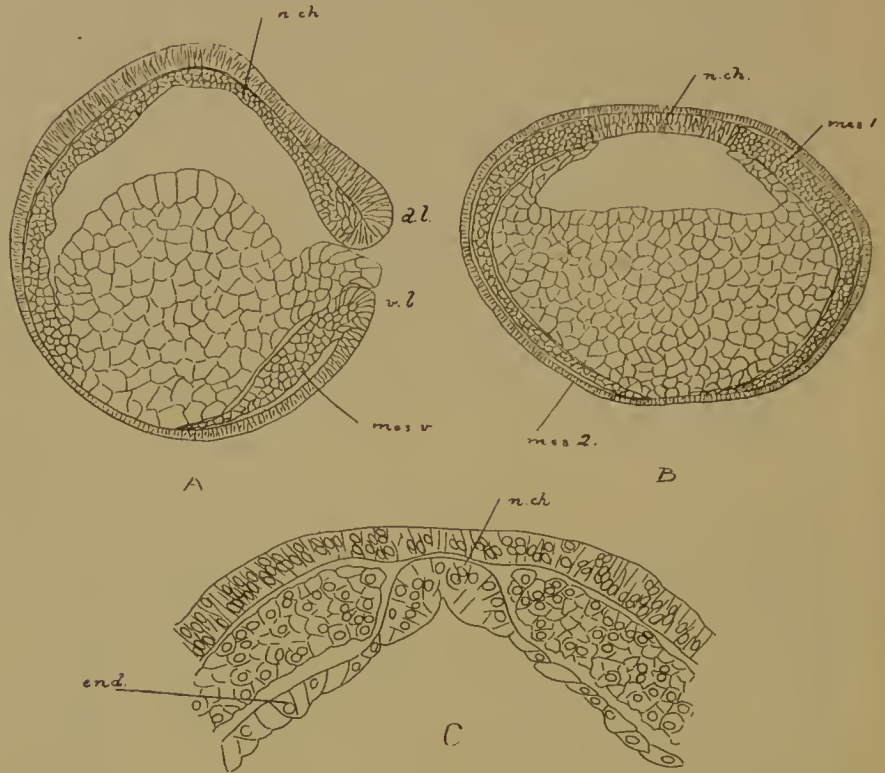


FIG. 78.—Formation of the germ-layers in the Axolotl.

A, Sagittal section after completion of the blastopore and rotation of the egg.

B, Transverse section of the same stage.

C, Dorsal part of a transverse section of a later stage. *n.ch.*, notochord; *d.l.*, dorsal lip; *v.l.*, ventral lip; *mes.v.*, mesoderm formed at ventral lip; *mes.1.*, dorsal mesoderm; *mes.2.*, ventral mesoderm (from the yolk-cells pushed into the segmentation cavity); *end.*, endoderm.

the formation of the embryo; in the second the yolk is gradually covered by an extension of the blastoderm in which the lateral and anterior margins are alone concerned. Secondly, in these cases a part only of the blastoporic lip is involved in the formation of the embryo, the lateral and ventral lips remaining wholly extra-embryonic.

GYMNOPHIONA

In this group the egg is so laden with yolk that in its segmentation nearly approaches the meroblastic type and results in a blastoderm lying on a partially divided yolk. This blastoderm consists of a superficial epithelium of columnar cells, covering

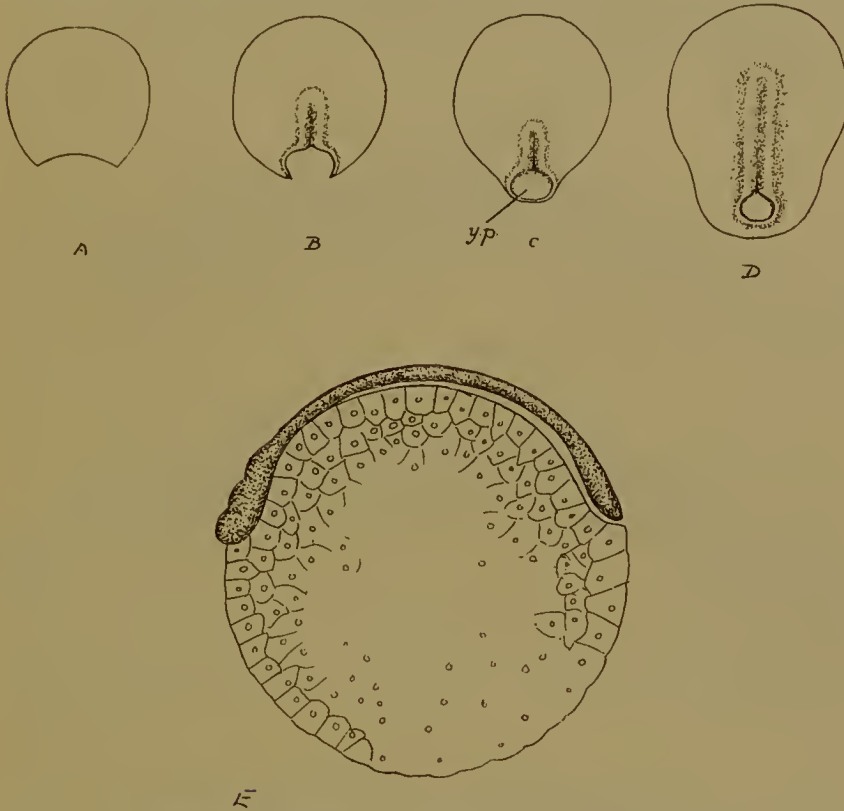


FIG. 79.—Formation and closure of the blastopore in the Gymnophiona. A-D, Surface views of the blastoderm of *Hypogeophis*. The lateral lips are seen to meet behind, and so form the ventral lip; *y.p.*, yolk-plug (after Brauer). E, Embryo of *Ichthyophis* lying on the partially segmented yolk which is still uncovered by the blastoderm. (After the brothers Sarasin.)

several irregular layers of scattered cells which are more abundantly supplied with yolk. The cavities between these cells are equivalent to the ordinary segmentation cavity. Below these again is the yolk, divided at its surface into cells, and containing nuclei scattered through its substance. Immediately round the blastoderm the surface of the yolk is also partially segmented.

At one point—the posterior middle point—of the edge of this

blastoderm the dorsal lip appears (Fig. 80); it exhibits the usual radiate arrangement of cells. The lip quickly grows back and so produces a long archenteron which comes to open into

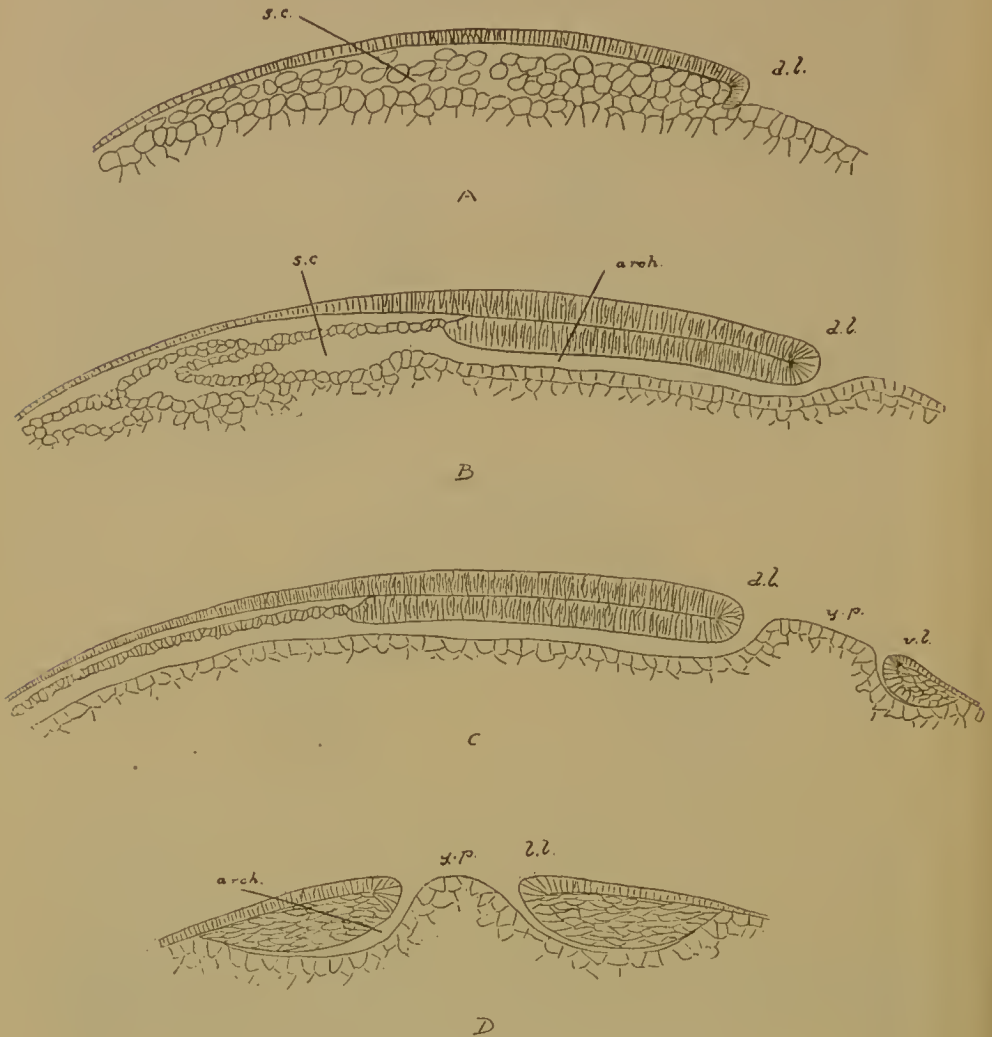


FIG. 80.—Formation of the germ-layers in *Hypogeophis*. (After Brauer.) A-C, Sagittal sections of three successive stages. D, Transverse section through the blastopore and yolk-plug (*y.p.*); *s.c.*, segmentation cavity into which in B and C the archenteron (*arch.*) opens; *d.l.*, dorsal lip; *l.l.*, lateral lip; and *v.l.*, ventral lip.

the segmentation cavity in front. The roof of the archenteron, which seems to be derived entirely from the superficial layer of the blastoderm, consists of a plate of columnar cells, its floor of the partially segmented yolk.

The process of overgrowth is not limited to the dorsal lip, but extends to the immediate right and left. Surface views (Fig. 79, A-D) show that the transversely placed lip soon becomes crescentic, and that the horns of the crescent then grow not only backwards, but towards the middle line as well, approaching one another until they meet and so form what is the ventral lip of the now circular blastopore. In section it is seen that there is a slight ingrowth at the lateral and at the ventral lips of a plate of cells continuous with the similarly formed plate

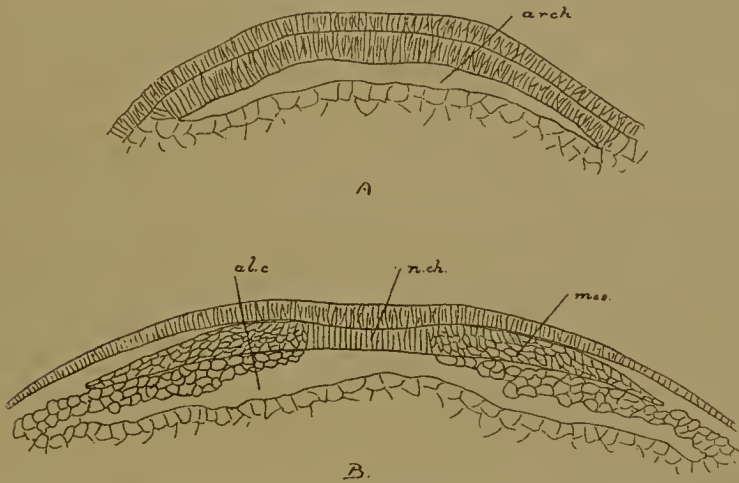


FIG. 81.—Transverse sections of *Hypogeophis* showing the differentiation of the roof of the archenteron into notochord (*n.ch.*) and mesoderm, and the formation of the roof of the gut (*al.c.*) by upgrowth of yolk-cells from the sides. (After Brauer.)

which forms the roof of the archenteron in front; beneath the plate is a slit-like space, also, of course, archenteric; in the midst of the blastopore is the projecting typically Amphibian yolk-plug.

But in spite of this resemblance there is a very serious difference between the ventral lip of the Gymnophiona and that of all other Anamnia. For while in the latter the whole of the edge of the blastoderm or small-celled area is converted into a blastoporic lip, the posterior point being the dorsal, the diametrically opposite anterior point becoming sooner (in small-yolked eggs) or later (in large-yolked eggs) the ventral lip, and while consequently the whole of the vegetative surface of the egg is covered up when the blastopore closes, in the former the anterior and

a large part of the two lateral edges take no part in this process, which is confined to the posterior and immediately adjacent portions of the edge; this small portion gives rise to the dorsal and two lateral lips, which latter by their fusion produce the remarkable similitude of the ventral lip of other forms. As a result the vegetative hemisphere is still uncovered when the blastopore has become circular (Fig. 79, D, E). The importance of this fact for the correct understanding of the relations of the blastopore to the blastoderm in the Amniota cannot possibly be over-emphasized.

To return to the germinal layers. The superficial layer is now the ectoderm. The roof of the archenteron becomes divided into a median strip—the notochord, and two lateral sheets—the mesoderm—which are continuous with one another behind the yolk-plug by means of the cell-plate invaginated at the lateral and ventral lips (Fig. 81). The mesoderm has in fact precisely the same relations as in other Anamnia at this stage. The notochord passes back into the dorsal lip. No additions are made to either notochord or mesoderm from any other source. The roof of the gut (endoderm) is completed by upgrowth and ingrowth of vegetative cells underneath the middle layer.

AMNIOTA

Whereas in the Anamnia the blastoporic lip appears at the edge of the blastoderm, in the Amniota it lies wholly within the latter. The blastopore leads into an archenteron, and with the formation of these structures the materials for the germinal layers are laid down. Only in the more primitive forms is the archenteric cavity well developed; usually it is much reduced and represented only by the 'neurenteric' passage or 'chordacanal'. In primitive forms the upper and lower layers are still united at the point where the blastopore and archenteron arise, and both layers may perhaps be said to share in their formation; but in most cases all these parts are derived from the upper layer of the blastoderm alone, the subsequent fusion with the lower layer being purely secondary. The edge of the blastoderm, which is entirely independent of the blastopore, grows steadily over the surface of the yolk, finally enclosing it at the vegetative pole.



FIG. 82.—Three stages in the formation of the blastopore at the hinder end of the embryonic shield of a Reptile (*Platydictylus*). Surface views. (After Will.)

The Reptiles will be considered first as the whole process is far clearer in them than in the other two groups.

REPTILIA

There is distinguishable in the blastoderm at the close of segmentation a circular or oval area placed excentrically towards the posterior end ; this area is the embryonic shield. The upper layer of the blastoderm consists of cylindrical cells in the embryonic shield, of flat cells in the surrounding region ; below it is the segmentation cavity. The lower layer is an irregular sheet of scattered rounded cells, not arranged at present in an epithelium, and is constantly being reinforced by the addition of cells from the nucleated yolk beneath. Between the lower layer and the yolk is a shallow cavity, the subgerminal cavity. In some forms, such as *Platydictylus* and *Lacerta*, there is one point in the margin of the embryonic shield where upper and lower layers are continuous ; this is the primitive plate, and it is situate at what will be the hinder end (Fig. 83, A). The lower layer cells before long arrange themselves in a flat epithelium. Meanwhile a depression has appeared in the primitive plate ; this is the beginning of the archenteron, and its anterior margin is the dorsal lip of the blastopore. Seen from the surface (Fig. 82) the dorsal lip presents the appearance of a transverse rim bounding a groove at the hinder edge of the embryonic shield. The rim rapidly becomes crescentic, the horns of the crescent turn back, meet, and fuse behind the primitive plate which now corresponds exactly to the Gymnophionan yolk-plug.

During the backgrowth of the horns of the crescent, which are the lateral blastoporic lips, the cavity of the archenteron has rapidly extended until it reaches the anterior end of the embryonic shield (Fig. 83) ; the cavity is broad. The roof consists of a layer of columnar cells which at the dorsal lip turn over in the ordinary way into the cells of the upper layer. The floor is in front distinct from the lower layer, and here it consists of a single layer of cubical cells ; behind the dorsal lip—in the primitive plate—it is much thickened, and from this thickening there proceeds backwards a narrow tongue of cells between the upper and the lower layers.

A transverse section (Figs. 84, A; 86) through the blastopore shows the mass of cells of the primitive plate flanked on each side by a projecting blastoporic lip and sending out between the upper and lower layers two lateral sheets of cells.

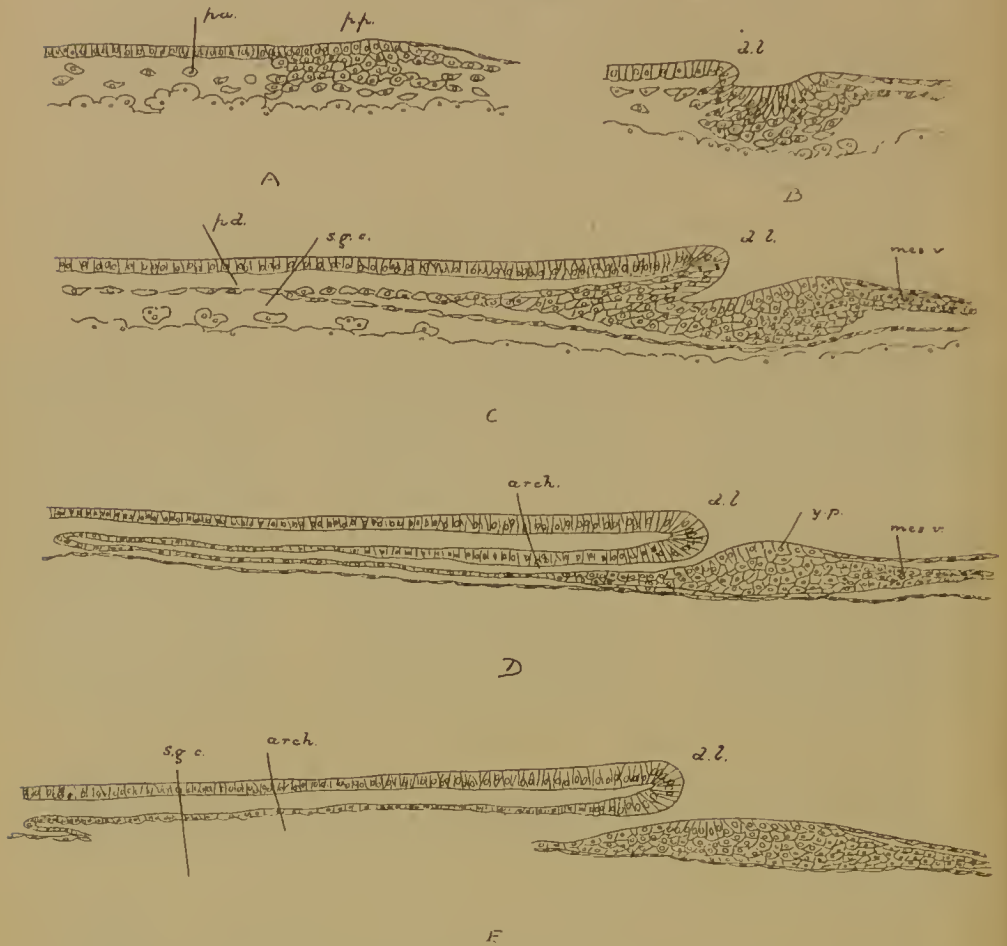


FIG. 83.—Sagittal sections of the blastopore and archenteron in the Gecko *Platydactylus*. (After Will.) A-E, Successive stages; *p.p.*, primitive plate; *p.d.*, lower layer or paraderm; *s.g.c.*, subgerminal cavity; *arch.*, archenteron; *d.l.*, dorsal lip; *y.p.*, yolk-plug; *mes.v.*, mesoderm formed at the ventral lip.

The resemblance between these structures and those in the Amphibian, and particularly the Gymnophionan egg when the blastopore has become circular, is sufficiently obvious. The dorsal and lateral lips (there is no ventral lip in the Reptiles) clearly correspond in the two cases; the mass of cells in the primitive plate embraced by these lips is the yolk-plug; the

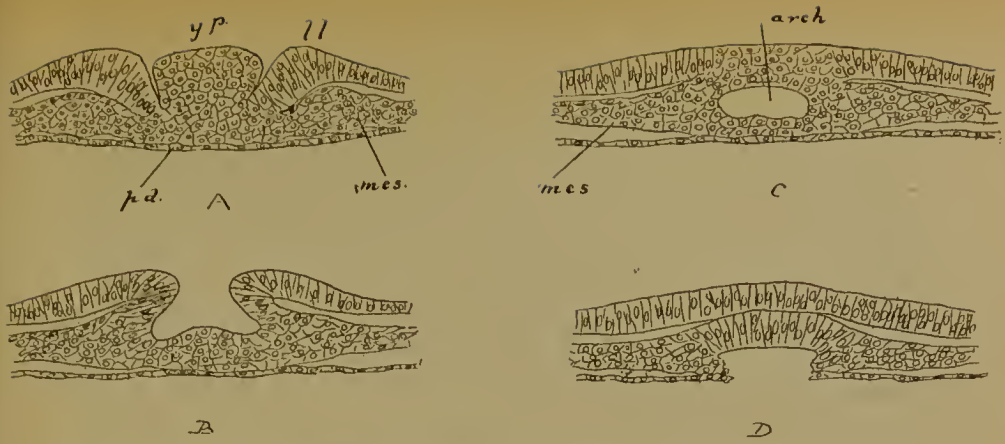


FIG. 84.—Four successive transverse sections through the blastopore and archenteron of *Platydactylus*. (After Will.)

A, Posterior section through the yolk-plug (*y.p.*); *ll.*, lateral lip; *p.d.*, lower layer; *mes.*, mesoderm springing from the lateral lips.

B is more anterior, just behind the dorsal lip.

C is just in front of the dorsal lip, where the floor of the archenteron (*arch.*) is still intact, and

D more anterior, where the archenteron communicates with the sub-germinal cavity.

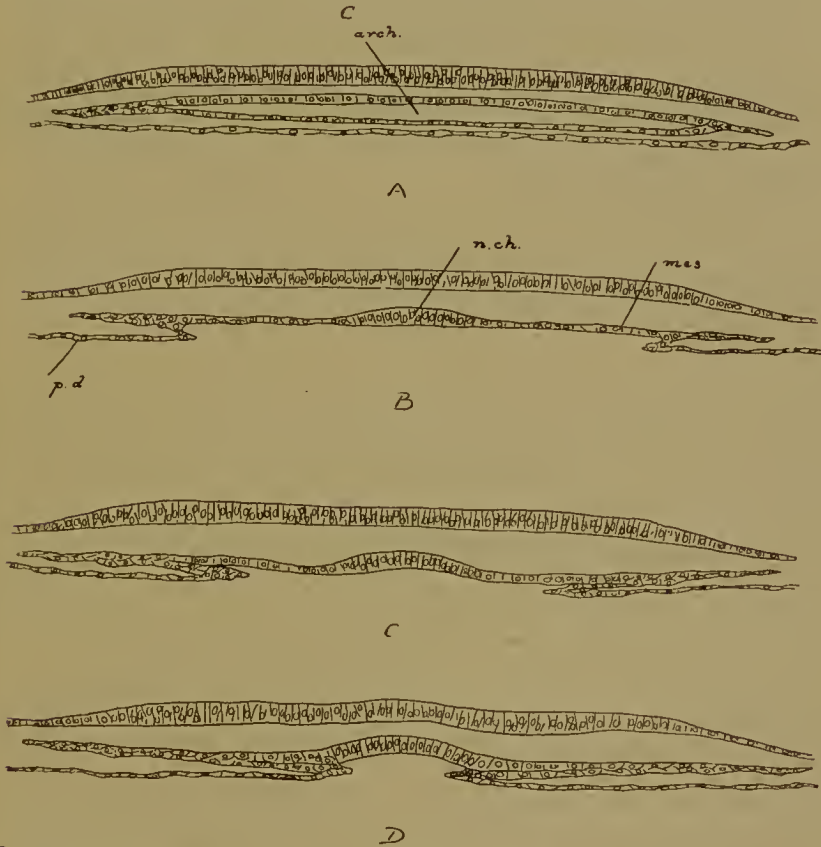


FIG. 85.—Four stages of the differentiation of the notochord (*n.ch.*) and mesoderm (*mes.*) from the roof of the archenteron (*arch.*) and the growth of the lower layer (*p.d.*) or endoderm towards the middle line after the destruction of the floor of the archenteron. (*Platydactylus*, after Will.)

cavity of invagination is the archenteron in which floor corresponds to floor and roof to roof; lastly, the sheets of cells projecting beneath the upper layer at the sides of and behind the blastopore are the equivalents of the mesoderm formed at the lateral and ventral lips in the Amphibia.

From this comparison it follows of course that cells which are the morphological equivalents of the yolk-cells of the Amphibia are to be found in the upper layer of the Reptilian blastoderm. That layer, therefore, cannot be termed the ectoderm until the process of invagination is complete.

The floor of the archenteron now fuses throughout with the lower layer, and as soon as the fusion is completed perforations

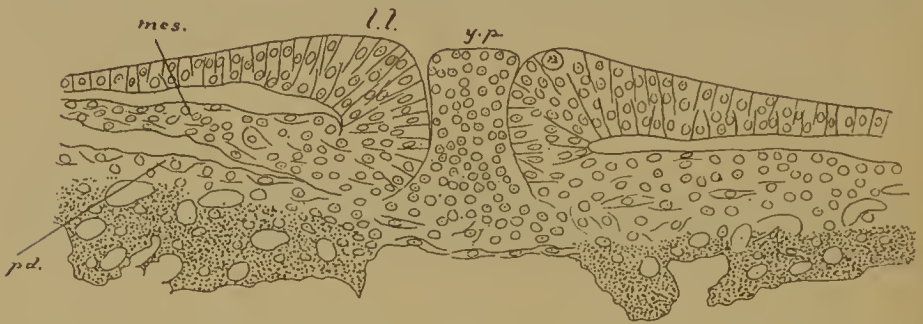


FIG. 86.—Transverse section of the blastopore and yolk-plug (*y.p.*) of the tortoise (*Trionyx*). (After Mitsukuri.) *l.l.*, lateral lip; *mes.*, mesoderm produced at the lateral lips; *pd.*, lower layer not yet detached from the yolk (stippled).

begin to appear in the fused layers (Figs. 83, E; 84, E). They seem to be unable to keep pace with the general growth of the blastoderm and to become first stretched and then fenestrated. But to whatever causes the perforation may be due, the floor of the archenteron with the underlying lower layer completely disappears, and the archenteron then communicates freely with the subgerminal cavity. The roof of the archenteron is now inserted by its edges into the surrounding lower layer.

The median strip of the roof next thickens to form the notochord (Fig. 85), and separates from the two lateral portions which then become the mesoderm. The notochord passes posteriorly into the dorsal lip, the plates of mesoderm into the lateral lips of the blastopore, and here the latter are perfectly continuous with the mesoderm produced at the sides of and behind the



FIG. 87*.—Area pellucida of the hen's egg. A, After 12 hours', B, After 18 hours' incubation, as seen by transmitted light. *pr.g.*, primitive groove; *n.ch.*, notochord; *pr.am.*, pro-amnion.

blastopore (Figs. 84, A, B; 86). The mesoderm thus exhibits all the relations which it has in the Anamnia.

The lining epithelium of the alimentary canal (endoderm) is derived from the lower layer, which grows in from the sides below the mesoderm and notochord (Fig. 85, c, d). From this layer the gut is subsequently folded off, the remainder being yolk-sac epithelium. In several cases the lip of the blastopore is not the only source of origin of notochord and mesoderm, both receiving additions in front, and the mesoderm at the sides also, from the lower layer.

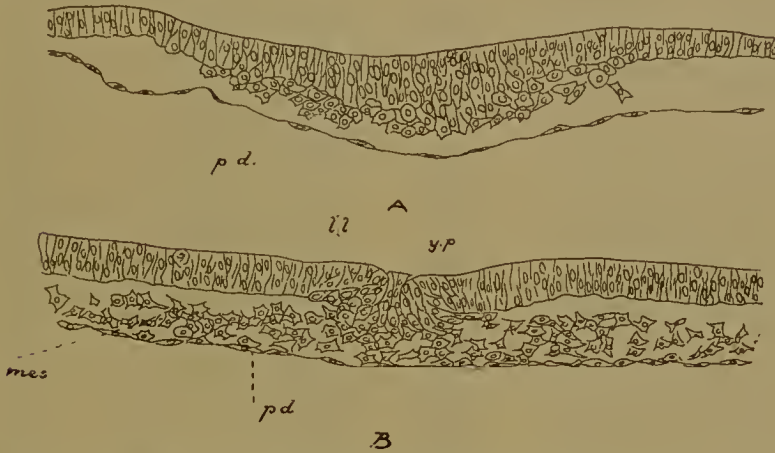


FIG. 87.—Formation of the primitive streak and groove of the chick by proliferation of cells of the upper layer. Transverse sections.

A, At 10 hours. There is at present no sign of the primitive groove; the lower layer (*pd.*) takes no part in the proliferation.

B, At 15 hours. The primitive groove has appeared. It is occupied by a projecting mass of cells, the yolk-plug (*y.p.*), and bounded by the lateral lips (*l.l.*). The proliferated cells spread out on each side as the lateral sheets of mesoderm (*mes.*).

AVES

The conditions observed in the Birds are very readily derived from and very easily understood in the light of those which obtain in the Reptiles.

There appears in the posterior region of the blastoderm a proliferation of cells in the upper layer (Fig. 87, A); this rapidly extends in the median line, and along it there appears a narrow groove. The cell proliferation is the 'primitive streak', the groove the 'primitive groove' (Fig. 87*).

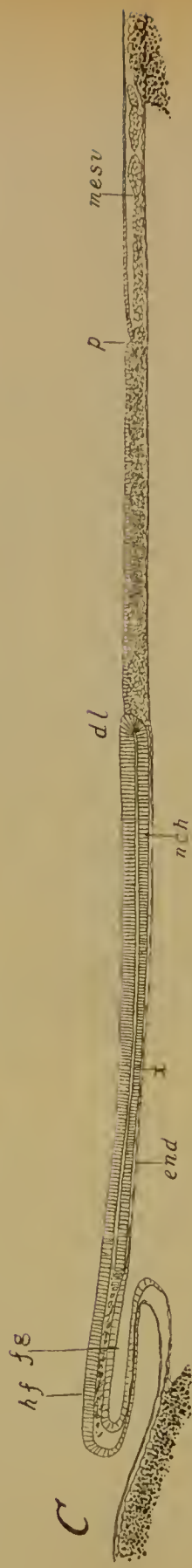


FIG. 88.—Median longitudinal (sagittal) sections of the blastoderm of the chick at A, 10, B, 15, and C, 24 hours, showing the development of the primitive streak (*d.l.* to *p.*), the formation of the notochord (*n.ch.*) in front of the anterior end of the streak (*d.l.*, dorsal lip), and of mesoderm (*mes.v.*) behind the posterior end (*p.*) or ventral lip. At both *d.l.* and *p.* there are slight depressions; *end.*, lower layer (endoderm); *f.g.*, fore-gut folded off from the endoderm inside the head-fold of the embryo (*h.f.*); *x.*, the position of the first mesodermal somite.

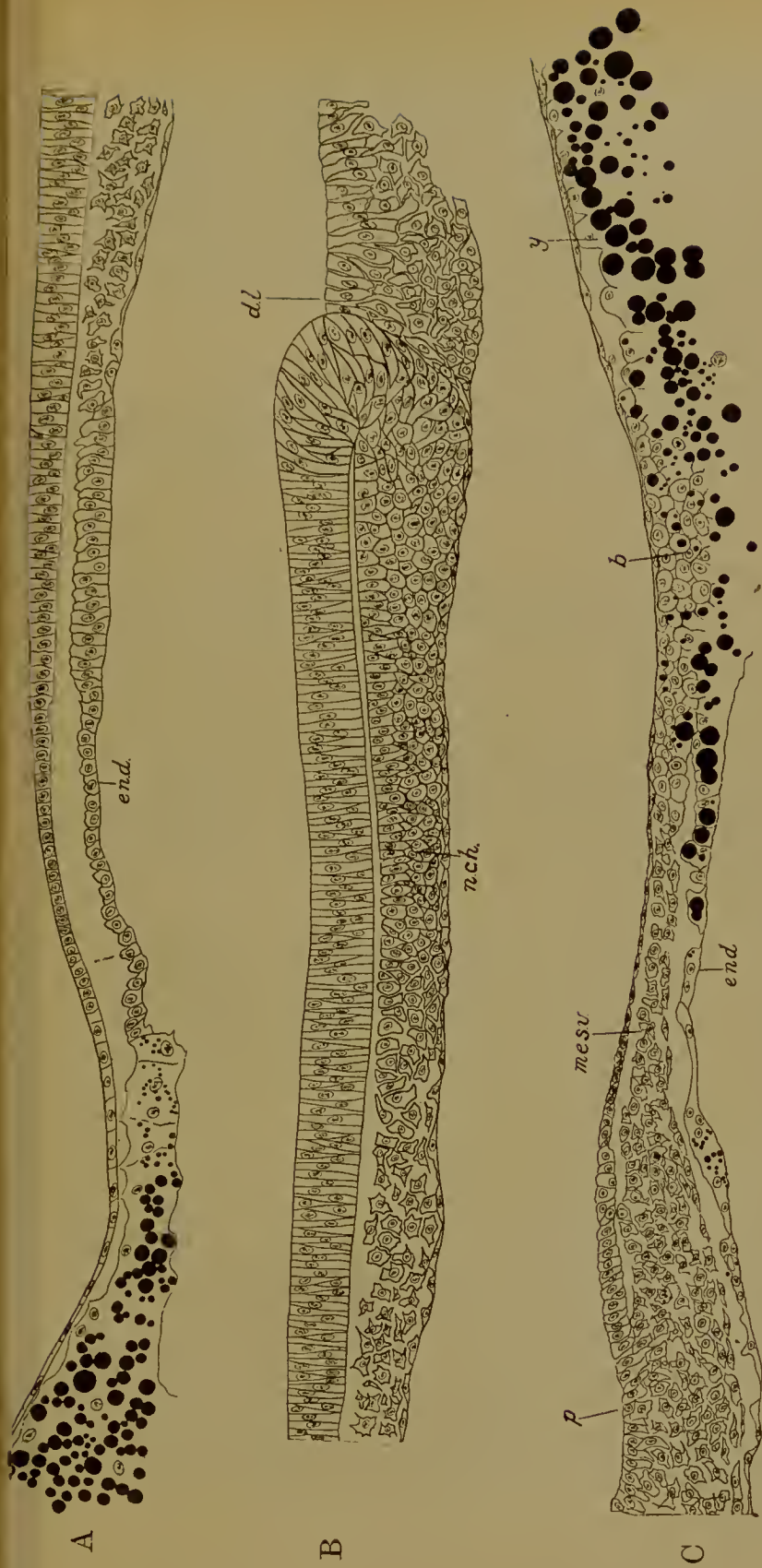


FIG. 89.—Enlarged views of the anterior (A), middle (B), and posterior (C) regions of the sagittal section of 15 hours (Fig. 88, B); *end.*, lower layer thickened where the fore-gut will be formed (in A) and passing anteriorly into the nucleated yolk. In B the turning over of the cells at the dorsal lip (*d.l.*) is easily seen. The cells so turned over pass into the mass of cells in front, which is the notochord (*n.ch.*). In C there is a depression at the hind end (*p.*) of the primitive streak, behind which the mesoderm (*mes.v.*) projects back freely between upper and lower layers. This mesoderm comes into contact with the masses of cells lying on the yolk at the edge of the blastoderm, the future blood islands (*b.*). With these and the nucleated yolk (*y.*) the lower layer (*end.*) is continuous.

This primitive groove is simply an elongated and laterally compressed blastopore. In front of the anterior end—the dorsal lip—the notochord is produced (Figs. 88, 89); to right and left of the notochord are the sheets of mesoderm which, springing from the sides—the lateral lips—of the groove (Fig. 87, B), are continued into one another behind its posterior end, where there may be an actual ventral lip (Fig. 90). The archenteric cavity

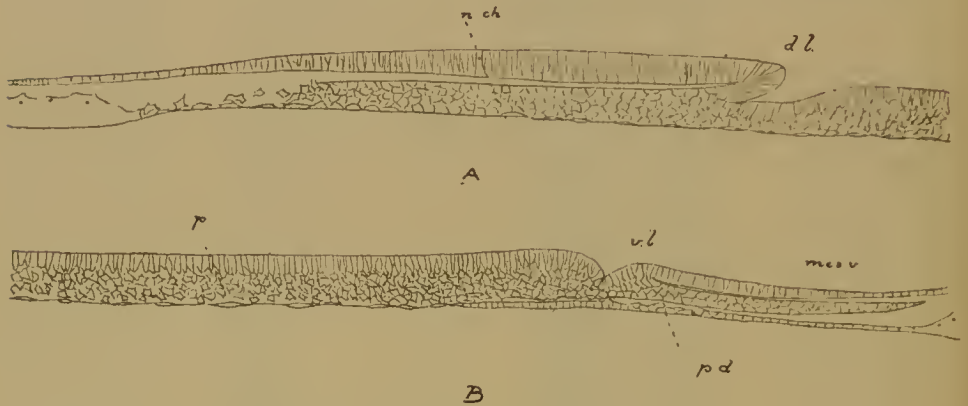


FIG. 90.—Anterior (A) and posterior (B) halves of a sagittal section through the primitive streak and associated structures of the sparrow. (After Schauinsland.) There is a slight cavity, archenteron, below the dorsal lip (*d.l.*), and a well-marked ventral lip (*v.l.*). *n.ch.*, notochord; *p.s.*, primitive streak; *mes.v.*, mesoderm behind the ventral lip; *p.d.*, lower layer.

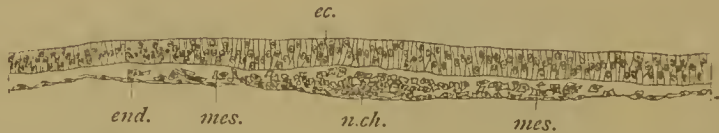

FIG. 91.—Transverse section of the anterior end of the blastoderm of the chick at 15 hours showing the formation of anterior notochord (*n.ch.*) and mesoderm (*mes.*) directly from the lower layer (*end.*); *ec.*, ectoderm.

has, however, in most cases disappeared, though a vestige of it is sometimes to be seen (Fig. 90). Between the sides of the groove—which still exhibit the structure characteristic of blastoporic lips, is merely a mass of cells—representative of the yolk-plug (Fig. 87, B)—fused with the lower layer. The so-called ‘neurenteric canal’, which appears later, is the sole remnant of the archenteron together with the communication which we have seen to become established between it and the subgerminal cavity in Reptiles.

The primitive streak and groove invariably originate in the

upper layer, fusion with the lower layer being merely secondary ; only after the germ-layers have been formed can the upper layer be described as ectoderm.

The notochord and mesoderm receive increments in front from the lower layer (Fig. 91).

The gut (endoderm) is formed as in Reptiles.

MAMMALIA

In the Monotremata there is a long archenteron with a much reduced lumen produced from the upper layer. The blastopore is an elongated 'primitive groove'. The notochord and mesoderm have the usual relations to these structures. The interpretation put by Wilson and Hill on their observations—namely, that the dorsal lip and archenteron are derived from the 'primitive plate' while the primitive streak and groove are of distinct origin—is probably erroneous. We may accept Assheton's explanation that the 'primitive plate' of the authors is simply the point of final enclosure of the yolk by the blastoderm, a precociously rapid process in this form, and that archenteron and primitive groove are, as everywhere else, parts of one and the same structure (Fig. 92).

We are still in ignorance of the formation of the germinal layers in Marsupials, though we may hazard the conjecture that the embryonic area of the blastocyst wall will be found to behave like the embryonic shield in Reptilia, that a blastopore and archenteron will be developed near its posterior edge in connexion with which the notochord and mesoderm will arise in the usual way, that the archenteron will break through into the subgerminal cavity below the lower layer, and that this layer will give rise to the gut.

This indeed is what occurs in the Placental Mammals, the only difference being that here the embryonic area is from the first enclosed in the sac of the trophoblast as part of the embryonic knob. This knob, as we have already seen, is, together with the lower layer, differentiated from the original inner mass.

The embryonic area (Fig. 92*), derived from the embryonic knob, behaves precisely as the embryonic shield of the upper layer in Reptiles, giving rise to an archenteron and blastopore ; this event is, however, postponed until after the amnion has been formed.

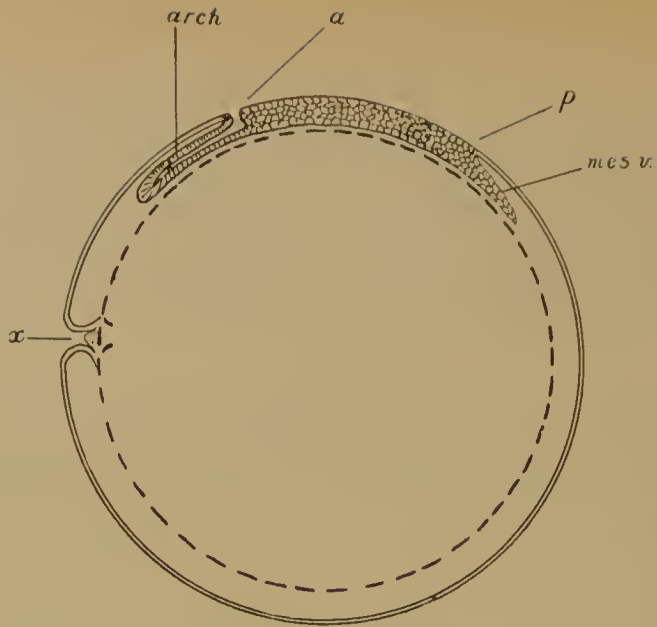


FIG. 92.—Diagram of the egg of *Ornithorhynchus* after formation of the germinal layers. (After Assheton's modification of Wilson and Hill.) *x*, the point at which the blastoderm has finally enclosed the yolk; here the upper layer (double line) and lower layer (broken line) are continuous with one another and with the yolk. This is the 'primitive plate' of Wilson and Hill. *a* to *p*, primitive streak; *a*, anterior end (dorsal lip); *p*, posterior end. In front of *a* is the archenteron (*arch.*), behind *p*, the mesoderm of the ventral lip (*mes.v.*).




FIG. 92*.—Embryonic shield of the dog. (After Bonnet.) In the embryonic shield, where the cells are columnar, the nuclei are more closely packed than in the surrounding trophoblast, where the cells are flat. At the posterior end is a notch, the blastopore (lower end in the figure).

When the archenteron has been developed it behaves in the manner we are already acquainted with. Its floor fuses with the lower layer, and then the two break away so that the archenteron comes to communicate with the subgerminal or yolk-sac cavity (Fig. 93). The notochord is differentiated out of its roof, the mesodermal sheets pass into the lateral lips and are

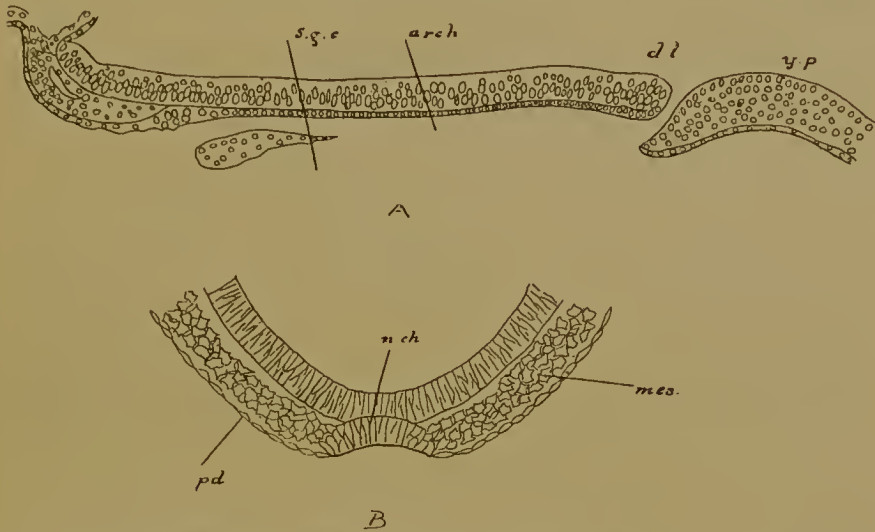


FIG. 93.—A, Longitudinal section of the embryonic shield and blastopore of the bat, *Vespertilio*. (After Van Beneden.) The archenteron (*arch.*) has broken through into the subgerminal cavity (*s.g.c.*) or cavity of the blastopore. Below the dorsal lip (*dl.*) is the blastopore (so-called neurenteric canal), and behind this the yolk-plug (*y.p.*). (With this should be compared Fig. 138, which shows a human embryo in the same stage.)

B, Transverse section showing the origin of the notochord (*n.ch.*) from the roof of the rudimentary archenteron in the mouse. The floor of the archenteron has already disappeared. *mes.*, mesoderm; *pd.*, lower layer. Above is the ectoderm of the medullary plate.

continuous with one another behind the blastopore. Accessory notochordal and mesoblastic material is proliferated in front from the lower layer. After this the lower layer is endoderm, and gives rise to the gut and yolk-sac, after growing in from the sides underneath the notochord.

The archenteron may be well developed (as in *Vespertilio*), but more usually is reduced to a narrow canal, the 'chorda-canal' or, so called, 'neurenteric' passage.¹

¹ Neurenteric passage means properly the communication between the medullary tube and the hind end of the archenteron. See below, chap. vii.

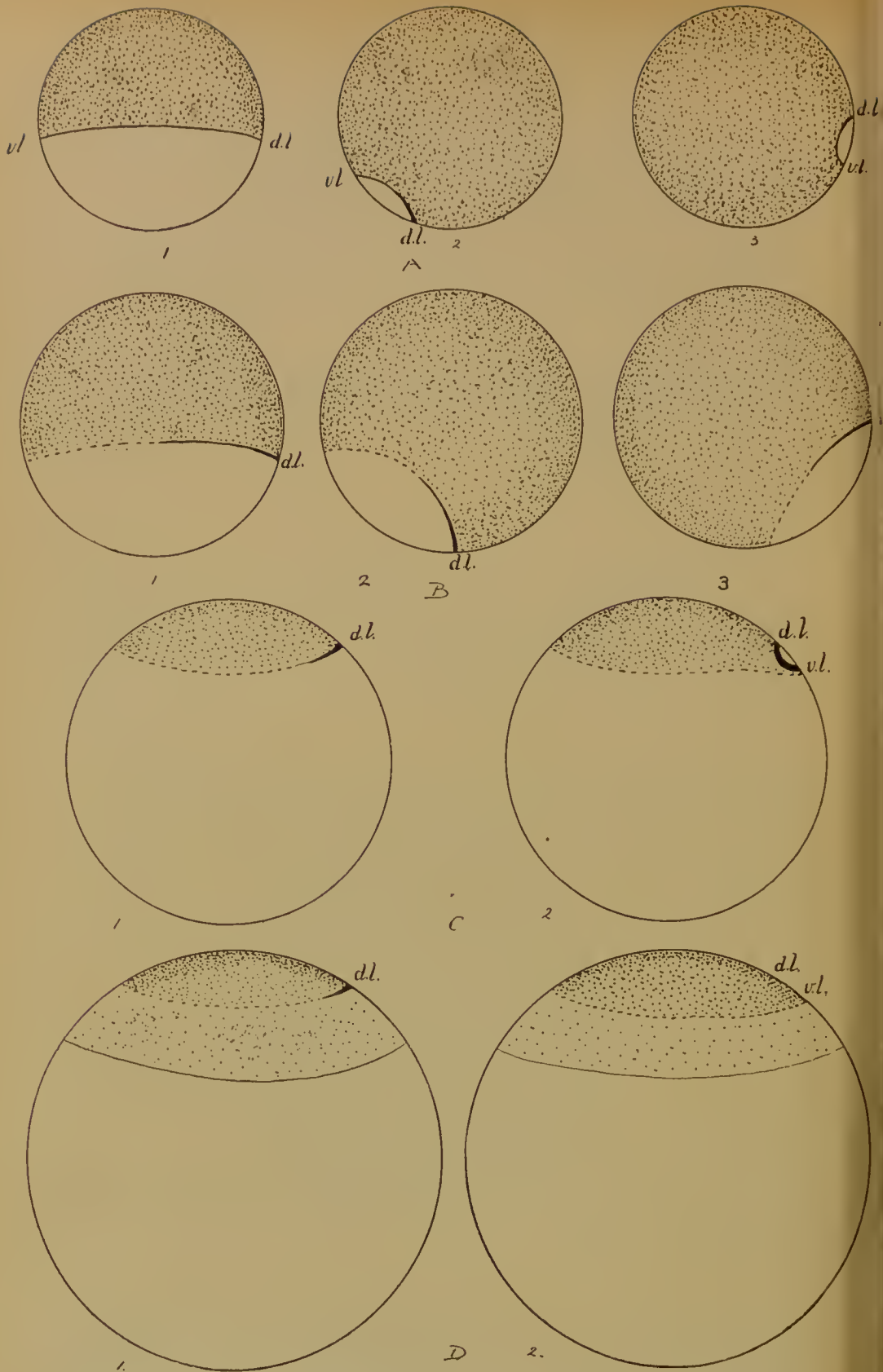


FIG. 94.—Diagram to illustrate the relation between the Anamniote and Amniote blastopores. For description see p. 147.

THE RELATION BETWEEN THE AMNIOTE AND THE
ANAMNIAN BLASTOPORE

The facts we have now reviewed will have made it evident that there are certain features common to the separation of the germinal layers in all Vertebrates.

Thus in all cases the material for the germ-layers is laid down during an overgrowth and ingrowth of cells which takes place at the lip of the blastopore during the formation and closure of the latter. This closure is always bilaterally symmetrical, beginning at the dorsal lip and taking place most actively there, less actively at the lateral lips, and least of all at the ventral lip. It leads to the formation of a bilateral archenteron, the extent of which is greatest anteriorly, least posteriorly. The layer that now remains outside is the ectoderm. The notochord is differentiated out of the roof of the archenteron in the middle line in front of the dorsal lip, while the mesoderm sheets which flank the notochord pass back to the lateral lips and are confluent with one another behind the ventral lip.

A, 1-3, The closure of the blastopore in such a form as the frog; 1, 2, before, 3, after rotation of the egg. The blastoderm, or small-celled area, is heavily stippled. Its whole edge, which becomes the lip of the blastopore, is represented by a thick continuous line. *d.l.*, dorsal, *v.l.*, ventral lip.

B, 1-3, Three similar stages in such a form as *Lepidosiren*, where the ventral lip is absent. Only that part of the edge of the blastoderm which becomes converted into a blastoporic lip—namely, the posterior and immediately adjacent parts—is indicated by the thick continuous line. *d.l.*, dorsal lip.

c, 1, 2, The condition seen in the *Gymnophiona*, where still less of the edge of the blastoderm—only a small part at the posterior end, represented by the thick line—becomes the lip of the blastopore, but the lateral lips swing back, meet, and fuse to form the ventral lip, *v.l.* Thus the yolk (white) remains uncovered.

D, 1, 2, The Amniote blastopore. The heavily stippled area is the embryonic shield, the central portion only of the Amniote blastoderm, but the equivalent of the whole blastoderm of the Anamnia. From the posterior part of its margin a blastoporic lip is formed (*d.l.*, dorsal lip), and by the bending back and union of the lateral lips a ventral lip (*v.l.*), as in the *Gymnophiona*.

The lightly stippled area outside this represents the extra-embryonic portion of the blastoderm, which is equivalent to the yolk-cells immediately surrounding the blastoderm of the *Gymnophiona*.

This rests on the unsegmented yolk (white). Thus the blastopore of the Amniote is formed inside its blastoderm, but at the edge of what is equivalent to the Anamniotic blastoderm, namely, the embryonic shield.

The yolk is finally covered later on by the growth of the blastoderm.

So far there is general agreement. There is, however, a very serious difference between the two great groups of Vertebrates in respect of the relation of the blastopore lip to the blastoderm—the cap of cells produced at the end of segmentation in a large-yolked egg or the area of small cells in a small-yolked egg—for in the Anamnia the blastopore arises from the edge of this blastoderm (Fig. 94, A), while in the Amniota it arises inside it (Fig. 94, D). By the help of the Gymnophiona, however, the second condition may without difficulty be derived from the first.

In the Gymnophiona (Fig. 94, c) (1) the blastoderm is an oval area of columnar cells resting upon and surrounded by a partially segmented yolk. (2) Only a part of the edge of the blastoderm is converted into a blastopore lip, namely, a small region at the posterior end. Here a dorsal lip is formed and lateral lips quickly follow; the lateral lips then turn back, encircling a small area of the yolk, behind which they meet and fuse to form a ventral lip to the now circular blastopore. In this process the anterior margin of the blastoderm is wholly unconcerned. (3) The archenteron opens into the segmentation cavity, notochord and mesoderm are derived from its roof, the endoderm from the yolk-cells which lie in its floor. The notochord stretches in front of the dorsal lip; the mesoderm sheets springing from the lateral lips are continuous with one another behind the ventral lip.

As a result of this peculiarity in the formation of the ventral lip the yolk remains uncovered. In all other Anamnia, however, where the ventral lip is developed from the anterior edge of the blastoderm, the yolk is necessarily covered up by the closure of the blastopore.

We turn now to the Amniota, to the Reptiles for instance, and find (1) that the embryonic shield is a circular or oval area of columnar cells resting upon a lower layer, and surrounded by a zone of flattened cells. (2) At the posterior margin of this embryonic shield upper and lower layers are continuous. Here a dorsal lip is formed and lateral lips quickly follow; the lateral lips turn back encircling a small area of the outer zone of cells—where these are continuous with the lower layer—behind which they meet and fuse to form (a virtual, in some cases an actual)

ventral lip to the now circular blastopore. In this process the anterior margin of the embryonic shield is wholly uneoneerned.

(3) The archenteron opens into the subgerminal cavity, notochord and mesoderm are derived from its roof, the endoderm from the lower layer. The notochord stretches in front of the dorsal lip, the sheets of mesoderm springing from the lateral lips are continuous with one another behind the ventral lip.

It seems clear, then, that the embryonic shield of the Amniota is the representative of the blastoderm of the Gymnophiona (and of all Anamnia), while the marginal zone of the upper layer, together with the lower layer with which it is at one point—the primitive plate—still united, represents the yolk-cells or nucleated yolk.

In passing from the Gymnophiona to the higher Vertebrates we have therefore to suppose that with the further increase of yolk segmentation has become restricted not to the blastoderm alone (as in Fishes), but to the blastoderm and those circumjaecnt and subjacent cells which in the Gymnophiona are partially segmented from the yolk. In the most primitive Reptiles the lower layer cells are still crowded with yolk and still retain a connexion, in the primitive plate, with the marginal cells of the upper layer. In other Reptiles, in Birds, and in Mammals this primitive connexion is lost, and it is only secondarily, after the formation of the primitive groove and streak, that the upper fuses with the lower layer.

The Gymnophionan condition must in turn be derived from some Anamnian blastopore in the formation of which the anterior edge takes no part, in which consequently no ventral lip is formed. Such a form may be found in *Lepidosiren* (Fig. 94, B), in which the yolk is less abundant than in the Gymnophiona, but more abundant than in the typical small-yolked egg. Here the formation of a blastopore is restricted to the dorsal and lateral lips. The absence of a ventral lip may be a very primitive feature, since none is found in *Petromyzon*.

It may also be noticed that the union of segmentation cavity with archenteron occurs here and there in various Anamnia, sometimes in *Rana*, and in *Petromyzon*, thus foreshadowing the condition seen in Gymnophiona and the Amniota.

In the Anamnia, indeed, the archenteron has a direct relation to the endoderm in that, after notochord and mesoderm have been differentiated, the alimentary canal is formed from its roof, or floor, or both. But as we pass up the series the archenteric cavity loses this significance, its lumen dwindles and finally disappears, and its function is reduced to the differentiation of notochord and mesoderm alone. The endoderm is then derived from the lower layer cells—representative of yolk-cells—which line the segmentation cavity.

The same lower layer cells may contribute to the notochord and mesoderm anteriorly, and this, as we have seen, is of constant occurrence in such small-yolked Anamnian types as the Amphibia, and *Petromyzon*; not, however, in the large-yolked eggs of Fishes.

THE SIGNIFICANCE OF THE GERMINAL LAYERS

It will have been repeatedly noticed that the same elementary organ or germ-layer may come into being by different processes. This is true of the front end of the notochord and mesoderm, and still more obviously of the endoderm, for the lining epithelium of the alimentary canal may be derived from the roof only of the archenteron (Elasmobranchs and Teleostei), from the floor only (*Petromyzon*, Urodela, *Ceratodus*), from both roof and floor (*Rana*, *Lepidosiren*), from the yolk-cells in the floor and from those in the segmentation cavity (*Gymnophiona*, occasionally *Rana*), or from the lower layer (yolk-) cells of the segmentation cavity alone (Amniota).

In considering such discrepancies in the mode of origin of homologous structures—and discrepancies of this kind are of common occurrence, not only in development from the egg but also in budding and regeneration—it must be borne in mind that experiment has shown the formation of the embryonic organs—such as the germ-layers—to be dependent on the presence of certain stuffs in the cytoplasm of the ovum, but that these stuffs are not necessarily deposited in the situations which will eventually be occupied by the organs to which they give rise, nor even in the same position in the ova of animals belonging to the same group. Thus they may occupy dissimilar

positions also in the segmented ovum, and again in the later stage which we speak of as gastrulation or the closure of the blastopore. The necessary materials—now cut up into cells—have then to move into their definite positions, and thus we witness the roof of the gut being formed by an upgrowth of yolk-cells, or its floor by a bending down of the roof of the archenteron.

The way in which an organ is developed is not, therefore, necessarily a criterion of its homologies. Homologous structures, that is, those derived, like the alimentary tract of the Vertebrate, from some common ancestral structure, may differ in their origin during individual development. The stuffs on which their differentiation depends are doubtless comparable, but the paths by which that differentiation is achieved may be diverse.

LITERATURE

R. ASSHETON. Professor Hubrecht's paper on the early ontogenetic phenomena in Mammals. *Quart. Journ. Micr. Sci.*, 1909.

E. VAN BENEDEN. Untersuchungen über die Blätterbildung, den Chordakanal und die Gastrulation bei Säugetieren. *Anat. Anz.* iii, 1888.

R. BONNET. Beiträge zur Embryologie des Hundes. *Anat. Hefte*, 1^{te} Abt. ix, 1897.

A. BRAUER. Beiträge zur Entwicklungsgeschichte der Gymnophionen. *Zool. Jahrb.* x, 1897.

BASHFORD DEAN. The early development of gar-pike and sturgeon. *Journ. Morph.* xi, 1895.

BASHFORD DEAN. On the embryology of *Bdellostoma stouti*. *Festschr. f. C. von Kupffer*, Jena, 1899.

L. F. HENNEGUY. Embryogénie de la truite. *Journ. de l'Anat. et de la Phys.* xxiv, 1888.

J. W. JENKINSON. Remarks on the germinal layers of Vertebrates and on the significance of germinal layers in general. *Mem. Manchester Lit. and Phil. Soc.* 1, 1906.

J. GRAHAM KERR. The development of *Lepidosiren paradoxa*. *Quart. Journ. Micr. Sci.* xlv, 1901.

K. MITŠUKURI and C. ISHIKAWA. On the formation of the germinal layers in Chelonia. *Quart. Journ. Micr. Sci.* xxvii, 1886.

J. RÜCKERT. Die erste Entwicklung des Eies der Elasmobranchier. *Festschr. f. C. von Kupffer*, Jena, 1899.

H. SCHAUINSLAND. Studien zur Entwicklungsgeschichte der Sauropsiden. *Zoologica*, xvi, 1903.

- R. SEMON. Die Furchung und Entwicklung der Keimblätter bei *Ceratodus forsteri*. *Zool. Forschungsreise in Australien*, 1901.
- A. E. SHIPLEY. The development of *Petromyzon fluviatilis*. *Quart. Journ. Micr. Sci.* xxvii, 1887.
- J. SOBOTTA. Die Gastrulation von *Amia alva*. *Verhandl. Anat. Gesellsch. Berlin*, 1896.
- C. O. WHITMAN and A. C. EYCLESYMER. The egg of *Amia* and its cleavage. *Journ. Morph.* xii, 1897.
- L. WILL. Die Entwicklungsgeschichte der Reptilien. *Zool. Jahrb.* vi, ix.
- H. V. WILSON. The embryology of the sea-bass (*Serranus atrarius*). *Bull. U. S. Fish Commission*, ix, 1889.
- J. T. WILSON and J. P. HILL. Observations on the development of *Ornithorhynchus*. *Phil. Trans. Roy. Soc.*, Series B, excix, 1907.
- H. E. ZIEGLER. Beiträge zur Entwicklungsgeschichte von *Torpedo*. *Arch. mikr. Anat.* xxxix, 1892.

FIG. 95.—External features of the development of the tadpole of the Frog.

a. Medullary plate, anterior end: the three divisions of the brain are apparent.

b. The same embryo from the posterior end: the sides of the medullary plate pass back on either side of the blastopore. The blastopore is now reduced to a narrow slit by the approximation of the lateral lips; at the dorsal and ventral lips the aperture is rather wider.

c. Medullary folds and groove, anterior end: the three divisions of the brain are readily seen, and the anterior part of what will be the spinal cord. External to the inner medullary folds are the outer, and these pass in front into the broad gill-plates, in front of which again are the sense-plates.

d. Closure of medullary folds, but the suture is still visible: the gill-plate is divided on each side into two, and in front of it is the sense-plate; behind the gill-plate is a slight constriction.


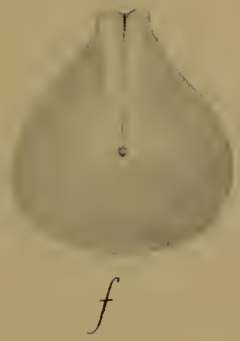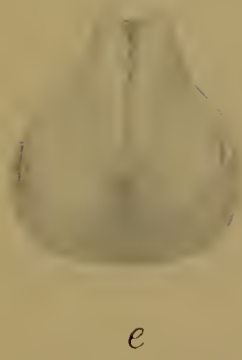
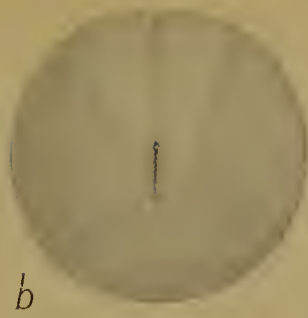
e. Anterior view of the same embryo: the medullary folds have not quite closed in front. Beneath their anterior end is a depression, the stomodaeum, and on either side of this the sense-plates; the gill-plates can just be seen behind these.

f. Posterior view of the same embryo: the medullary folds have closed over the dorsal division of the blastopore (neurenteric canal) while the ventral remains as the proetodaeum. The middle region of the blastopore is marked by a very narrow suture.

g. Later embryo from below showing the stomodaeum, in front of the V-shaped sucker, and posteriorly the proetodaeum at the base of the tail-stump.

h. Older embryo from the right side. The tail is rather longer, the proetodaeum at its base: the stomodaeum can be seen in front between the two halves of the sucker. At the side of the head in front is the nostril, behind the gill-slits.

i. Older embryo (ready to hatch) with well-developed tail and external gills.



CHAPTER VII

THE EARLY STAGES IN THE DEVELOPMENT OF THE EMBRYO

A. In the Anamnia

THE common frog affords a very good type of the development of the embryo from a small-yolked egg.

We left the frog's egg at the moment when the rotation was complete, the blastopore had been reduced to a small circle, and the material for the three germinal layers laid down and brought into position.

The circular blastopore soon becomes laterally compressed and so reduced to a narrow vertical slit, the yolk-plug being at the same time withdrawn into the interior. The opposite sides will in a little while meet together and fuse, so dividing the blastopore into a dorsal and a ventral portion. The dorsal portion will become the neurenteric canal. The ventral portion will close but reopen later as the proctodaeum or anus (Fig. 95).

Meanwhile, the rudiment of the nervous system has appeared in the form of a raised area of thickened ectoderm upon the dorsal side of the egg. This area is triangular or rather pear-shaped, being broad in front, narrow behind (Fig. 95, A). It is known as the medullary plate. From the broad anterior end the brain will be developed, from the narrow posterior end the spinal cord. The edges of the medullary plate fade away on each side of the slit-shaped blastopore (Fig. 95, B).

There presently appears in the middle line a groove running the whole length of the medullary plate, the medullary groove. In the brain region this is wide and divided by transverse ridges into three depressions, the rudiments of the fore-, mid-, and hind-brains, in the region of the spinal cord narrow. At the same time the edges of the medullary plate begin to rise up on each side as the medullary ridges or folds. These folds are each

divided longitudinally into two, an outer and an inner fold. The latter will form the wall of the medullary tube. The outer fold is especially wide and prominent in front, where it is divided by a slight transverse furrow into two areas, the sense-plate and the gill-plate (Fig. 95, c). The posterior part of the outer medullary fold is narrow.

The outer medullary fold is due to the presence below the surface of the neural crest, a ridge of ectodermal cells from which the ganglia of the spinal nerves and of some of the cranial nerves are derived. The sense-plate contains the material for the fifth and seventh cranial nerve ganglia, the gill-plate that for the ninth and tenth, while the posterior narrow portion gives rise to the spinal ganglia.

The inner medullary folds now approach one another in the middle line, meet and fuse (Fig. 95, d). The groove is thus converted into a closed canal, the medullary tube; from the wide anterior portion of this the ventricles of the brain will be formed, from the narrow posterior portion the canal of the spinal cord. At the extreme hind end, as we have already seen, the medullary folds pass into the sides of the blastopore. When they meet in this region they naturally cover over the dorsal half of the latter. The enteron therefore no longer opens to the exterior by means of the blastopore, but into the hinder end of the medullary tube. In this way the dorsal part of the blastopore is converted into a passage of communication between the nervous system and the gut: it has become the neurenteric canal (Fig. 95, f).

The ventral division of the blastopore is not covered by the medullary folds. It closes, but will reopen as the proctodaeum or anus.

The embryo now begins to elongate (Fig. 95) and a constriction appears behind the gill-plate separating the head from the trunk. At the anterior end and rather on the ventral side a depression is now seen—the stomodaeum or mouth invagination—and a little way behind this a V-shaped groove with prominent lips, the apex of the V pointing backwards. This is the cement gland or sucker. At the hinder end the proctodaeum is now visible in the place where the ventral division of the blastopore closed (Fig. 95, g).

The body is at this time ciliated ; by this means the embryo turns over and over inside the jelly.

The tail appears as an outgrowth of the posterior end above the proctodaeum (Fig. 95). Apparently single, the tail is in reality double, as it is due to the fusion in the middle line of two separate tail buds or caudal swellings. These two tail buds arise one on each side of the blastopore, and the lateral compression of the latter is in reality the approximation of the two buds. The double (bilateral) origin of the tail is clearly to be seen in those cases where, as by the application of some external agent (heat, salt solution, and so on), the blastopore is prevented from closing, the tail buds are unable to meet, and consequently the tadpole has two tails.

At the anterior end the olfactory pit is seen on each side. The front end of the head is obliquely truncated. The V-shaped sucker is now divided into two. The gill-plate has become subdivided by transverse furrows into three bars, the first, second, and third branchial arches. The hyoid and mandibular arches lie in the region of the sense-plate (Fig. 95, H).

The trunk is laterally compressed dorsally, but ventrally swollen out by the yolk in the floor of the gut. Later the tail grows longer and is provided with a ventral and a dorsal fin, the latter being continued into the trunk region. On the dorsal side of the body and in the tail the myotomes or muscle segments become clearly visible.

The embryo elongates still more (Fig. 95, I), the external gills are developed as branched filaments on the three branchial arches in regular order from before backwards, the eye and the divisions of the brain cause prominent swellings at the side of the head, while another lateral swelling—behind the gills—marks the position of the pronephros or larval kidney. The caudal fin becomes wider.

Soon after this the embryo hatches out of the jelly as the larva or tadpole. The mouth now opens and the tadpole, fastening on to the jelly by its suckers, begins to feed on it. The suckers, however, are transitory organs and soon disappear. The mouth becomes transversely elongated and provided with rows of horny teeth. The external gills are soon covered by the operculum,

a membranous fold growing back from the hyoid arch, which becomes fused with the body behind, leaving only one aperture, the spiracle, by which the water taken in at the mouth and passed out by the gill-slits can escape. This is on the left side. The external gills atrophy and are replaced by internal gills. Further details of the tadpole's structure and its metamorphosis into the frog do not, however, concern us here, and may be passed over.

We turn to the changes that have been taking place internally, and begin with the organs derived from the ectoderm. These are the epidermis and the nervous system and the sense-organs: the stomodaeum and proctodaeum may be considered with the alimentary canal.

The ectoderm is composed of two layers, an outer pigmented epidermal layer of columnar cells, and an inner nervous layer of polyhedral cells. Both layers are present in the medullary plate, but while the epidermal layer remains thin, the nervous layer is very considerably thickened, being composed here of six or more layers of cubical or columnar cells. The whole medullary plate is seen in section (Fig. 96, A) to be divisible into five tracts, a median, two internal lateral, and two external lateral. In the median tract the ectoderm is thin, in the lateral tracts it is thickened.

As the medullary folds rise up (Fig. 96, B), meet and fuse (Fig. 97), it is seen that the thin median tract becomes the floor of the medullary tube, the thick inner lateral tracts (which are the inner medullary folds) the thick side walls of the medullary tube, while the outer lateral tracts (the outer medullary folds) are carried up in the angle of the folds on either side as wedge-shaped masses of cells, the neural crests. When the folds have finally closed the outer layer of ectoderm is detached from the thin roof of the medullary tube, while the neural crests remain adherent to the latter. The neural crests are longitudinal ridges. Later they become transversely divided into segments in accordance with the segmentation of the mesoderm (see below). In the region of the spinal cord these segments become the ganglia and give rise to the dorsal roots of the spinal nerves. In the region of the brain they give rise to the roots and ganglia

of some of the cranial nerves, namely, the fifth, seventh, eighth, ninth, and tenth.

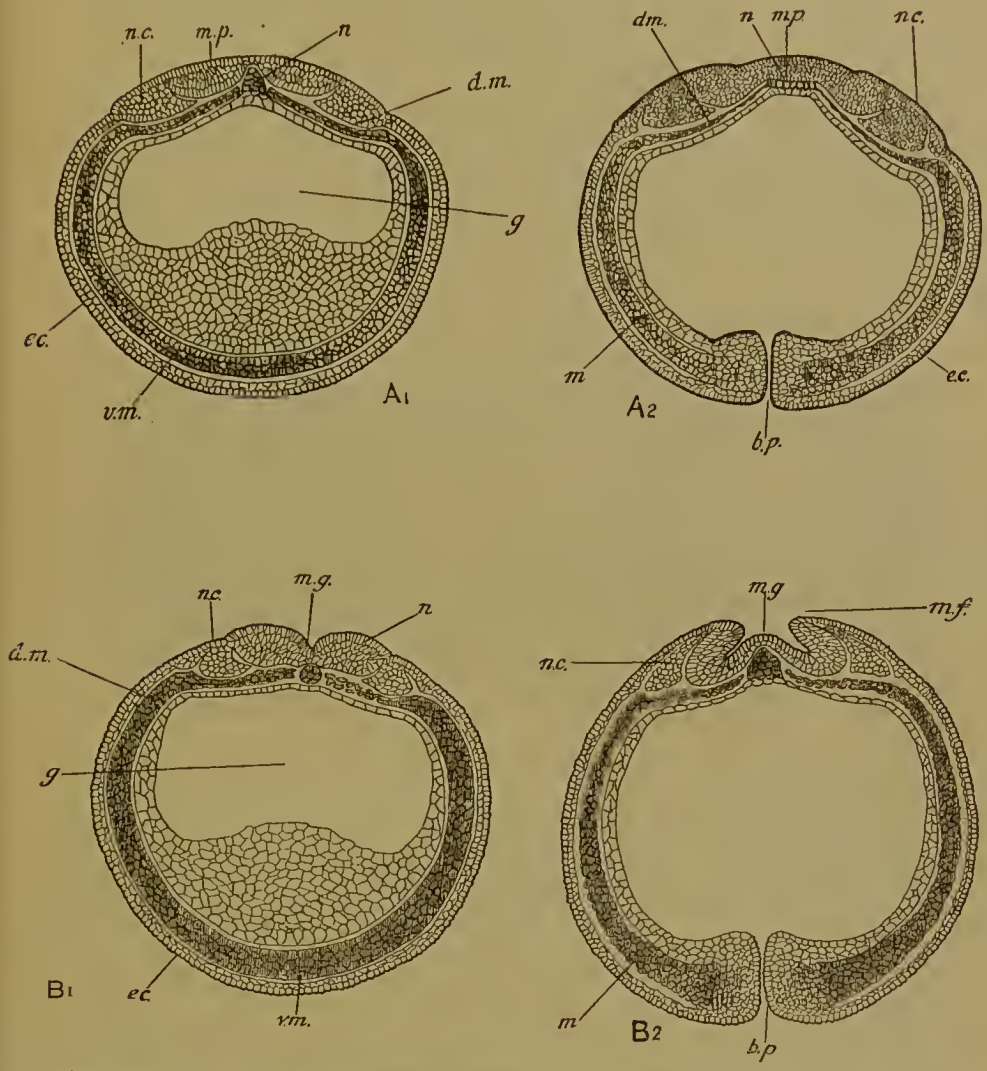


FIG. 96.—Transverse sections of the embryo of the frog at two succeeding stages, A and B. A1, B1, Sections transverse to the trunk. A2, B2, Sections transverse to the head and therefore cutting the blastopore (b.p.) behind. m.p., medullary plate; m.f., medullary fold; m.g., medullary groove; n.c., neural crest; n., notochord; m., mesoderm; d.m., dorsal mesoderm; v.m., ventral mesoderm; ec., ectoderm; g., gut. The mesoderm in this and the following figures is shaded.

The ventral roots of the spinal nerves are not formed from the neural crest, but by outgrowth of cells of the spinal cord. The third, fourth, and sixth cranial nerves (all purely motor) are

formed in the same way as ventral spinal-nerve roots. The first cranial nerve arises by outgrowth of the front end of the brain, while the fibres of the second grow back from cells in the retina. The retina is, however, itself a derivative of the brain, as we are now to see.

The brain, as pointed out already, is divided into fore-, mid-, and hind-brains (Fig. 98).

By what is known as the primary cranial flexure the fore-brain is in the embryo bent ventrally upon the mid-brain, so

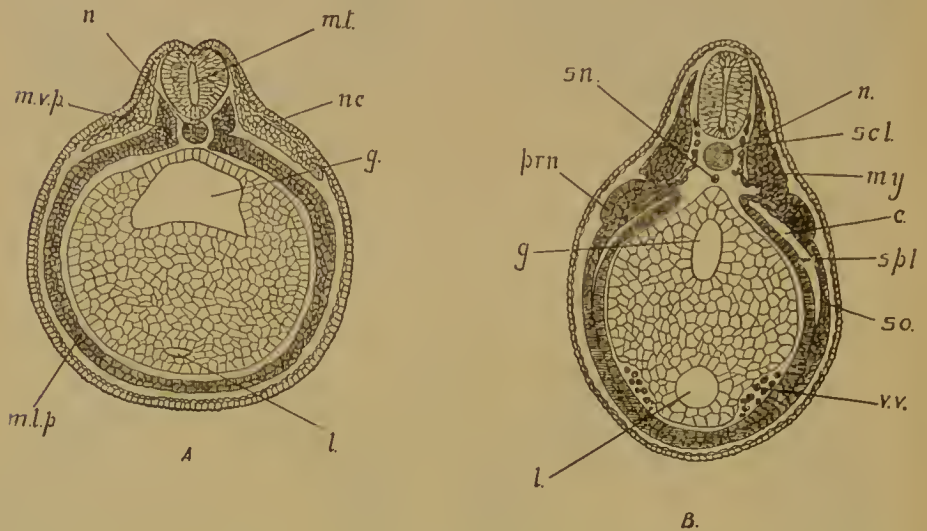


FIG. 97.—Transverse sections of frog embryos showing the further development of the nervous system and mesoderm. *m.t.*, medullary tube; *n.c.*, neural crest; *n.*, notochord; *s.n.*, sub-notochordal rod; *m.v.p.*, vertebral plate, *m.l.p.*, lateral plate of the mesoderm; *my.*, myotom; *scl.*, sclerotom; *c.*, coelom (splanchnocoel); *so.*, somatopleure; *spl.*, splanchnopleure; *prn.*, pronephric ridge; *v.v.*, vitelline vein; *g.*, gut; *l.*, liver.

that the latter is brought to the front end of the body (Fig. 98). The brain, however, soon straightens out again.

The hind-brain gives rise to the medulla oblongata and cerebellum, its cavity becomes the fourth ventricle; the mid-brain, whose cavity becomes the iter, gives rise to the optic lobes and crura cerebri, while the fore-brain becomes divided into the prosencephalon and thalamencephalon. The first comprises the two cerebral hemispheres, which are lateral outgrowths of the fore-brain, the rest of which then becomes the thalamencephalon; its cavity, the third ventricle, is produced into a hollow dorsal

outgrowth, the pincal body, a hollow ventral outgrowth, the infundibulum, and two ventro-lateral outgrowths in front of the infundibulum, the optic vesicles.

The optic vesicles (Fig. 99, A) are the rudiments of the retinae of the eyes. Each hollow outgrowth communicates at first by a wide aperture with the lumen of the fore-brain, but the aperture soon becomes narrowed to a tube, the optic stalk. The optic vesicle then becomes converted into the optic cup, by the pushing in of the outer and thicker wall (Fig. 99, B). The cavity

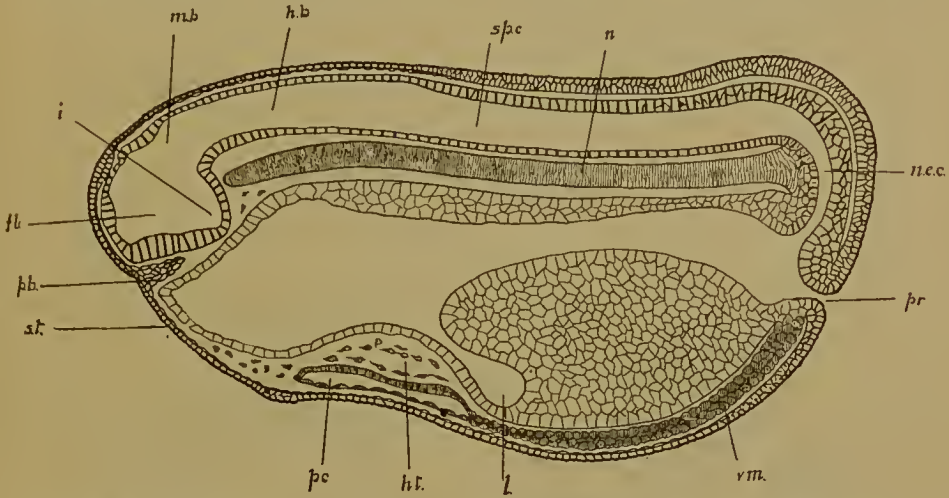


FIG. 98.—Median longitudinal section of a frog embryo, when the medullary tube has closed and the proctodaeum (*pr.*) has opened. *f.b.*, fore-brain; *i.*, infundibulum; *m.b.*, mid-brain; *h.b.*, hind-brain; *sp.c.*, spinal cord; *n.e.c.*, neurenteric canal; *n.*, notochord; *p.b.*, pituitary body; *st.*, stomodaeum; *pc.*, pericardium; *ht.*, heart; *v.m.*, ventral mesoderm; *l.*, liver.

of the vesicle is thus obliterated. It is essential for the due comprehension of the embryology and anatomy of the eye to observe that this inpushing is not confined to the outer surface of the optic vesicle, but is extended along its ventral surface as well. There is therefore an opening to the optic cup on its lower as well as on its outer side, and when the latter is closed by the lens the former remains as a narrow slit through which mesodermal structures—blood-vessels and the cells which secrete the vitreous humour—pass into the cup. This slit is the choroid fissure. The wall of the cup, from the mode of its formation, is composed of two layers: the outer, which is thin, consisting of one sheet of cells, becomes the pigment layer of the retina,

while the inner, which soon comes to consist of several sheets of cells, becomes the retina itself, except at the edge of the cup (Fig. 100). Here it remains thin, and together with the outer layer, with which it is continuous, gives rise to the ciliary processes and iris.

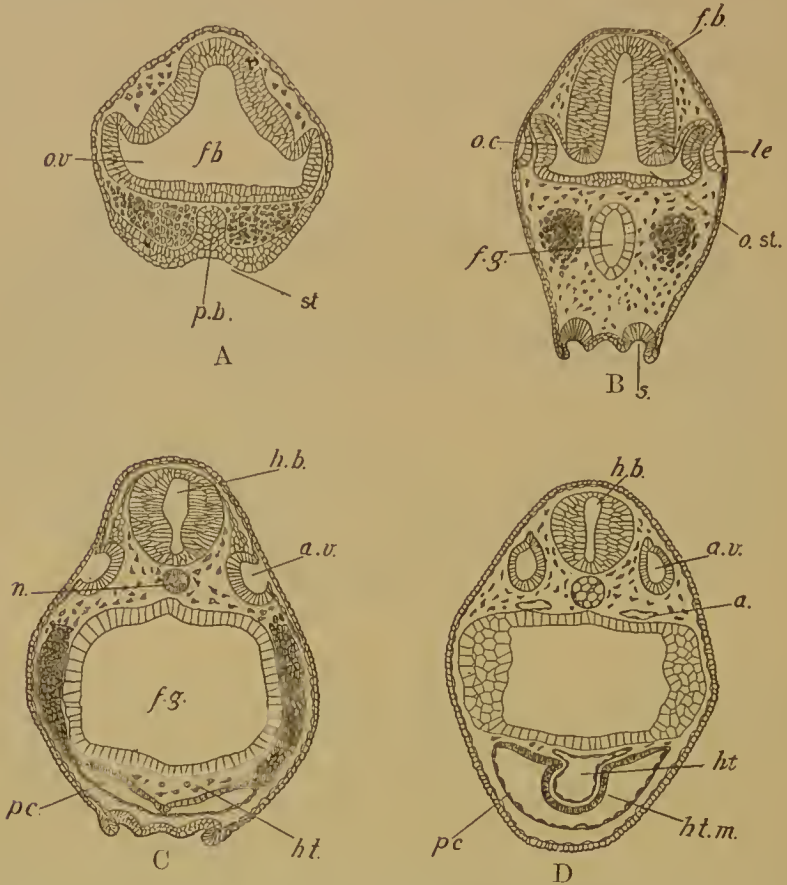


FIG. 99.—Sections illustrating the formation of the eye (A, B), ear, and heart (C, D) in the frog. *fb.*, fore-brain; *hb.*, hind-brain; *o.v.*, optic vesicle; *o.c.*, optic cup; *o.st.*, optic stalk; *le.*, lens; *p.b.*, pituitary body; *st.*, stomodaeum; *s.*, suckers; *n.*, notochord; *a.*, aorta; *a.v.*, auditory vesicle; *ht.*, heart endothelium; *ht.m.*, muscular wall of the heart; *pc.*, pericardium.

The lens is derived from the superficial ectoderm by invagination of the deep or nervous layer opposite the mouth of the cup. The invaginated cells become detached as a hollow vesicle, which is then fitted into the mouth of the optic cup. The cells of the outer wall of the lens vesicle remain cubical, and are the lens epithelium, but those of the inner wall become elongated into

the lens fibres. The cavity of the vesicle is thus obliterated. The sclerotic, choroid, vitreous body and cornea are all mesodermal structures; the first and second are formed from cells applied to the outer wall of the optic cup, the third from cells which migrate in by the choroid fissure, the fourth from cells which pass between the superficial ectoderm and the lens. The pigment soon disappears from this superficial ectoderm.

The muscles of the eyeball—recti and obliques—are derived from the mesodermal head somites, to which we shall refer later.

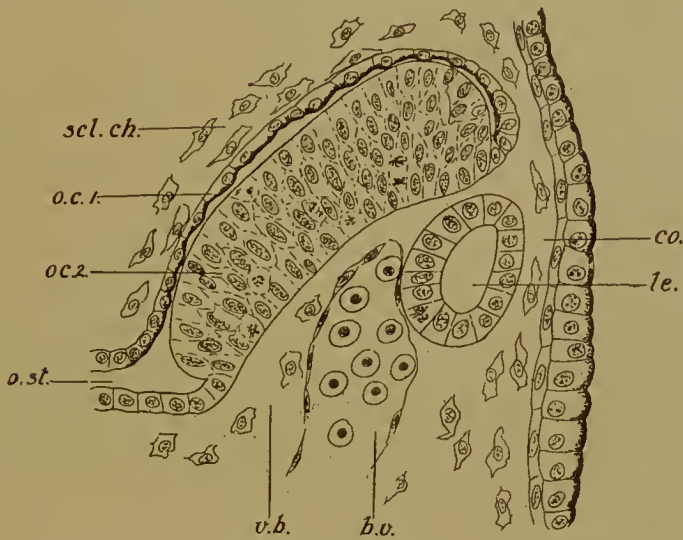


FIG. 100.—Section, transverse to the body, of the eye at a later stage. The section therefore passes down the length of the choroid fissure. *o.st.*, optic stalk; *o.c.1*, outer layer of optic cup (pigment layer of retina); *o.c.2*, inner layer of optic cup (retina); *le.*, lens; *co.*, cornea; *v.b.*, vitreous body mesoderm; *b.v.*, blood-vessel; *scl.ch.*, mesoderm which will form the sclerotic and the choroid.

The optic nerve-fibres are outgrowths of nerve-cells situated in the retina: the fibres pass out by the choroid fissure and back to the brain along the optic stalk. The stalk, therefore, merely serves as a guiding path to the fibres. The passage of the fibres through the choroid fissure explains the apparent perforation of the back of the eyeball by the optic nerve.

The olfactory pit (Fig. 104) arises by simple invagination of both layers of the ectoderm: it later becomes deepened to form the olfactory sac, the aperture being the nostril. The auditory vesicle—which will develop into the labyrinth or internal ear—

is formed, like the lens of the eye, by invagination of the nervous layer of the ectoderm (Fig. 99, c, d). Its connexion with the ectoderm is soon severed, the ductus endolymphaticus being the remains of the communicating passage.

The organs derived from the mesoderm are the muscular and skeletal systems, the connective tissue, the blood and vascular system, the coelom and urogenital organs.

We have seen how the mesoderm is laid down in the form of two sheets of tissue lying between the ectoderm and the endoderm, separated dorsally in the middle line by the notochord (and when it is formed, by the medullary tube as well), but continuous with one another below the gut (Fig. 96, A1, B1).

The first differentiation that occurs in the mesoderm is the separation on each side of a small dorsal portion—the vertebral plate—from a large ventral portion—the lateral plate (Fig. 97, A). The vertebral plates of the two sides are separated, but the lateral plates are continuous below. The vertebral plate soon becomes segmented transversely into a number of protovertebral or mesodermal somites, which give rise to the skeletal tissue and the muscles of the trunk and limbs. This segmentation begins at the front end and extends backwards, there being therefore for some time at the hind end and eventually in the tail a strip of unsegmented mesoderm (Fig. 101). The first mesodermal somite is found behind the auditory vesicle. In front of this the mesoderm is not compact, but composed of scattered cells, and no traces of segments are found. This is also true of all higher Vertebrates, but there is good reason for believing that virtual if not actual somites are present in this region, since in Elasmobranch fishes and in Cyclostomes head somites are clearly visible. The number of these somites is three, one in front of the mandibular visceral arch, one at the level of the mandibular arch, and one at the level of the hyoid arch. From these somites the recti and oblique muscles of the eyeball are formed.

The part of the head in which the mesoderm is thus cut up into somites comparable with the somites of the trunk is the posterior part, including the mid- and hind-brains and the anterior extremity of the notochord. It is of the greatest interest to observe that the cranial nerves which arise from these

two regions of the brain are also derived from segmental nerves, comparable, though not in every detail, with the segmental nerves of the trunk. We have already seen that in the trunk the neural crest becomes segmented, in conformity with the segmentation of the mesoderm, into a number of pieces, out of which the ganglia and dorsal roots of the spinal nerves are developed, while the ventral roots arise separately from the spinal cord. The neural crest is continued into the posterior region of the head and is divided into segments, the first of which lies between the first and second head somites and gives rise to the ramus ophthalmicus of the fifth nerve, the second between the second and third head somites and gives rise to the main branch of the fifth nerve, the third between the third head somite and first trunk somite and gives rise to the seventh and eighth nerves, the fourth between the first and second trunk somites and gives rise to the ninth nerve, while the fifth between the second and third trunk somites gives rise to the tenth nerve; the next segment of the neural crest becomes the ganglion and dorsal roots of the first spinal nerve.

It is clear, therefore, that the fifth, the seventh with the eighth, the ninth, and the tenth cranial nerves are developed in the same way as the dorsal roots of spinal nerves, and represent the dorsal roots of the nerves corresponding to the head somites and anterior trunk somites. The corresponding ventral roots—of the first, second, and third head somites—become the motor nerves innervating the eye-muscles, namely, the third, fourth, and sixth. These three are therefore the ventral roots of the same somites to which the fifth (two divisions) and the seventh with the eighth belong. The ventral roots corresponding to the ninth and tenth disappear (in the lamprey).

Hence the part of the head containing the anterior extremity

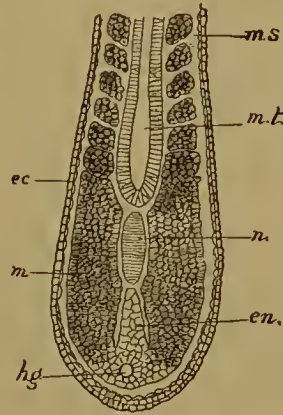


FIG. 101.—Horizontal section of the hind end of a frog embryo; *m.s.*, mesodermal somites; *m.*, posterior unsegmented mesoderm; *m.t.*, medullary tube; *n.*, notochord; *en.*, endoderm; *h.g.*, hind gut; *ec.*, ectoderm.

of the notochord and the mid- and hind-brains consists in reality of a number of trunk segments with their corresponding dorsal and ventral nerve roots, fused together and telescoped on to the back of a more anterior region which comprises the fore-brain with its sensory nerves, the olfactory and optic. The relations of these dorsal nerve roots, ventral nerve roots, and somites are shown in the accompanying table.

Segments of neural crest	I	II	III	IV	V	VI
Nerves derived from them	V ramus ophthal- micus	V main branch	VII and VIII	IX	X	dorsal root of 1st spinal

Meso-dermal Somites	Head Somites			Trunk Somites			
	Preman- dibular	Man- dibular	Hyoid	1st	2nd	3rd	4th
Ventral roots	I	II	III	IV	V	VI	
Nerves derived from them	III	IV	VI	dis- appears	dis- appears	ventral root of 1st spinal	

To return to the mesoderm. The somites remain for some little time connected to the lateral plate, each by a little neck of tissue, the intermediate cell-mass. These necks of tissue are, like the somites, metamericly segmented. They are a morphologically distinct part of the mesoderm of great importance, since from them is derived the whole of the system of kidney-tubules and ducts. For this reason they are termed the nephrotoms. The lateral plate mesoderm remains unsegmented and unpaired; it is continuous below the gut from the right side to the left, and also from the anterior end to the posterior.

The coelomic cavity soon appears, as a narrow space in the mesoderm (Fig. 97, B). It is not only found in the lateral plate, but extends into the intermediate cell-mass and somite. Three

distinct divisions of the coelom may therefore be recognized—the muscle coelom or myocoel of the somite, the nephrocoel, the canal of the nephrotom or intermediate cell-mass, and the splanchnocoel or gut-coelom in the lateral plate. The third of these extends ventrally below the gut and from the front to the hind end of the body. The three divisions of the coelom communicate freely with one another as long as the intermediate

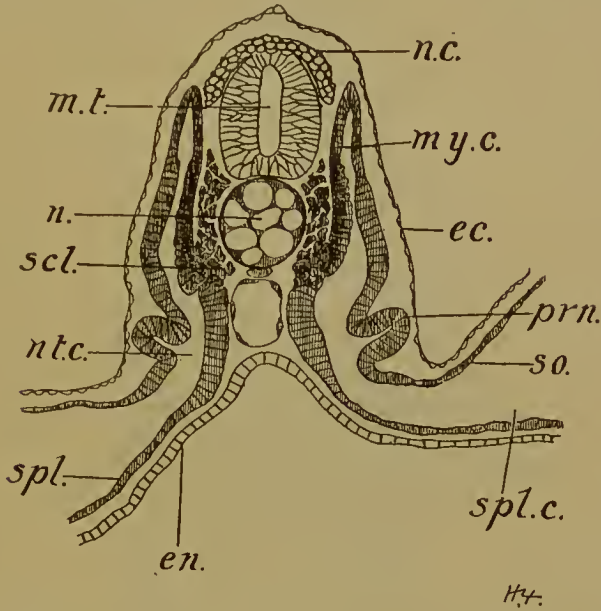


FIG. 102.—Transverse section of a dog-fish embryo, through the front end of the body. *m.t.*, medullary tube; *n.c.*, neural crest; *n.*, notochord; *my.c.*, myocoel; *scl.*, sclerotom; *nt.c.*, intermediate canal or nephrocoel; *prn.*, pronephric tubule growing out from the somatopleure of the nephrocoel; *spl.c.*, splanchnocoel; *so.*, somatopleure; *spl.*, splanchnopleure; *en.*, endoderm of gut (here open to yolk-sac).

cell-masses remain in connexion with the somites on the one hand and the lateral plate on the other. In the frog the relations of these parts are not so clear, as the intermediate cell-masses soon become detached from the somites and merged in the lateral plates, and the myocoel is smaller. They are, however, easily made out in, for example, an Elasmobranch embryo (Fig. 102).

From the ventral inner end of the somite the skeletal cells are produced, by simple emigration, or by outgrowth of a partially hollow mass, suggesting an evagination. These several segmental

groups of cells produced from the segmental somites are known as sclerotoms. The cells pass in and up, round the notochord and the medullary tube to form later the centra and neural and haemal arches of the vertebrae (Figs. 97 B, 102).

The remainder of the somite, now termed a myotom, gives rise to the muscles of the back, limbs, and body-wall. The

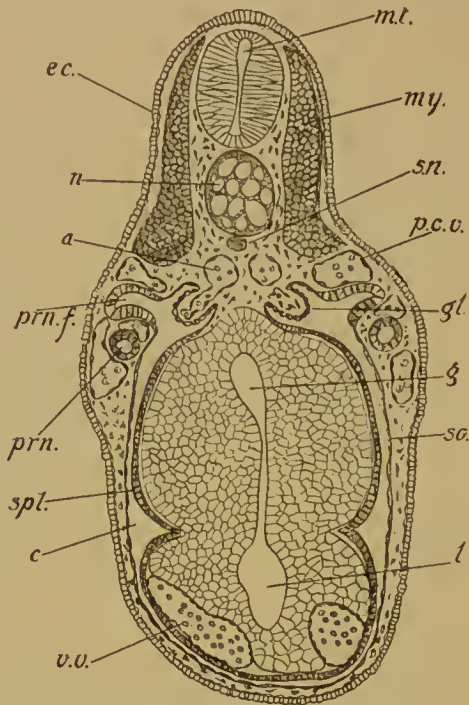


FIG. 103.—Transverse section of an advanced frog embryo. *mt.*, medullary tube; *n.*, notochord; *sn.*, sub-notochordal rod; *my.*, myotom; *a.*, aorta; *p.c.v.*, posterior cardinal vein; *prn.*, pronephric tubule; *prn.f.*, pronephric funnel; *gl.*, glomus; *c.*, coelom; *so.*, somatopleure; *spl.*, splanchnopleure; *g.*, gut; *l.*, liver; *v.v.*, vitelline vein; *ec.*, ectoderm.

myocoel disappears, the cells of the inner wall become differentiated as muscle fibres, while those of the outer wall form a connective tissue cutis.

From the nephrocoel the kidney is derived. Kidney tubules arise by outgrowth—hollow or solid—of the outer wall or somatopleure of the nephrocoel. In all cases the pronephros is the first part of the kidney system to appear (Fig. 97, B). In the frog the pronephros consists of three well-developed tubules, produced by outgrowth of the somatopleure of the nephrotom

(but after that has become merged in the lateral plate): each tubule opens by a ciliated funnel into the coelom, and at its other extremity into a longitudinal duct which in turn discharges its contents into the cloaca. The duct is split off from the somatopleure, from before backwards, its anterior end being *ab origine* in continuity with the outgrowths which give rise to the tubules. The pronephric tubules coil amongst the capillaries of the posterior cardinal vein. The glomus is a bunch of blood-vessels

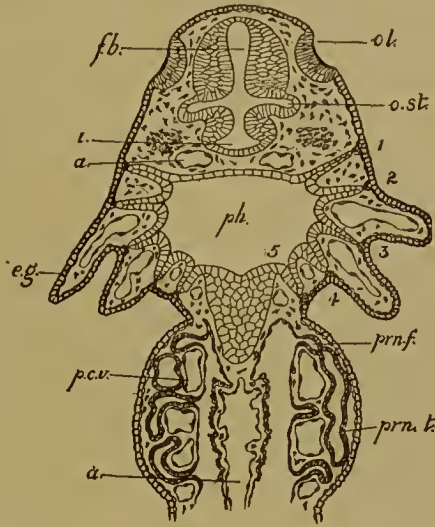


FIG. 104.—Horizontal section through the head of an embryo of the same age as the last. *ol.*, olfactory pit; *fb.*, fore-brain; *i.*, infundibulum; *o.st.*, optic stalk; *a.*, aorta; 1, 2, 3, 4, 5, the five gill-slits (hyomandibular and four branchial); *e.g.*, external gills on the first and second branchial arches. Those on the third are not yet formed. The mandibular arch lies in front of gill-slit 1, the hyoid in front of gill-slit 2. *ph.*, pharynx; *p.c.v.*, posterior cardinal vein; *prn.f.*, pronephric funnel; *prn.t.*, pronephric tubule.

hanging into the coelom at the root of the mesentery of the gut opposite the mouths of the pronephric tubules: its blood-supply is from the aorta. The pronephros is the larval kidney. The origin of the germ-cells has been described in a previous chapter.

The coelom of the lateral plate or splanchnocoel becomes the body-cavity of the adult. Its anterior end contains the heart, and is subsequently shut off as the pericardium from the posterior end or peritoneal cavity in which lie the gut, liver, kidneys, and gonads. When the lungs are developed and pushed into this

cavity it is pleuro-peritoneal. The epithelium lining it is of course the peritoneum, and reflected over the gut and other viscera. The mesentery of the gut is therefore a double layer of peritoneum. The coelom naturally divides the mesoderm into an outer and an inner layer. The former, next the body wall, is the somatopleure; the latter, near the gut, the splanchnopleure (Fig. 97, B). From the splanchnopleure come the muscles of the alimentary canal and of the heart.

The endothelial lining of the heart is derived from some scattered cells detached from the floor of the fore-gut (Fig. 99, c). As we have already seen, the ventral mesoderm is separated off from the yolk-cells which lie in the floor of the archenteron. The separation of these heart-cells is to be regarded as a later phase of the same process. The scattered cells soon unite to form a tube, the heart, which quickly pushes the splanchnopleure of the gut in front of it and so projects into the coelom, now the pericardium (Fig. 99, D). The splanchnopleure surrounding the endothelial tube becomes the muscular wall of the heart. For a short time the heart is attached to the ventral body-wall by a ventral mesocardium, but as soon as the two sides of the pericardium coalesce this disappears. At its anterior end the heart gives off the arterial arches: of these there are at first three, passing to the external gills on the first, second, and third branchial arches: later a fourth is added. These are the four afferent branchial arteries: from the gill capillaries the blood passes by the four efferent arteries into the two dorsal aortae, which are united only some way back into a single median aorta. In the frog there are no arterial arches in the mandibular and hyoid arches.

Posteriorly the heart receives the two ductus Cuvieri, bringing back the blood from the cardinal veins in the body-wall, and the two vitelline veins bringing blood from the liver and gut. These last are formed from the ventral surface of the gut in the same way as the endothelial cells of the heart, and are to be looked upon as retarded ventral mesoderm. Blood corpuscles are derived from the same source and immediately fall into the veins. Other blood-vessels, aortae, cardinal veins, and so on, are produced by the union of scattered mesoderm cells, that is, wandering cells

detached from the general mesoderm. Other cells detached in the same way form the connective tissue.

The notochord, which, we have seen, takes its origin at the same time and in the same way as the dorsal mesoderm, quickly assumes its characteristic histological features. It becomes cylindrical, the cells flat and discoidal, placed at right angles to the length of the notochord, and highly vacuolated. The notochord is surrounded by a delicate cuticular sheath, the chordal sheath or *membrana elastica interna*. Round it the vertebral column is laid down by the skeletal cells of the sclerotoms. Anteriorly the notochord terminates at the pituitary body behind the fore-brain.

The alimentary canal is derived from the endoderm, with the exception of the short stomodaeum and proctodaeum.

From the dorsal side of the stomodaeum the pituitary body grows, as a cord of ectodermal cells, up towards the infundibulum to which it becomes attached. By the formation of the floor of the skull it is shut off from the mouth (Figs. 98, 99 A).

From the endodermal lining of the alimentary canal come the thyroid, gill-slits, thymus, lungs, liver, pancreas, and bladder. The gill-slits are endodermal outgrowths met by slight ectodermal ingrowths. There are five in the tadpole, the hyomandibular and four branchial (Fig. 104). The hyomandibular is never open. The remaining become perforated and functional.

The first or hyomandibular persists as the Eustachian passage.

The gill-arches alternate with the gill-slits. The mandibular lies in front of the first, then come in order the hyoid and four branchial arches. The arterial arches (of which in the frog there are only four pairs) run in the branchial arches.

The thyroid is a median ventral diverticulum of the pharynx opposite the second gill-slit. The thymus is formed from dorsal epithelial remains of the gill-slits. The carotid gland and the epithelial corpuscles are ventral epithelial remains. The parathyroid is a rudimentary sixth gill-slit. Lungs, liver, pancreas and bladder arise as ventral diverticula of the gut.

The mass of yolk-cells in the floor of the gut of the embryo becomes slowly absorbed. While present it forms what might almost be termed a yolk-sac.

In the forms with large-yolked eggs, Myxinoids, Elasmobranchs, and Teleosts, there is a well-developed yolk-sac. The embryo is developed from the median and posterior area of the blastoderm before that has spread over the yolk, and is folded off from it. The extra-embryonic blastoderm then encloses the yolk, the sac so formed being attached by a narrow (Elasmobranchs) or wide (Teleostei) yolk-stalk to the body (see above, Figs. 71, 72). The ectoderm of the embryo is thus continuous with that of the yolk-sac, the endoderm passes out on to the yolk, and a layer of mesoderm extends in between these two.

The general development of the embryo itself is quite similar to that in small-yolked forms, and only one or two points need to be mentioned. The tail is paired in origin, being formed by the coalescence of the two caudal swellings. The tail grows back freely above the surface of the yolk. On its upper surface is the hinder end of the medullary tube, on its lower side the tail gut or post-anal gut. This is formed by the bending down of the sides of the archenteric roof—after separation of the notochord and mesoderm—until they meet and fuse ventrally. At the hind end—the dorsal lip of the blastopore—all three germ-layers unite in a common cell-mass, and behind this point the medullary tube and post-anal gut are in communication by a neurenteric canal.

The heart is formed, after the fore-gut has been folded off from the yolk-sac, in the same way as in the frog, as a single median tube. The nervous system usually arises by medullary folds, but in Teleostei, *Petromyzon*, *Lepidosteus*, and *Lepidosiren* there is a solid wedge-shaped ingrowth of ectoderm along the middle dorsal line (see above, Figs. 65 C, 75 A). In this the cavity of the medullary tube appears later on. The rudiments of optic vesicles, auditory vesicles, and olfactory pits are similarly solid at first.

The yolk-sac is provided with an area vasculosa of blood-vessels by which the food material is conveyed to the body of the embryo. In Elasmobranchs there are in this area at first two venous rings, one peripheral—the sinus terminalis—and connected with the subintestinal vein of the embryo at the root of the tail; the other central, pouring its blood directly into the heart. The latter becomes converted into an arterial ring by

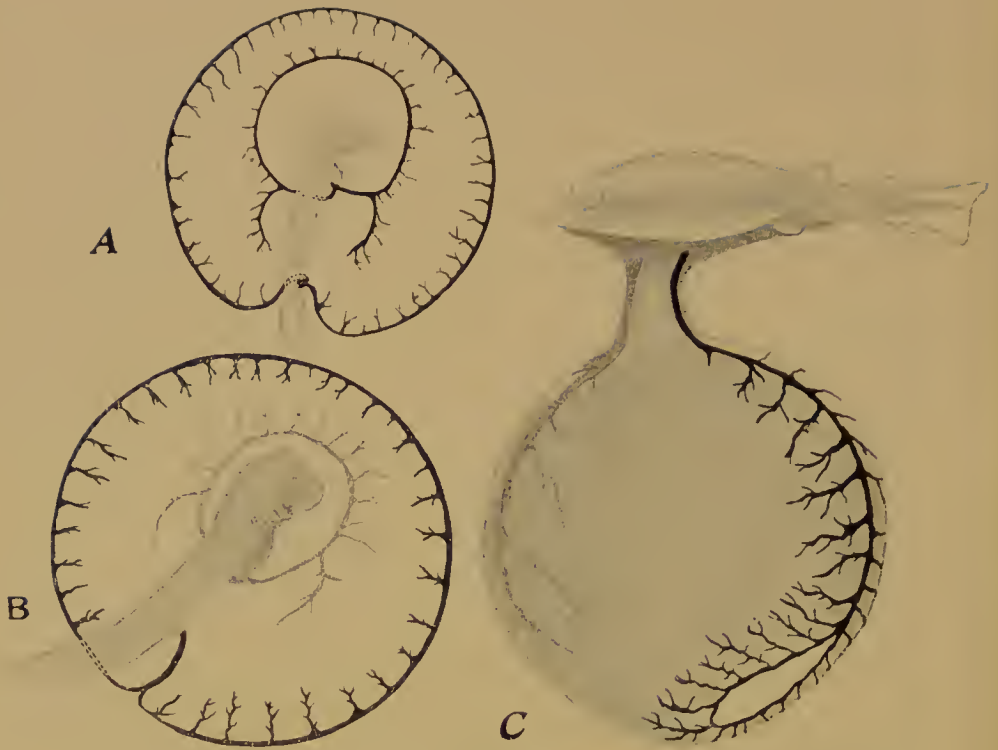


FIG. 104*.—Development of the area vasculosa in the Elasmobranch *Torpedo*. (After Rückert.)

A, Early stage. There are two venous rings; the external one (sinus terminalis) at the edge of the blastoderm opens into the sub-intestinal veins of the embryo behind; the internal ring opens into the heart in front.

B, Later stage when the internal ring has become arterial, being now connected to the aorta.

C, Last stage, when the arterial ring has become modified to form the anterior median artery (stippled) while the sinus terminalis is reduced to a small ring as the blastoderm encloses the yolk.

being connected directly to the aorta, disconnected from the heart. The arterial ring then becomes broken into two arteries, which finally fuse by their bases into a single median stem. As the blastoderm encloses the yolk the marginal sinus terminalis is correspondingly reduced (Fig. 104*).

B. In the Amniota.

In all Amniota the embryo is developed from the central area of the blastoderm only, the remainder being extra-embryonic.

This central embryonic area is at first spread out flat like the rest of the blastoderm—but as the embryo is developed it becomes gradually folded and constricted off from the surrounding blastoderm, as in the large-yolked Fishes. Here, however, the process is complicated by the development of the amnion, a sac enclosing the body of the embryo. The development of the chick may be taken as typical.

As we have already seen, the blastoderm of the chick at the beginning of incubation consists of an upper and a lower layer. The upper layer is a columnar epithelium; the lower layer is a sheet of scattered cells. At its edge the blastoderm rests upon the yolk, with which its marginal cells are continuous: in the yolk immediately surrounding the blastoderm are numerous nuclei, without cell-divisions. This nucleated ring is the syncytium or germinal wall.

Between the upper and lower layers is the segmentation cavity, and between the lower layer and the yolk the subgerminal cavity (continuous with and a part of the segmentation cavity).

After incubation has been in progress for a short time the lower layer cells unite to form a definite membrane or lower layer. The segmentation cavity is now separated from the subgerminal cavity. Marginally the lower layer is continuous with the germinal wall and with the upper layer. The blastoderm grows over the yolk by nuclear and cell division in this marginal zone, and several layers of cells are formed. At the surface is a layer continuous on the one hand with the upper layer of the blastoderm, on the other by its extreme marginal cells with the yolk. Underneath this are several layers of cells continuous with the lower

layer of the blastoderm : the lowermost cells and the marginal cells are still continuous with the nucleated yolk or syneytium.

The subgerminal cavity below the central area of the blastoderm gives to it a transparent appearance ; this area is hence known as the area pellueida ; but the marginal zone, resting directly on the yolk, is opaque, and termed the area opaea. The extension of the subgerminal cavity is less rapid than the cell-division going on in the marginal zone, hence the area opaea increases more quickly than the area pellueida and soon forms a broad zone round about it (Fig. 106, A). The area pellueida meanwhile becomes pear-shaped, the broad end being anterior, and soon the first sign of the embryo appears (about the twelfth hour of incubation) in the form of the primitive streak, a dark median line in the posterior part of the area, down the axis of which runs the primitive groove (Fig. 105).

The area pellueida—and therefore later the embryo—is always oriented in a definite way with regard to the egg-shell, in which the ovum is so placed that the long axis of the pear-shaped area pellueida lies transversely to the long axis of the shell, while the broad anterior end is away from the observer when the blunt end of the shell is on his left.


As we already know, the primitive groove is an elongated laterally compressed blastopore, and the primitive streak the mesoderm produced at its sides and hinder end, the notochord being given off in front. (To the notochord the term ‘head process of the primitive streak’ has been applied.)

The sheets of mesoderm grow forwards on the right and left, flanking the median notochord ; at the anterior end—in front of where the head of the embryo will be—they diverge somewhat, leaving between them a space in which the ectoderm rests directly upon the endoderm. This space is known as the proamnion. In front of the proamnion the mesoderm-sheets (at a later stage) meet and fuse, and eventually the proamnion is invaded by mesoderm and so disappears. Meanwhile a third area—the area vaseulosa—has begun to appear between the pellueida and the opaea (Fig. 106).

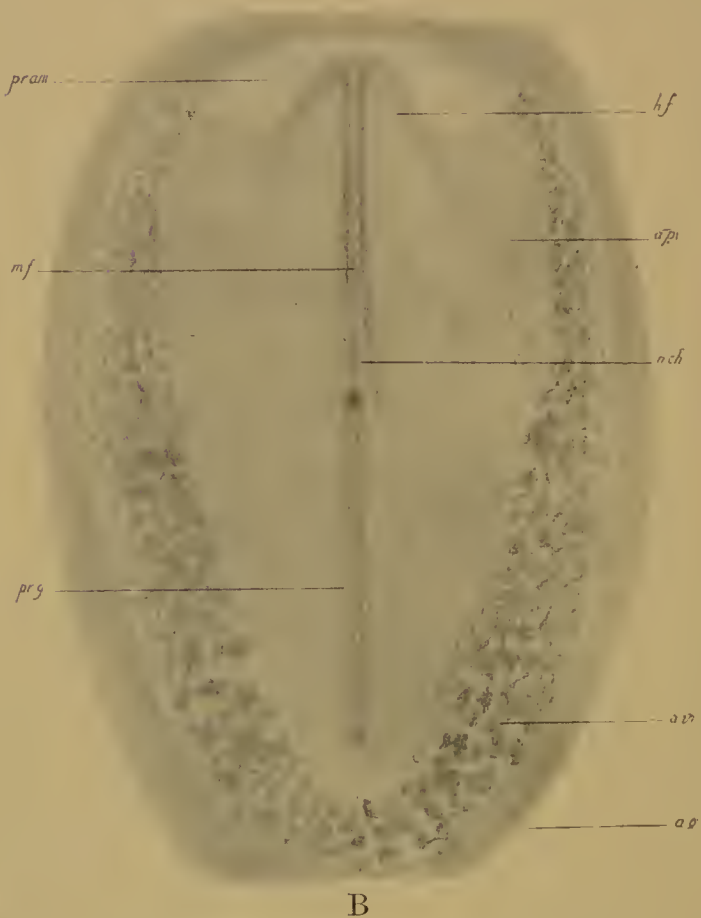
The vaseular area is first seen in the form of blotches of tissue along the inner edge of the area opaea, behind and at the sides



FIG. 105.—Area pellucida of the hen's egg. A, After 12 hours', B, After 18 hours' incubation, as seen by transmitted light. *pr.g.*, primitive groove; *n.ch.*, notochord; *pr.am.*, pro-amnion.



A



B

FIG. 106.—A, Blastoderm of the hen's egg after 20 hours' incubation. *h.f.*, head-fold of the embryo; *a.p.*, area pellucida; *a.v.*, area vasculosa; *a.o.*, area opaca.

B, Embryo, area pellucida, and area vasculosa of the same blastoderm. *m.f.*, medullary folds. Other abbreviations as before. Both as seen by transmitted light.

of, but not in front of, the area pellucida. These blotches are the blood-islands. They are formed from the masses of cells in

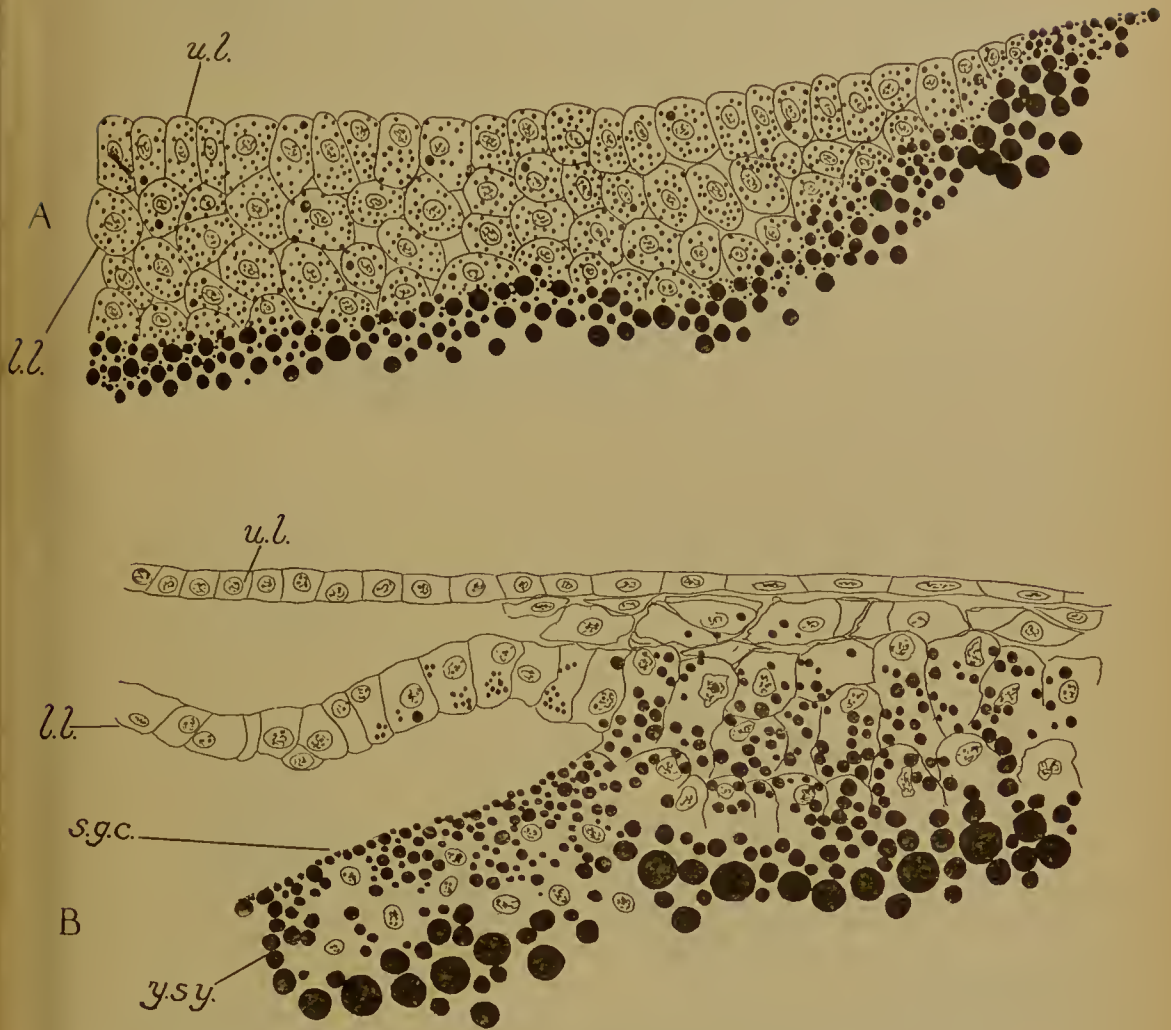


FIG. 107.—A, Edge of the blastoderm of the unincubated hen's egg. *u.l.*, upper layer; *l.l.*, the lower layer cells in several sheets, the lowermost of which is continuous with the yolk.

B, Edge of the blastoderm after 15 hours' incubation. *u.l.*, upper layer; *l.l.*, lower layer continued into the mass of cells lying on the yolk (area opaca). The lowermost of these cells are continuous with the yolk. In the yolk are also nuclei with no cell-boundaries, the yolk-syncytium (*y.s.y.*). This extends a little way below the subgerminal cavity (*s.g.c.*).

the area opaca which lie between the upper layer above and the nucleated yolk below, between the lower layer on the central side and the nucleated yolk again on the peripheral side (Fig. 107).

The cells become closely packed in groups, which are the blood-islands: from them the blood-vessels and blood-corpuseles of the area vasculosa are derived (Fig. 108). In each group the outermost cells become arranged in a thin flat epithelium—which becomes the endothelium of a capillary vessel—while the

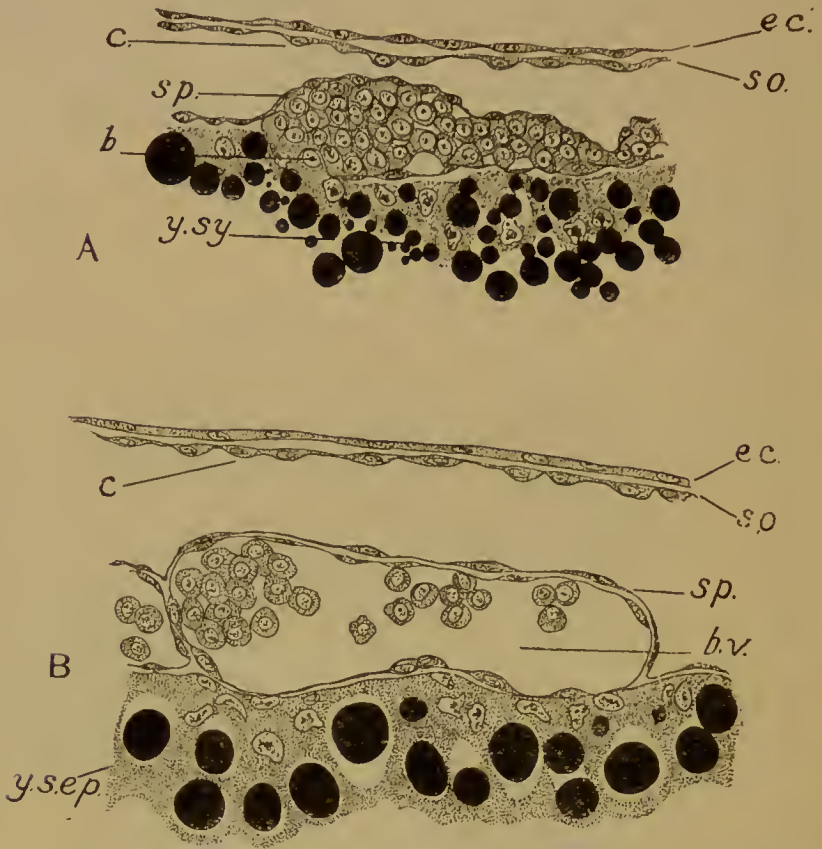


FIG. 108.—Formation of a blood-vessel (B) from a blood-island (A). *b.*, blood-island; *b.v.*, blood-vessel; *ec.*, ectoderm; *so.*, somatopleure; *c.*, coelom; *sp.*, splanchnopleure; *y.sy.*, yolk-synectium; *y.sep.*, yolk-sae epithelium.

rounded cells inside are the corpuseles. By the secretion of fluid cavities appear in between these cells, and the cavities run together to form the lumen of the capillary, inside which the corpuseles float freely. By the anastomosis of the blood-islands with one another the network of vessels of the area vasculosa is formed. The vessels soon come into connexion with others formed in the area pellucida.

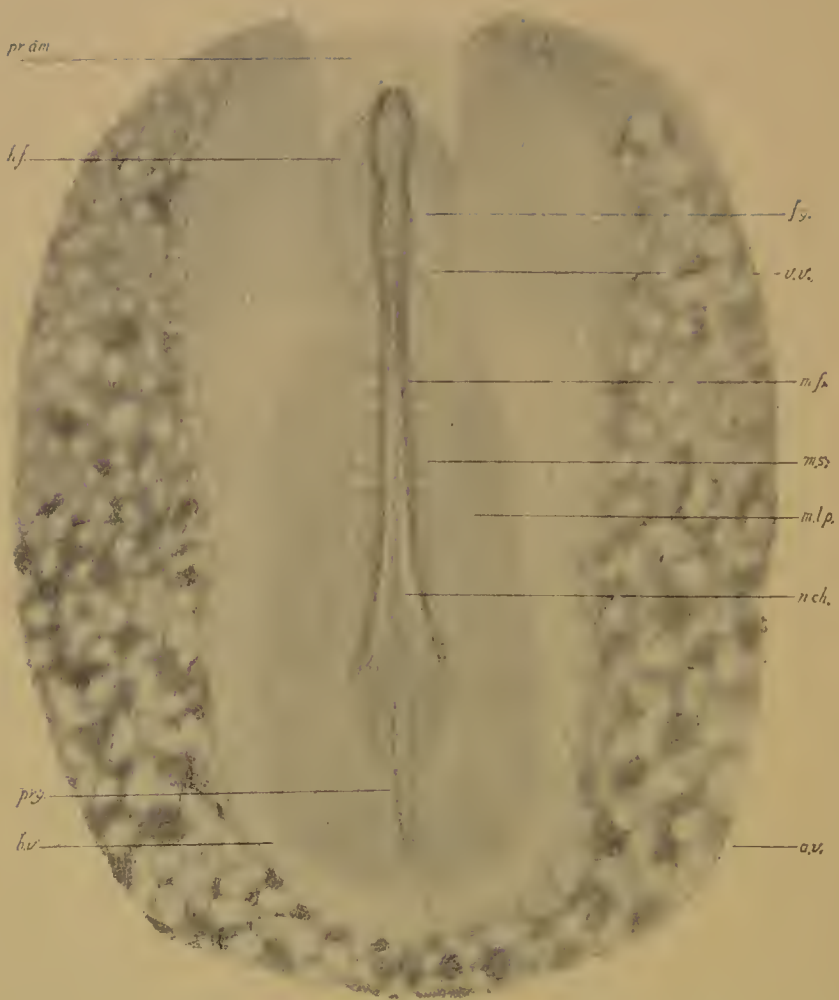


FIG. 109.—Chick with area pellucida and area vasculosa after 24 hours' incubation. *f.g.*, fore-gut; *v.v.*, vitelline vein; *m.s.*, mesodermal somite; *m.l.p.*, mesoderm of lateral plate. Other letters as before. As seen by transmitted light.

There is an evident similarity between the mode of formation of these vessels and corpuscles and the origin of the blood-corpuscles and endothelium of the vitelline veins in the frog. As these vessels and their corpuscles are derived in the frog from the large yolk-laden cells of the gut, so here the blood-islands arise from the thickened margin of the lower layer or endoderm : and just as in the former case, so in the latter we may consider this to be a retarded development of mesodermal structures from the yolk-cells.

In the meantime the outline of the body of the embryo has begun to appear in the form of the medullary plate (Fig. 109). This lies in front of the primitive groove. The notochord and mesoderm extend beneath it.

Down the middle of the plate the medullary groove is soon formed, bordered on each side by the medullary folds, which diverge behind and then pass inwards into the sides of the primitive groove. In front the groove is wide, and divides later on into the three regions of fore-, mid-, and hind-brains ; behind it is narrow, the spinal cord. By the fusion of the folds the groove is converted into the closed medullary canal.

The head of the embryo now begins to be lifted up and folded off from the blastoderm. This is known as the head-fold of the embryo (Figs. 109, 111). By an exactly similar process lateral folds and a tail-fold are formed, and so the whole body of the embryo is gradually constricted off from the blastoderm. We shall see later that the gut of the embryo, which is at the same time and in the same way folded off from the yolk-sac, remains connected to the latter by the yolk-stalk, but that the body-wall of the embryo is united with the amnion.

Before the embryo has been folded off from the blastoderm there is no ventral side to its body : the ventral side can only be made by the folding off, during which process parts which lie in front, at the sides of, and behind the embryonic area are bent underneath it.

The head of the embryo is immediately over the mesoderm-free area, or proamnion. In front of this there soon rises up a fold of the extra-embryonic blastoderm. This is the head-fold of the amnion. It grows back, as a sort of hood, over the head

and body of the embryo: presently it is met by side-folds and a tail-fold, and eventually all the folds meet over the back of the embryo in the posterior region, and the amnion becomes closed.

The mesoderm undergoes the same differentiation that we have made ourselves familiar with in the frog (Fig. 110). It becomes divided on each side into a vertebral plate next the notochord and medullary tube, and a lateral plate which extends outwards into the extra-embryonic region of the area pellucida and finally into the area vasculosa. The vertebral plate is

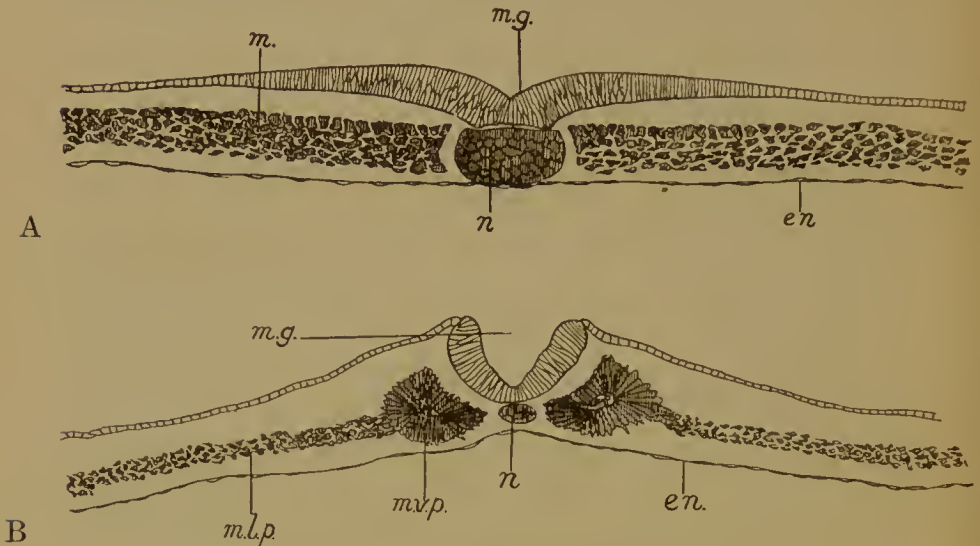


FIG. 110.—Chick. Differentiation of the mesoderm. A, Posterior; B, Anterior section of the blastoderm at 24 hours. *m.g.*, medullary groove; *n.*, notochord; *m.*, mesoderm; *m.l.p.*, lateral plate; *m.v.p.*, vertebral plate; *en.*, endoderm.

segmented into somites. The separation and segmentation of the vertebral plate take place in regular order from before backwards, so that at the hinder end there is a strip of mesoderm still unsegmented and still united with the lateral plate, and passing back to the primitive groove (Fig. 109).

The first somite is at the side of the hind-brain—immediately behind the auditory vesicle, but, as already stated, there is every reason to believe that virtual if not actual somites exist in the mesoderm in front of this.

Each somite remains connected to the lateral plate for some time by an intermediate cell-mass or nephrotom. From the

nephrotoms are produced the kidney tubules (Figs. 112, 118). The anterior tubules or pronephros are rudimentary in the chick (and in all Amniota), but the segmental duct is formed from their union. The mesonephric or Wolffian tubules are, however, well developed, and function as the embryonic kidney. The adult kidney or metanephros is formed from more posterior tubules.

The coelom comprises the myocoel of the mesodermal somite, the nephrocoel of the nephrotom, and the splanchnocoel of the lateral plate (Fig. 110). The first soon disappears. The somite

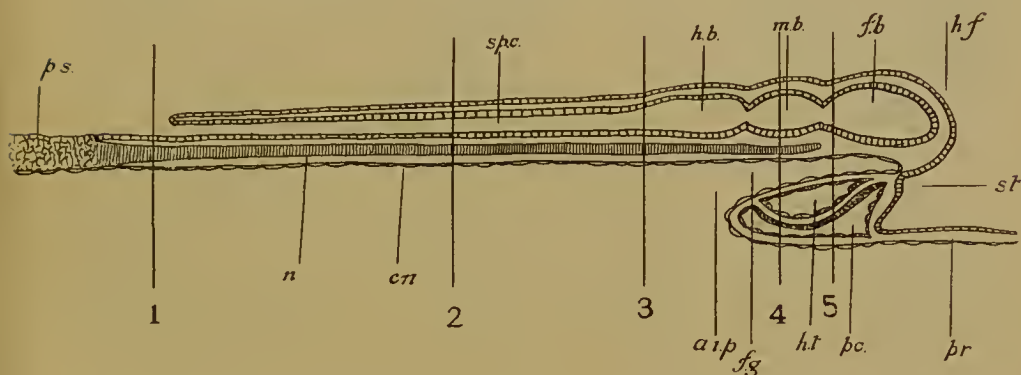


FIG. 111.—Diagram of a longitudinal section of a chick of about 30 hours, to show the folding off of the head of the embryo from the blastoderm, the folding off of the fore-gut from the yolk-sac, and the position of the heart. *h.f.*, head-fold of embryo; *f.b.*, fore-brain; *m.b.*, mid-brain; *h.b.*, hind-brain; *sp.c.*, spinal cord; *p.s.*, primitive streak; *n.*, notochord; *en.*, endoderm; *f.g.*, fore-gut; *a.i.p.*, anterior intestinal portal; *st.*, stomodaeum; *h.t.*, heart; *p.c.*, pericardium; *pr.*, proamnion. 1–5, The planes of the sections shown in Fig. 112.

is differentiated into sclerotom and myotom. The second persists as the cavity of the capsule of the kidney tubule. The third also persists. In the embryonic region it becomes subdivided into the pericardium in front and the pleuro-peritoneal cavity behind (in Mammalia the pleural cavities become of course separated by the diaphragm from the peritoneal cavity). In the extra-embryonic region it extends out to the edge of the mesoderm. Here, therefore, the somatopleure lies against the extra-embryonic ectoderm, the splanchnopleure against the (endodermal) epithelium of the yolk-sac. In the area vasculosa, therefore, the splanchnopleure lies over the top of the blood-

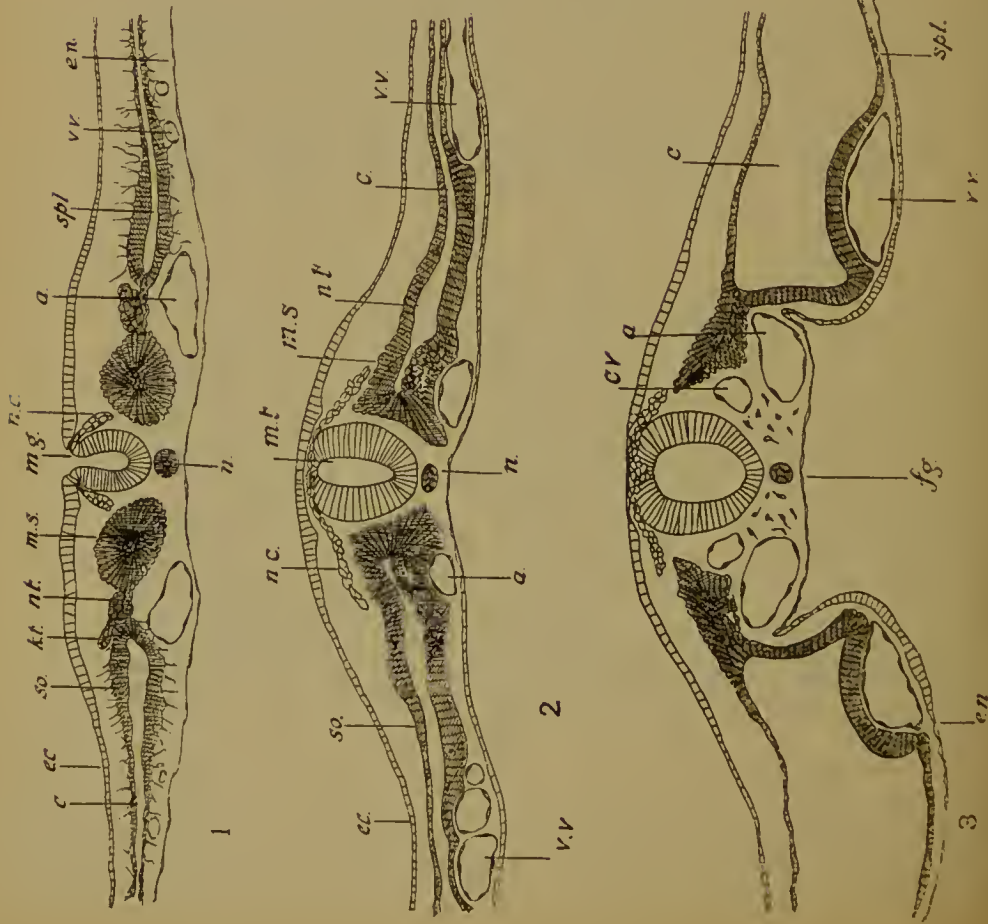


FIG. 112.—A series of five transverse sections through a chick of 30 hours, to illustrate the folding off of the fore-gut from the yolk-sac, and the coalescence of the two vitelline veins to form the heart. The planes of section are indicated in Fig. 115. 1 is posterior, 5 anterior. Labels: *ec.*, ectoderm; *so.*, somatopleure; *c.*, coelom; *spl.*, splanchnopleure; *mt.*, mesenteric tube; *m.g.*, medullary groove; *m.t.*, medullary tube; *v.v.*, vitelline vein; *en.*, endoderm; *n.*, notochord; *n.c.*, neural crest; *f.g.*, fore-gut; *ht.*, heart endothelium; *ht.m.*, muscular wall of heart; *p.c.*, pericardium; *a.*, auditory vesicle.

the sections are indicated in Fig. 115. 1 is posterior, 5 anterior. Labels: *m.s.*, mesodermal somite; *a.*, aorta; *c.v.*, cardinal vein; *m.g.*, medullary groove; *f.g.*, fore-gut; *v.v.*, vitelline vein; *en.*, endoderm; *n.*, notochord; *n.c.*, neural crest; *f.g.*, fore-gut; *ht.*, heart endothelium; *ht.m.*, muscular wall of heart; *p.c.*, pericardium; *a.*, auditory vesicle.

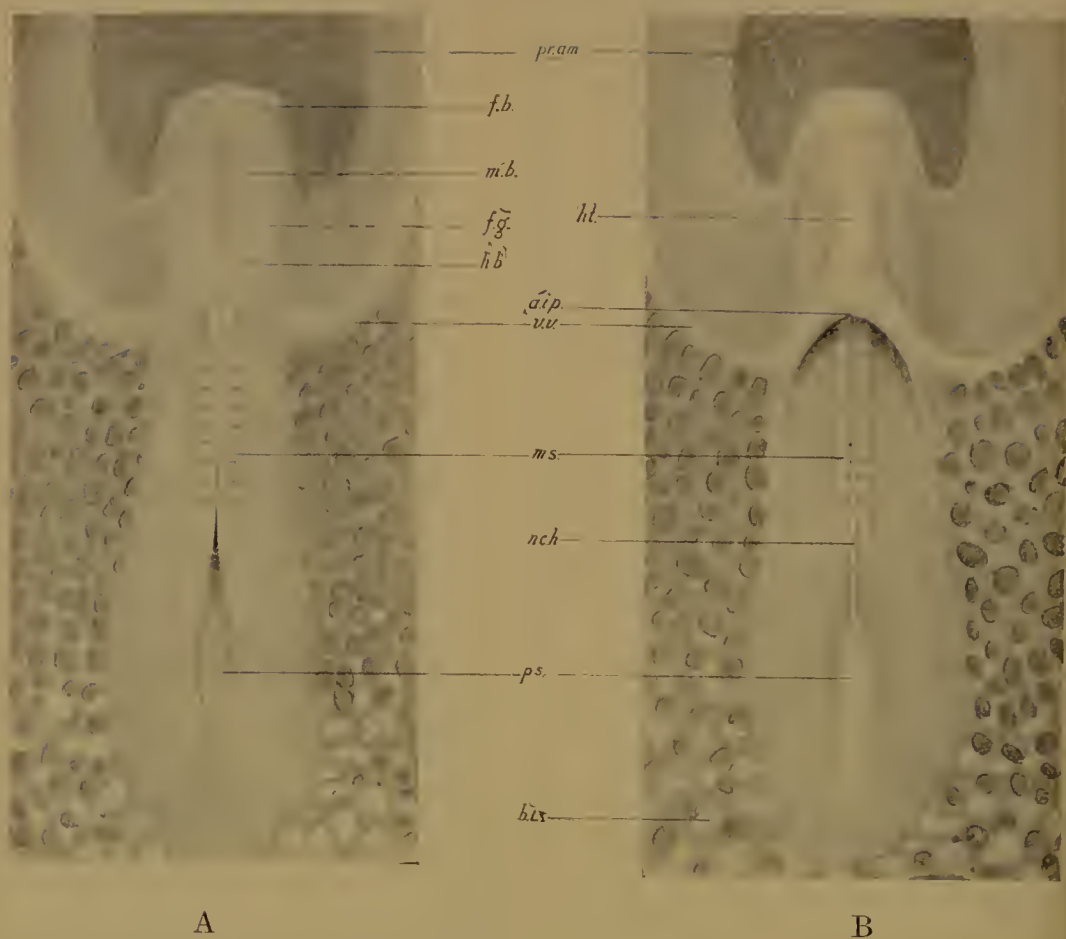

FIG. 113.—Chick of 30 hours as seen by reflected light on a dark background, A from above, B from below. *f.b.*, fore-brain with optic vesicles; *m.b.*, mid-brain; *h.b.*, hind-brain; *a.i.p.*, anterior intestinal portal; *p.s.*, primitive streak; *b.i.*, blood-islands; *ht.*, heart. Other letters as before.

islands, and the capillaries, when they are formed, are between the splanchnopleure and the yolk-sac (Fig. 108).

There is thus an extra-embryonic as well as an intra-embryonic coelom. The former is coextensive with the mesoderm, is found, therefore, behind and at the sides of the embryo, but not in the proamnion in front.

A network of blood-vessels soon appears in the area pellucida, continuous with those of the area vasculosa. It seems that these arise, not by encroachment of the capillaries of the latter region upon the former, but *in situ*. They are formed from the splanchnopleure and come into connexion with the others. The blood-vessels of the embryo, the two dorsal aortae and the cardinal veins, are also formed *in situ* from loose connective tissue, mesodermal cells which come together to form tubes, the vessels. The heart of the chick (and of all Amniota) is not, however, formed in the body of the embryo after that has been folded off from the blastoderm (as is the case in Fishes), but from the union of two veins which lie on the right and left, in the area pellucida, apparently outside the body of the embryo.

These are the vitelline veins, into which flows the blood from the capillaries of the area vasculosa. By the actual process of folding off the head and with it the fore-gut from the blastoderm, the two veins are made to lie side by side underneath the fore-gut (Fig. 111), where they coalesce to form a single median tube, the heart (Figs. 112, 113). The heart lies in a cavity, the pericardium, which is simply the anterior portion of the coelom of the lateral plate. As the head is folded off, somatopleure and splanchnopleure are naturally folded off with it, and with them the coelom. In the pericardium the heart is suspended by a mesocardium to the ventral side of the gut. The vitelline veins merely form the endothelium of the heart. Its muscular coat comes from the splanchnopleure covering it.

Though thus derived from two separate veins the cavity of the heart soon becomes single. The double origin has nothing whatever to do with the subsequent division into systemic and pulmonary portions. It is due simply to the fact that the veins are there before the gut is folded off from the yolk-sac. In

Fishes the reverse is the case, and the heart is a single tube from the beginning.

The heart continues to receive the two vitelline veins at its hinder end. These come from the anterior region of the area vasculosa, which extends just as far as the mesoderm, that is, up to the edge of the proamnion on each side.

The two vitelline veins reach the heart by travelling along the anterior edge of the opening of the fore-gut into the yolk-sac, or, to put it in another way, along the line which marks the posterior limit of the head-fold of the endoderm. This opening is the anterior intestinal portal.

At its anterior end the heart gives rise to the aortic arches which pass round the sides of the throat between the gill-slits. These take the blood into the two dorsal aortae, whence it escapes, by the vitelline arteries, on to the area vasculosa again. We shall study the distribution of the blood-vessels in the yolk-sac later on.

Just as the fore-gut so is the hind-gut folded off from the yolk-sac, the opening being the posterior intestinal portal. The middle region remains for some time widely open to the cavity of the yolk-sac below, the communication being the yolk-stalk, but as development proceeds this becomes reduced to a narrow tube.

The changes we have so far described—closure of the medullary tube, differentiation of the mesoderm, formation of the coelom, folding off of the head and fore-gut, and development of the heart—have all taken place before the thirtieth hour of incubation. Other events now occur (Figs. 114, 115). The optic vesicles become apparent as lateral outgrowths of the fore-brain, the auditory vesicles are visible as two shallow pits lying one on each side of the hind-brain, and between the thirtieth and thirty-sixth hours the heart begins to be bent to the right-hand side. The part of the heart that is so bent is the ventricle, and will become divided into the two ventricles of the adult heart. In front of the ventricular region is the truncus arteriosus; this remains in the middle line and gives off the aortic arches. Behind the ventricle is the auricle, also in the middle line, and behind that the sinus venosus receiving the two vitelline veins.

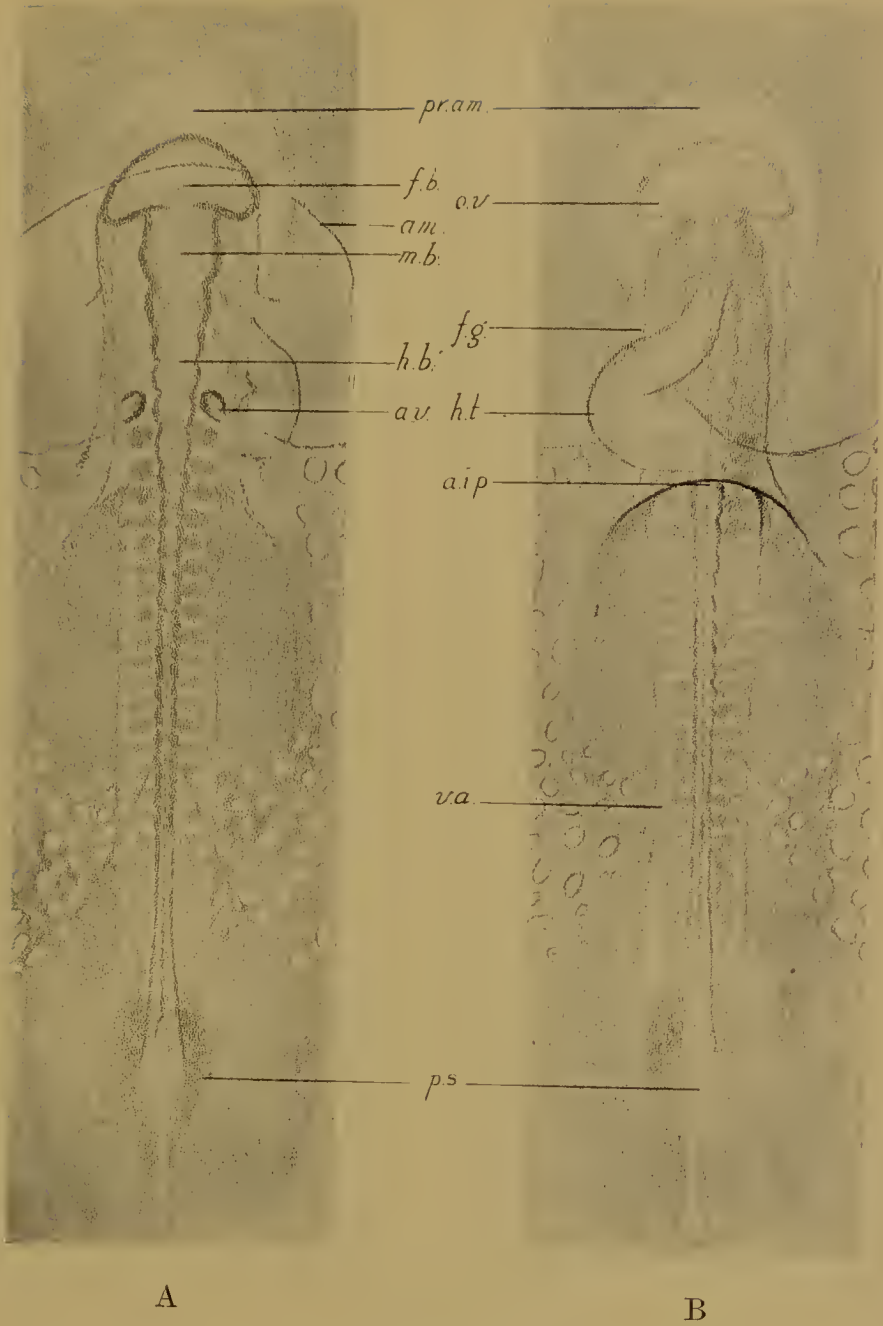


FIG. 114.—Chick of 36 hours as seen by transmitted light. A, from above, B, from below. The heart is bent out to the right. The head-fold of the amnion (*am.*) has begun to grow over the head. *o.v.*, optic vesicle; *a.v.*, auditory vesicle; *v.a.*, vitelline artery. Other abbreviations as before.

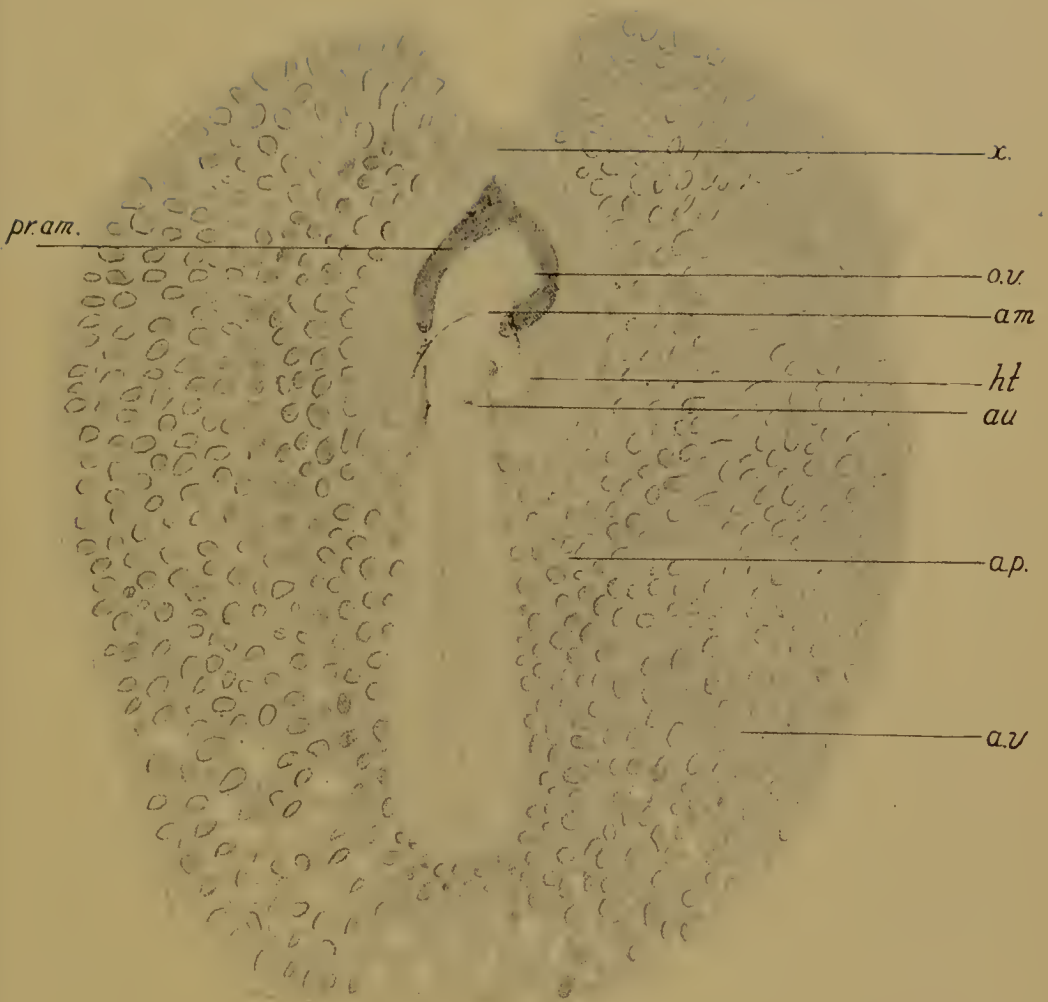


FIG. 115.—Chick of 44 hours' incubation with area pellucida and area vasculosa, seen by reflected light. At *x* the mesoderm sheets have met in front of the pro-amnion. *au.*, auditory vesicle; *a.v.*, area vasculosa. Other letters as before. The head is beginning to turn to the right.

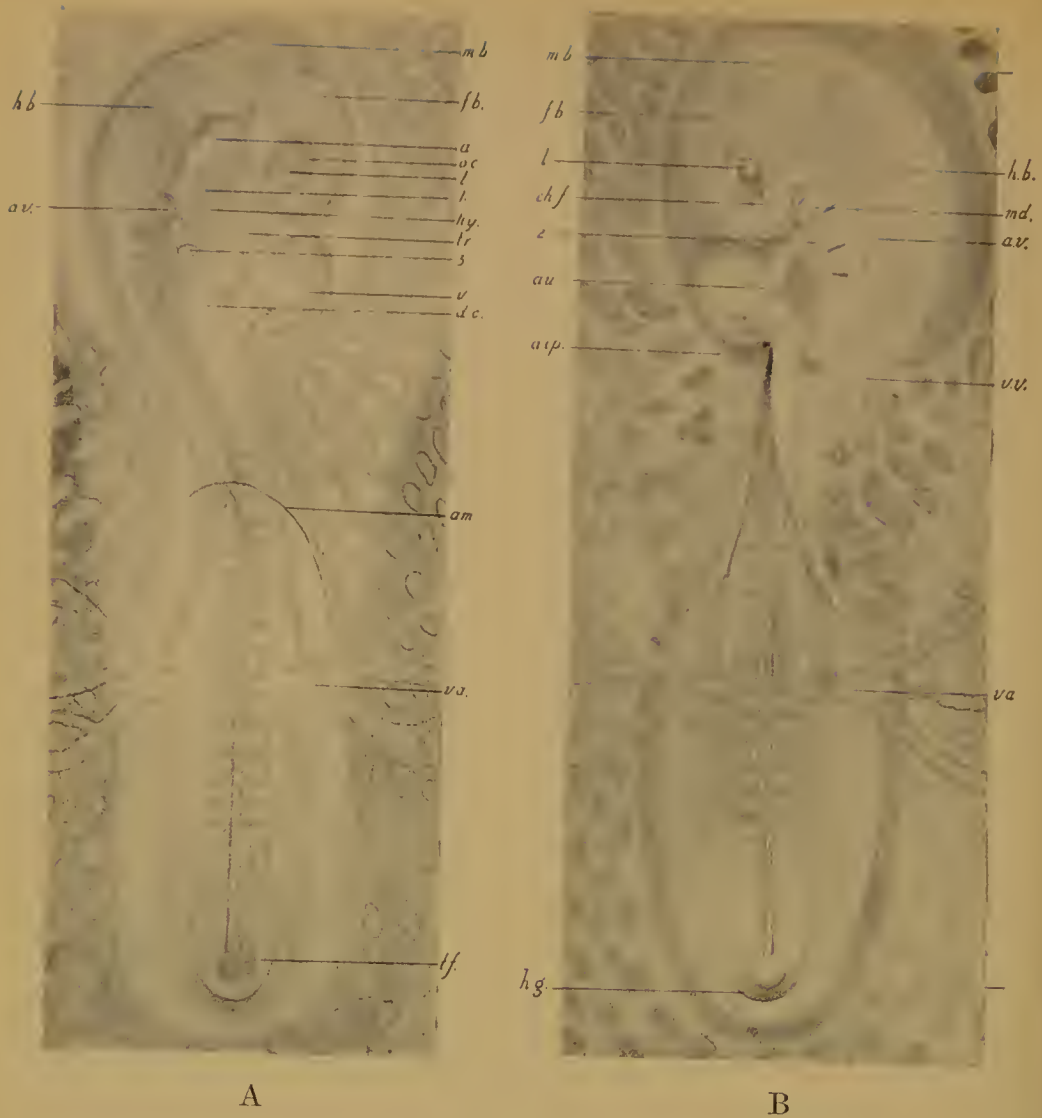


FIG. 116.—Chick of 60 hours, A, from above by transmitted light, B, from below by reflected light. The head is turned to the right and lies with its left side on the yolk-sac. The fore-brain is bent down on the mid-brain (cranial flexure) and the hind-brain slightly bent on the body (cervical flexure). Three gill-slits are present (1, 2, 3) and three aortic arches (mandibular, hyoid, and first branchial). The optic cup and lens are formed, the auditory vesicle has sunk into the head. The head-fold of the amnion has grown over the head and partly over the trunk. The hind-gut is beginning to be folded off from the yolk-sac.

a.v., auditory vesicle; *v.v.*, vitelline vein; *v.a.*, vitelline artery; *au.*, auricle; *v.*, ventricle; *tr.*, truncus arteriosus; *a.*, aorta; *d.c.*, ductus Cuvieri; *o.c.*, optic cup; *l.*, lens; *ch.f.*, choroid fissure; 1, 2, 3, hyomandibular, first branchial, and second branchial clefts; *md.*, mandibular arch; *hy.*, hyoid arch; *h.g.*, hind-gut; *t.f.*, tail-fold of embryo.

The head of the chick now begins to be turned to the right, so that it lies with its left side upon the blastoderm (48 hours). At the same time the fore-brain is beginning to be bent down below the mid-brain so that the latter comes to lie at the anterior end of the body. This is known as the primary cranial flexure. Later, by the cervical flexure, the hind-brain becomes bent down upon the body.

At the sides of the fore-brain may be seen the two optic cups—formed by pushing in the outer wall of the optic vesicles—and opposite the mouth of each optic cup the lens is being invaginated from the superficial ectoderm. The head-fold of the amnion has grown a little way back over the head.

By the middle of the third day (Fig. 116) all the four gill-slits are formed, and there are three pairs of aortic arches conveying the blood into the dorsal aortae. The blood which is distributed to the body of the embryo makes its way back to the heart by the anterior and posterior cardinal veins, and the ductus Cuvieri.

The cerebral hemispheres are beginning to be protruded from the front of the fore-brain. The lens invagination has closed. The auditory vesicle has sunk into the head and lost its connexion with the exterior. The amnion has grown back over the head and front part of the trunk. By the end of the third day the amnion is closed and the allantois is visible outside the body of the embryo at the posterior end.

The foundations of the various systems of organs are now well established. It will be clear that they arise in essentially the same manner as in the frog. The nervous system—medullary tube and neural crest—and the sense-organs do not differ in any important particular. It may be pointed out, however, that the lens (Fig. 117) and the auditory vesicle (Fig. 112, 5) are, in the chick, invaginations of the whole thickness of the ectoderm, and not merely of an inner layer. The pituitary body is a hollow, not a solid upgrowth from the stomodaeum. The differentiations of the primary mesoderm are the same in the two cases. Attention has already been directed to the mode of formation of the heart. From the endoderm the same set of structures arises, the gut and its outgrowths or derivatives, thyroid, gill-slits,

thymus, lungs, liver, pancreas, and bladder or allantois. We shall have to refer to the last-mentioned again, as it is one of the foetal membranes or appendages. Though the chick—like other Amniote embryo—possesses gill-slits, formed in the same way as in the frog by outgrowths of the pharynx wall, gills are never present. The number of these gill-slits is four, namely, the hyomandibular and three branchial. The first three are perforated and remain open up to the fourth (first and second) or fifth (third) day. The fourth slit is never open. The

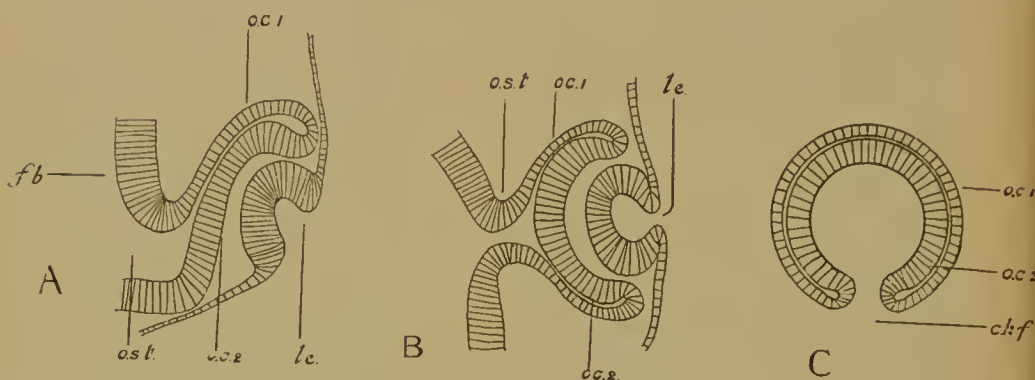


FIG. 117.—Development of the eye in the chick. A, Section including the choroid fissure (transverse to the head); B, Section horizontal to the head; C, Section parallel to the sagittal plane of the head and so transverse to the choroid fissure. *o.st.*, optic stalk; *o.c.1*, outer layer of optic cup; *o.c.2*, inner layer of optic cup; *le.*, lens; *ch.f.*, choroid fissure; *f.b.*, fore-brain.

hyomandibular cleft remains to form the tympanic cavity and Eustachian passage. The arterial aortic arches bear the same relation to these gill-clefts as in the lower water-breathing forms, but are not divided by the gill-capillaries into afferent and efferent portions, and so pass uninterruptedly from the ventral aorta (truncus arteriosus) to the dorsal aortae.

By the middle of the third day three aortic arches are formed. A fourth is added at the end of the third day, and later two more, thus making six in all. The first of these is the mandibular, the second the hyoid, the remaining the four branchial aortic arches, being named from the gill-arches in which they run.

The two dorsal aortae unite posteriorly into one (Fig. 118).

The foetal membranes. The real difference between the early development of the Amniota and the Anamnia is due to the presence in the former of certain wrappings and appendages, known as the foetal membranes.

The foetal membranes are the amnion, the false amnion or chorion, the yolk-sac, and the allantois.

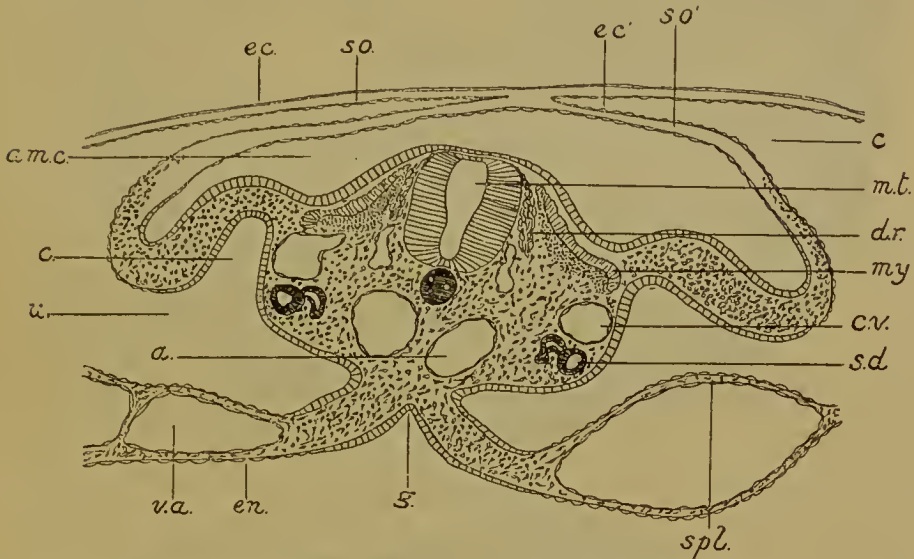
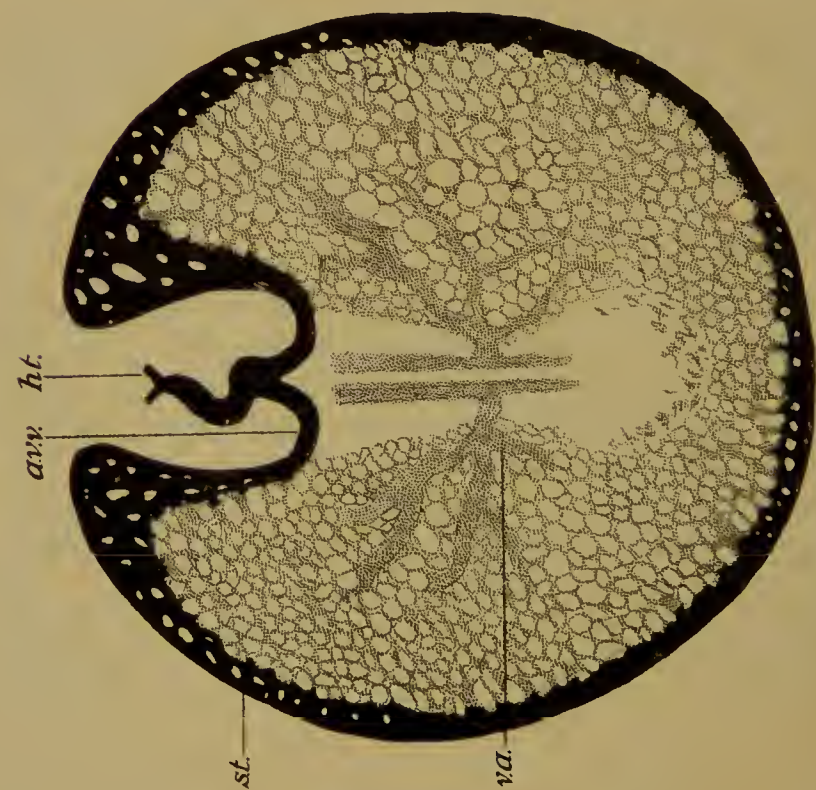


FIG. 118.—Section through the hind end of the chick on the third day when the amnion is closing. *ec.*, ectoderm of false amnion with *so.*, its somatopleure; *ec'* and *so'*, ectoderm and somatopleure of true amnion; *am.c.*, amniotic cavity; *c.*, extra-embryonic, *c'*, intra-embryonic coelom; *u.*, umbilicus; *m.t.*, medullary tube; *d.r.*, dorsal root of spinal nerve; *my.*, myotom; *s.d.*, segmental duct (Wolffian duct after degeneration of pronephros); *c.v.*, cardinal vein; *a.*, aorta; *v.a.* vitelline artery; *spl.*, splanchnopleure; *en.*, endoderm; *g.*, gut.

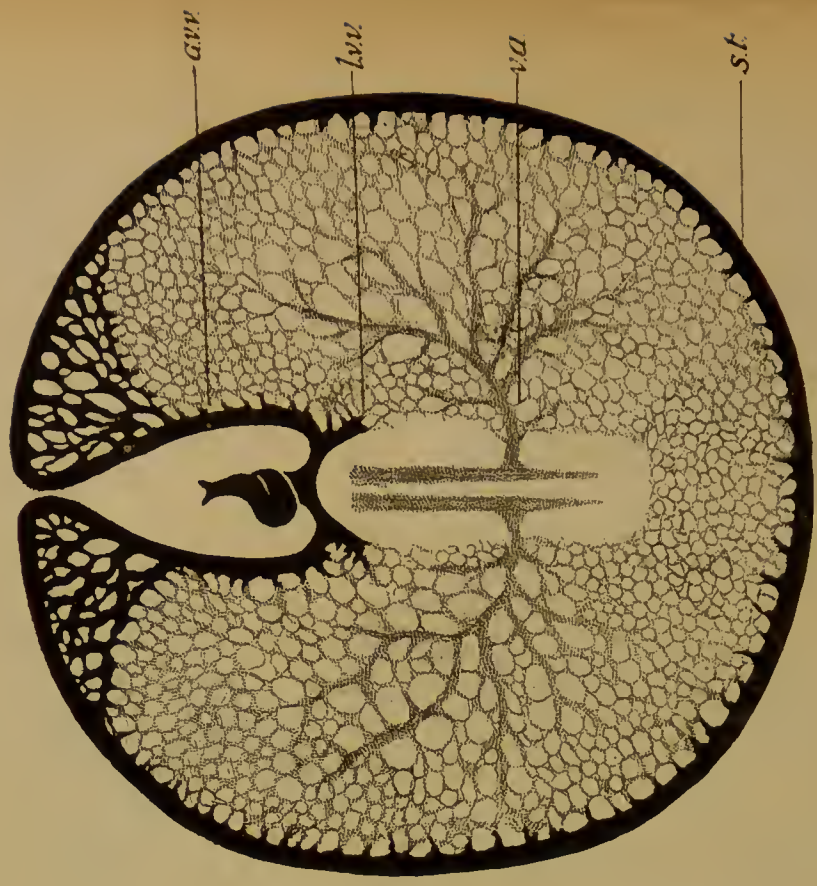The yolk-sac is the layer of endoderm with its covering of vascular splanchnopleure which encloses the yolk. It is connected to the gut, which has been folded off from it by a hollow stalk, the yolk-stalk (Fig. 120). In the splanchnopleure are the vessels of the area vasculosa.

The origin of these has already been seen. The arrangement of the main vessels undergoes considerable modification during the first few days of incubation (Fig. 119).

At about the thirtieth hour the two vitelline veins (anterior vitelline veins) come from the anterior end of the area vasculosa,



A



B

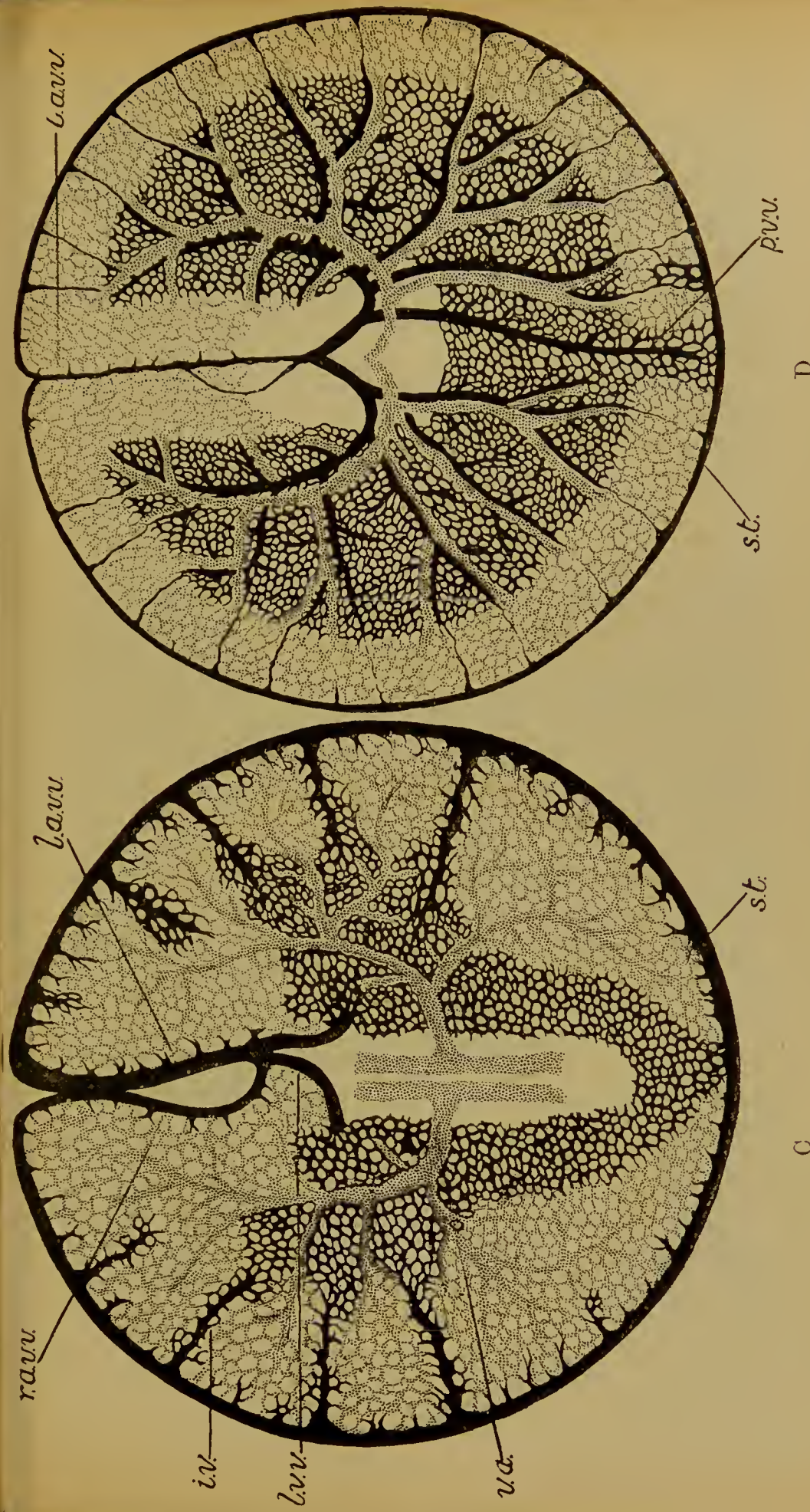


FIG. 119.—The area vasculosa as seen from the under side. (After Lillie, after Popoff.) A, after 38 hours; B, after 44 hours; C, after 48 hours, and D, after 3 days of incubation. The arteries are stippled, the veins black. *h.t.*, heart; *a.v.v.*, anterior vitelline vein (*l.*, left; *r.*, right); *l.v.v.*, lateral vitelline vein; *i.v.*, intermediate vein; *p.v.v.*, posterior vitelline vein (on left); *s.t.*, sinus terminalis; *v.a.*, vitelline artery.

passing along the inner edge of the mesoderm which borders the proamnion ; there they are seen to arise from an annular vessel—the sinus terminalis—which runs round the edge of the area vasculosa. Into this venous ring the blood leaks from the capillaries of the area, to which it is brought by a pair of vitelline arteries which are given off from the aortae. These vitelline arteries are only just being differentiated out of the network in the area (Fig. 119, A).

A little later (44 hours) the vitelline arteries and their branches are well developed. The two (anterior) vitelline veins are beginning to unite in front, just where they spring from the sinus terminalis. At the same time traces of two new lateral vitelline veins can be seen (Fig. 119, B).

On the third day the anterior vitelline veins are united in front, and the right-hand one is being reduced in diameter. The lateral vitelline veins are further advanced and receive their blood from a central part of the network, which is now no longer arterial but venous. This venous network is placed at the sides of and behind the embryo. Veins—called intermediate—open from it into the sinus terminalis. The vitelline arteries—which are still better developed—pass right through the venous network before breaking up into capillaries in the marginal part of the area vasculosa (Fig. 119, C).

On the fourth day the right anterior vitelline vein has nearly disappeared, while the new lateral vitelline veins are conspicuous, receiving their blood from the central part of the area vasculosa. From this central part the blood passes also in the other direction by the intermediate veins into the sinus terminalis. There is also a single posterior vitelline vein which arises from the sinus terminalis : it lies on the left-hand side.

The arteries go through the central venous area as before to reach the marginal part. They course alongside the main venous trunks, lying always on the ventral side of the latter (Fig. 119, D).

Finally (on the tenth day) the anterior and posterior vitelline veins, the intermediate veins, and the sinus terminalis all disappear, and only the lateral veins are left.

The lining epithelium of the yolk-sac—which is made of large

vacuolated columnar cells—is produced internally into septa (Fig. 121), which are perforated by stomata.

The septa are supplied with blood-vessels from the area vasculosa.

As the blastoderm grows over the yolk the latter becomes more and more completely enclosed by the yolk-sac, the edges of which finally almost meet.

With the growth of the blastoderm the mesoderm and the extra embryonic coelom have also been advancing, so that the yolk-sac with its covering of vascular splanchnopleure becomes more and more detached from the somatopleure, until only a very small connexion is left between the two (Fig. 120, 4).

On the nineteenth day the yolk-sac, together with the adherent albumen sac (see below) is drawn into the body-cavity through the umbilicus, where it remains visible for some time as an appendage of the alimentary canal.

The amnion arises (Figs. 118 and 120, 1-3) by the formation of a fold of the extra embryonic ectoderm, together with the somatopleure which is applied to it. The yolk-sac and its splanchnopleure have no share in the process.

There are four parts to the amnion fold, the head fold, which arises first and is much larger than the others, the tail fold, and the two lateral folds.

The extra-embryonic coelom is continued into the folds, each of which consists of two layers. The folds grow up over the back of the embryo and meet and fuse towards the posterior end of the body. When the fusion is complete the outer layer of the folds is separated from the inner by the coelom. Each is composed of a sheet of ectoderm and a sheet of somatopleure. The outer layer, now detached from the body of the embryo, is continuous with the two upper layers, ectoderm and somatopleure, of the extra-embryonic blastoderm. It is known as the false amnion or chorion or serosa. The inner layer, on the other hand, also composed of ectoderm and somatopleure, is continuous with the two corresponding layers of the body-wall of the embryo. It is known as the true amnion. The embryo has meanwhile been folded off, but a large aperture is necessarily left on its

ventral side. This aperture is the umbilicus or navel. The amnion, therefore, now forms a completely closed sac inside which the body of the embryo is placed : the sac being inserted into the edges of an aperture, the umbilicus, which is left on the ventral side of the body. Through this aperture the intra-embryonic is in free communication with the extra-embryonic coelom ; through it pass out the stalks of the yolk-sac and the allantois. The amniotic cavity is filled with a fluid, the liquor amnii. The function of the amnion is to act as a water-bath and protect the embryo against shocks.

It has just been said that the false amnion becomes completely separated from the true. This is not quite accurate, since a small double strand of somatopleure is left at the point of closure, the sero-amniotic connexion (Figs. 120, 4, and 121). On the eleventh day this connexion becomes perforated and some albumen makes its way from outside into the amniotic cavity.

The false amnion continues to grow round the yolk with the rest of the extra-embryonic blastoderm, of which it is, of course, the outer layer. At its edge it is continuous, as heretofore, with the wall of the yolk-sac, the somatopleure of the false amnion with the splanchnopleure of the yolk-sac, the ectoderm of the former with the epithelium of the latter (Fig. 120). With the final enclosure of the yolk (Fig. 121) the false amnion practically becomes a closed sac, inside which lies the embryo in its amnion with its yolk-sac and its allantois.

The allantois is a median ventral diverticulum of the hind gut (Fig. 120, 3). It is covered by a layer of splanchnopleure. It grows out and through the umbilicus into the extra-embryonic coelom, where it expands into a large sac occupying all the available space between the amnion and yolk-sac on the inside, and the false amnion on the outside (Fig. 120, 4). The splanchnopleure covering it is vascular, and by means of its blood-vessels, the umbilical arteries and veins, the allantois is enabled to function as a respiratory organ. It is applied closely to the inside of the porous shell ; and here oxygen is taken up and carbon dioxide given off by the blood in its capillaries.

At the narrow end of the shell the allantois pushes out the false amnion in the form of a circular fold which encloses the

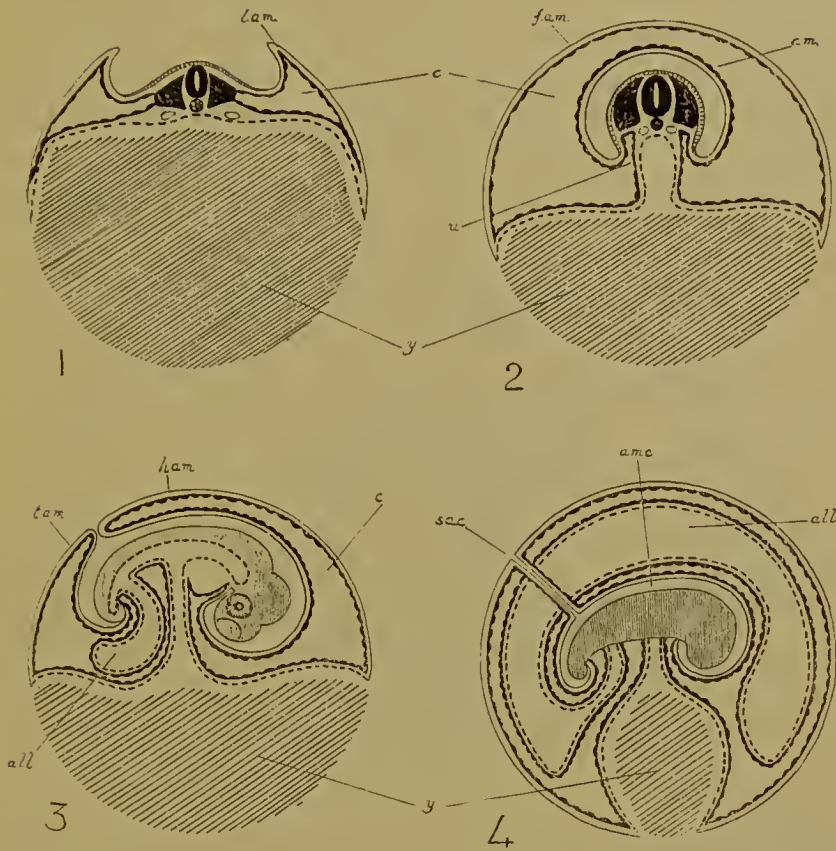


FIG. 120.—Diagrams showing the formation of the amnion, false amnion, yolk-sac, and allantois in the chick.

1, Transverse section. The lateral folds of the amnion are rising up; the gut is not yet folded off from the yolk-sac.

2, Transverse section. The amnion is closed and the gut is folded off from the yolk-sac. The section passes down the yolk-stalk.

3, Longitudinal section, when the amnion is about to close and the allantois is beginning to grow out.

4, Longitudinal section of a later stage, when the allantois has extended into the extra-embryonic coelom, and the yolk has nearly been enclosed at the vegetative pole.

In all the diagrams the ectoderm is represented by a thin continuous line, the mesoderm by a thick line swollen at intervals, the endoderm by a thick broken line, while the yolk is shaded. *lam.*, lateral amnion fold; *h.am.*, head amnion fold; *t.am.*, tail amnion fold; *am.*, true amnion; *f.am.*, false amnion; *am.c.*, amniotic cavity; *s.a.c.*, sero-amniotic connexion; *u.*, umbilicus; *c.*, extra-embryonic coelom; *all.*, allantois; *y.*, yolk in yolk-sac.

albumen. This is the albumen sac (Fig. 121). The albumen loses a great deal of water by evaporation during incubation. What remains of the albumen sac passes along with the yolk-sac through the umbilicus into the body cavity of the embryo.

At the time of hatching the amnion is broken and, with the allantois and false amnion, shrivels up. Morphologically, the

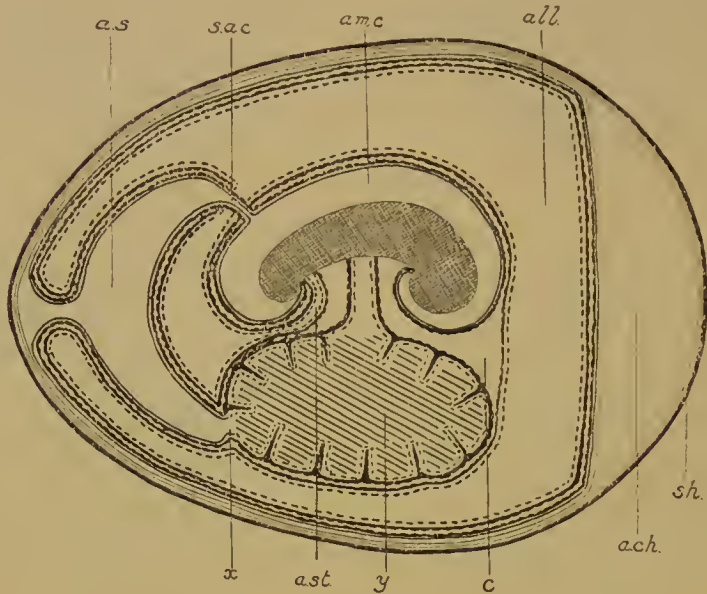


FIG. 121.—Diagram of the final arrangement of the foetal membranes in the chick. (After Duval and Lillie.) *sh.*, shell; *ach.*, air-chamber; *all.*, allantois; *ast.*, stalk of allantois; *a.s.*, albumen sac; *x.*, point of closure of yolk-sac; *am.c.*, amniotic cavity; *s.a.c.*, sero-amniotic connexion; *c.*, extra-embryonic coelom; *y.*, yolk in yolk-sac.

allantois is an extra-embryonic bladder. It is, like the bladder of Amphibia, a median ventral diverticulum of the hind gut. Its veins, the umbilical veins, take the same peculiar course as is taken by the anterior abdominal vein of the Amphibia, which receives the blood from the bladder, namely, in the ventral body-wall, and thence into the capillary system of the liver. In the Reptiles the umbilical veins of the embryo remain as the anterior abdominal vein or veins of the adult. Lastly, the stalk of the allantois persists as the bladder in the Reptiles and Mammals. In Birds the bladder is absent.

The same foetal membranes are present in all Amniota. In

the Ditrematous Mammalia they merit particular attention. The variety of their behaviour is manifold; the amnion has many modes of formation, the yolk-sae, though innocent of yolk, is always present to point to the descent of the small-yolked Mammalian ovum from some large-yolked type, while the allantois vascularizes a placenta developed from the trophoblast, or ectoderm of the false amnion. To the study of these questions we may now proceed.

LITERATURE

- F. M. BALFOUR. Comparative Embryology, vol. ii, London, 1885.
 T. H. BRYCE. Embryology, vol. i of *Quain's Anatomy*, London, 1908.
 M. DUVAL. Atlas d'Embryologie. Paris, 1887.
 O. HERTWIG. Handbuch der Entwicklungslehre der Wirbeltiere. Jena, 1906.
 O. HERTWIG. Die Elemente der Entwicklungslehre des Menschen und der Wirbeltiere. Jena, 1910.
 N. K. KOLTZOFF. Entwicklungsgeschichte des Kopfes von *Petromyzon planeri*. Bull. Soc. Imp. Nat. Moscou, 1901.
 F. R. LILLIE. The development of the chick. New York, 1908.
 A. MILNES MARSHALL. Vertebrate Embryology. London, 1893.
 C. S. MINOT. A Laboratory Text-book of Embryology. Philadelphia, 1910.
 T. H. MORGAN. The development of the frog's egg. New York, 1897.
 J. RÜCKERT. Die Entwicklung von Blut und Gefäßen der Selachier, in O. Hertwig's *Handbuch der Entwicklungslehre der Wirbeltiere*. Jena, 1906.

CHAPTER VIII

THE FOETAL MEMBRANES OF THE MAMMALIA

THE same foetal membranes are found in the Mammalia as in the Reptiles and Birds, namely, the chorion or false amnion, the true amnion, the yolk-sac, and the allantois. Here, however, the yolk-sac, except in the Monotremata, is devoid of yolk ; but it has the same anatomical relations, as an appendage of the gut, as in the other groups, and in its splanchnopleure are developed the blood-vessels of an area vasculosa supplied by a pair of vitelline arteries from the aorta, and by a pair of vitelline veins which enter the hind end of the heart. The size of the yolk-sac varies greatly in the different orders of Placental Mammals. The allantois is always found, though its cavity may be very greatly reduced. Its function is, in the Placental Mammals, to carry the foetal blood-vessels to and from the placenta. It may also act as a receptacle for the waste products of the foetus. Its stalk inside the body of the embryo always persists as the bladder. The amnion is chiefly of interest owing to the peculiarities of its mode of formation in Placentalia. The false amnion or chorion, enveloping as it does the embryo and these other foetal membranes, naturally comes into contact with the uterine wall, except in the Monotremata, and so brings about that relation between foetal and material tissues which constitutes a placenta. Its outer ectodermal layer is known as the trophoblast.

MONOTREMATA (Fig. 122, A)

The formation of the foetal membranes has not so far been described, but from the persistence, over the back of the embryo, of the connexion between the false and the true amnion, it may be gathered that the amnion was formed, as in the Sauropsida,

by folds of ectoderm and somatopleure. Yolk-sac and allantois are both large, the former lies on the left, the latter on the right of the embryo.

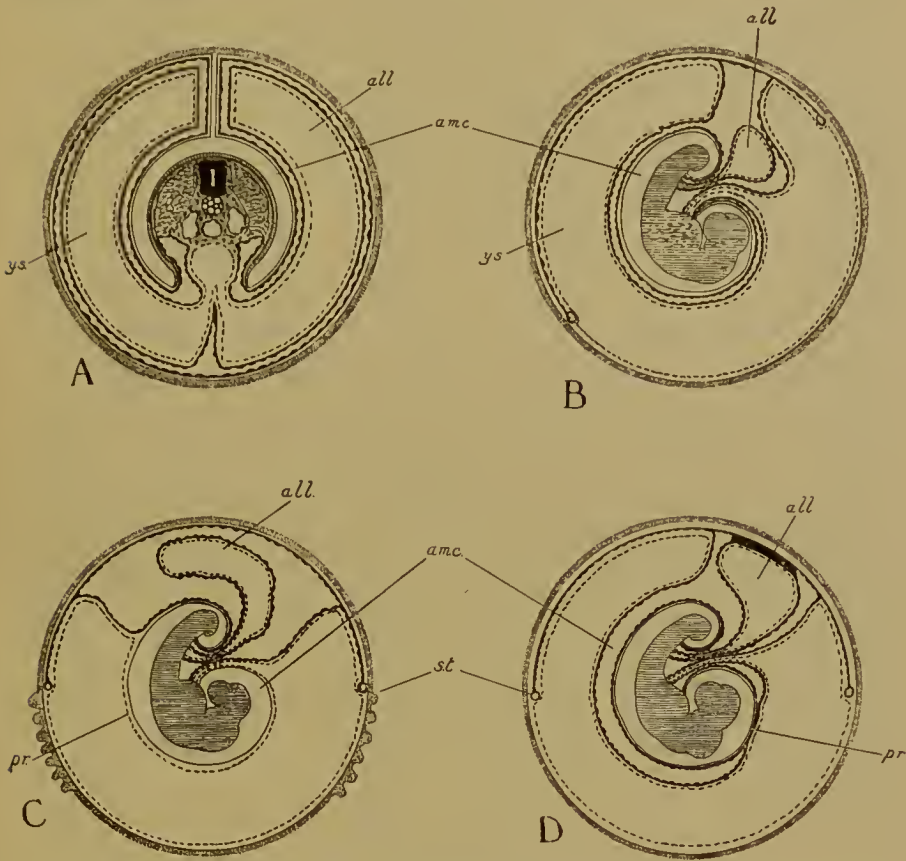


FIG. 122.—Foetal membranes of A, Monotremata; B, C, D, Marsupials. B, *Phalangista*, *Aepyprymnus*, *Didelphys*, *Bettongia*; C, *Dasyurus*; D, *Perameles* and *Halmaturus*. (In *Didelphys* the proamnion persists as in *Dasyurus*.) (A, B, D, after Semon; C, after Hill.)

In this and the following diagrams of Mammalian foetal membranes the trophoblast (ectoderm of false amnion) is stippled, the ectoderm of the true amnion represented by a continuous line, the endoderm by a broken line, and the mesoderm (somatopleure and splanchnopleure) by a thick line swollen at intervals. *all.*, allantois; *am.c.*, amniotic cavity; *pr.* proamnion; *y.s.*, yolk-sac; *s.t.*, sinus terminalis of area vasculosa.

MARSUPIALIA (Fig. 122 B, C, D)

We do not know the mode of origin of the amnion, but it is to be presumed, from the description of the structure of the blastocyst in *Dasyurus*, that the amnion is formed from folds, and that these arise at the edge of the embryonic area. The

inner layer of the folds—true amnion—would then be derived from the embryonic area, while the outer layer—false amnion—would come from the trophoblastic area, of which the other part of the blastocyst is composed.

There is generally a large proamnion—that region of the amnion below the head of the embryo from which mesoderm is absent—and this may persist (*Dasyurus*, *Didelphys*, *Perameles*).

In all Marsupials the yolk-sac is very large, its upper wall invaginated by the embryo. Between the lower (distal) wall and the trophoblast the mesoderm never completely extends, is absent in fact in the anti-embryonic half of the blastocyst, and in the mesoderm the extra-embryonic coelom never extends further than the line where the proximal turns over into the distal wall of the yolk-sac. In the mesoderm of the yolk-sac there is an area vasculosa, and at the extreme edge an annular vessel—the sinus terminalis. The allantois is always small. In some cases—*Didelphys*, *Aepyprymnus*, and others—it altogether fails to reach the false amnion, and its blood-supply is very poor. In others, however (*Phascolarctos*, *Halmaturus*, *Perameles*), the allantois is larger, reaches the trophoblast, and possesses well-developed blood-vessels, which in *Perameles* vascularize a placenta. This placenta, as we shall see below, has a very peculiar structure.

PLACENTALIA

The first of the foetal membranes to claim our attention must be the amnion, for though in a Placental Mammal the amnion may ultimately be formed by folds resembling those of the Birds and Reptiles, yet this is not always so; and even when that method does obtain, there is very good reason for supposing it to be not primary, but secondary.

In the Reptiles, Birds, and Monotremes we have seen that sooner or later, with the final enclosure of the yolk by the blastoderm, the false amnion comes to be a completely closed sac, in which lie the embryo in its amnion, with its yolk-sac and allantois. The cavity of the sac is extra-embryonic coelom; its wall consists of an outer ectodermal and an inner somatopleuric layer.

In Placental Mammals this condition is realized almost in the

first moment of development, for the first act of differentiation is the separation of the inner mass from the outer layer, and, as we are now to see, the inner mass contains within itself the material for the embryo, its amnion, yolk-sac and allantois, and, we may add, the somatopleure and splanchnopleure of the extra-embryonic coelom, while the outer layer or trophoblast is the representative solely of the ectodermal covering of the false amnion. It cannot be too often insisted that all Placental Mammals pass through this stage in which the material for the embryo with its membranes is shut up inside the sac of the trophoblast.

The next step is the separation in the inner mass of the embryonic knob—which comprises the material for embryo and amnion—from the lower layer—from which alimentary canal, yolk-sac, and allantois are derived. The lower layer quickly grows round the inside of the blastocyst.

There follows the formation of the amnion; two main types of which may be distinguished. In the first of these the future amniotic cavity is never open to the exterior, and the trophoblast over the embryonic knob persists. In the second the cells of the trophoblast overlying the embryonic knob—the so-called cells of Rauber—disappear, the embryonic knob comes up to the surface and the amnion is eventually formed by folds in a manner resembling that seen in Reptiles and Birds.

Of each of these types there are again two divisions.

I. (a) In the first division of the first type the future amniotic cavity never opens into any other cavity at all; it arises either inside the embryonic knob (*Cavia*), or between that and the trophoblast (*Erinaceus*).

(b) In the second division are those cases in which the amniotic cavity, developed in the embryonic knob, is in transitory communication with another cavity formed in the thickened overlying trophoblast. The connexion is soon lost and the trophoblastic cavity disappears (*Mus*, *Arvicola*).

II. (a) In the first division of the second type the embryonic knob is gradually folded out and becomes the embryonic plate. This is seen in *Talpa*, *Tupaia*, *Vespertilio*, *Sus*, *Tarsius*.

(b) In the other division the embryonic knob simply flattens

out without the formation of any depression, and so becomes the embryonic plate (*Lepus, Ovis, Sorex*).

As a good example of type I (*a*), we may take the guinea-pig (*Cavia*) (Fig. 123). After the separation of the lower layer the embryonic knob begins to move away from its original pole of attachment to the opposite end of the oval blastocyst, as it does so pushing the lower layer in front of it. This lower layer represents here the upper wall of the yolk-sac only (and the alimentary canal of the embryo), the lower wall being never formed in the guinea-pig. The margins of the lower layer remain attached to the trophoblast at the original embryonic end. When the embryonic knob has reached the opposite end a cavity appears in it; this will be the amniotic cavity. The cells lining this cavity are at first columnar, but a difference soon appears between those next the yolk-sac and those on the side facing the original embryonic pole. The former remain columnar and represent the embryonic area of the upper layer of a Reptilian blastoderm; from these cells the blastopore, archenteron, notochord, and mesoderm presently originate, the remainder being the ectoderm. The latter soon become flattened and represent the inner part of the extra-embryonic blastoderm of the Reptiles; this wall of the cavity becomes the (true) amnion. Meanwhile the germinal layers have been formed and the mesoderm soon extends outside the embryonic region into the space between the amnion below, the trophoblast above, and the yolk-sac at the sides; a cavity appears in this mesoderm which is the extra-embryonic coelom, and is continuous with the coelomic cavity in the embryo. Where this mesoderm covers the trophoblast it is somatopleure, where it lies over the upper wall of the yolk-sac it is splanchnopleure, and where it passes over the amnion it is somatopleure again.

The development of the embryo continues, and its body is folded off from the amnion, the line of attachment of amnion to body-wall being brought continually nearer the mid-ventral line of the embryo and the umbilicus so narrowed. The gut of the embryo has meanwhile been folded off from the yolk-sac, the stalk of which passes through the umbilical aperture.

The trophoblast has now essentially the same relations to the

yolk-sac, embryo, and amnion, as has the false amnion of the chick when the blastoderm has completely invested the yolk. In the chick at this moment the false amnion is a completely closed sac enveloping the embryo in its amnion with its yolk-sac; in the guinea-pig the trophoblast does the same. The differences are due to: (1) the absence of a lower wall to the yolk-sac; (2) the restriction of mesoderm and coelom to the region between the trophoblast, the upper wall of the yolk-sac,

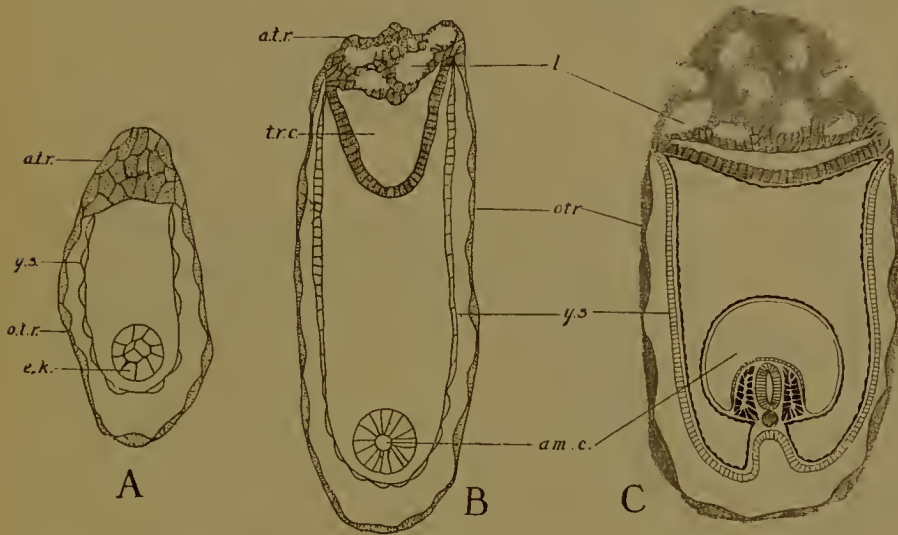


FIG. 123.—Formation of the amnion in the guinea-pig (*Cavia*). (After Sclenka.) A, early, B, later, C, latest stage. *a.t.r.*, allantoidean (placental) trophoblast; *otr.*, omphaloidean trophoblast; *l.*, lacuna; *e.k.*, embryonic knob; *am.c.*, amniotic cavity; *y.s.*, yolk-sac.

and the embryo in its amnion; and (3) to the invagination of the embryo into the upper wall of the yolk-sac.

Thus the amniotic cavity has developed as a cavity closed from its very inception.

The method of amnion formation in Monkeys and Man is not yet known, but it seems very possible that it is according to this first type.

The absence of the lower wall of the yolk-sac led, many years since, to a curious misinterpretation of the development of the guinea-pig, which was known as the 'Inversion of the Germinal Layers'. Early investigators missed altogether the trophoblast in the region of the yolk-sac—which is indeed thin and closely

adherent to the uterine tissues—and then found the embryo in its amnion enveloped in a membrane which was—as we now know—the upper wall of the yolk-sac. This membrane they traced into the alimentary canal and so called it endoderm. At the other end of the blastoeyst the same membrane was found adherent to the trophoblast—here thickened in connexion with the development of the placenta—and believed to be continuous with it. The wall of the blastoeyst was therefore endodermal

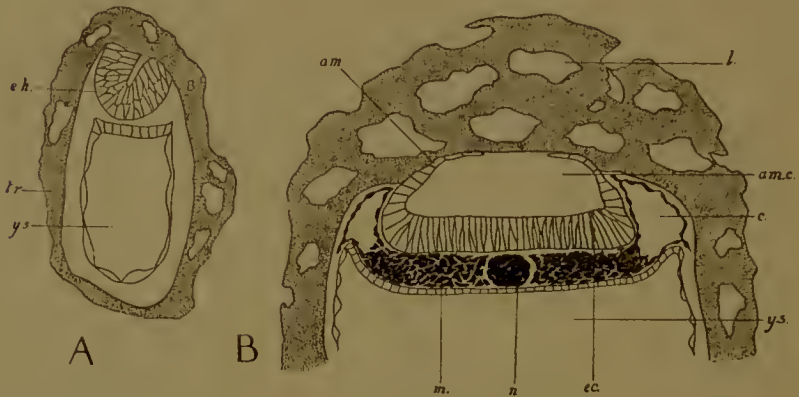


FIG. 124.—Formation of the amnion in the hedgehog (*Erinaceus*). (After Hubrecht.) *tr.*, trophoblast; *y.s.*, yolk-sac; *e.k.*, embryonic knob; *am.*, amnion; *l.*, lacuna; *ec.*, cetoderm of embryonic plate; *n.*, notochord; *m.*, mesoderm; *c.*, extra-embryonic coelom. A, early, B, later stage.

and the germinal layers had in some mysterious fashion become turned inside out. The mistake was cleared up by the researches of Selenka.

Although in the hedgehog the amniotic cavity is not formed in quite the same way as in the guinea-pig, yet it never opens to the exterior or into any other cavity. The embryonic knob becomes detached in its centre from the trophoblast, while remaining adherent to it by its edge. The space between the two will be the cavity of the amnion. As the space enlarges the embryonic knob becomes transformed into a curved plate of columnar cells—the embryonic plate—the edges of which are rather thinned out. The cavity continues to enlarge and the thin edges, of flattened cells, grow up and in between the trophoblast and the cavity, so forming a roof to the latter. This roof is the amnion. In the meantime the coelom has been formed

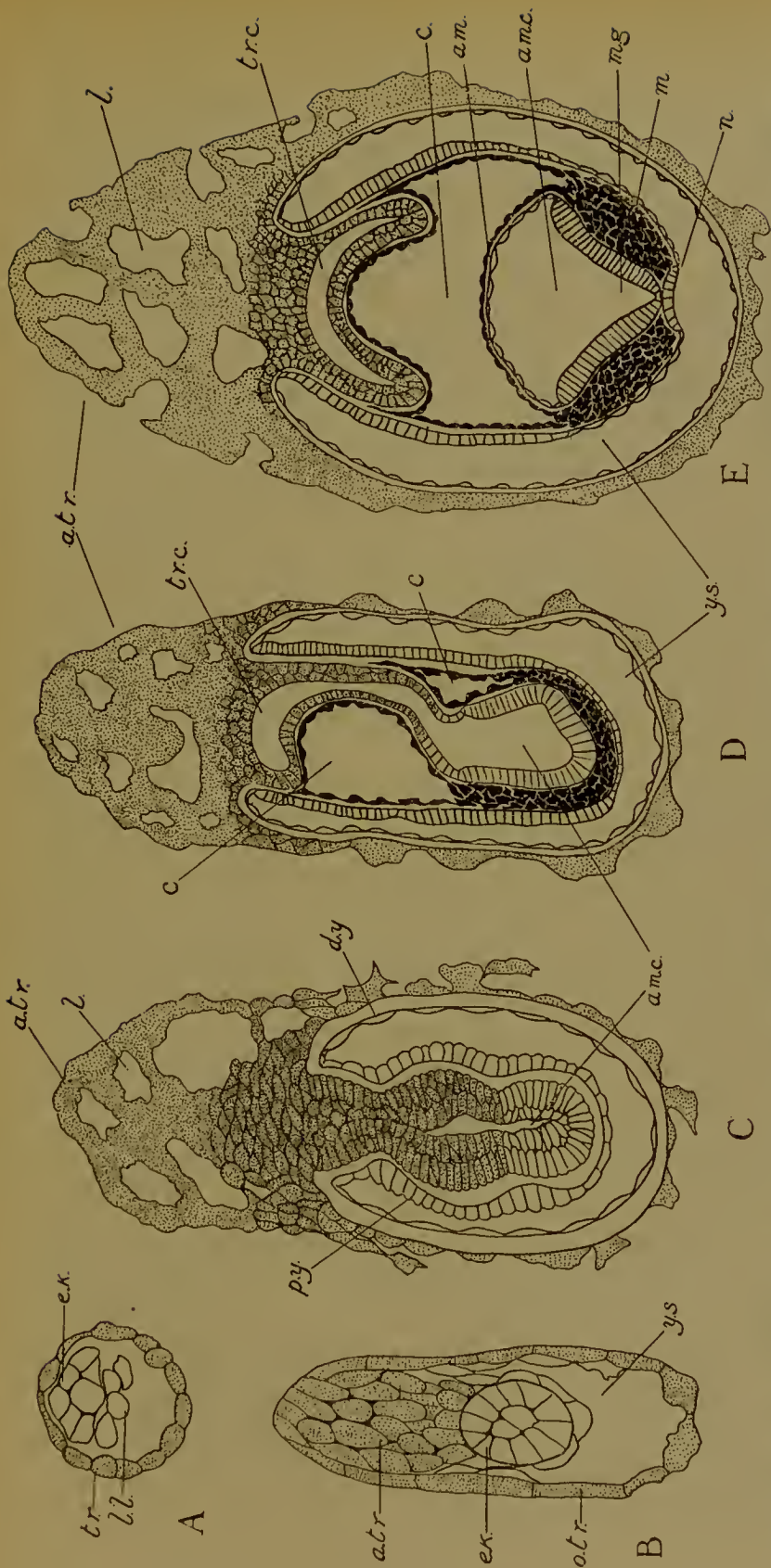


FIG. 125.—Formation of the amnion in the mouse (*Mus*). A–E, Successive stages. *tr*, trophoblast; *a.tr.*, allantoidean, *o.tr.*, omphaloidean trophoblast; *l.*, lacuna; *ek.*, embryonic knob; *ll.*, lacuna; *y.s.*, yolk-sac; *p.y.*, proximal, *d.y.*, distal wall of yolk-sac; *am.*, amnion; *am.c.*, amniotic cavity; *tr.c.*, temporary trophoblastic cavity; *c.*, extra-embryonic coelom; *c.*, extra-embryonic coelom; *m.g.*, medullary groove; *n.*, notochord; *m.*, mesoderm.

and extends up with the amnion between the trophoblast and the embryo (Fig. 124).

I. (b) In the mouse, rat and field-mouse the same invagination of the embryo into the upper wall of the yolk-sac that we have seen in the guinea-pig also occurs, and is indeed found, though not necessarily at this early stage, in all Rodents. Here, however, the distal wall of the yolk-sac is complete. Further, the embryonic knob never leaves the trophoblast at the original embryonic pole, but is driven to the other end of the blastocyst by a great thickening of the trophoblast, which is associated with the formation of the placenta (Fig. 125).

Soon a cavity appears in the embryonic knob—the amniotic cavity—and this immediately comes into communication with a cavity in the trophoblast. As soon, however, as the extra-embryonic coelom is formed it extends into this region, forces the trophoblast away, and severs the connexion. The trophoblastic cavity disappears. That developed in the embryonic knob then becomes the amniotic cavity in precisely the same way as in the guinea-pig.

It is evident that here also the amnion is derived from the material of the embryonic knob, that the trophoblast is the homologue of the ectoderm of the false amnion alone.

II. (a) (Fig. 126). A depression appears in the embryonic knob. By the disintegration of the overlying trophoblast cells this depression comes to open to the exterior. The embryonic knob increases in size, the depression becomes wider and shallower, and the knob—or, as we may now call it, the embryonic plate—finally comes up on a level with the surface of the blastocyst. It is inserted by its edges into the surrounding trophoblast.

The amnion is formed by folds, which arise at the boundary of the embryonic plate. It is difficult to be certain, but it seems that the outer layer of the fold, that is, the false amnion, arises from the trophoblast, while the inner or true amnion comes from the embryonic plate itself.

II. (b) The amnion is formed in precisely the same way in this division; there is, however, no folding out of the embryonic knob: it becomes directly flattened to form the plate. The overlying cells of Rauber disappear (Fig. 127).

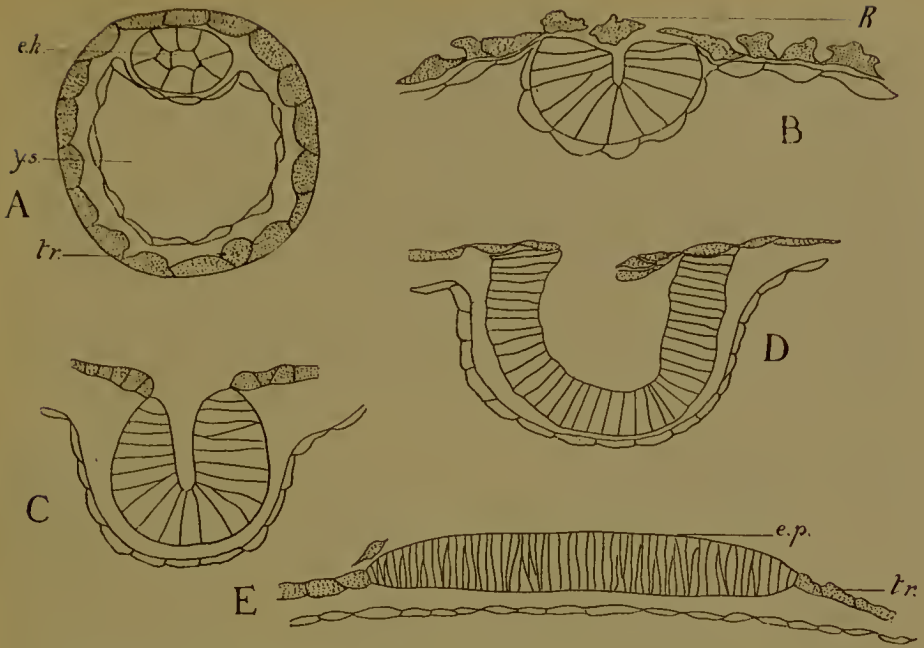


FIG. 126.—Formation of the amnion in *Tupaia* (an Insectivore). A-E, Five stages; *e.p.*, embryonic plate; *R.*, cells of Rauber. Other letters as before. (After Hubrecht.)

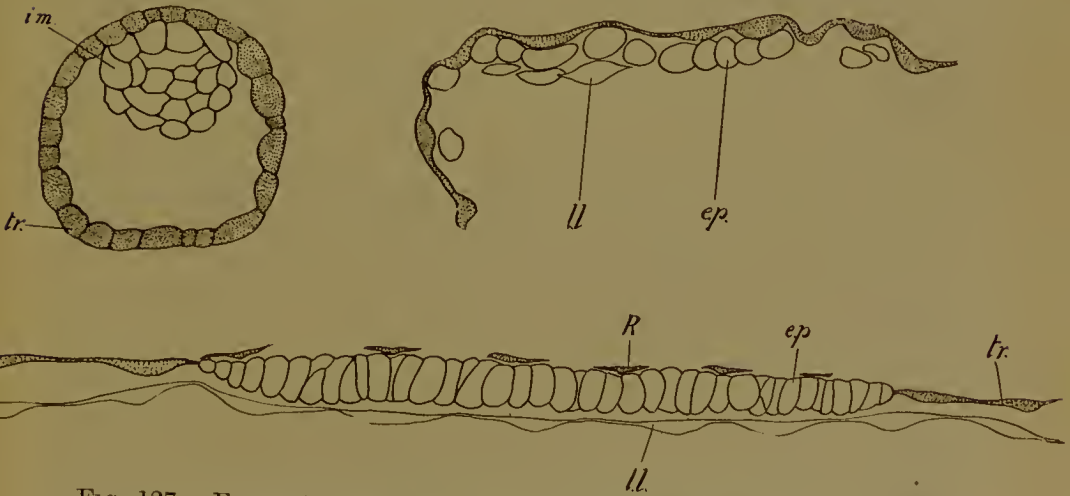


FIG. 127.—Formation of the amnion in the rabbit (*Lepus*); *i.m.*, inner mass; *ll.*, lower layer; *e.p.*, embryonic plate; *R.*, cells of Rauber. (After Assheton.)

In this second type—where the amnion is eventually formed by folds, the tail-fold often arises, as in *Tarsius* and the rabbit, before the head-fold (Fig. 128). Otherwise the resemblance between the way in which this membrane of the foetus is

developed in Placental Mammals and that seen in other forms is certainly very close, and this similarity has suggested that this is the primitive method of amnion formation in Placental Mammals—as distinct from the rest of the class—and that those cases (type I) where the amniotic cavity appears inside the embryonic knob are secondary modifications due to the restricted space in which the blastocyst develops. It is perfectly true that the blastocyst is compressed by the narrow limits of the space in which it is fixed in *Erinaceus*, *Cavia*, and *Mus*. To the

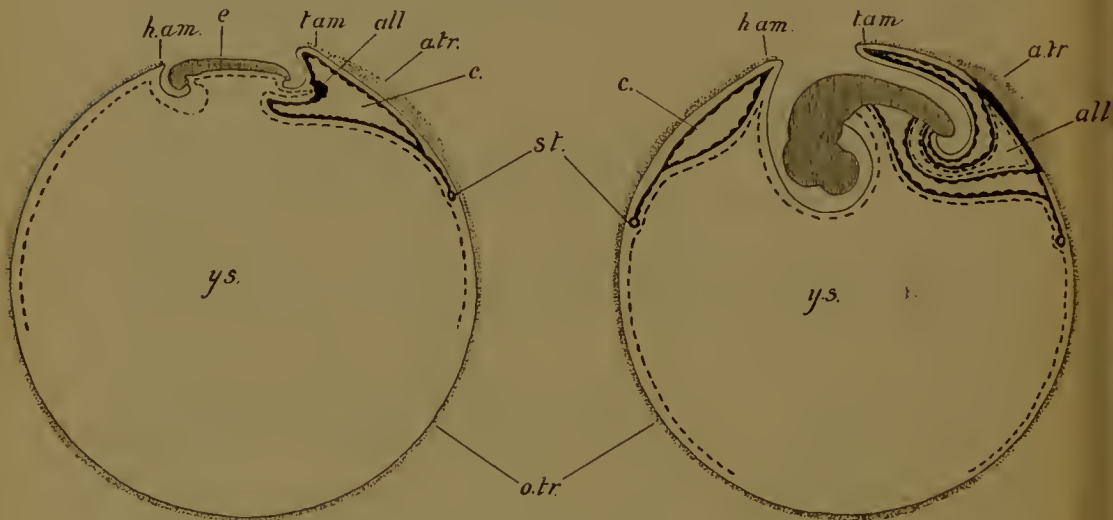


FIG. 128.—Further stages in the formation of the amnion in the rabbit. (After Van Beneden.) *h.am.*, head amnion fold; *t.am.*, tail amnion fold; *e.*, embryo; *all.*, allantois; *a.tr.*, allantoidean trophoblast; *y.s.*, yolk-sac; *o.tr.*, omphaloidean trophoblast; *c.*, extra-embryonic coelom; *s.t.*, sinus terminalis of area vasculosa.

proposed hypothesis there is, however, one fatal objection, and that is the presence of Rauber's cells in members of the second type, the existence of a stage in which the material for the embryo and amnion is wholly enveloped in a closed sac, which is the homologue of the false amnion of Reptiles, Birds, and Monotremes. This is a stage through which all Placental Mammals pass, and in an Insectivore, some Rodents, and possibly in Monkeys and Man, the sac of the trophoblast remains closed. In others, after the disappearance of Rauber's cells, the embryonic knob comes to the surface and amniotic folds are developed. We are justified, therefore, in regarding the first condition as

the primitive, the second as derived from it, and in supposing that one of the first effects of that loss of yolk which we know the ovum of the Placental Mammals has undergone, as compared first with the Marsupials and next with the Monotremes, was a precocious separation of the material for the embryo and its amnion from a closed sac, inside which the differentiation of the germ-layers and of the other foetal membranes could take place, secure from the pressure exerted by the contraction of the uterine walls. The loss of the shell, still retained by the Marsupials, may have been a contributory cause. Such a development has been preserved in those cases where the uterine cavity, or that part of it wherein the embryo is lodged, is narrow; where it is wider reversion to the original method of forming amniotic folds has taken place, unless we prefer to regard this as an independent piece of evolution. (The possibility of such an independent evolution is shown of course by the existence of amniotic folds in other animals, for example, in Insects.) Since the depression which marks the beginning of the folding out of the embryonic knob is probably the remains of the closed amniotic cavity seen in type I, the complete series illustrates the process of reversion to the original Mammalian method, while the distribution of type II over several orders (Insectivora, Cheiroptera, Ungulates, Rodents, Primates) is sufficient evidence of its repeated and independent occurrence.

THE YOLK-SAC AND ALLANTOIS

In the extent to which they are developed these vary greatly in the different orders.

In Rodents (Figs. 123, 125, 128) the yolk-sac is always large, and its upper wall sooner (*Cavia*, *Mus*) or later (*Lepus*, *Sciurus*) invaginated by the embryo. The mesoderm never extends further than the edge of the upper wall. In the splanchnopleure there is a well-developed area vasculosa, the blood-vessels of which convey to the embryo the nutrient materials absorbed by the yolk-sac from the uterus in the following way. The distal (lower) wall of the yolk-sac always disappears (in *Cavia* it is never formed) and then the lumen of the yolk-sac communicates freely with the uterine cavity. In the fluid contained in this

cavity is the proteid and fatty material secreted by the uterine glands; this is absorbed by the highly columnar, folded epithelium of the upper wall of the yolk-sae. The allantois is never large but may be quite well developed. In the mouse and guinea-pig, however, the endodermal outgrowth of the hind-gut is confined within the limits of the embryo's body, and only the vascular splanchnopleure passes out through the umbilicus

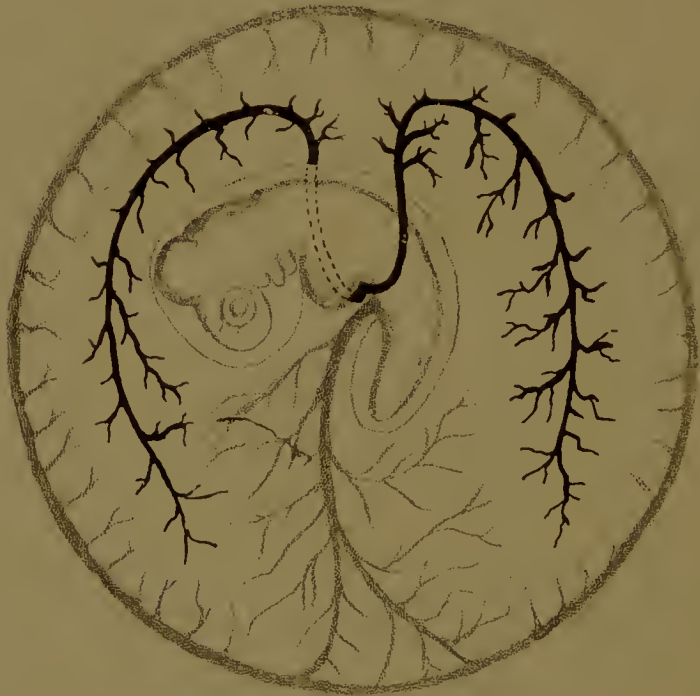

FIG. 128*.—Area vasculosa of the yolk-sac of the rabbit. (After Van Beneden and Julin.) Vitelline veins black, vitelline artery and sinus terminalis stippled.

and across the extra-embryonic coelom to convey the foetal blood-vessels to and from the placenta.

In the Carnivora (Fig. 129) the yolk-sac is small compared to the allantois, and of no importance in the later stages of development, though large and no doubt functional at first. So also in the Ungulates (Fig. 130). Of a fair size at first and provided with an area vasculosa, it is rapidly outgrown by the allantois, which attains enormous dimensions (Fig. 131), extending from one end of the elongated chorionic (trophoblastic) sac to the

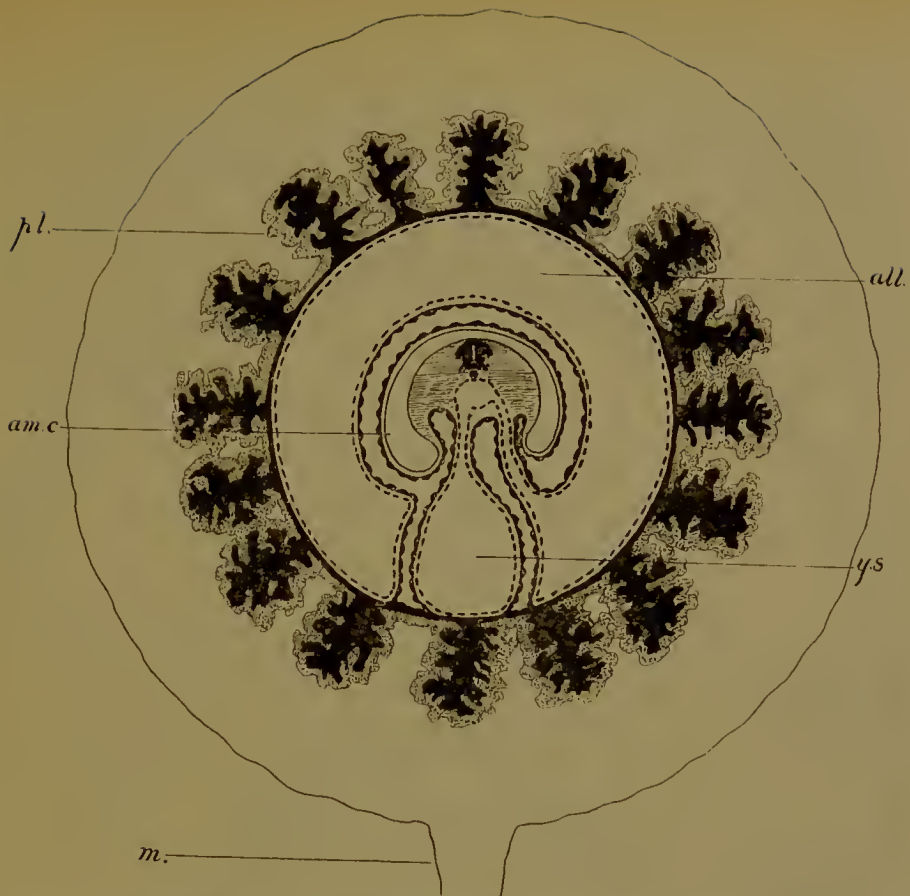


FIG. 129.—Foetal membranes and placenta of the dog. *m.*, mesometrium; *pl.*, zony placenta. Other letters as before. (After Duval.)
 Foetal blood-vessels in black in this and the following diagrams.

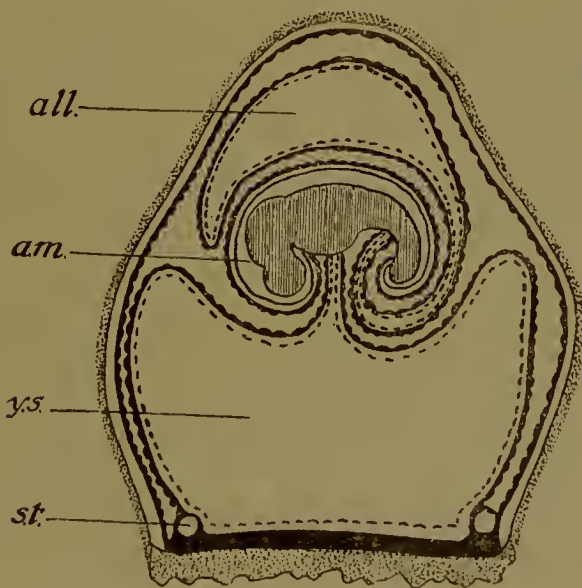


FIG. 130.—Foetal membranes of the horse, early stage. (After Bonnet.)
 Letters as before.

other, and occupying a very considerable space in the uterus. In its cavity are found floating large oval bodies, often very hard, known as hippomanes. These, as well as the fluid contents

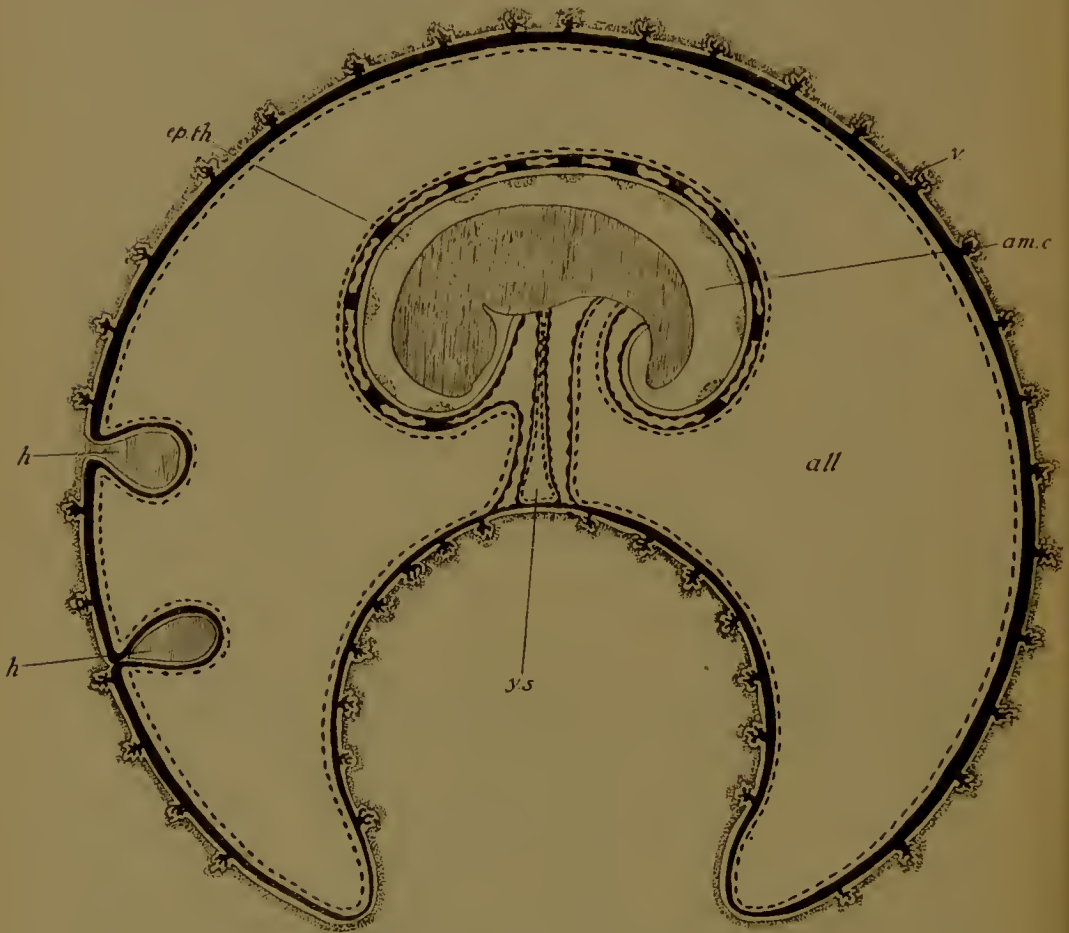


FIG. 131.—Foetal membranes of the horse, later stage. (After Bonnet.) *v.*, villus; *ep.th.*, epithelial thickenings of amnion; *h.*, hippomanes. Other letters as before.

of the allantois, we shall describe when we deal with the physiology of the placenta.

In the pig and sheep the tapering ends of the allantois and of the chorion which covers them, the so-called 'diverticula allantoidis', undergo a partial degeneration. They are sharply marked off from the main body by an annular thickening provided with a sphincter muscle.

In the Insectivora (Fig. 132), again, the yolk-sac is usually large in early stages of gestation, and its blood-vessels may actually (*Tupaia*) begin to penetrate the placental thickening of the trophoblast. But as the allantois develops it drives away the yolk-sac, and the importance of the latter is diminished, though it remains till the time of birth. In *Talpa*, *Erinaceus*, and *Sorex*, the lower (anti-embryonic) wall of the yolk-sac is

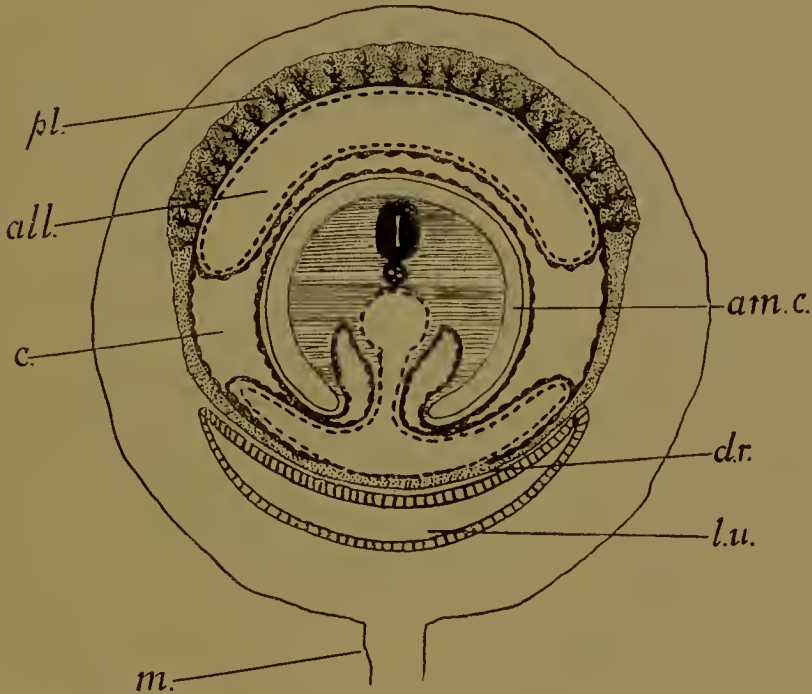


FIG. 132.—Foetal membranes and placenta of the hedgehog. (After Hubreeht.) *l.u.*, lumen uteri; *d.r.*, decidua reflexa. Other letters as before.

never covered by mesoderm. In *Sorex* the yolk-sac contains a bright green pigment, which is either biliverdin or nearly related to it, and is derived from the digestion of extravasated maternal corpuscles which have been eaten by the phagocytic trophoblast.

In the Cheiroptera (Fig. 133) similar conditions are found. The yolk-sac, large and important in early stages, is later replaced by the allantois.

Of the Edentate foetal membranes we know little, except that in the sloth *Choloepus* the allantois is small, the amniotic cavity

large enough to obliterate the extra-embryonic coelom, while the yolk-sac in the stage described has vanished. The same obliteration of the extra-embryonic coelom seems to occur in the Cetacea (*Orca*) and Proboscidea (*Elephas*).

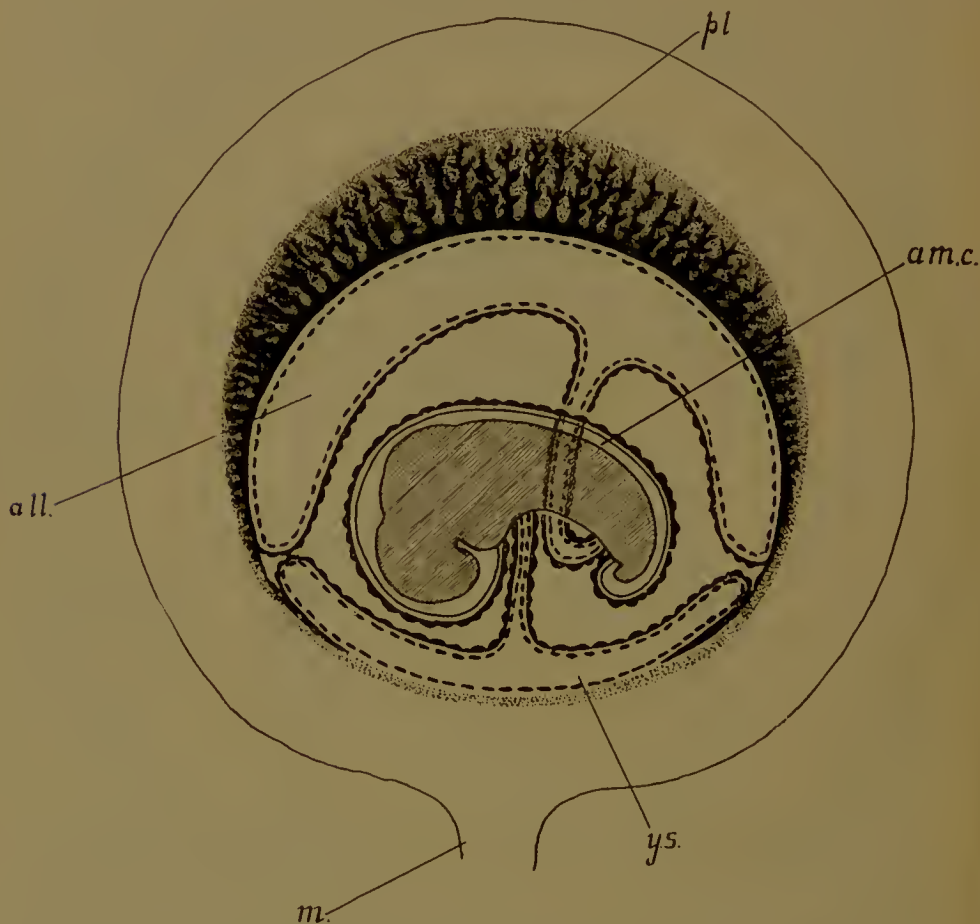


FIG. 133.—Foetal membranes and placenta of the bat (*Vespertilio*).
(After Nolf.) Letters as before.

In the Sirenia (*Halicore*) the allantois is as large as in Ungulata, extending to both ends of the chorionic sac.

In respect of their foetal membranes the Primates fall sharply into two groups.

In the Lemuroidea (Fig. 134) the yolk-sac seems to disappear early, while the allantois is very large, as in an Ungulate; the placenta also, as we shall see, is of the Ungulate type. In the

Anthropoids—Monkeys and Man—with which we must associate *Tarsius*—usually classed as an aberrant Lemur—the arrangement of the foetal membranes is utterly unlike anything found anywhere else amongst the Mammalia. The yolk-sac is diminutive but vaseular (Fig. 138), the endodermal cavity of the allantois is small and almost confined within the body of the embryo,

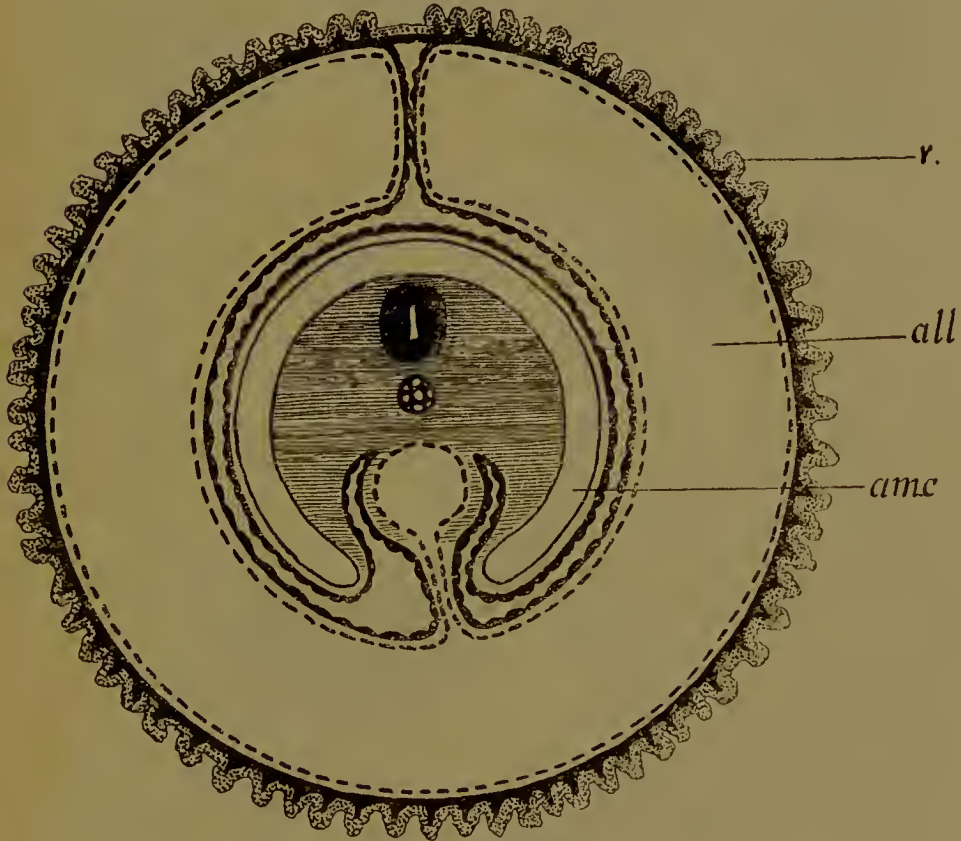


FIG. 134.—Foetal membranes of the lemur. (After Turner.)
v., villi. Other letters as before.

its splanchnopleure alone passing out to the placenta, while the extra-embryonic coelom is pre-embryonically developed.

In *Tarsius* the complete history of these membranes has been given to us by the researches of Hubrecht (Fig. 135). As a result of a proliferation of cells at the hinder end of the embryonic plate a sac is formed lying posteriorly between the trophoblast and the small yolk-sac. This sac is the extra-embryonic coelom. Very quickly it extends until it occupies a very large proportion

of the blastocyst. Where it covers the lower wall of the yolk-sac it is, of course, splanchnopleure; elsewhere, applied to the trophoblast, somatopleure. There is at present no mesoderm between the embryonic plate and the yolk-sac. Thus this extra-embryonic

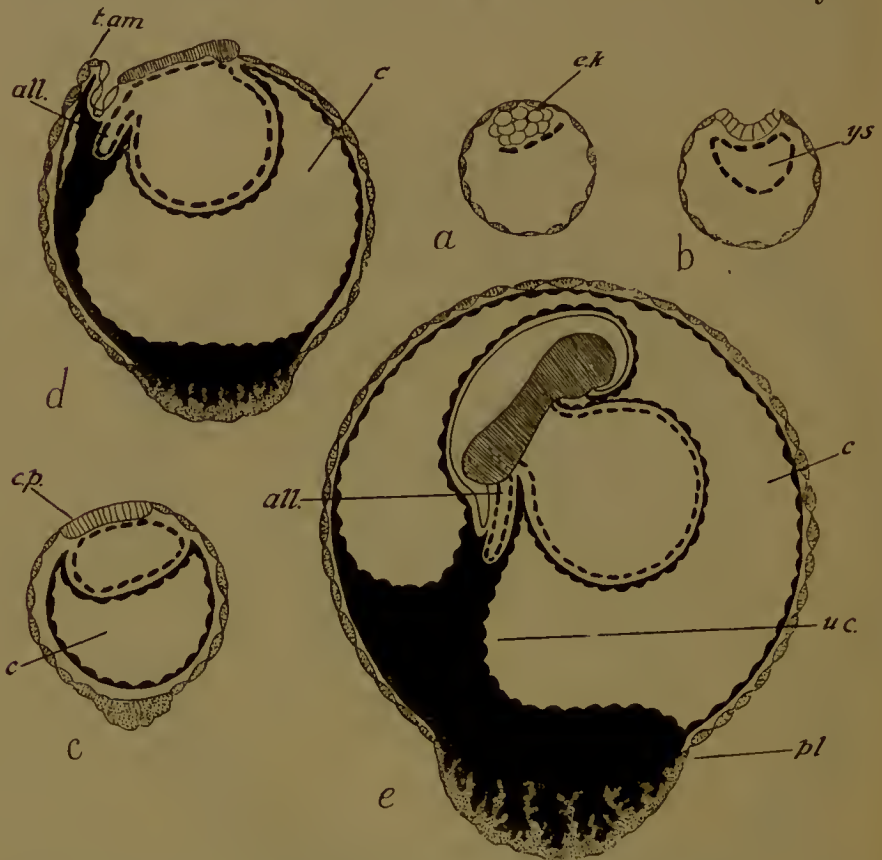


FIG. 135.—Development of the foetal membranes in *Tarsius*. (After Hubrecht.) *a*, blastocyst before Rauber's cells have disappeared; *b*, the embryonic knob (*e.k.*) is being folded out to the surface; the yolk-sac is complete; *c*, the embryonic plate (*e.p.*) is at the surface, the extra-embryonic coelom (*c*) is formed; *d*, the tail-fold of the amnion is growing forward (*t.am.*), the allantois (*all.*) has penetrated the mesoderm of the body-stalk, a placental thickening has been developed at the anti-embryonic pole; *e*, the amnion is closed and the body-stalk or umbilical cord (*u.c.*) is shifting its position, to be attached to the placenta (*pl.*).

mesodermal sac is well formed before the middle layer exists in the embryo. The yolk-sac remains small. Meanwhile, the amniotic folds have appeared, the tail-fold first, and as this grows forwards over the back of the embryo a solid cord of mesoderm is left connecting the hind end of the embryo with the trophoblast. The amnion closes, the embryo is developed

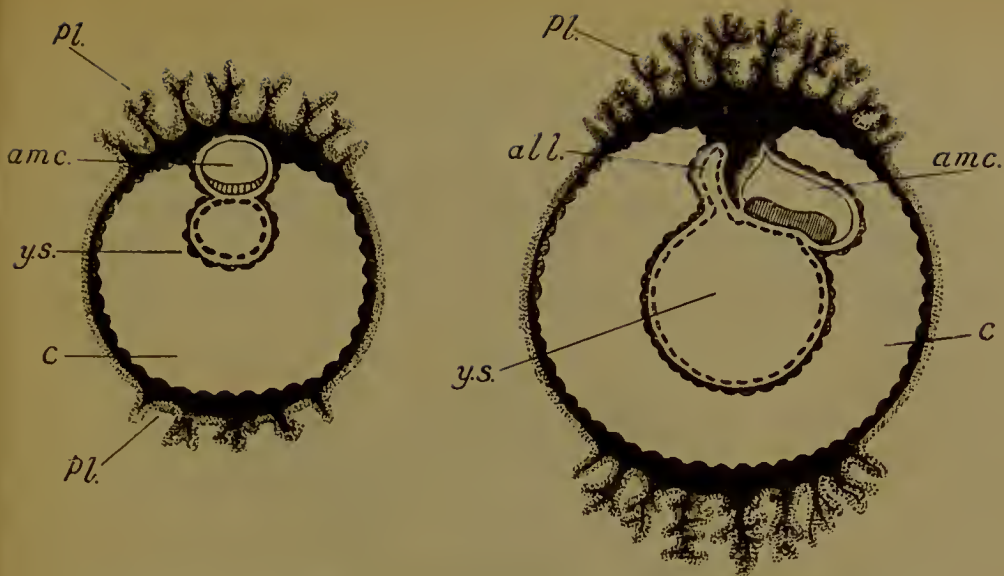


FIG. 136.—Two stages in the development of the foetal membranes in a monkey (*Cercocebus*). (After Selenka). Letters as before.

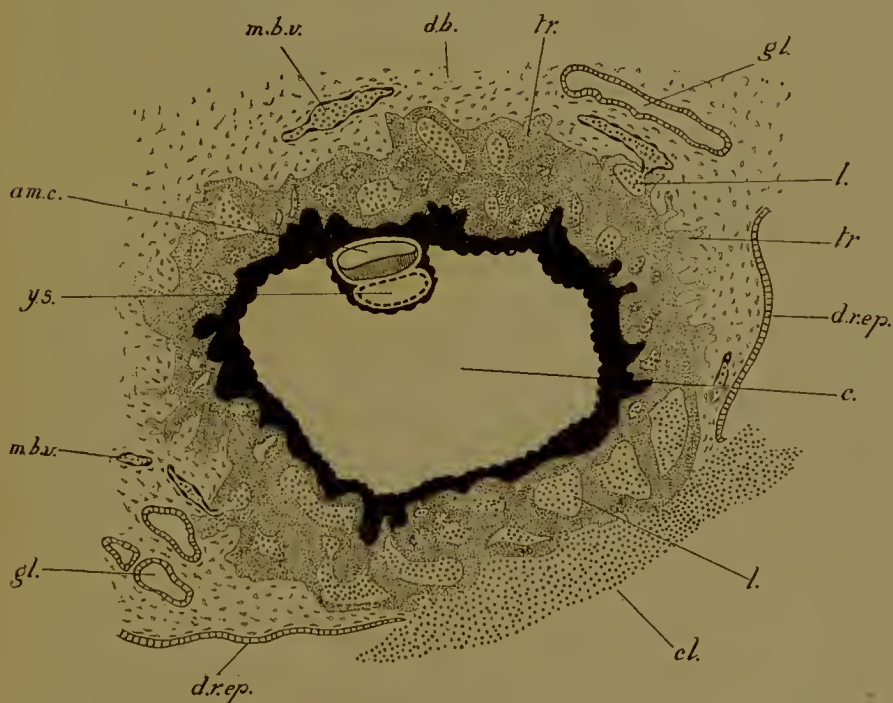


FIG. 137.—Early human embryo with its membranes. (After Peters.) *d.b.*, decidua basalis (scrotina); *d.r.ep.*, uterine epithelium covering the decidua reflexa or capsularis; *l.*, lacuna in trophoblast (*tr.*); *gl.*, uterine gland; *m.b.v.*, maternal blood-vessels opening here and there into lacunae; *cl.*, clot marking (probably) the point of entrance of the blastocyst; here the epithelium is interrupted. Other letters as before.

and folded off inside it, and the cord—which carries the allantois or umbilical blood-vessels and is indeed the umbilical cord—moves round until it is inserted into the original anti-embryonic pole of the trophoblast. It is here that the placenta is formed. The base of the cord is penetrated by the rudimentary allantoic outgrowth of the hind-gut.

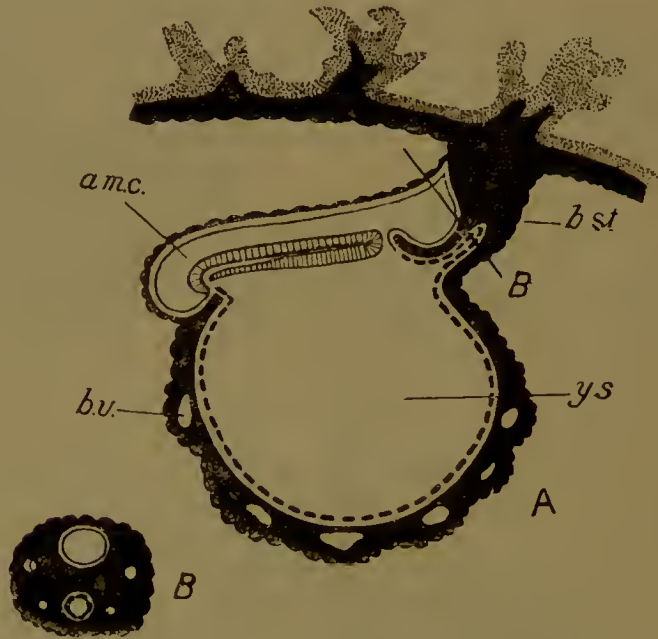


FIG. 138.—A, Longitudinal section of older human embryo. The allantois has grown out and penetrated the base of the body-stalk (*b.st.*) (future umbilical cord). At the hind end of the embryo is a large blastopore (so-called neurenteric canal) leading into the yolk-sac. The gut has hardly yet been folded off. Underneath the medullary plate and in front of the blastopore is seen the notochord. (This figure should be compared with that of the bat, Fig. 93, A.) *b.v.*, blood-vessels in the splanchnopleure of the yolk-sac. Other letters as before.

B, Transverse section of the body-stalk in the plane indicated at B in A. Above is seen the amniotic cavity, below the allantois, and at the sides the umbilical arteries and veins. (After Graf Spee.)

The mutual relations of the membranes in Monkeys and Man are similar, but their origin has not yet been seen. We do know, however, that in the earliest human embryo yet described (Fig. 137), and in the corresponding stage observed in Monkeys (Fig. 136), there is a large extra-embryonic coelom, a small yolk-sac attached firmly to the lower side of the embryonic plate which itself forms the floor of a small cavity, the future

amniotic cavity, the roof of which is the amnion. The embryo in its amnion with its attached yolk-sac is suspended to the somatopleure of the trophoblast by a short cord or stalk of mesodermal tissue. In this the umbilical artery and vein will be developed, while the rudimentary allantois will penetrate its base (Fig. 138). This cord is the so-called 'ventral stalk' ;

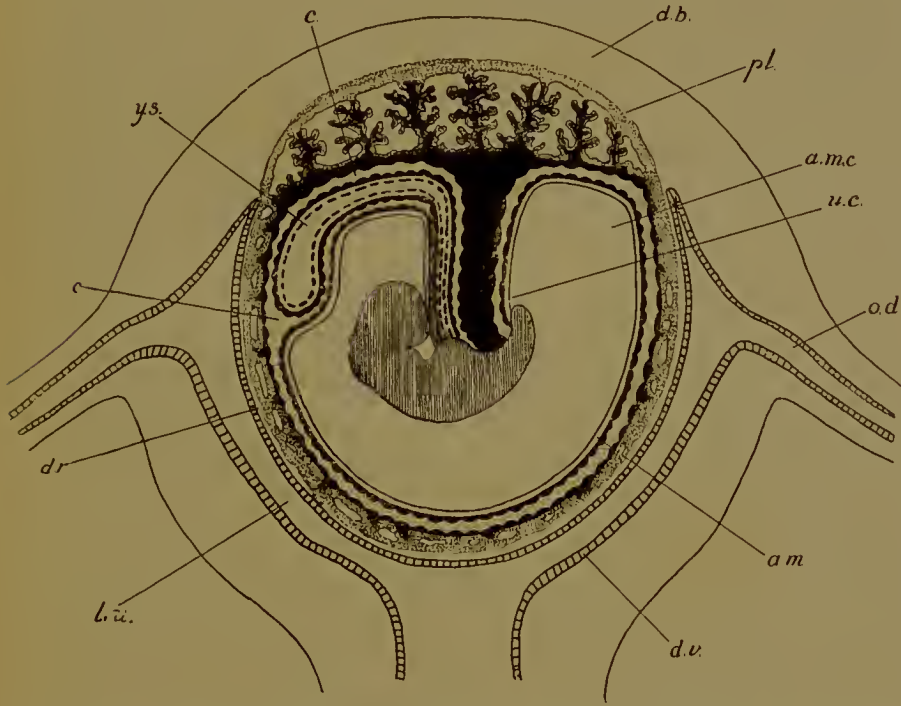


FIG. 139.—Human foetal membranes and placenta. (After Balfour, after Longet.) The amniotic cavity (*am.c.*) has enlarged and occupies nearly the whole of the extra-embryonic coelom (*c.*), being reflected over the umbilical cord (*u.c.*) and yolk-sac (*y.s.*). *d.b.*, decidua basalis (serotina); *d.r.*, decidua capsularis (reflexa); *d.v.*, decidua vera; *l.u.*, lumen uteri; *am.*, amnion; *pl.*, placenta; *o.d.*, oviduct.

but it is not in this early stage ventral in position, but rather posterior and dorsal. Body-stalk (Minot) would be a preferable term. Though we do not know the precise mode of development of these structures, it would probably not be too hazardous to surmise that the amniotic cavity has been formed, as in the guinea-pig, inside the embryonic knob and not by folds, that the extra-embryonic coelom was developed with the first formation of mesoderm, and that the body-stalk is the attachment left

between embryo and trophoblast when this cavity spreads under the yolk-sac and over the amnion. The allantois—or rather the umbilical cord—would not then grow out to reach the trophoblast, for it would have been united with it *ab initio*.

Later on the umbilical cord shifts its insertion on to the ventral side of the body of the embryo, as the hinder end of the latter is folded off inside the amniotic cavity. It retains its original point of union with the trophoblast, for the placenta is formed on this side.

In later stages of gestation the amniotic cavity is greatly enlarged, and the extra-embryonic coelom suppressed. The remains of the yolk-sac is thus squeezed up against the umbilical cord, and the whole invested by the amniotic epithelium (Fig. 139).

(The literature will be found at the end of the following chapter.)

CHAPTER IX

THE PLACENTA

THE placenta is that organ in which the blood-vessels of the embryo are brought into intimate anatomical and physiological relation with the spaces—which may be blood-vessels or lacunae of quite a different character—in which maternal blood is circulating. Though the apposition of foetal to maternal blood-channels is very close, there is yet never any communication between the two ; an injection passed into the maternal will not make its way into the foetal vessels, and conversely. At the same time the tissues that separate the two sets of channels are so thin that substances can readily travel by diffusion from the one to the other. In this way the embryo obtains its oxygen and probably food-stuffs, while by the same means it gets rid of its carbon dioxide and possibly of other waste products of its metabolism. The foetal blood is brought to the capillaries of the placenta by the allantois, which carries umbilical arteries and veins, while the maternal blood-supply is from the uterine vessels. The embryonic tissue which comes immediately in contact with the uterine wall is the trophoblast—the outer or ectodermal layer of the false amnion or chorion,—and it is the trophoblast which ensures the adherence of the embryo to the uterine wall and plays a part of conspicuous importance in the edification of the placenta, particularly in placentas of the so-called ‘deciduate’ type.

In addition to the placenta—this organ formed by the trophoblast and vascularized by the capillaries of the allantois—the embryo has frequently other means of obtaining nutrition. Thus the trophoblast is often phagocytic—in early stages, before the allantois is developed, and in later stages in regions where it is not adherent to the uterine wall, the débris of dead maternal tissues and extravasated maternal corpuscles are devoured by it and passed on to the embryo inside. Again, in several forms, the

yolk-sac with its absorptive epithelium and area vasculosa is instrumental in securing additional nutriment for the foetus. These processes we shall consider individually in the several groups.

Although it has been usual to separate the Eutheria as Placental Mammals from the Marsupials or Metatheria, it must yet be remembered that in the latter group there are arrangements by which the trophoblast is able to secure nourishment for the embryo from the walls of the uterus, which is handed on by means of the area vasculosa of the yolk-sac, and that in one case there is a true allantoic placenta, though it is of a peculiar type, not met with anywhere else.

The Marsupials thus stand apart in this as well as in other reproductive characters (the birth of the young in a very undeveloped condition, the large size of the egg, the presence of an egg-shell, the mode of segmentation, and the structure of the blastocyst), and we shall accordingly consider them separately.

THE MARSUPIALS

The yolk-sac, as we have seen, is large and its upper wall invaginated by the embryo. On this upper wall is an area vasculosa, which extends only a short way over the outer or lower wall, the greater part of the latter being directly in contact with the trophoblast.

In *Didelphys* the trophoblast opposite the area vasculosa of the yolk-sac is a columnar epithelium, thrown into folds. These folds fit into corresponding depressions in the uterine wall from which they appear to absorb nutrient material, which is then handed on to the vessels of the yolk-sac.

In *Dasyurus* the same region of the trophoblast is applied closely to the uterine wall, and there is also beyond the limits of the area vasculosa a conspicuous annular zone of thickened trophoblast (Fig. 122, c). Cell-boundaries disappear and the syncytium so formed sends out pseudopodial processes which attack the uterine epithelium, grow in and enlose portions of it and the subjacent capillaries. The enclosed capillaries enlarge and maternal blood passes in between the trophoblast and the yolk-sac ; presumably it serves as food, for, as we shall see when

we come to the Placentalia, maternal corpuscles are the source from which the embryo obtains its necessary iron.

In *Perameles* there is an allantoic placenta (Fig. 140). Where the trophoblast over the allantois touches the uterine wall the epithelium of the latter thickens to form a syncytium, from which processes grow down into the connective tissue; the syncytium is soon invaded by maternal capillaries. Meanwhile the thin trophoblast has disappeared and the foetal capillaries of the allantois, passing into the irregular depressions on the

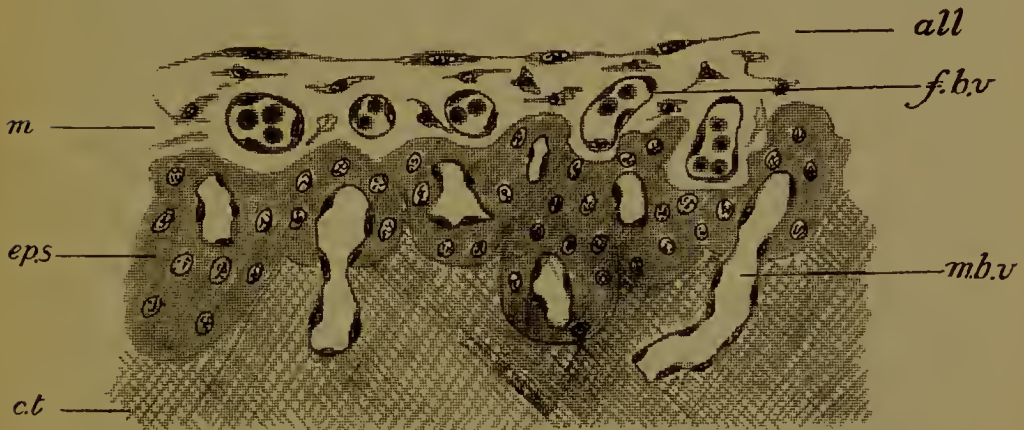


FIG. 140.—Section through the placenta of *Perameles*. (After Hill.) *all.*, allantoic epithelium; *m.*, mesoderm of allantois together with somatopleure of false amnion; *f.b.v.*, foetal blood-vessel; *ep.s.*, syncytium of uterine epithelium; *m.b.v.*, maternal blood-vessels; *c.t.*, subepithelial connective tissue.

outside of the syncytium, are brought into fairly intimate relation with the maternal vessels.

At birth the allantois and its blood-vessels are left behind and absorbed by maternal leucocytes. This condition has been termed 'contra-deciduate'. The same fate befalls the syncytium.

The foetal tissues are similarly absorbed in *Dasyurus*.

THE PLACENTALIA

It has long been the custom to sharply distinguish two principal types of placenta from one another as the Indeciduate and Deciduate. In the former the connexion between foetal and maternal tissues is so slight that at parturition the first

easily separate from the second, no maternal tissue is lost or 'deciduous', and the placenta is 'indeciduate'. In the other type, however, the union of foetal to maternal tissues was held to be so fast that at birth a considerable quantity of the latter was carried away by the former, and there was, in the language of a terminology which was invented when the histology of the placenta was not understood, a 'decidua'. This entirely erroneous conception of the structure of certain types of placenta (found, for example, in Rodents, Insectivora, and the human being), was based on the structure of the placenta in Ungulates. In the Ungulata, as was then well known, the 'indeciduate' placenta arises by the penetration of foetal (chorionic or trophoblastic) processes into crypts or depressions in the uterine wall, from which crypts the processes or villi are readily pulled out at birth. Not unnaturally, in ignorance of the facts, it was surmised that the 'deciduate' placenta originated in similar fashion, with the difference that the chorionic villi adhered so closely to the crypt walls that at birth they dragged away not only crypts but connective tissue and blood-vessels as well.

Thus the term 'decidua' came to be applied to the tissue of the uterine wall, whether an embryo and placenta were present or not.

Now while it is true that the placenta of the Carnivora is developed in this kind of way, modern research has conclusively shown that in the majority of the so-called 'Deciduates' the genesis of the placenta proceeds on an entirely different plan. If, therefore, we retain the name 'deciduate' for the placenta of the Rodents, Insectivora, Cheiroptera, and some Primates (*Tarsius*, Monkeys, and Man), it must be on the distinct understanding that the word bears its original meaning no longer. The term 'indeciduate' is not inapplicable to the Ungulate placenta, and there is no objection to its use.

We shall begin with the Ungulate as exhibiting structurally the simplest type.

UNGULATA

In Ungulata the placenta is of the indeciduate form. At the surface of the chorionic sac there are produced finger-shaped processes or villi, formed of a single layer of trophoblast, and

provided with a core of mesodermal tissue in which are the foetal capillaries. The endodermal epithelium of the allantois is not continued into the villi. These villi fit into depressions in the wall of the uterus known as crypts. The crypts are lined by an epithelium which is perfectly continuous with the ordinary epithelium of the uterus and persists throughout gestation. The persistence of the uterine epithelium is the real mark by which the indeciduate is distinguished from other placentas. Below the epithelium of the crypts are the maternal capillaries and connective tissue. The villi do not adhere closely to the crypt

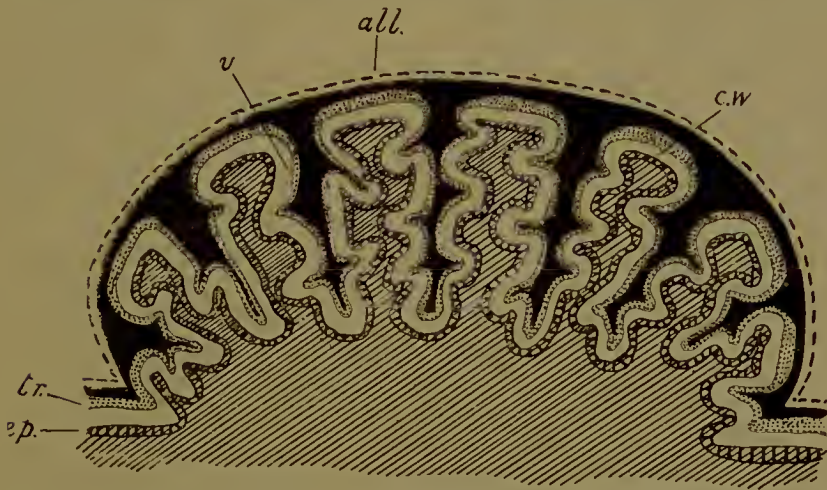


FIG. 141.—Diagram of a foetal and maternal cotyledon of the cow. *all.*, allantoic epithelium; *tr.*, trophoblast; *v.*, villus; *ep.*, uterine epithelium continued into crypt; *c.w.*, wall of crypt. The maternal connective tissue is shaded.

walls, and at birth are easily removed without damage to the maternal tissues.

The Ungulate Placenta may be Diffuse, or Cotyledonary, or of an intermediate type. In the first the whole surface of the chorionic sac is covered uniformly with villi which may be simple (as in the pig) or branched (as in the horse) (Fig. 131). In the cotyledonary placenta the villi are gathered together into bunches or cotyledons, the intervening regions of the chorion being smooth (Fig. 141). The villi—which are much branched—fit into crypts of a corresponding shape, the whole aggregation of crypts for the reception of the villi of a single cotyledon being termed a maternal cotyledon. The points in the wall of the uterus

where these maternal cotyledons will be formed are predetermined and recognizable as raised areas—the cotyledonary caruncles—before gestation, can be seen indeed in the uterus of the unborn calf. The foetal cotyledons are scattered all over the surface of the chorion, except at its extreme ends, the ‘diverticula allantoidis’ so called.

A cotyledonary placenta is characteristic of the Ruminants.

In some cases (*Cervus*, *Giraffa*, *Oreas*, *Tetraceros*) the placenta is of an intermediate type, simple villi being found between the cotyledons.

As examples of indeciduate placentation we may take the cow and sheep.

Before describing the anatomy and physiology of the actual placenta it will be convenient first to consider the changes that take place in the wall of the uterus preparatory to the reception of the embryo, as well as the nutrition of the embryo while it is still free in the uterine cavity.

In the period known as the ‘pro-oestrus’, which precedes heat or ‘oestrus’, the subepithelial connective tissue of the uterus becomes hypertrophied, while the capillaries increase in number and become enlarged. Numbers of corpuscles—both haematids and leucocytes—are now extravasated from these swollen blood-vessels into the surrounding stroma of connective tissue, where many of the haematids are devoured and digested by leucocytes with the resultant deposition of pigment in the cytoplasm of the latter. This brown pigment, derived from the haemoglobin of the extravasated corpuscles, may remain in the wall of the uterus for a considerable time. Meanwhile, as a result possibly of the pressure exerted by the congested capillaries, the uterine epithelium has given way; patches of it degenerate and are cast into the uterine lumen along with some debris of sub-epithelial cells, haematids, and leucocytes. The fluid in the uterus already contains proteid, glycogen, and fat secreted by the uterine epithelium and glands. In this fat-secretion the outer ends of the cells, containing fat-globules, are nipped off and ejected. There are also present (in the sheep) rod-like or needle-shaped bodies, composed of an albuminous substance and secreted by the epithelium. Iron, too, is found, derived from the digested

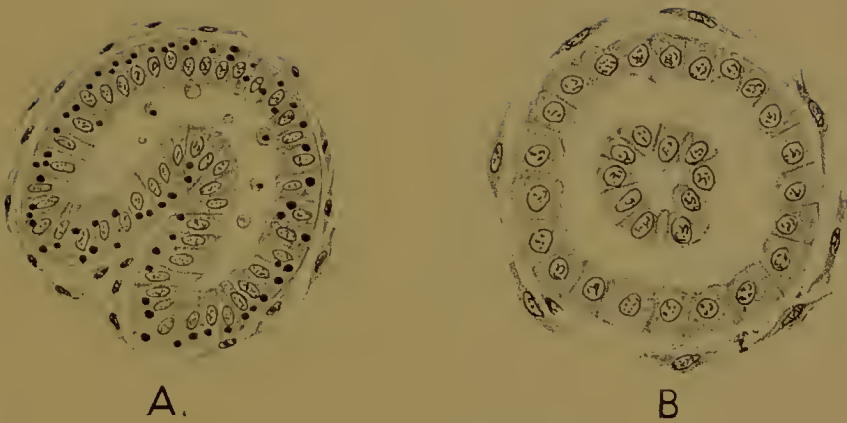


FIG. 142.—Cellular secretion in the glands of the uterus. A, horse (after Kolster); B, dog (after Bonnet). In A a piece of the epithelium is being invaginated into the lumen of the gland. In B this has been nipped off. In A the secretion of fat (black globules) and pieces of cells is also shown.

haemoglobin of the extravasated haematids. To all this must be added the products of the cellular secretion of the glands (Fig. 142). Small tracts of the epithelial wall become invaginated into the gland-lumen, are cut off, degenerate, and are thrown out by the mouths. The secretion of fat and proteid, of the albuminous rod-shaped bodies and of cell-masses by the glands, is not confined to the period of 'pro-oestrus' but occurs throughout gestation.

The material thus provided is of a thick, viscid consistency and of a yellow colour, like pus, and is known as 'uterine milk'. It is of the greatest importance for the nutrition of the embryo.

Ovulation or the escape of the ovum from the Graafian follicle occurs in 'oestrus': the ovum passes into the Fallopian tube, where fertilization takes place. Development begins and the blastocyst enters the uterus. Here the trophoblast at once begins to absorb the nutriment prepared for it. The cells are phagocytic and ingest solid particles of the uterine milk: they also absorb fat and possibly iron.

The blastocyst next becomes attached by its trophoblast to the uterine wall, and the placenta is formed.

The uterine epithelium, where destroyed, has now been restored. In the cotyledonary caruncles it is continued into the crypts, which are now developed. If we may judge of what happens now by what is known of the manner in which accessory maternal cotyledons are formed in the later stages (in the cow), the crypts arise (Fig. 143) by a pitting of the columnar ciliated epithelium, the cells which are at the bottom of the pits becoming shorter than the ordinary columnar cells around (*a*), followed by the outfolding of the epithelium between the pits (*b*); into these folds connective tissue soon penetrates (*c*), and later blood-vessels.

Villi or finger-shaped processes of the trophoblast are now formed and enter the crypts. The epithelium lining the latter soon becomes modified, the cilia are lost, and the cells become cubical (*d*, *e*) (in the cow) or very flat (in the sheep). Even in the latter case, however, small patches of cubical cells remain, from which fresh crypts are formed by downgrowth into the subepithelial tissue (Fig. 144).

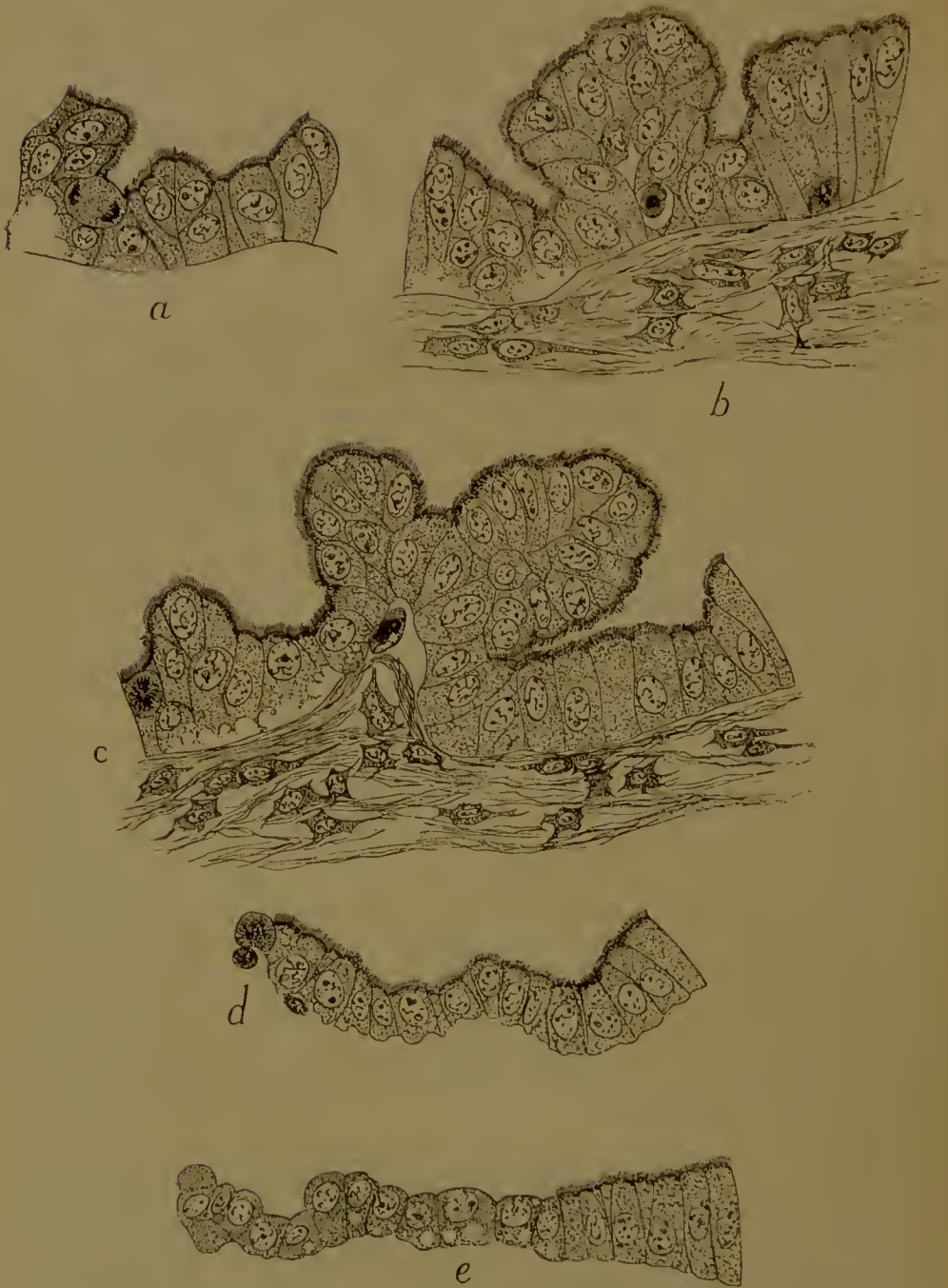

FIG. 143.—*a-e*, Five stages in the formation of a crypt in the cow. *a-c*, pitting and folding of the epithelium; *d*, the epithelium becomes cubical; *e*, the cilia are lost.

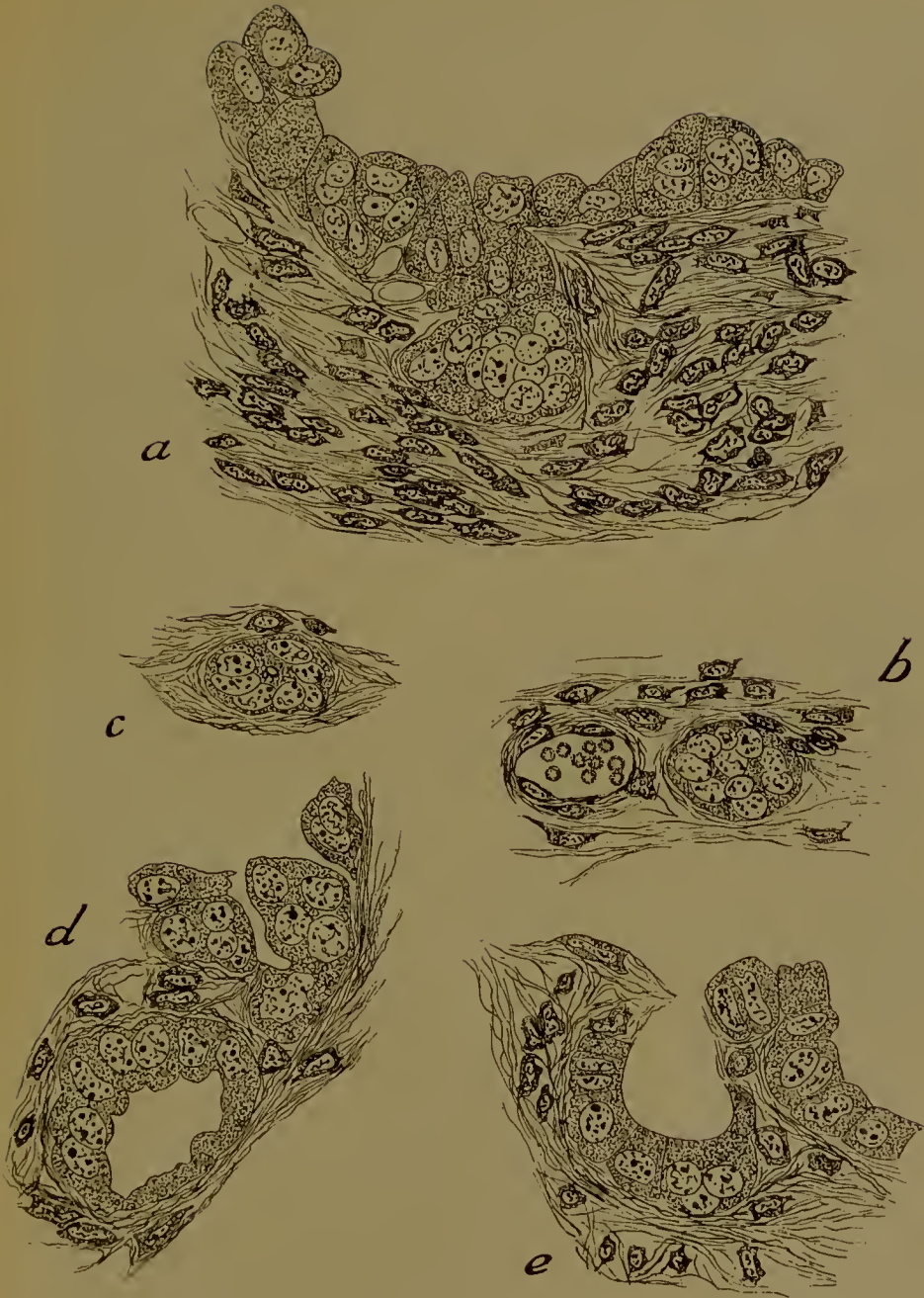

FIG. 144.—Formation of accessory crypts in the sheep. In *a* and *b* the downgrowth of epithelium is still solid; in *c* it is becoming hollow; in *e* it is open to the old crypt.

With continued development the villi and crypts elongate and branch repeatedly, and the maternal cotyledon is raised above the level of the uterine wall (Fig. 141). The free surface is convex in the cow, but deeply concave in the sheep, where also the base of attachment is constricted to a narrow stalk.

In the cow the trophoblast covering the villi is composed of rounded or cubical elements, amongst which are gland-cells and curious oval binucleate cells (found also in the sheep). The core of each villus is occupied by connective tissue (somatopleure of the false amnion plus splanchnopleure of the allantois) and foetal capillaries, the latter very close to the epithelial cells (Fig. 145, 1).

The crypt is lined by cubical cells which secrete fat and proteid, the ends of the cells with the contained fat-globules being protruded, pinched off, and thrown into the space between crypt and villus. Fat can be demonstrated in the trophoblast, which doubtless absorbs the proteid also. The gland-cells may be of importance in this respect.

Below the epithelium in the crypt-walls are maternal connective tissue and maternal capillaries. The foetal and parental blood-streams are thus separated by the endothelium of the foetal capillaries, some connective tissue (not always), the trophoblast, the epithelium of the crypts, the connective tissue, and the endothelium of the maternal vessels. Through these layers oxygen diffuses from maternal to foetal blood, and carbon dioxide in the reverse direction; other substances may also pass. In the cotyledons, therefore, the respiratory exchange takes place and the absorption of fat and proteid.

It is, however, not merely by means of its cotyledonary villi that the embryo obtains nutrition. At the bases of the villi and therefore opposite the summits of the walls between the crypts the trophoblast is very tall and columnar (Fig. 145, 2). The outer ends of the cells are pseudopodial and ingest quantities of cell-débris and maternal red blood-corpuscles. The capillaries at the summits of the crypt-walls are gorged, blood is extravasated, and together with the remains of epithelial and sub-epithelial cells eagerly devoured by the trophoblast, and digested.

The ingested haematids get clumped together in the cells, and often surrounded by a food-vacuole (Fig. 145, 3). As intra-

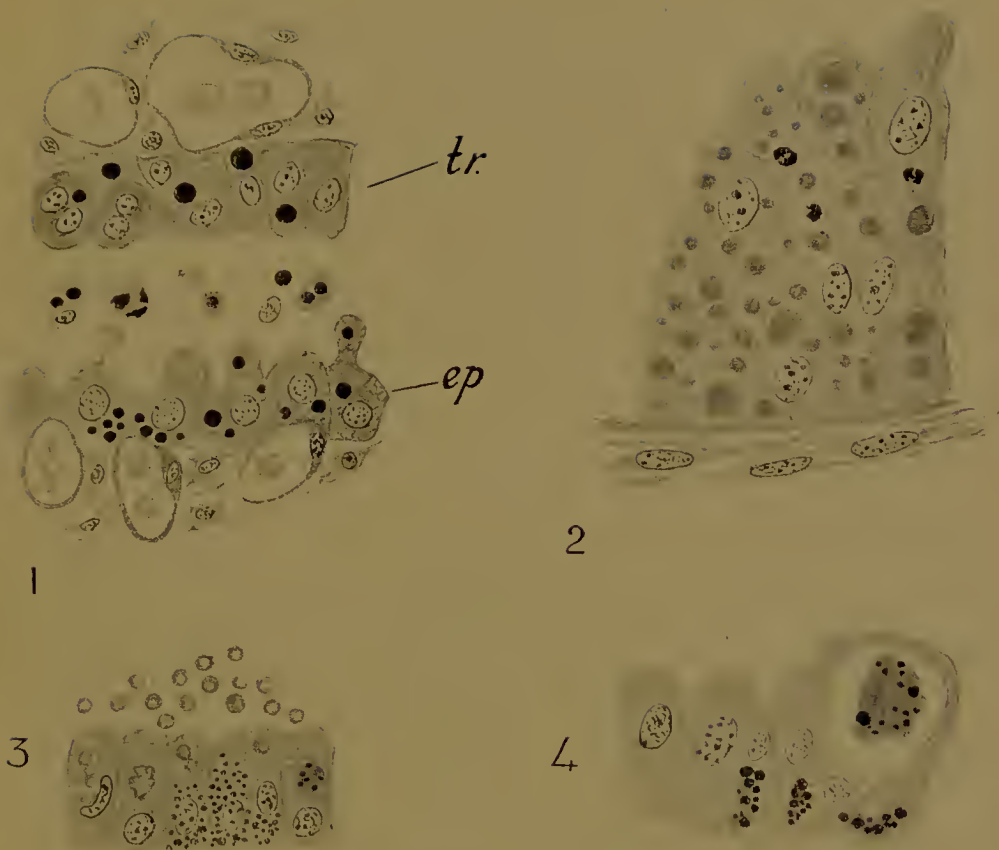

FIG. 145.—Histology of the placenta in the cow and sheep.

1, Foetal and maternal tissues in a cotyledon. *tr.*, trophoblast of a villus; the cells are absorbing fat (black). In the trophoblast are two binucleate cells. Behind the trophoblast are the connective tissue and blood-vessels of the allantois. *ep.*, uterine epithelium lining a crypt. Fat secretion is going on, the ends of the cells with fat-globules being pinched off and thrown into the lumen of the crypt. Below the epithelium are the maternal capillaries and connective tissue.

2, Columnar trophoblast cells from between the bases of the cotyledonary villi. The cells are full of ingested matter (corpuscles, nuclear, and cell debris).

3, Ingestion of extravasated maternal corpuscles by the trophoblast in the sheep. The corpuscles are seen inside the cells. The cells also contain pigment.

4, Deposition of pigment after digestion of the haemoglobin of ingested corpuscles in trophoblast cells of the cow. The pigment-granules (black) are seen to be deposited on irregular masses in the cells.

cellular digestion proceeds little granules of yellow-brown pigment appear on the surface of the mass, and gradually the whole assumes the same colour (Fig. 145, 4). The pigment probably contains no iron, at least when digestion is completed, the iron of the haemoglobin having been separated and carried off to the embryo by the blood of the allantois. Thus the foetus obtains its necessary iron in this as in earlier stages from the haemoglobin of extravasated maternal corpuscles, devoured by the trophoblast. The pigment remains in the trophoblast, where large quantities of it are accumulated by the end of gestation. In neutral solution it shows two bands very nearly in the position of those of oxyhaemoglobin, in acid solution two bands almost exactly in the position of those of acid haematoporphyrin, but in alkaline solution not the four bands of alkaline haematoporphyrin, but only the two seen in the neutral solution. It is probably related to haematoporphyrin: it is certainly a haemoglobin derivative, and from it bile-pigments may be formed.

We have already had occasion to notice the curious rounded or elongated, often flattened bodies, sometimes soft, sometimes hard and brittle, found floating in the allantoic fluid and familiar for many centuries under the title of 'hippomanes'.

In the cow they are white or pale yellow, in the sheep a dirty brown. In the sheep they are formed by local accumulations of the viscid uterine milk, which get into pockets of the trophoblast, between the cotyledons. Gradually, pushing the trophoblast and allantois in front of them, they make their way into the cavity of the latter, in which they lie attached by a stalk to the wall; the stalk narrows and breaks, and they are free in the cavity. At first they are surrounded by a membrane—the remains of their covering of allantois and trophoblast—and are soft: they are composed of a granular coagulable material, full of cell-detritus, degenerating nuclei, globules of fat and glycogen, and leucocytes. Later the membrane disappears, and the bodies become hard by being saturated with calcium oxalate in the form of 'envelope' crystals. In the cow, when outside the chorion and still soft, they are a bright orange colour, due to the presence of bilirubin, doubtless derived from the extravasated corpuscles eaten by the trophoblast; they are, indeed,

found at the bases of the villi, just where these extravasations occur.

Large allantoic bodies impregnated with calcium oxalate are found in the horse.

Small quantities of glycogen are found in the uterine epithelium and subepithelial tissues, and in the uterine milk. Much larger quantities are found stored up in the amniotic thickenings—masses of stratified epithelium on the inner surface of the amnion. Towards the end of gestation the glycogen diminishes, and the cells undergo fatty degeneration and are impregnated with calcium oxalate. As the glycogen diminishes the dextrose in the amniotic fluid increases (from 1% to 0.37%).

Glycogen also occurs in the trophoblast, in the connective tissue of the chorion and in the umbilical cord round the blood-vessels and allantoic epithelium. In the body of the embryo it is abundant in all tissues, except in the liver, where it only appears late, when it is disappearing from the others.

The glycogen in the amniotic bodies appears to be a reserve store. We shall find a similar storage of glycogen in other cases.

Besides dextrose the amniotic fluid contains albumin, mucus, and chlorides of sodium and potassium.

In the allantoic fluid are dextrose (0.3%), albumin, mucin, magnesium, sodium, and calcium phosphates, sodium chloride and sulphate, and 'envelope' crystals of calcium oxalate; further, a yellow pigment, and allantoin, the embryonic representation of urea.

It appears, therefore, that the allantois is a receptacle for the waste products of foetal metabolism.

Cetacea. In *Orca* the placenta appears to be indeciduate and diffuse, uniformly studded with villi. The chorionic sac extends into both cornua of the uterus. The villi, which are branched, are only absent at the ends, opposite the Fallopian tubes, and again opposite the os uteri.

Sirenia. *Halicornis* possesses an indeciduate, diffuse placenta. It is known that the uterine epithelium persists in the crypts. The villi, which are slightly branched, are limited to an annular area surrounding the chorionic sac, not quite in the middle of the latter. When the region of the trophoblast, which enters

into such intimate relations with the uterus as to form a placenta, is of this annular shape, the placenta is spoken of as zonary. (A zonary placenta may be of the deciduate type.)

Hippomanes are found in *Halicore*, but there are no amniotic bodies.

Proboscidea. In the elephant the shape of the placenta is zonary, though diffuse villi occur at the ends of the chorionic sac. These villi appear to be of the nature of those found in Ungulates. In the zonary region the villi appear to have become embedded in the wall of the uterus by their ends, while maternal blood is extravasated between their bases. In the absence of more exact information this placenta cannot be properly classified. Brown pigment abounds in the trophoblast of the villi, presumably a haemoglobin derivative.

Hyracoidea. In *Hyrax* the placenta is zonary in shape, with villous patches at the poles.

EDENTATA

The placenta is stated to be bell-shaped in *Myrmecophaga* and *Tamandua*, zonary in *Orycteropus*, oval in *Dasypus*, diffuse in *Manis* and *Choloepus*, but we have no knowledge of its minute structure.

LEMUROIDEA

In this, the lower division of the Primates, the placenta is of the diffuse indeciduate type (except in *Tarsius*, which must certainly be placed with Monkeys and Man).

In *Galago* (Fig. 146) the chorionic sac is large and occupies both horns of the uterus. It is covered with short simple villi at the extremity of each of which is a slight pit, the cells of which contain granular greenish masses (? haemoglobin derivatives). The villi lie in grooves lined by a persistent epithelium, from which they are easily pulled out. The chorionic vesicles are invaginations of the trophoblast opposite depressions in the uterine wall at the bottom of which glands open. Both chorionic vesicles and depressions are filled with a granular material—uterine milk—which appears to be absorbed by the villi which spring from the floor of the vesicle.

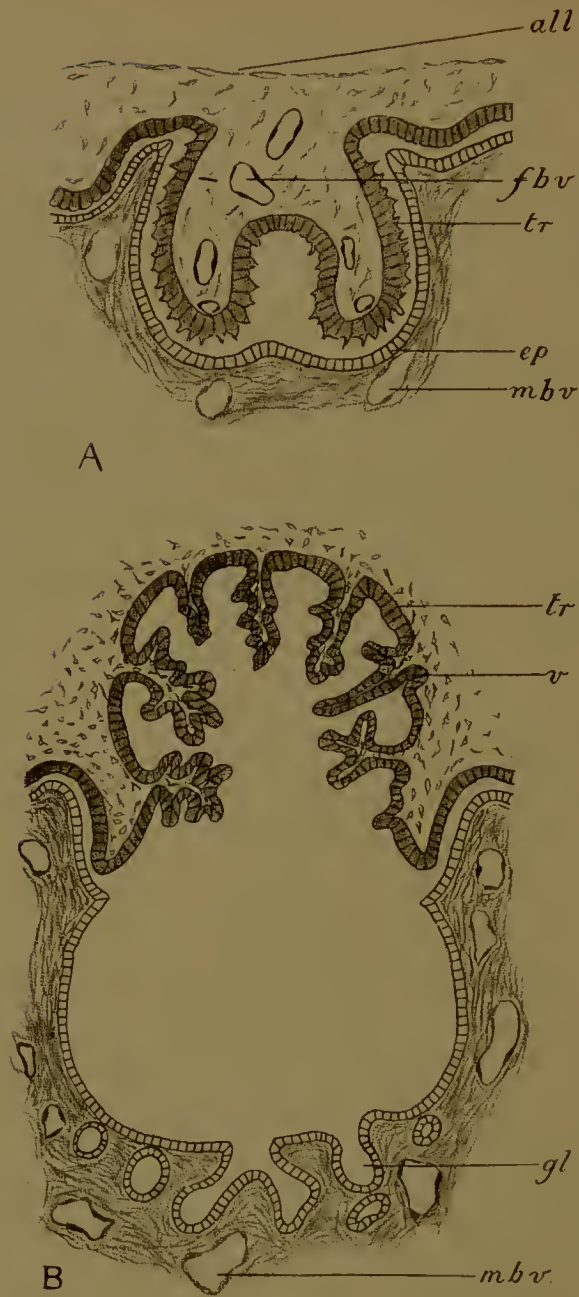


FIG. 146.—Placenta of the lemur *Galago*. (After Strahl.)

A, Section of a villus with the crypt in which it is lodged. The uterine epithelium (*ep*) lining the crypt persists; *m.b.v.*, maternal blood-vessel; *all.*, allantois epithelium; *f.b.v.*, foetal blood-vessel; *tr.*, trophoblast.

B, Section through a chorionic vesicle and the opposed depression of the uterine wall; *tr.*, trophoblast; *v.*, small branching villi protruding into the chorionic vesicle; *gl.*, glands opening into the uterine depression; *m.b.v.*, maternal blood-vessels.

CARNIVORA

In the Carnivora we meet with a group which is from the comparative anatomical point of view of the greatest importance, since the placenta here holds an intermediate position between the Indeciduate and Deciduate (so-called) types. While in the disappearance of the uterine epithelium it must be ranked with the latter, it differs widely from them in the fact that the channels in which the blood of the mother circulates are the capillaries of the uterine wall, between which the trophoblast has penetrated after the destruction of the superficial epithelium. In this mutual apposition of foetal vessels and maternal vessels the Carnivorous does indeed resemble the Ungulate type, from which it may conceivably have been derived, and comes very near to fulfilling the original definition of a 'deciduate' placenta, since at birth the maternal vessels and connective tissue are removed along with the foetal constituents. The shape of the placenta is always zonary. The genera most carefully investigated are the dog and cat.

We begin with a description of the processes preparatory to the reception of the embryo.

In the period of pro-oestrus prior to 'heat' the uterus becomes swollen and hyperaemic owing to the multiplication and enlargement of the blood-vessels and capillaries. Blood is extravasated first into the subepithelial tissue, and masses of brown pigment appear, as the result, presumably, of the digestion of the haemoglobin by the abundant leucocytes. Soon the superficial columnar epithelium gives way, and quantities of haematids with a certain amount of destroyed epithelial and connective tissue are discharged into the lumen of the uterus.

The uterine glands are long and twisted, and branch; they apparently secrete some proteid material and masses of cells in the way already described in the Ungulata (Fig. 142). In addition there are the crypts, short tubular downgrowths of the epithelium.

During the following period of oestrus a regeneration of the destroyed epithelium takes place. Should fertilization have occurred the blastocyst is developed and makes its way into the

uterus, in the placental regions of which the following changes now occur.

While the blastocyst is still unattached fat appears in the superficial epithelium of the uterus, and in that of the necks of the glands and crypts. The necks of the glands widen, so giving rise to the 'spongy' layer. A thick layer of dense subepithelial tissue is formed, in which run the capillaries. The surface epithelium next becomes lower, while its nuclei begin to degenerate, and eventually the whole epithelium disappears. The openings of the crypts and glands are closed by masses of enlarged epithelial cells which, uniting to form syncytia, soon show signs of degeneration (Fig. 147, A).

Attachment now occurs. In the zonary placental region the trophoblast is produced into finger-shaped villi—which may be solid or provided with a core of mesoderm—and these villi make their way into the connective tissue from which the epithelium has now been removed, as well as into the plugs of degenerating syncytia closing the mouths of the crypts and glands. To these syncytia are added the cellular secretions of the glands.

The cells of the trophoblast are phagocytic and devour all this detritus. Where the trophoblast invades the connective tissue between the crypts and gland it comes into intimate relation with the capillaries there, and as soon as the villi have been penetrated by the foetal blood-vessels the placenta may be said to have been established (Fig. 147, B).

Below the placenta are the wide parts of the glands, separated only by thin lamellae of connective tissue in which run the larger blood-vessels. By these lamellae the placenta is attached to the muscularis.

The placenta so formed is at first thin, but soon grows in thickness by the simultaneous elongation of the trophoblastic villi and of the connective tissue which covers them and includes the maternal capillaries (Fig. 147, C). The villi meanwhile branch, the branches being thin sheets (perpendicular to the surface) and radiating out from the original villi: the foetal blood-vessels of course branch correspondingly, as do, on the other side, the maternal connective tissue and capillaries. In the cat certain large cells are present in between the maternal capillaries which are possibly hypertrophied connective tissue-cells, but

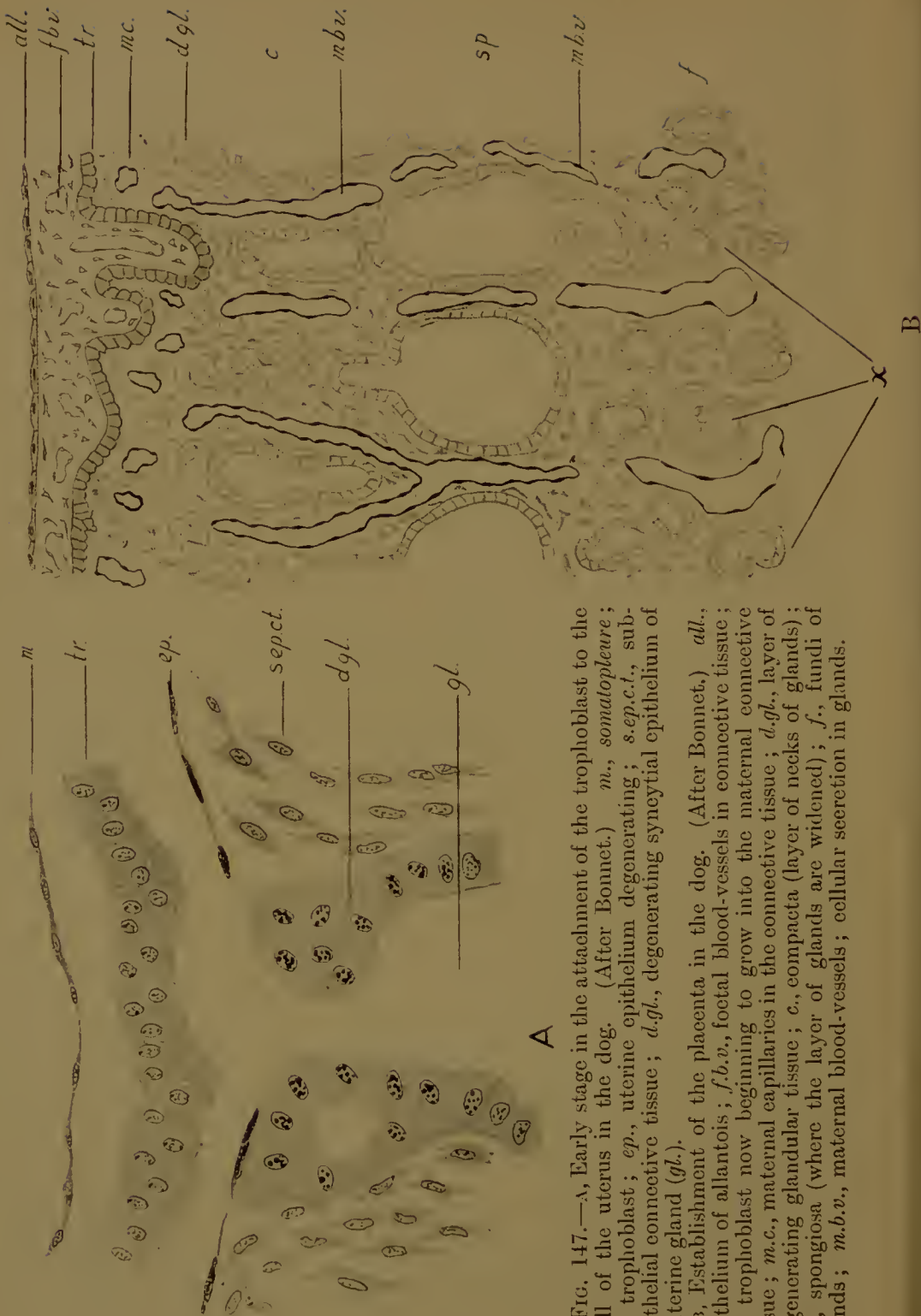
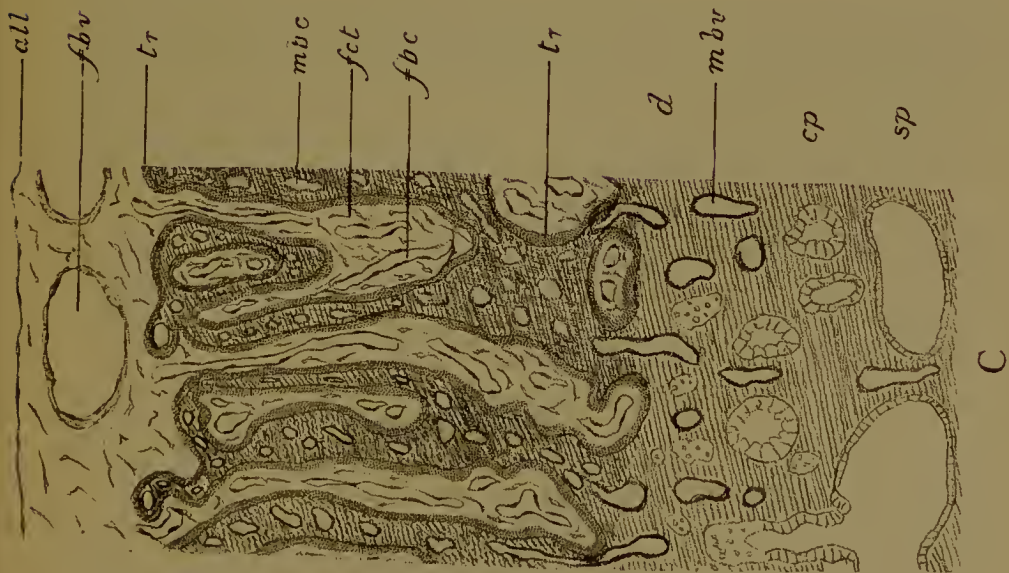
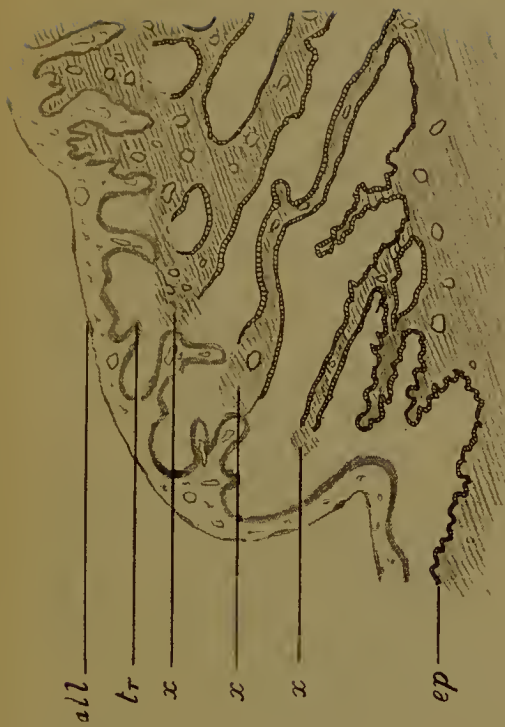
FIG. 147.—A, Early stage in the attachment of the trophoblast to the wall of the uterus in the dog. (After Bonnet.) *m.*, somatopleure; *tr.*, trophoblast; *ep.*, uterine epithelium degenerating; *s.ep.c.t.*, sub-epithelial connective tissue; *d.gl.*, degenerating syncytial epithelium of a uterine gland (*gl.*).

B, Establishment of the placenta in the dog. (After Bonnet.) *all.*, epithelium of allantois; *f.b.v.*, foetal blood-vessels in connective tissue; *tr.*, trophoblast now beginning to grow into the maternal connective tissue; *m.c.*, maternal capillaries in the connective tissue; *d.gl.*, layer of degenerating glandular tissue; *c.*, compacta (layer of necks of glands); *sp.*, spongiosa (where the layer of glands are widened); *f.*, fundi of glands; *m.b.v.*, maternal blood-vessels; cellular secretion in glands.



C



D

FIG. 147.—C, Section through the placenta and uterine wall of the cat. *all*, epithelium of allantois; *f.b.v.*, large foetal blood-vessels; *f.b.c.*, foetal capillaries; *f.c.t.*, foetal connective tissue; *tr.*, trophoblast (stippled); *m.b.c.*, maternal blood capillaries; these are immediately surrounded by maternal connective tissue (shaded); *m.b.v.*, maternal blood-vessels passing through the layer of glandular detritus (*d.*); *cp.*, compacta (necks of glands); *sp.*, spongiosa (dilations of glands).

D, Edge of the placenta (green border) of the dog. (After Duval.) *all.*, allantoic epithelium; *tr.*, trophoblast lining the pockets of the chorion in which extravasated maternal blood is lodged; *x*, *x*, *x*, points at which extravasation occurs; *ep.*, uterine epithelium.

they may be trophoblastic (Fig. 148). The trophoblast at the base of the placenta continues to ingest and absorb the cell-débris and fat supplied by the glands up to the end of gestation.

A feature of great physiological interest is the 'green border', a system of pockets in the trophoblast along both edges of the placenta filled with masses of extravasated maternal blood, to which extravasation indeed the formation of the pockets is due (Fig. 147, D). Leucocytes are present, fibrin, and a green pigment (haematochlorine), a derivative of haemoglobin; what its relation is to biliverdin is not known. There is also a yellow-brown pigment, and, at the end of gestation, a black one. All this material is ingested by the trophoblast. The green border is poorly developed in the cat.

It will be evident that the placenta we have just considered is made of a compound tissue, foetal in the trophoblast and connective tissue and capillaries of the allantois, maternal in the connective tissue and capillaries surrounded and engulfed by the invading villi.

The placentas we have still to study are not constructed on this plan, for though they have this much in common with that of the Carnivora, that the uterine epithelium disappears, yet they differ wholly from it in that the maternal blood circulates not in blood-vessels enclosed by the trophoblast but in lacunae, excavated in that tissue, into which extravasated maternal blood is poured. No maternal tissue, therefore, is lost at birth except the blood, apart from fragments of connective tissue adherent to the maternal side of the placenta.

A placenta of this kind is found in the Rodents, Insectivora, Cheiroptera, and, amongst the Primates, in *Tarsius*, Monkeys, and Man. We shall begin with the Rodents.

RODENTIA

The placenta is always discoidal in shape, and attached to the mesometric side of the uterus.

As an example we may take the mouse. The uterine cavity is bounded by a columnar epithelium in which fat is secreted. Into it open glands with long necks. These secrete a coagulable, presumably proteid, material. These secretions are absorbed

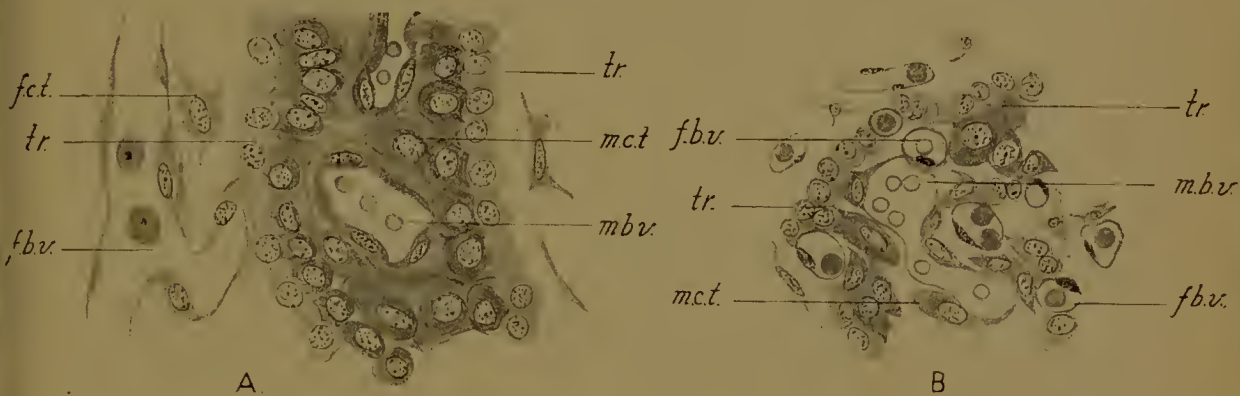


FIG. 148.—Histology of the placenta of the cat. A, Earlier; B, later stage (full time). *f.ct.*, foetal connection tissue; *tr.*, trophoblast (pale); *m.ct.*, maternal connective tissue (dark); *f.b.v.*, foetal capillary; *m.b.v.*, maternal capillary.

FIG. 149.—Five stages in the formation of the placenta in the mouse.

A, The blastocyst free in the uterus.

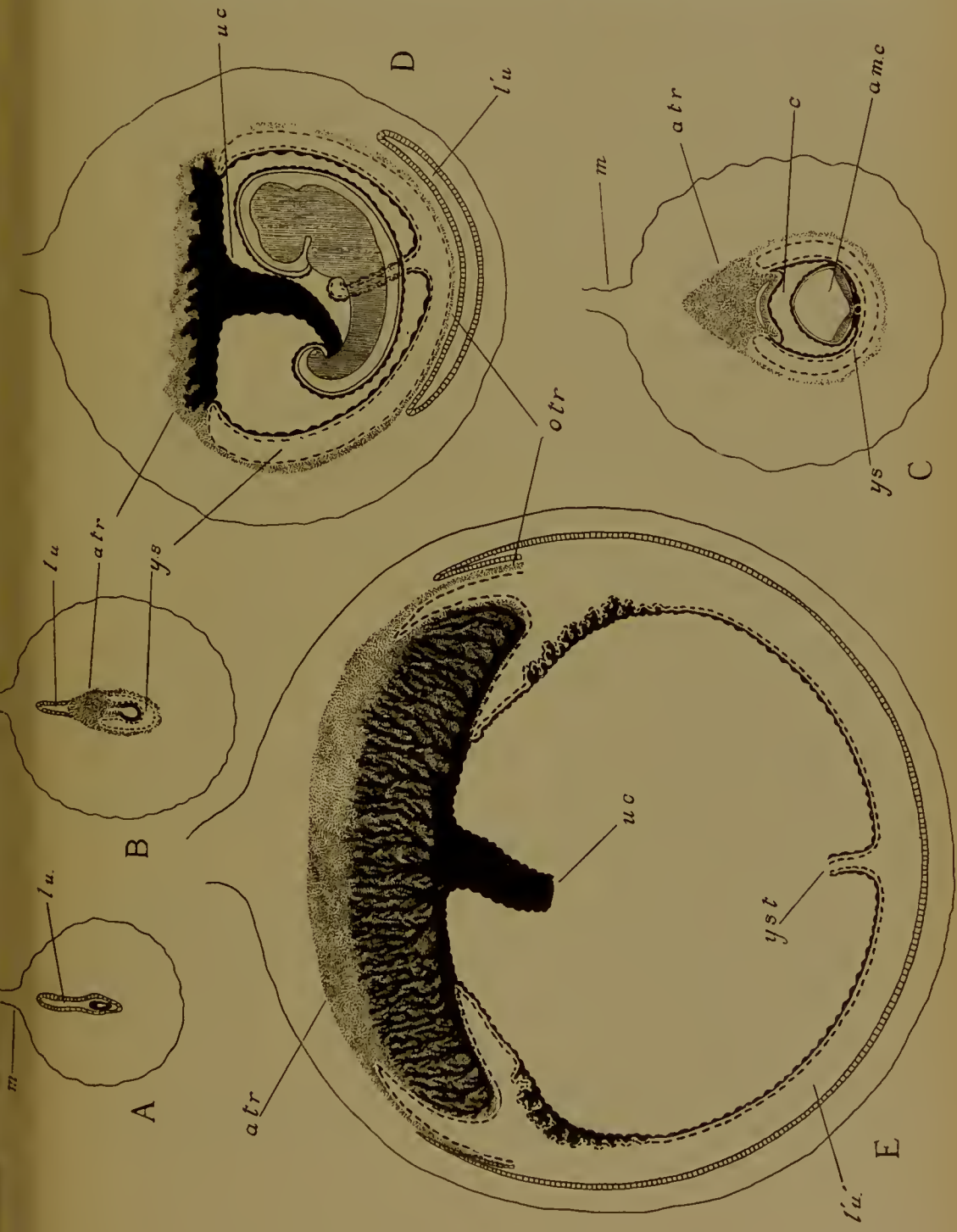
B, The blastocyst attached and the placental thickening of the allantoic trophoblast developed (*a.tr.*).

C, Later stage, after closure of the amniotic cavity (*am.c.*).

D, The foetal blood-vessels beginning to penetrate the allantoic trophoblast.

E, Elaboration of the placenta. Disappearance of the distal wall of the yolk-sac and omphaloidean trophoblast (*o.tr.*).

l'u', new uterine lumen on the anti-mesometric side; *l.u.*, original lumen of the uterus; *y.s.*, yolk-sac; *y.st.*, yolk-stalk; *u.c.*, umbilical cord; *m.*, mesometrium.



by the free blastocyst (Figs. 149, A ; 150, A). There is prepared for the reception of the blastocyst a pit on the antimesometric side of the uterus. This pit lies in the middle of a pronounced swelling, due to the hypertrophy of the subepithelial connective tissue and enlargement and multiplication of the blood-vessels. To this tissue may be applied Hubrecht's term ' trophospongia '. By it the glands are driven away towards the muscularis, their necks stretched and eventually broken. The mouse produces a large litter of young, and there is a correspondingly large series of these swellings along the uterus. The pit in the middle of each swelling is open freely to the main cavity of the uterus (towards the mesometrium), and in each pit a blastocyst is lodged with its embryonic pole towards the opening of the pit. It is at this pole that the trophoblast will thicken to form the placenta, which is therefore on the mesometric side (Figs. 149, B ; 150, B).

Where the trophoblast touches the sides of the pit the epithelium, clothing the latter, now disappears, the cells becoming cubical, then flat, and finally vanishing. The nuclei are resolved into spherules of chromatin, the cytoplasm undergoes fatty degeneration. The fat is absorbed by the trophoblast. The trophoblast is thus brought into immediate contact with the subepithelial tissues.

The same degradation later attacks the epithelium at the bottom of the pit, and later still extends to that lining the main uterine lumen above it. This lumen then disappears and each embryonic pit is isolated, as also are the inter-embryonic regions of the uterus. At a subsequent stage a fresh lumen will be formed on the anti-mesometric side of the embryo, and this re-unites the inter-embryonic regions with one another and once more there is a continuous uterine lumen.

At the embryonic pole the trophoblast now thickens and drives the embryonic knob towards the opposite end, so invaginating the upper wall of the yolk-sac ; the amnion is then developed and separated from the temporary cavity in the trophoblast as the extra-embryonic coelom extends between the two in the fashion already described.

This thickening is the precursor of the placenta. It extends towards the mesometrium and is at first conical (Figs. 149, c ;

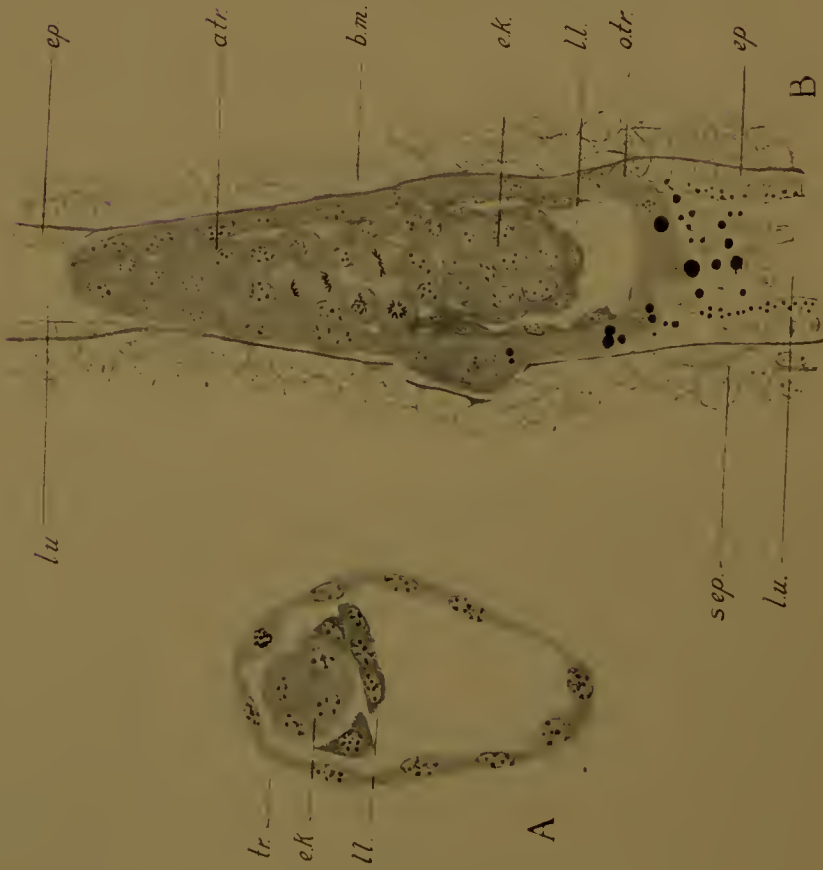

FIG. 150.—Placentation of the mouse. Details of the five stages of Fig. 149.

A, The blastocyst free in the uterus. *tr.*, trophoblast; *ek.*, embryonic knob; *ll.*, lower layer.

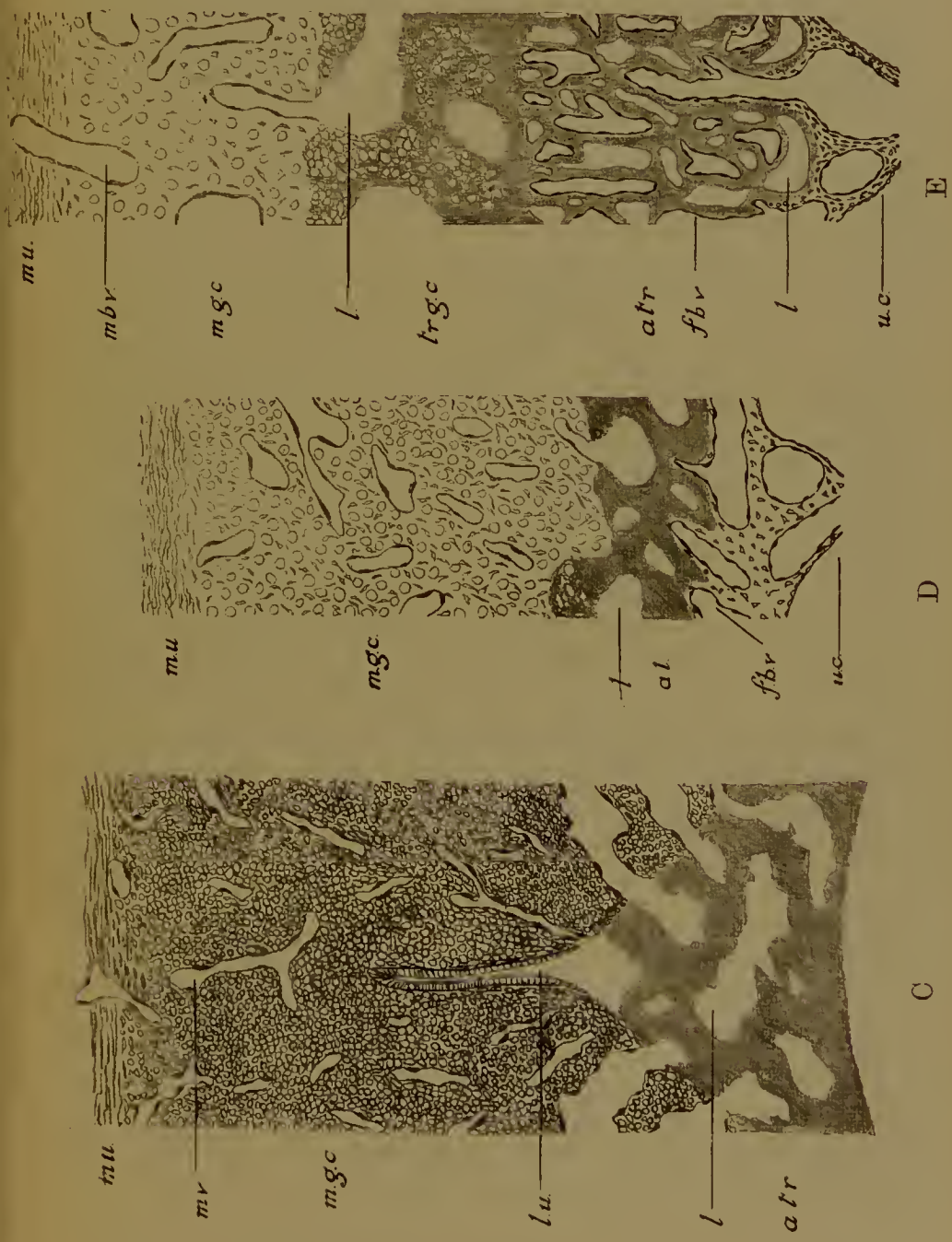
B, (slightly younger than stage B). *ep.*, uterine epithelium above and below the blastocyst; at the sides it has disappeared; *b.m.*, basement membrane of this epithelium which is being pushed away by the trophoblast at one point (on the left); *s.ep.*, sub-epithelial uterine tissues. Other letters as before. The black globules are globules of fat.

Fig. 150.—Placentation of the mouse. Details of the five stages of Fig. 149.

C, Strip of a section through the allantoic-dean trophoblast and overlying maternal tissues in stage C. *mu*, muscularis; *m.v.*, maternal blood-vessel, opening below into *l*, lacunae of the trophoblast; *m.g.c.*, maternal glyeogenic tissue. Other letters as before.

D, Similar strip of the same parts in stage D. *f.b.v.*, foetal blood-vessel; *u.c.*, umbilical cord. Other letters as above.

E, Similar strip of the last stage. *tr.g.c.*, trophoblastic glyeogenic tissue. Other letters as before.



150, c), but soon becomes discoidal as the embryo in its amnion and extra-embryonic coelom enlarge. It is in contact with the distended uterine capillaries, and very quickly these burst and the extravasated maternal blood is poured into irregular spaces or lacunae excavated in the trophoblast. Many of the haematids are phagocytically devoured by the trophoblast (Fig. 151, 8). The blood enters these spaces in the centre, leaves them by a number of wide vessels at the periphery. At its base this trophoblast remains cellular, but elsewhere it becomes syncytial by the disappearance of cell-boundaries; the two regions have been termed respectively cyto- and plasmodi-trophoblast. Between the blood-vessels that supply these trophoblastic lacunae is the subepithelial connective tissue (Fig. 151, 7), and this soon undergoes an important modification. While some of the cells remain unaltered—fusiform or stellate in shape—as a supporting tissue, others become rounded and filled with globules of glycogen. The cells, though fairly closely packed, are distinct from one another. The nucleus is spherical, not very chromatic, and has one nucleolus. We shall speak of this tissue as the maternal glycogenic tissue (Fig. 151, 4). It is at about the zenith of its development by the time the foetal blood-vessels reach the placenta.

The future placental region of the trophoblast may be distinguished as 'allantoidean' from the 'omphaloidean' region, which lies immediately against the distal wall of the yolk-sac and therefore on the anti-mesometric side. The cells here become enormously hypertrophied and their nuclei correspondingly enlarged (hence the term 'megalokaryocytes'): in the nuclei there are large nucleoli, and the chromatin is in irregular strings. They are incapable of mitosis. In contact with the subepithelial tissues they eagerly devour débris of degenerate cells, leucocytes and the haematids, which are abundantly extravasated in this region also (Fig. 151, 6, 9). They apparently play an important rôle in the nutrition of the embryo during this stage, prior to the development of the allantois, but later they are less important and disappear long before the end of gestation. Presumably the stuffs they have digested are passed on by means of the area vasculosa of the yolk-sac to the embryo.

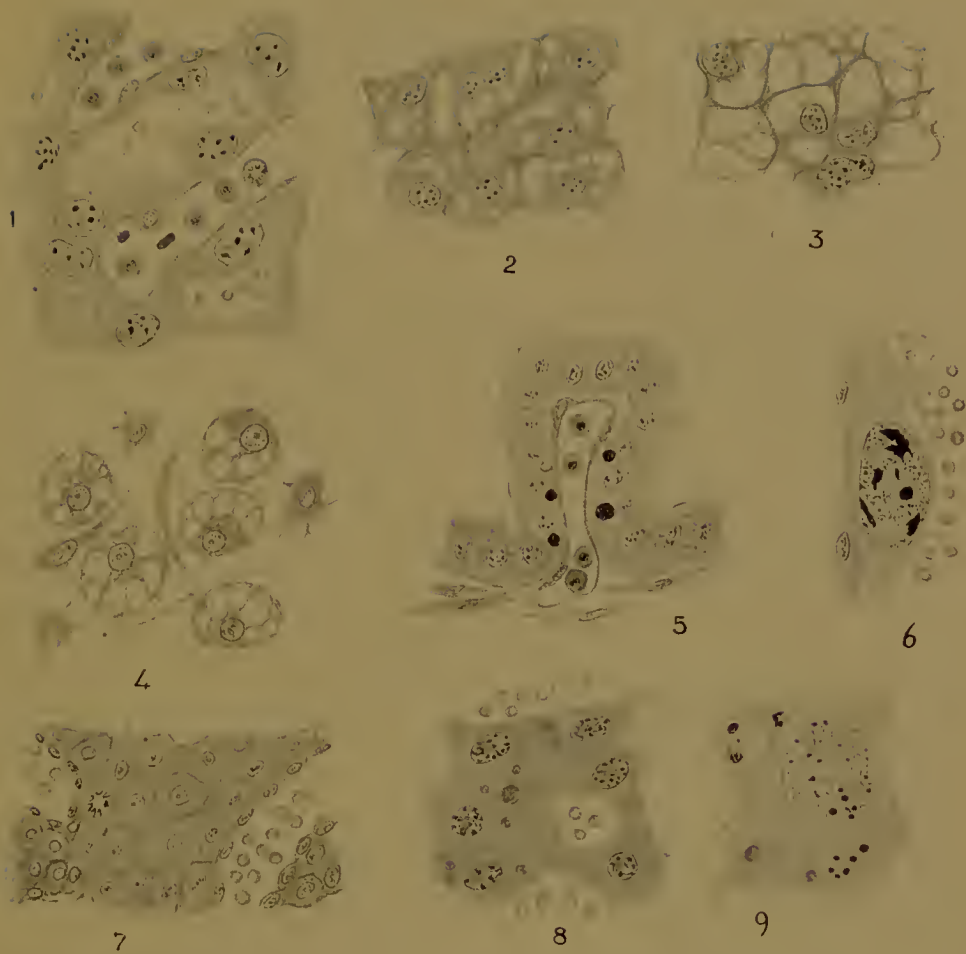


FIG. 151.—Histology of the placenta of the mouse.

1, Foetal capillaries (with nucleated corpuscles) lying alongside the lacunae of the trophoblast (stage E).

2, 3, Early and late stages of glycogenesis of the trophoblast (stages E and later).

4, Maternal glycogenic cells with intervening connective tissue-cells (stage D).

5, Fold of epithelium on the proximal wall of the yolk-sac with blood-vessel (stage E).

6, Megalokaryocyte from the omphaloidean trophoblast. On the right extravasated maternal corpuscles, on the left the flat epithelium of the distal wall of the yolk-sac (stage D).

7, Closely packed maternal sub-epithelial tissue with blood-vessels (stage C).

8, Allantoidean trophoblast, the cells ingesting maternal corpuscles (stage C).

9, Megalokaryocyte of the omphaloidean trophoblast ingesting corpuscles and detritus of maternal cells (stage C).

In the next stage (Figs. 149, D; 150, D) the allantois is developed, grows with its blood-vessels across the coelom, reaches the somatopleure at the base of the allantoidean trophoblast, and sends its capillaries into the latter in between the lacunae. The necessary relation between the foetal and maternal circulations which constitutes a placenta is now established. Further change is mainly one of growth.

Firmly fixed in the trophoblast the capillaries soon elongate and branch, mostly parallel to one another and perpendicular to the surface of the placenta. The trophoblast with its lacunae keeps pace, and so the whole organ, attaining a thickness many times greater than that which it originally possessed, comes ultimately to project button-like towards the centre of the uterus (Figs. 149, E; 150, E). The trophoblast lining the lacunae becomes finally much attenuated except for the protrusions due to the rather large nuclei (Fig. 151, 1).

On the foetal side of the placenta are somewhat large lacunae to which blood is brought by channels passing directly through the centre of the placenta; hence it passes into the smaller lacunae round the foetal capillaries and so into the efferent maternal vessels which leave the organ peripherally. The capillaries of the allantois, however, never penetrate the whole thickness of the trophoblast. On the maternal side there is a layer, increasingly broad, between the ends of the foetal vessels and the maternal tissues, a layer only traversed by the large channels which lead to and from the smaller lacunae (Fig. 150, E). In this layer the secretion of glycogen begins at the stage when the allantois has just reached the trophoblast, and soon attains enormous dimensions (Fig. 151, 2, 3). The whole tissue consequently appears highly vacuolated. The cells—if we may indeed speak of cell-boundaries—are oblong, the nuclei oval, rich in chromatin and provided with several nucleoli, thus differing from the maternal glycogen cells. We shall speak of this as the trophoblastic glycogenic tissue.

The previously differentiated maternal glycogenic tissue ceases to grow further, with the enlargement of the whole uterus the constituent cells get separated, the glycogen cells having given up their glycogen collapse, disintegrate, and disappear, and only

the supporting cells are left between the maternal blood-vessels. Upon the space so left vacant the trophoblastic glycogen tissue encroaches, engulfing the blood-vessels as it does so, and finally extends as far as the muscularis.

There can be no doubt that this tissue holds in reserve a store of food material for the use of the embryo. As sugar the glycogen passes into the maternal vessels and into the lacunae, and so is absorbed by the foetal capillaries. When the glycogen is used up the cells collapse, and their collapse may be a factor in determining the moment of parturition, since it is across this layer that the placenta breaks away. The trophoblastic is much more voluminous than the maternal glycogenic tissue ever was.

In the omphaloidean regions important changes have meanwhile occurred. A new lumen has been formed on the anti-mesometric side, placing the inter-placental portions of the uterus once more in communication with one another. This new lumen (Fig. 149, D, E, *l'.u'*) is separated from the cavity of the yolk-sac by (1) the distal wall of the yolk-sac, (2) the omphaloidean trophoblast, (3) the subepithelial tissues, and (4) the epithelium. All these layers cease to grow, become passively stretched, and finally rupture, disintegrate, and disappear.

The yolk-sac now opens freely into the uterine lumen, and the richly folded columnar epithelium (Fig. 151, 5) of the upper wall is able to absorb the fat and proteid material secreted by the uterine epithelium and glands. Thus the yolk-sac acts and continues to act till the end of gestation as an accessory organ of nutrition. It also forms a protective envelope, since its edge is inserted into the margin of the placenta. This edge is later carried up some little way on the outer surface of the placenta, the base of attachment of the latter to the uterine wall being narrowed, while at the same time the yolk-sac is inflected on the foetal side towards the insertion of the umbilical cord.

In a placenta of this type the foetal is only separated from the maternal blood by the endothelium of the capillaries and the trophoblastic lining of the lacunae, the foetal connective tissue being in the last stages negligible. There is no penetration of foetal tissues into maternal (except for the encroachment of

the glycogenic tissue of the trophoblast on the space between the maternal blood-vessels), and there is no maternal tissue in the organ but the blood in the lacunae (except again the blood-vessels in the glycogenic region). The relation between maternal and foetal blood-streams is brought about by the fastening of the trophoblast upon the subepithelial tissues after the destruction of the uterine epithelium; once fixed there lacunae are excavated in it in which extravasated maternal blood circulates, and it is finally vascularized from the foetal side by the capillaries of the allantois.

In the guinea-pig (*Cavia*) the blastocyst is placed in a pit on the anti-mesometric side; it comes into contact with the subepithelial tissues by burrowing beneath the epithelium, which is then destroyed. The original lumen of the uterus is obliterated in the embryonic swellings; a new lumen is formed anti-mesometrically, and the tissues between it and the upper wall of the yolk-sac are distended and disintegrate, thereby placing the yolk-sac in continuity with the uterine cavity, precisely in the way already described for the mouse, except that the lower wall of the yolk-sac has never been present. The placenta is discoidal and mesometrically placed; it is developed from a thickening of trophoblast at the embryonic pole of the blastocyst. On its maternal side is an abundant glycogenic tissue, but whether this is of maternal or foetal origin, or both, has not been determined.

In the rabbit and squirrel no anti-mesometric pit is formed for the reception of the blastocyst. In the rabbit there are on the mesometric side two prominent folds, the placental folds, and in the future embryonic regions these become greatly thickened by the proliferation of the subepithelial tissue and blood-vessels (trophospongia). They have been termed 'cotyledons', but the expression is here inapplicable. To these two swellings the blastocyst attaches itself by the trophoblast behind and at the sides of the embryonic plate; the latter is at the surface when Rauber's cells have disappeared, but sinks inside when the amnion closes (Fig. 152).

The uterine epithelium, where touched by the trophoblast now disappears, and the latter is brought into immediate contact

with the subepithelial tissue and blood-vessels. The blood-vessels are to a very slight extent engulfed by the growing trophoblast, but their endothelial walls soon break down and their extravasated blood is discharged into lacunae excavated in the trophoblast, now much thickened and syneytial (plasmodi-

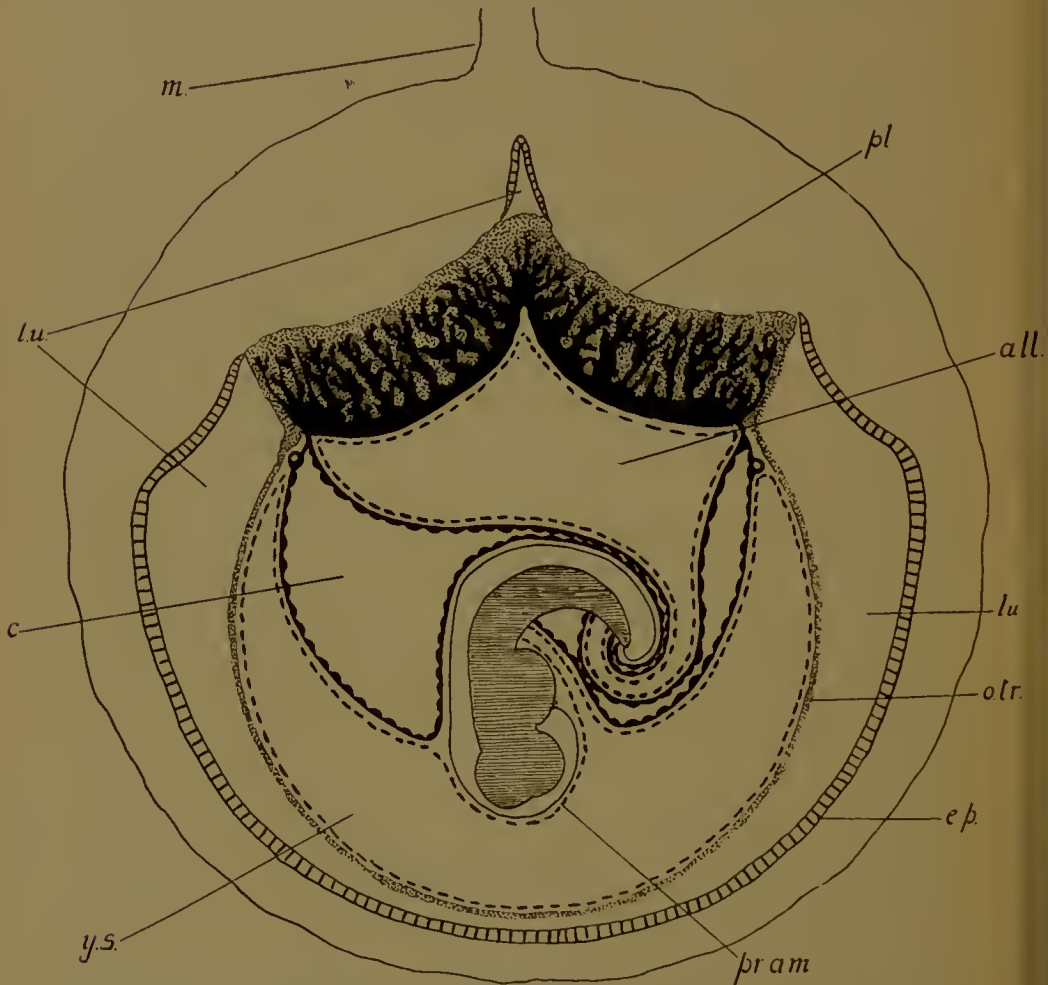


FIG. 152.—Foetal membranes and placenta of the rabbit. *pr.am.*, pro-annion. Other letters as before. (After Duval and Van Beneden.)

trophoblast), except at its base, where cell-boundaries remain (cyto-trophoblast). The allantoic capillaries then make their way into the trophoblast and the placenta is established.

The trophoblast with its lacunae and the foetal tissues grow *pari passu*; the placenta thus increases in thickness and projects

into the uterine cavity. In shape it is discoidal, but made up of two distinct halves or lobes, due to the attachment of the trophoblast to the two enlarged placental folds.

There is a voluminous glycogenic tissue on the maternal side, stated to be entirely of maternal origin. A good deal of it is, however, probably trophoblastic. It has been shown that the glycogen of the placenta increases up to the twenty-first day of gestation, but then diminishes till the end (twenty-ninth day). The glycogen in the foetal liver, which is at first almost negligible, increases rapidly during the last week of pregnancy. A glycogen splitting ferment has also been isolated from the placenta; it is found, too, though less active, in the overlying maternal tissues. In the placenta, therefore, the embryo has a means of controlling the glycogen metabolism; but this function is taken on by the foetal liver towards the close of gestation. The yolk-sac in these forms also is an accessory organ of nutrition. The lower wall disappears, the cells of the upper wall then absorb material from the uterine cavity, and pass it on to the embryo by means of the area vasculosa.

CHEIROPTERA

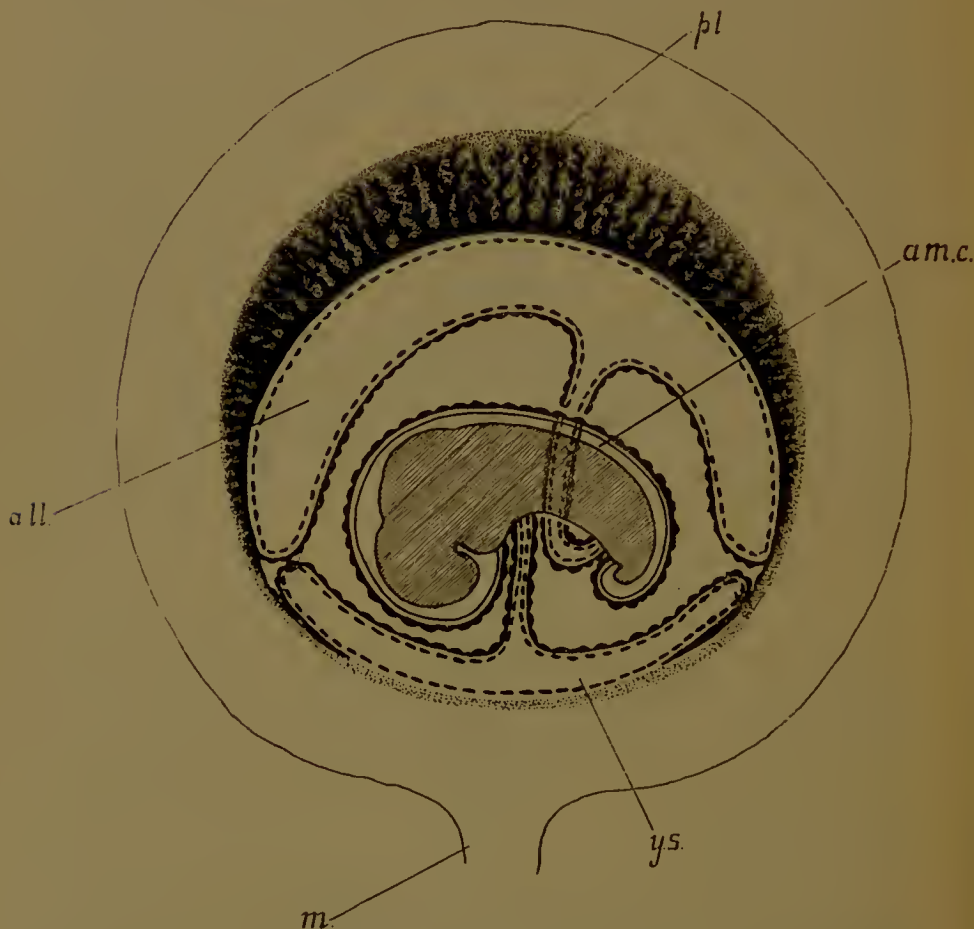
In *Vespertilio* there is a discoidal placenta, or rather, since it is concave, saucer-shaped or bell-shaped (Fig. 153).

The blastocyst attaches itself by its embryonic pole to the anti-mesometric side of the right cornu of the uterus: only one is present at a time.

Below the epithelium the connective tissue has thickened, and the blood-vessels have increased in number and size. The uterine epithelium disappears, and the trophoblast then fixes itself by invading the subepithelial tissue and engulfing some of the superficial capillaries. The endothelium of these capillaries then degenerates, and they are indistinguishable from the lacunae formed in the way with which we have become familiar in the Rodent placenta.

The blood-vessels of the yolk-sac are at first applied to this mass of trophoblast, but as soon as the allantois is developed it pushes the yolk-sac away and sends its capillaries into the trophoblast. The placenta increases in thickness by the simul-

taneous growth of capillaries and lacunar trophoblast, and in area by an extension at the edges of the same process by which it was formed. After the first fixation there is no further penetration of the maternal by the foetal tissues.



[FIG. 153.—Foetal membranes and placenta of the bat (*Vespertilio*).
(After Nolf.) Letters as before.

On the anti-embryonic side (mesometrie) the uterine epithelium also disappears, the fatty débris, together with that of the underlying connective tissue, being eaten up by the trophoblast.

In *Pteropus* the placenta is discoidal but mesometrie: the uterine epithelium seems to disappear.

INSECTIVORA

In this order the placenta is again discoidal, and usually concave; but in *Tupaia* there are two placentas, one right, the other left, at the sides of the uterus, and in *Centetes* a large number. Where there is only one (*Erinaceus*, *Sorex*, *Talpa*) it is anti-mesometric in position.

In all cases the uterine epithelium disappears in that region where the placenta is formed: the thickened trophoblast fastens on the subepithelial tissues, and lacunae are formed in it; in

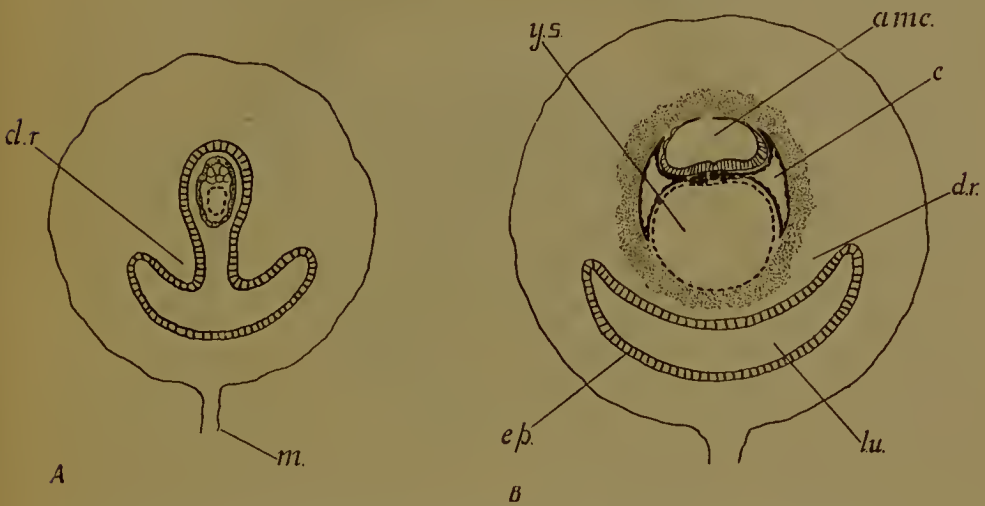


FIG. 154.—Two stages in the formation of the decidua reflexa of the hedgehog. (After Hubrecht.) *d.r.*, decidua reflexa. Letters as before.

these the maternal blood circulates. The whole is then vascularized from the foetal side by the allantoic capillaries.

In *Erinaceus*, the hedgehog, the most interesting feature is the formation of a 'decidua reflexa' or 'capsularis' resembling the structure known by that name in human embryology.¹ On the anti-mesometric side of the uterus there are formed two thick folds by the proliferation of the subepithelial vascular tissue (trophospongia). Between these two folds the blastocyst is lodged with its embryonic pole turned away from the mesometrium (Fig. 154, A). By the closure of the lips of the folds

¹ It is highly probable, however, that the human 'reflexa' is formed in a different manner. (See below.)

and obliteration of the cavity in front and behind this point the blastocyst is securely shut up in a coat of maternal tissue, the 'decidua reflexa' (Fig. 154, B). The whole of the trophoblast now thickens enormously, becomes syneytial, destroys and devours the epithelium lining the cavity which lodges it, while into the lacunae hollowed out in it quantities of maternal blood are soon discharged from the adjacent swollen capillaries. The

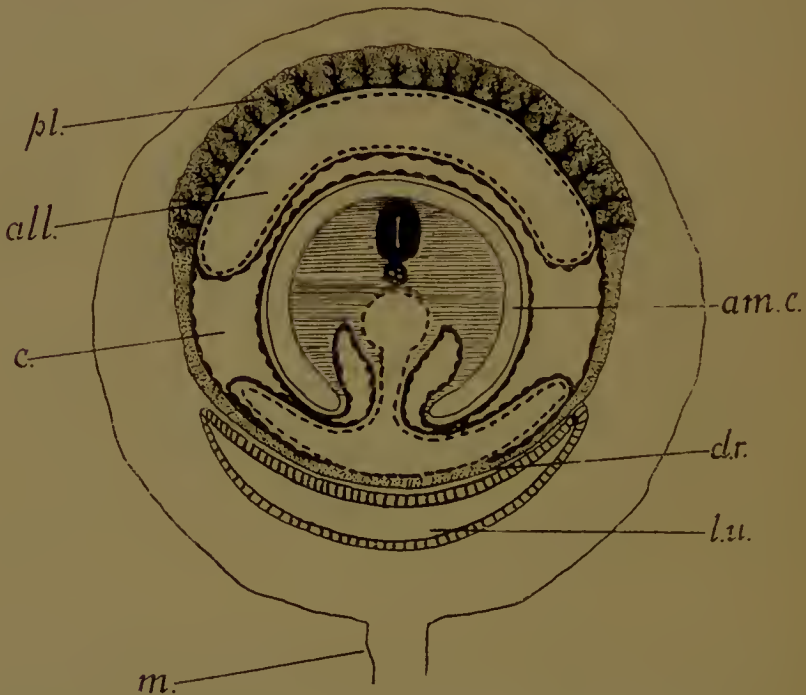


FIG. 155.—Foetal membranes and placenta of the hedgehog. (After Hubrecht.) *l.u.*, lumen uteri; *d.r.*, decidua reflexa. Other letters as before.

yolk-sac and omphaloidean trophoblast, against which its lower wall lies, are at the anti-embryonic end, that is, towards the covering 'decidua reflexa', while towards the opposite end the allantois grows out and reaches the 'allantoidean' trophoblast. It is from this part that the placenta is formed (Fig. 155), the foetal capillaries being driven into the trophoblast between the lacunae. The whole grows in thickness.

The 'deciduofracts' are phagocytic trophoblastic cells which eat up the maternal tissues adjoining the placenta.

In the omphaloidean region relations are at first established

between the yolk-sac and the trophoblast with its lacunae. But as the allantoic placenta becomes increasingly functional the yolk-sac dwindles in importance and is folded up under the 'decidua reflexa'. By the extension of the uterine cavity round

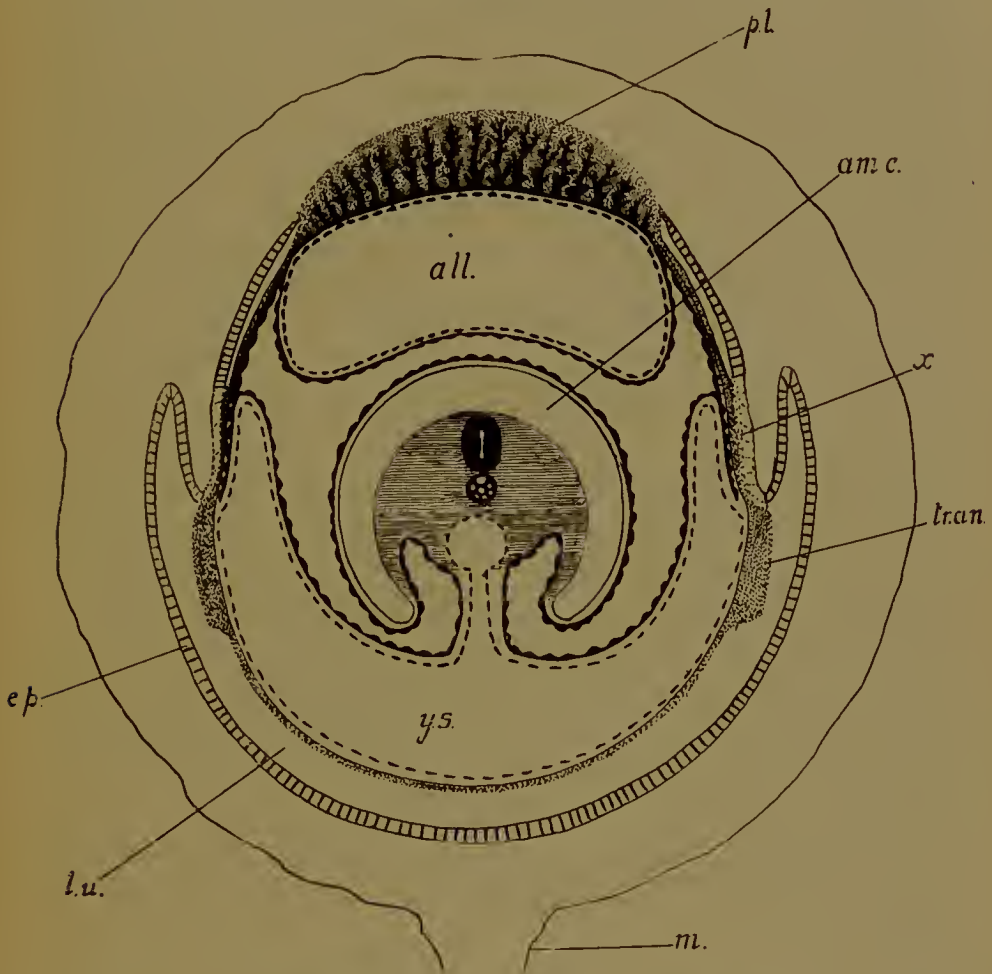


FIG. 156.—Foetal membranes and placenta of the shrew (*Sorex*). (After Hubrecht.) *x*, point where the omphaloidean trophoblast is in contact with the maternal tissues; *tr.an.*, trophoblastic annulus, or thickening of trophoblast below *x*.

the base of the placenta the 'reflexa' is enlarged, and surrounds the embryo on all sides except at the placenta. It becomes stretched, and the trophoblast beneath it much attenuated.

In the mole (*Talpa*) the uterine epithelium is also destroyed on the mesometric (non-placental) side; the trophoblast comes into immediate contact with the subepithelial tissues. At birth

the allantoic capillaries are pulled out of the placental trophoblast, which remains behind to be absorbed by the leucocytes of the mother. This arrangement is known as 'contra-deciduate'.

In *Sorex* (Fig. 156) there is, prior to the attachment of the trophoblast in the placental region, a conspicuous proliferation of the uterine epithelium with concomitant development of crypts between the glands on the anti-mesometric side. Into these the syncytial trophoblast makes its way, and then the epithelium is destroyed. The further stages in the development of the placenta are similar to those occurring in other forms.

Laterally there are also independent proliferations of the uterine epithelium to which the trophoblast becomes attached. The fused maternal and foetal tissues afterwards degenerate together and are dehisced from the wall; the continuity of the uterine lumen is then restored. The area vasculosa of the yolk-sac which had been applied to this region is at the same time detached. Further towards the anti-embryonic pole there is an annular thickening of the trophoblast. The cells are here phagocytic and ingest quantities of extravasated maternal haematids. Digestion of these presumably takes place in the trophoblast, since a bright-green pigment (? haemoglobin derivative) fills the yolk-sac. The iron would then be carried off by the blood-vessels of the area vasculosa. At the anti-embryonic pole the trophoblast is thin and not attached to the uterus; here the epithelium persists.

In *Tupaia* the yolk-sac, which has at first relations with the placental regions of the trophoblast, is later displaced by the allantois.

TARSIUS, MONKEYS, AND MAN

As we have already had occasion to see, the aberrant Lemur *Tarsius* agrees with Monkeys and the human being in the possession of a diminutive yolk-sac (provided, nevertheless, with an area vasculosa), a large and precociously developed extra-embryonic coelom, and a rudimentary allantois which only extends far enough outside the body of the embryo to penetrate the base of the ventral or body-stalk, which connects the embryo in its amnion and with its yolk-sac to the wall of the blastocyst and

is to be developed into the umbilical cord. Such an arrangement of the foetal membranes is found nowhere else amongst the Mammalia. We have now to inquire whether in the origin and minute structure of the placenta there is an equally complete agreement.

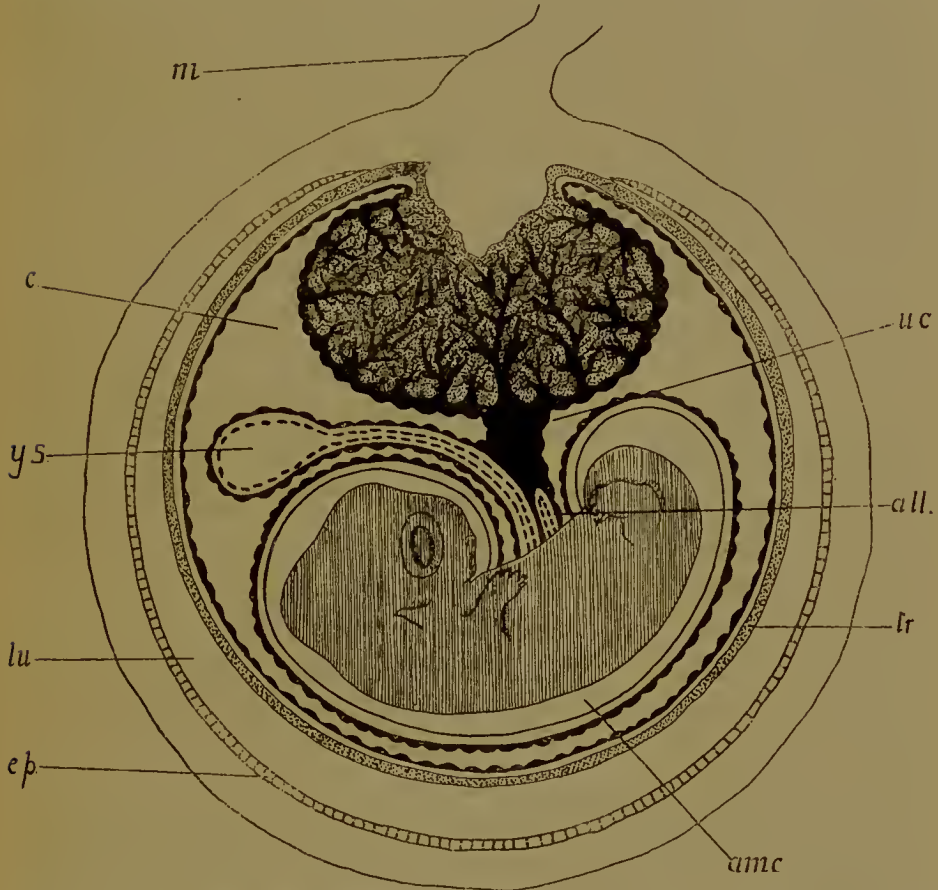


FIG. 157.—Foetal membranes and placenta of *Tarsius*. (After Hubrecht.)
Letters as above.

In *Tarsius* alone is the complete history of the placenta known, and there is no doubt whatever here at any rate that the placenta is of that type which prevails in Rodents, Insectivores, and Chiroptera. In form it is discoidal, or rather button-shaped, protruding into the uterine cavity; it is developed at the anti-embryonic pole of the blastocyst, and is placed on the mesometric side of the uterus (Fig. 157). Here there is, prior to fixation, a 'trophospongia' or area of proliferating connective

tissue and enlarged blood-vessels, and with this the placental trophoblast comes in contact as soon as, under its influence, the epithelium has been destroyed. Firmly fixed here, the trophoblast becomes hollowed out by lacunae, in which maternal blood circulates and is invaded from the other side by the foetal capillaries. The whole then grows into the lumen of the uterus until the complete thickness of the placenta is attained. An interesting feature is the conversion of much of the trophoblast into 'megalokaryocytes', large cells with enormous nuclei containing big nucleoli, similar to those seen in the omphaloidean trophoblast of the mouse.

Unfortunately, we have no such thorough knowledge of the genesis of the placenta of Man and Apes, but the structure of the fully formed organ is known, and such early stages as have been described are comparable, without difficulty, with stages in the development of such placentas as those of *Tarsius*, *Insectivores*, and so on.

When completed, the placenta is discoidal in shape. Amongst the Platyrrhine (New World) Monkeys it is double in *Cebus*, single (occasionally double) in *Myctes*. The two placentas are placed respectively on the dorsal and ventral walls of the uterus, and are connected, of course, by blood-vessels. Where only one is present it is ventral, but there is on the dorsal wall a placentaloid—a thickened region of widened blood-vessels—as though for the reception of a second placenta.

In the Catarrhines (Old World tailed Monkeys) there are usually two placentas, dorsal and ventral, as in *Semnopithecus* and *Cercocebus* (*Macacus*) (Fig. 136), but one (the ventral) may be absent. Either of the two may be the primary one. The umbilical cord in *Cercocebus* passes to the ventral placenta, whence blood-vessels travel to the other.

In the Simiidae (*Hylobates*, the gibbon) and *Simia* (the orang) and in Man there is but a single discoidal placenta, placed in the two Apes on the anterior (ventral) wall of the uterus, in Man usually on the posterior wall, though the position is variable. Further, in these forms the blastocyst or chorionic sac is always embedded in maternal tissue which forms, between it and the lumen uteri, a layer known as the 'decidua reflexa', or, in more

modern parlance, the 'capsularis' (Fig. 158). What has been regarded as a precursor of this structure—a ridge running round the placenta—has been observed in *Mycetes* and *Cercocebus*.

Human anatomists distinguish from the 'decidua reflexa' or 'capsularis' that maternal tissue to which the placenta is attached as 'decidua serotina' or 'basalis', while the opposite

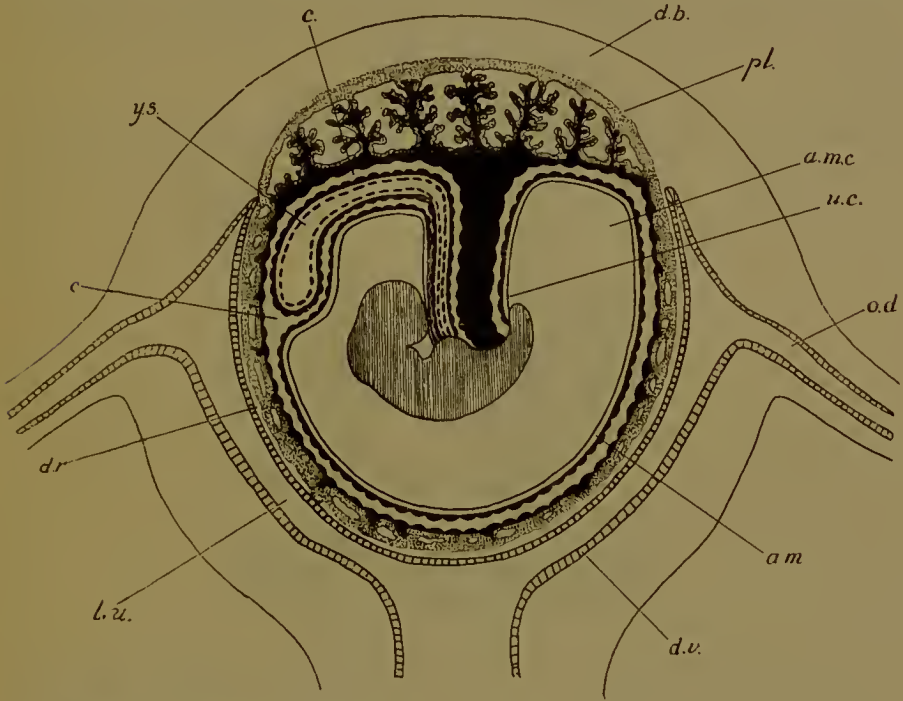


FIG. 158.—Human foetal membranes and placenta. (After Balfour, after Longct.) The amniotic cavity (*am.c.*) has enlarged and occupies nearly the whole of the extra-embryonic coelom (*c.*), the amnion being reflected over the umbilical cord (*u.c.*) and yolk-sac (*y.s.*). *d.b.*, decidua basalis (serotina); *d.r.*, decidua capsularis (reflexa); *d.v.*, decidua vera; *l.u.*, lumen uteri; *am.*, amnion; *pl.*, placenta; *o.d.*, oviduct.

wall of the uterus is known as the 'decidua vera'. The application of the term 'decidua' to maternal tissues has already been alluded to; it dates from the time when the type of placenta we are considering was supposed to include, and carry away at parturition, a considerable portion of the uterine wall.

Structurally all these placentas resemble one another very closely. The maternal blood circulates in large spaces known as sinuses, which are supplied by the blood-vessels of the uterine

wall (the decidua serotina or basalis in the Simiidae and in Man) (Fig. 158*). These sinuses are lined everywhere—not only over the foetal blood-vessels, but also on the maternal and on the foetal sides—by a syncytial layer, usually referred to as the syncytium, below which is a layer of cells—the cell-layer of Langhans of human embryology. These two layers separate the maternal blood in the sinuses from the foetal connective tissue and blood-capillaries (Figs. 159, 160). The more usual way,

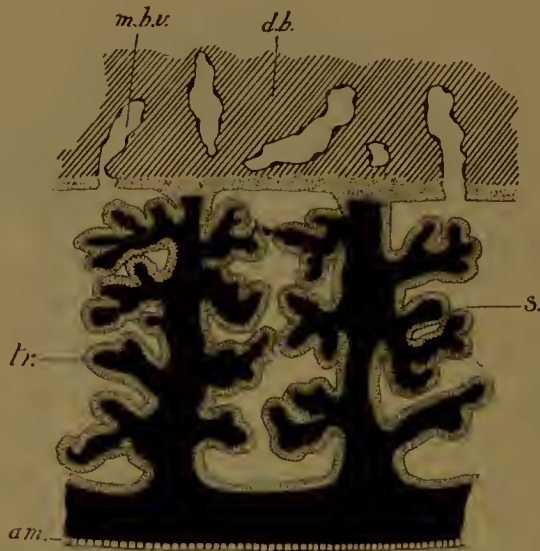


FIG. 158*.—Diagram of the structure of the human placenta. *m.b.v.*, maternal blood-vessels in the decidua basalis (*d.b.*) opening into the sinuses of the placenta (*s*) in which the villi branch. The villi are covered and the sinuses lined on all sides by trophoblast (*tr.*) (syncytial layer and cell layer of Langhans). *am.*, epithelium (ectoderm) of the amnion.

perhaps, of describing this arrangement is to say that the foetal villi—meaning by that the capillaries, and connective tissue and the cell-layer and syncytium covering them—branch about in sinuses filled with maternal blood. The expression 'villi' dates, however, from the older conception of the origin of these structures from villi similar to those seen in an Ungulate, a conception which is almost certainly erroneous. The foetal capillaries do branch very considerably it is true, but the syncytium and cell-layer are continued over the outer walls of the sinuses, next the tissues of the serotina. The sinuses, in fact, are lined everywhere by these two layers.

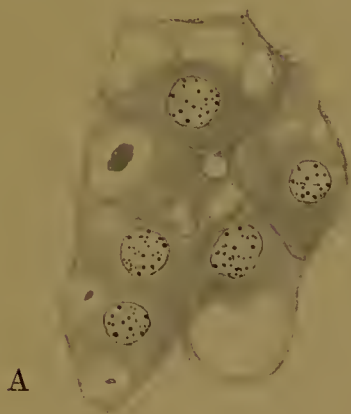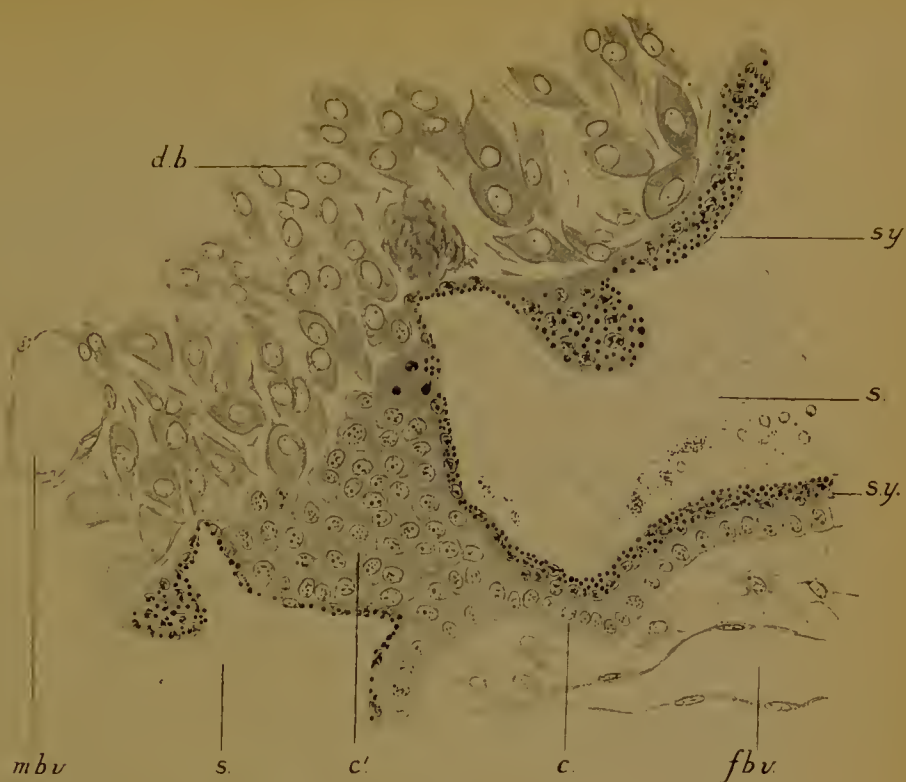
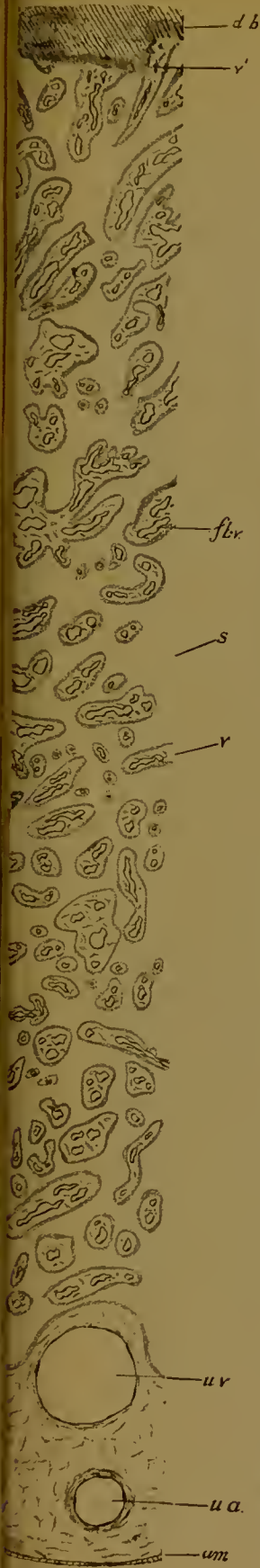


FIG. 160.—Structure of the insertion of a 'villus' into the 'decidua basalis' of the human placenta. *db.*, large cells ('decidual cells') of the basalis; *mb.v.*, maternal blood-vessels; *s.*, sinus of the placenta; *sy.*, syncytial layer, and *c.*, cell-layer covering villus; *c'*, mass of vacuolated cells continuous with the cell-layer and covering the extremity of the villus. The fat globules in the syncytium are rendered in black.

A, Large glycogen cells from the maternal side of the human placenta (5 months).

FIG. 159.—Middle strip of a section through the middle of the human placenta at 5 months. *db.*, decidua basalis; *v''*, villi inserted into basalis; *s.*, sinus; *v.*, villi in sinus; *fb.v.*, foetal vessel in villus; *u.v.*, umbilical vein; *u.a.*, umbilical artery; *am.*, epithelium of amnion.

The syncytium and cell-layer covering the villi and lining the sinuses are stippled. Notice that this cell-layer is found between the end of the villus and the maternal tissue of the basalis.



Further, the cell-layer at the outer extremities of the villi is continued into a mass of cells which separate the villus from the tissue of the decidua basalis. These cells are vacuolated, containing glycogen.

In *Mycetes* there is a syncytial network between the 'villi', cutting up the sinuses into smaller cavities (? lacunae): there is no cell-layer.

In the human placenta the syncytium contains fat; in late stages the cell-boundaries vanish in the layer of Langhans also.

On the maternal side of the placenta in the 'basalis' there are in man, *Simia*, *Hylobates*, and the Catarrhines, enlarged connective tissue-cells, known as 'decidual' cells (Fig. 160). These decidual cells get intermingled with the masses of cells which, continuous with the layer of Langhans, cover the outer extremities of the villi and contain glycogen, the two together being disposed in a sheet known as the chorio-basalis. In *Simia* and in man there are also septa, that is, peninsulae of basalis tissue projecting into the placenta proper.

In man the layer of the basalis next the placenta is known as the compacta. In this are the necks of glands. As gestation proceeds the epithelial lining of these glands degenerates, the inter-glandular tissue undergoes a fibrinous degeneration, and there are extravasations of blood in between these cells and into the glands. Similar extravasations occur in *Hylobates* and *Simia*. The whole layer becomes stretched and thinned. Beyond the compacta is the spongiosa, a layer of maternal tissue in which the gland-necks are much enlarged. There is slight degeneration here also. A spongiosa is found in *Simia*, but not in *Hylobates*.

In the lower Monkeys which possess no decidua capsularis the chorion is smooth except in the placental region or regions, but in *Hylobates*, *Simia*, and Man the chorion which is covered by the capsularis is in an early stage produced into 'villi' (which become poorly vascularized), as well as that opposite the basalis. Later the 'villi' disappear, and this part of the chorion is then, to use an old term, the 'chorion laeve', as distinct from the 'chorion frondosum' of the placenta.

The capsularis is covered by a cubical epithelium (Fig. 158).

In it, at the sides only, are a few glands with openings into the lumen uteri. There are blood-vessels and extravasations. The whole layer gets distended by the growth of the embryo and eventually its tissues wholly degenerate; the chorion is then immediately apposed to and united with the vera on the opposite side, and the uterine cavity is

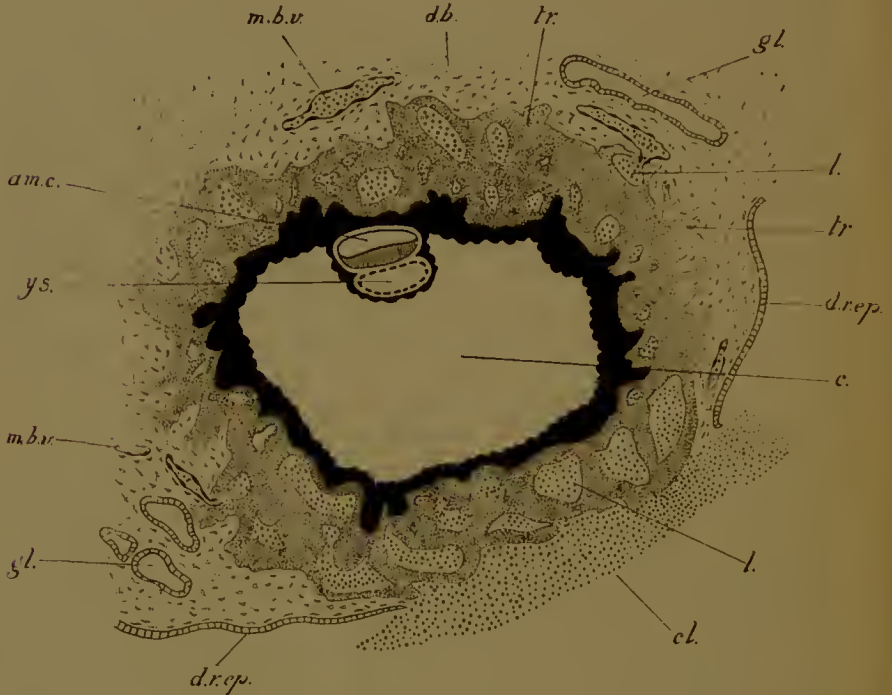


FIG. 161.—Early human embryo with its membranes. (After Peters.) *d.b.*, decidua basalis (serotina); *d.r.ep.*, uterine epithelium covering the decidua reflexa or capsularis; *l.*, lacuna in trophoblast (*tr.*); *gl.*, uterine gland; *m.b.v.*, maternal blood-vessels opening here and there into lacunae; *cl.*, clot marking (probably) the point of entrance of the blastocyst; here the epithelium is interrupted. Other letters as before.

obliterated. Only in the condition known as placenta reflexalis does the maternal circulation continue on this side.

In the decidua vera the epithelium ultimately disappears, the compacta is stretched and attenuated, and there are slight degenerative changes.

Such is the structure of the placenta in Man and Apes. We have still to discuss the mode of formation of the capsularis and the nature of the ' villi ' and ' sinuses '.

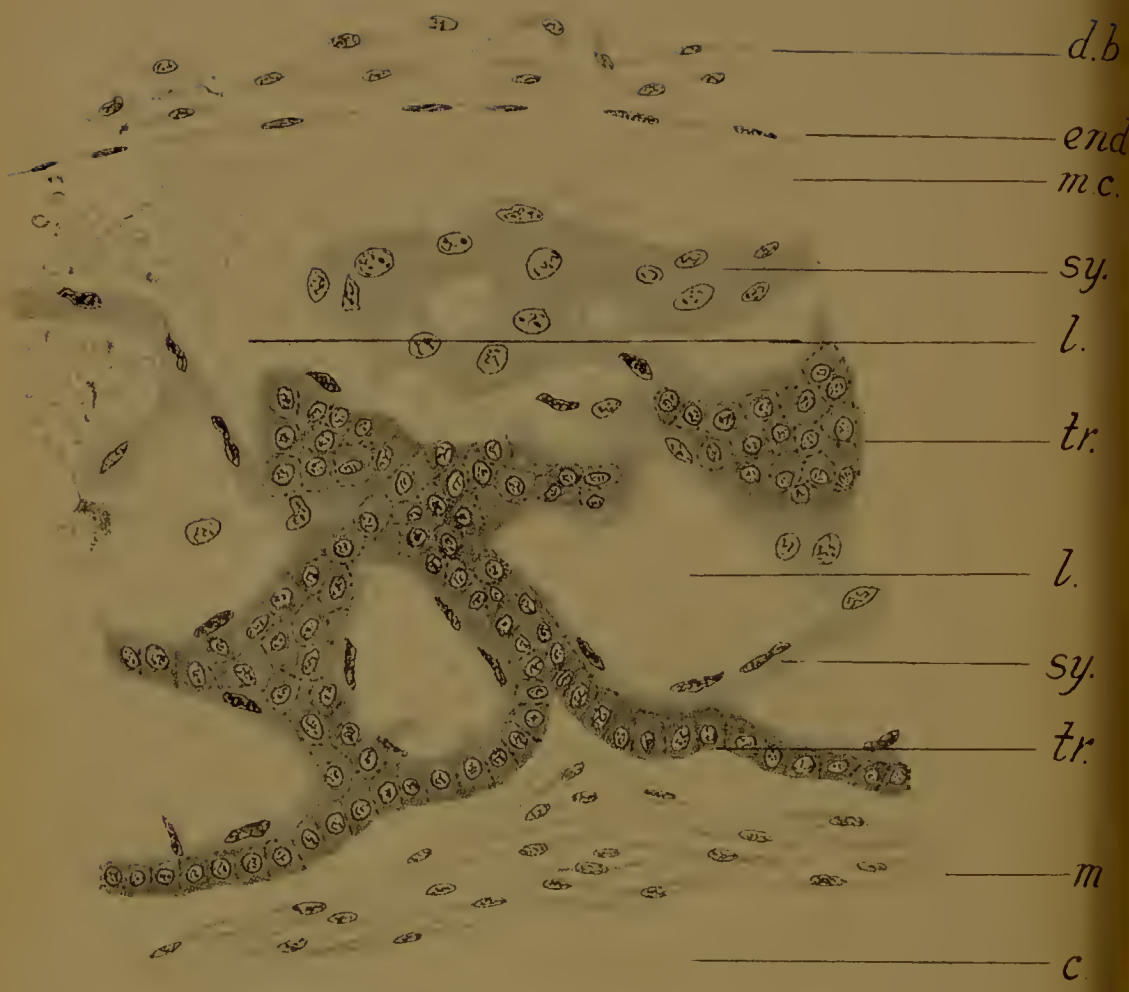


FIG. 162.—A small portion of the wall of the embryonic sac—on the side of the decidua basalis—of the human embryo shown in the last figure. (After Peters.) *d.b.*, maternal connective tissue of decidua basalis; *end.*, endothelium of maternal capillary (*m.c.*), opening into lacuna (*l.*); *sy.*, syncytium (plasmodi-trophoblast); *tr.*, cellular trophoblast (cyto-trophoblast): the syncytium is pale, the cyto-trophoblast more deeply staining; *m.*, somatopleure lining the extra-embryonic coelom (*c.*).

In the hedgehog and mouse we have seen the blastocyst embedded in a pit in the uterine wall, in which it becomes securely enclosed. The pit is lined by a continuation of the uterine epithelium, which, however, soon disappears. The relation of the blastocyst to the enveloping maternal tissues is then very similar to the relation between the human chorionic sac and its capsularis, and it has not unnaturally been suggested that the latter is really developed in the same way.

There is, however, known to us another way by which the mammalian blastocyst may come into contact with subepithelial tissue, for, as we have seen, the blastocyst of the guinea-pig bores its way through the epithelium. In the earliest human embryos known to us—those described by Peters and Bryce¹—there are very strong indications that the human capsularis is formed in this way, for in both cases there is in the centre of this layer an interruption in the continuity of the epithelium, marked, in Peters's case, by a blood-clot (Fig. 161). This would then be the spot where the ovum effected its entrance. If so then there can never have been any uterine epithelium on the other side of the blastocyst, the side of the basalis where the placenta is developed. This should be borne in mind in considering the next question, the origin of the 'villi' and 'sinuses'. In the embryos described by Peters and Bryce the somatopleuric wall of the extra-embryonic coelom is covered on the outside by a layer of cubical cells. Next to and perfectly continuous with this layer is a thick mass, composed of similar but polyhedral cells or in some places of a syncytium, with nuclei similar to those of the cellular tissue. In this mass are lacunae, and in these are maternal blood-corpuscles (Fig. 162). Outside all this is the subepithelial connective tissue of the uterus, with glands and blood-vessels: the latter open into the lacunae.

There can be no reasonable doubt that the whole of this lacunated mass, with a basal cellular layer next the somatopleure, is the trophoblast, which has become thickened and

¹ The embryo described by Bryce is perhaps slightly the younger of the two, as the extra-embryonic coelom appears to be not yet properly formed. That described by Peters was, however, obtained *in situ* in the uterus, and so gives us more information as to the relation between the foetal and maternal tissues.

hollowed out for the reception of extravasated maternal blood. We have seen this occurring in a part only of the trophoblast—as in the mouse—or in the whole of it—as in the hedgehog, and there is no reason why any other interpretation should be put upon this stage in human ontogeny. The steps in its formation have, however, not yet been observed. The comparative anatomy of the placenta has taught us that in cases of this kind the necessary relation between foetal and maternal blood-streams is brought about by the penetration of the allantoic capillaries into the trophoblast. Exactly the same process occurs presumably in the human being: the embryonic blood-vessels, with their surrounding connective tissue, make their way into the trophoblast between the lacunae. There they branch repeatedly and become the 'villi' of the completed placenta, while the sinuses are the transformed lacunae. The syncytial and cellular layers lining the sinuses and covering the villi are then both trophoblastic in origin, and similar to the plasmodi-trophoblast and cyto-trophoblast seen in other placentas of this type, in the mouse for example: they may be derived respectively from the outer and inner layers of trophoblast in the early stage. It is now possible to understand why the sinuses are lined throughout, on the maternal side against the basalis, as well as over the 'villi' and on the foetal side, by the syncytium and cell-layer, and why the outer extremities of the villi are separated from the decidual cells of the basalis by the cell-masses continuous with the layer of Langhans.

If this interpretation is correct then such hypotheses as that the sinuses are enlarged veins and the syncytium the endothelium of those veins, or that the syncytium is derived from uterine epithelium, must evidently be discarded; the second of these views is indeed already ruled out of court if the implantation of the blastocyst is really effected in the way we have suggested, for there could be in that case no uterine epithelium on the side of the decidua basalis.

Such views as these date from the period when it was believed that the human, like other 'deciduate' placentas, was derived from the condition found in Ungulates by a simple adherence of the villi to the crypt-walls; and this belief was supported by

the existence of 'chorionic villi', that is, branching processes of the trophoblast, all over the outer surface of the early blastocyst, before the foetal vessels had appeared. But these 'chorionic villi' were observed only in blastocysts removed violently, perhaps after post-mortem changes, from the sac of the capsularis, and a proper histological examination of foetal and maternal tissues together has revealed their true nature; they are not 'villi' or processes plunging into maternal tissues, but the irregular walls between the lacunae excavated in a thickened trophoblast.

The placenta of Man and Monkeys is, then, of the same kind as that seen in *Tarsius*, and in Rodents, Insectivora, and Cheiroptera. It contains no maternal tissue except the blood circulating in the sinuses or enlarged trophoblastic lacunae, and, in addition to the blood, no maternal tissue is lost at birth beyond the thin layer of the degenerate compacta—in both the deciduae basalis and vera—across which the break occurs, and such septa as may have forced their way into the placenta.

We may now briefly review the genesis of the Mammalian placenta in its varied types.

In Marsupials the placenta is wholly dissimilar from anything met with elsewhere, since the trophoblast degenerates while the syncytium is of uterine epithelial origin.

The Ungulates possess a typical Indeciduate placenta, with villi dipping loosely into crypts lined by a persistent epithelium, from which they may be readily withdrawn without injury to the maternal tissues. Haemorrhage from the uterine blood-vessels does, however, occur during gestation, and is of physiological importance in foetal nutrition.

The placenta is similar in Cetacea, Sirenia, and in the Lemuroidea (except *Tarsius*).

In the Proboscidea these haemorrhages are perhaps more extensive.

In the Carnivora the conditions are different, for here the trophoblast does not send villi into specially prepared crypts, but, after the destruction of the uterine epithelium, eats its way into the tissues, engulfing the maternal capillaries. These and the surrounding connective tissue grow *pari passu* with the

trophoblast to produce the full thickness of the placenta. The foetal capillaries grow into the trophoblast. The placenta is therefore compounded of foetal and maternal tissues.

In the remaining orders this is no longer the case, for, after the destruction of the epithelium, the trophoblast merely fastens on to the underlying tissues; only occasionally are the immediately adjacent capillaries engulfed (in the rabbit and in the bat), and even here their endothelium soon vanishes. Once fixed to the uterine wall the trophoblast grows not into the wall but from it towards the centre of the uterus, receiving into its lacunae the stream of maternal blood; from the other side it is vascularized by the allantois.

But distinct though these three types of placentation are, it is yet possible that the third might have been derived from the second—if we imagine the centripetal growth of the trophoblast to occur before the ingrowth into the maternal tissues has taken place—and the slight enclosure of maternal capillaries in the bat and rabbit almost demonstrates the change, while the insertion of the trophoblast into the newly formed crypts in *Sorex* recalls another Carnivorous character. The second, in turn, may have sprung from the first by the suppression of the uterine epithelium.

These, however, are mere speculations, for which alternative hypotheses may without difficulty be substituted.

One other point requires brief consideration. It has been held that the characters of the placenta are a valuable criterion of genetic relationship, and may accordingly be used for classificatory purposes. Now while it must be pointed out that single characters in regard either to the gross or the minute anatomy cannot be employed legitimately in this way—there is no justification, for example, in grouping together the elephant, *Hyrax*, the Sirenia, *Orycteropus*, and the Carnivora, because they all possess a zonary placenta, nor on the other hand do we believe it is yet proposed to separate the Lemuroid Primates, with their typically Indeciduate, from the Anthropoids, with their Deciduate placenta—yet a combination of characters is often found to be a constant mark of a natural order—for instance, the large yolk-sac with its lower wall lost and the mesometric discoidal placenta of Rodents, the zonary shape of the (histologically)

peculiar placenta of Carnivora—and it is for this reason that we hold that the remarkable structure of its foetal membranes and its placenta entitle *Tarsius* to be separated from the Lemurs and ranked with Monkeys and Man.

LITERATURE

E. VAN BENEDEN. Recherches sur les premiers stades du développement du Murin (*Vespertilio murinus*). *Anat. Anz.* xvi, 1899.

E. VAN BENEDEN et C. JULIN. Recherches sur la formation des annexes fœtales chez les Mammifères. *Arch. de Biol.* v, 1884.

R. BONNET. Die Uterinmilch und ihre Bedeutung für die Frucht. *Festschr. f. Bischoff*, 1882.

R. BONNET. Beiträge zur Embryologie der Wiederkäuer gewonnen am Schafei. *Arch. Anat. u. Phys. (Anat.)*, 1884, 1889.

R. BONNET. Beiträge zur Embryologie des Hundes. *Anat. Hefte*, 1^{te} Abt. xvi, 1901.

T. A. BRYCE and J. W. TEACHER. The early embedding and development of the human ovum. Glasgow, 1908.

W. CHIPMAN. Observations on the placenta of the rabbit, with especial reference to the presence of glycogen, fat, and iron. *Laboratory Reports, Roy. Coll. Phys. Edinburgh*, viii, 1903.

M. DUVAL. Le placenta des Carnassiers. *Journ. de l'Anat. et de la Phys.* xxix-xxxii, 1893-5.

M. DUVAL. Le placenta des Rongeurs. *Journ. de l'Anat. et de la Phys.* xxv-xxviii, 1889-92.

R. GÖHRE. Dottersack und Placenta des Kalong (*Pteropus edulis*). *Selenka's Studien zur Entwicklungsgeschichte der Tiere*, v, 2. Wiesbaden, 1892.

W. HEAPE. The development of the mole. *Quart. Journ. Micr. Sci.* xxiii, 1883.

J. P. HILL. The placentation of *Perameles*. *Quart. Journ. Micr. Sci.* xl, 1897.

J. P. HILL. On the foetal membranes, placentation and parturition of the native cat (*Dasyurus viverrinus*). *Anat. Anz.* xviii, 1900.

A. A. W. HUBRECHT. The placentation of *Erinaceus europæus*. *Quart. Journ. Micr. Sci.* xxx, 1889.

A. A. W. HUBRECHT. The placentation of the shrew (*Sorex vulgaris*). *Quart. Journ. Micr. Sci.* xxxv, 1893-4.

A. A. W. HUBRECHT. Die Phylogenese des Amnions und die Bedeutung des Trophoblastes. *Verhand. Kon. Akad. Wetensch. Amsterdam*, viii, 1902.

A. A. W. HUBRECHT. Die Keimblase von *Tarsius*. *Festsch. f. Gegenbaur*. Leipzig, 1896.

A. A. W. HUBRECHT. Ueber die Entwicklung der Placenta von *Tarsius* und *Tupaia*. *Proc. Internat. Congr. Zool.* Cambridge, 1899.

J. W. JENKINSON. Observations on the histology and physiology of the placenta of the mouse. *Tijd. Nederl. Dierk. Ver.* (2) vii, 1902.

- J. W. JENKINSON. Notes on the histology and physiology of the placenta in Ungulata. *Proc. Zool. Soc.*, 1906.
- F. KEIBEL. Zur vergleichenden Keimesgeschichte der Primaten. *Selenka's Studien über Entwicklungsgeschichte der Tiere*, 10. Wiesbaden, 1903.
- J. KOLLMANN. Ueber die Entwicklung der Placenta bei dem Makaken. *Anat. Anz.* xvii, 1900.
- R. KOLSTER. Die Embryotrophe placentarer Säuger. *Anat. Hefte*, 1^{te} Abt. xviii, xix, 1902, 1903.
- R. KOLSTER. Weitere Beiträge zur Kenntniss der Embryotrophe bei Indeciduaten. *Anat. Hefte*, 1^{te} Abt. xx, 1903.
- J. LOCHHEAD and W. CRAMER. The glycogenic changes in the placenta and the foetus of the pregnant rabbit. *Proc. Roy. Soc. B.* lxxx, 1908.
- F. H. A. MARSHALL and W. A. JOLLY. Contributions to the physiology of Mammalian reproduction. *Phil. Trans.*, Series B, cxviii, 1905.
- F. H. A. MARSHALL. The physiology of reproduction. London, 1910.
- F. H. A. MARSHALL. The oestrous cycle and the formation of the corpus luteum in the sheep. *Phil. Trans.*, Series B, cxvi, 1903.
- P. NOLF. Étude des modifications de la muqueuse utérine pendant la gestation chez le Murin. *Arch. de Biol.* xiv, 1896.
- H. PETERS. Die Einbettung des menschlichen Eies. Leipzig, 1899.
- E. SELENKA. Keimblätter und Primitivorgane der Maus. Wiesbaden, 1883.
- E. SELENKA. Die Blätterumkehrung im Ei der Nagethiere. Wiesbaden, 1884.
- E. SELENKA. Die Entwicklung des Gibbon. Wiesbaden, 1899, 1900.
- R. SEMON. Die Embryonalhüllen der Monotremen und Marsupialier. *Zool. Forschungsreise in Australien*, ii.
- F. GRAF VON SPEE. Neue Beobachtungen über sehr frühe Entwicklungsstufen des menschlichen Eies. *Arch. Anat. u. Phys. (Anat.)*, 1896.
- F. GRAF VON SPEE. Die Implantation des Meerschweincheneies in die Uteruswand. *Zeitschr. Morph. u. Anthropol.* iii, 1901.
- H. STRAHL. Ueber Primaten-Placenten. *Selenka's Studien über Entwicklungsgeschichte der Tiere*, 12. Wiesbaden, 1903.
- H. STRAHL u. H. HAPPE. Ueber die Placenta der Schwanzaffen. *Selenka's Studien über die Entwicklungsgeschichte der Tiere*, 13. Wiesbaden, 1905.
- SIR W. TURNER. Lectures on the comparative anatomy of the placenta. Edinburgh, 1876.
- SIR W. TURNER. On the foetal membranes of the eland (*Oreos canna*). *Journ. Anat. and Phys.* xiv, 1879.
- SIR W. TURNER. On the placentation of *Halicore dugong*. *Trans. Roy. Soc. Edinburgh*, xxxv, 1890.
- J. H. VERNHOUT. Ueber die Placenta des Maulwurfs. *Anat. Hefte*, 1^{te} Abt. v, 1894.
- C. WEBSTER. Human Placentation. Chicago, 1901.
- W. F. R. WELDON. Note on the placentation of *Tetraceros quadricornis*. *Proc. Zool. Soc. London*, 1884.

INDEX OF SUBJECTS AND AUTHORS

- Absorption by cells, 12, 217, 246.
 — of water, 15.
Acanthias, 27.
Acanthocystis, 57.
Acipenser, 36, 41, 52, 102, 127.
 Acrosome, 48, 54, 56, 81.
Aepyprymnus, 194.
 Afferent branchial arteries, 168.
 Agar, 69.
 Aggregation of cells, 11.
 Air-chamber, 48, 190.
 Albumen, 46, 47.
 — sac, 187, 190.
 Albumin, 226.
 Alimentary canal, 107, 110 sqq., 128,
 139, 143, 150, 169, 179.
 Allantoidean, 236, 244.
 Allantoin, 226.
 Allantois, 108, 181, 183, 188 sqq., 192,
 203 sqq., 246.
Amblystoma, 15.
Amia, 35, 38, 40, 102, 103, 127.
 Amitosis, 104.
 Amnion, 171, 175, 181, 183, 187 sqq.,
 194 sqq.
 Amnion, false, 108, 183, 187 sqq.
 Amniota, 106, 107, 111, 134 sqq., 147,
 171 sqq.
 Amniotic thickenings, 226; bodies,
 227.
 Amphibia, 15, 16, 27, 36, 39, 40, 43,
 46, 47, 49, 77, 78, 86, 95, 102, 129,
 190.
 Anamnia, 107, 111, 133, 147.
 Anastomoses, 12, 174.
 Animal pole, 40, 95.
 Annelids, germ-cells, 35; polar rings,
 35.
 Annular zone of trophoblast, 216, 246.
 Anterior abdominal vein, 190.
 Anterior intestinal portal, 180.
 Anthropoidea, 209, 255.
 Anti-mesometric pit, 234, 239.
 — placenta, 241, 243, 246.
 Anura, 129.
 Anus, 153, 154.
 Aorta, 168, 179, 180, 183.
 Aortic arches, 180, 181, 182.
 Archenteron, 111 sqq.
 Area, increase of, 12.
 Area opaca, 172; pellucida, 172, 174;
 vasculosa, 170, 172, 177, 183 sqq.,
 203, 241, 246.
 Arterial arches, 168, 169, 180, 182.
 Arteries, branchial, 155, 169, 182;
 umbilical, 188; vitelline, 171, 180.
 Artificial parthenogenesis, 87.
Arvicola, 195.
Ascaris, 34.
 Ascidians, 35.
 Assheton, 107, 143, 201.
 Auditory vesicle, 161, 170, 176, 180.
 Auricle, 180.
 Axial filament, 48, 54, 56, 57.
 Axis of ovum, 40, 95, 111.
 Axolotl, 41, 51, 52, 64, 77, 78, 81 sqq.,
 130.
 Balbiani, 72.
 Balfour, 213.
 Balfour's rule, 99.
 Ballowitz, 50, 51.
 Basal cells, in testis, 58, 59.
 Bat, 74, 145, 195, 208, 241, 242.
Bdellostoma, 120.
 Van Beneden, 145, 202, 204, 240.
 Bilateral egg structure, 89, 90, 100.
 — segmentation, 97.
 — closure of blastopore, 111, 113, 147.
 Bile-pigments, 48, 225, 246.
 Bilirubin, 225.
 Biliverdin, 232.
 Binucleate cells, 224.
 Birds, 29, 36, 37, 40, 43, 46, 47, 49, 77,
 78, 86, 90, 103, 105, 139, 190.
 Bladder, 169, 182, 190, 192.
 Blastocoel, 97, 98, 132, 171.
 Blastocyst, 107-9, 195, 253.
 Blastoderm, 104, 107, 120, 129, 131,
 133 sqq., 143, 147 sqq., 171, 187.
 Blastomere, 96.
 Blastopore, 111 sqq., 147 sqq., 172.
 Blastula, 98.
 Blood, 168, 174.
 Blood-clot, 253.
 Blood-islands, 173, 174, 177.
 Blood-vessels, 168, 179.
Bombinator, 50, 51.
 Bone, 11.
 Bonnet, 144, 205, 206.
Bos, 52, 220 sqq.
 Brain, 153, 158, 175.
 Branchial arches, 155, 169, 182.
 Branchial arteries, 168, 169, 182.
 Branchial clefts, 169, 182.
 Brauer, 131 sqq.

- Broman, 51.
 Bryce, 253.
 Budding, 9, 35.
Bufo, 15, 51, 52, 129.
 Butyric acid, 87.

 Calcium oxalate, 226.
Canis, 36, 144, 205, 229 sqq.
 Capillary, 174, 179; of placenta, 216, 217, 220, 224, 229, 230, 236, 237, 238, 240, 244, 250.
 Capsule of kidney tubule, 177.
 Cardinal veins, 167, 168, 179.
 Carnivora, 204, 229 sqq., 255, 256.
 Carotid gland, 169.
 Caruncle, cotyledonary, 220, 221.
 Cat, 31, 229 sqq.
 Catarrhines, 248.
 Caudal swelling, 122.
Cavia, 17, 18, 20, 31, 36, 49, 50, 52, 55, 74, 108, 195-7, 203, 204, 239, 253.
 Cavity, of segmentation, 97, 98, 132, 171.
 — subgerminal, 135, 149, 171; peritoneal, 167; pleural, 177; pleuro-peritoneal, 168, 177; of amnion, 188; of trophoblast, 200.
Cebus, 248.
 Cell-division, 10, 14, 88, 100.
 Cell-layer of Langhans, 250, 251, 254.
Centetes, 243.
 Centrosome, 48, 54-7, 65, 78, 83-5.
 Centrosphere, 54-7, 74, 78.
 Cephalopoda, 34.
Ceratodus, 41, 102, 128, 150.
Cercocebus, 210, 248, 249.
 Cerebellum, 158.
 Cervical flexure, 158, 181.
Cervus, 220.
 Cetacea, 208, 226, 255.
 Chalaza, 46.
 Change of growth-rate, 17, 22.
 Cheiroptera, 203, 207, 218, 241 sqq.
 Chemistry of yolk, 37; of egg-membranes, 46, 47; of spermatozoon, 52.
 Chick, 15, 139-143, 171 sqq.
 Cholesterin, 38, 47, 52.
Choloepus, 207, 227.
 Chorda-canal, 134, 145.
 Chordal sheath, 169.
 Chorion-basalis, 252.
 Chorion, of ovum, 45; (false amnion) 187, 192; laeve, 251; frondosum, 251.
 Chorionic villi, 218, 255; vesicles, 227.
 Choroid, 161.
 Choroid fissure, 159, 161.
 Chromatin, 23, 66 sqq., 78 sqq., 85, 87, 92, 93.
 Chromatoid accessory body, 55.
 — body, 74.
 Chromosomes, number of, 23, 66 sqq., 78 sqq.; division of, 79; accessory, 81; in fertilization, 85; in inheritance, 80, 87, 92, 93.
Chrysemys, 28.
 Cilia, 155, 221.
 Ciliary processes, 160.
 Cleavage, 95 sqq.
 Closure of blastopore, 111 sqq.
 Clot, 253.
 Clupein, 52.
 Coelom, 164, 165, 177.
 Colour of yolk, 37, 38; of egg-shell, 48.
 Concrecence of layers, 13.
 Connective tissue, 166, 169.
 Contraction figure, 65, 72.
 Contra-decudate, 217, 246.
 Convergence of chromatic filaments, 66, 72.
 Compacta, 251, 252, 255.
 Composition, 11.
 Cord, spinal, 156, 175.
 Cords, medullary, 31; sex, 31, 34.
 Cornea, 161.
 Corpus luteum, 44.
 Corpuseles, blood, 168.
 — — extravasation of, 220, 224, 225, 227, 232, 236, 240, 246, 251.
 Cortex of ovary, 31.
 Cotyledon, 219.
 Cotyledonary, 219.
 Cow, 220 sqq.
 Cranial flexure, 158, 181.
 Crest, neural, 154, 156.
Crocodilus, 52.
 Cross-furrow, 96.
 Crura cerebri, 158.
 Crustacea, 57.
 Crypts, 219, 221 sqq., 226, 227, 229, 246.
 Cumulus proligerus, 43.
 Cuticle of egg-shell, 47.
 Cutis, 166.
 Cyclops, 34.
 Cyclostomata, 118, 162.
Cymatogaster, 27.
 Cysts, of testis, 57, 59.
 Cytoplasm, increase of, 21; significance of in development, 43, 73, 74, 92, 93, 102, 150.
 Cyto-trophoblast, 236, 240, 254.

Dasyppus, 227.
Dasyurus, 36, 40, 48, 107, 194, 216, 217.
 Davenport, 14, 15, 16.
 Dean, 120, 127.

- Decidua, 218.
 — basalis, 249 sqq.
 — capsularis, 243, 249 sqq.
 — reflexa, 243, 244, 245, 248 sqq.
 — serotina, 249 sqq.
 — vera, 249 sqq.
 Decidual cells, 251.
 Deciduate, 215, 217, 229, 256.
 Deciduofraets, 244.
 Deciduous, 218, 254.
 Degeneration of uterine epithelium, 220, 229, 230, 234, 239, 241, 244, 245, 248, 252.
 Determination of sex, 81.
 Development, defined, 9.
 Dextrose, 47, 226.
 Diaphragm, 177.
 Dietyate, 32, 33, 73.
Didelphys, 36, 194, 216.
 Differentiation, 10, 14, 151.
 — histological, 11.
 — and senescence, 21; and segmentation, 102.
 Diffuse, 219.
Dimorpha, 57.
 Diplotene, 32, 59, 66, 72.
 Dipnoi, 128.
Discoglossus, 49, 52.
 Discoidal segmentation, 104.
 — placenta, 232, 239, 241, 242, 243.
Diseus proligerus, 43.
 Dispersion of elements, 13.
 Ditrematous Mammalia, 191 sqq.
 Diverticula allantoidis, 206, 220.
 Division of cell-masses, 13; of cells, 14, 95 sqq.; of chromosomes, 78, 79.
 Dog, 36, 144, 205, 229 sqq.
 Dorsal division of blastopore, 153.
 — lip of blastopore, 111 sqq.
 — placenta, 248.
 — roots, 156, 163, 164.
 Duet, pronephrie, 167.
 Duetus Cuvieri, 168, 181.
 Duetus endolymphaticus, 162.
 Duval, 190, 205, 231, 240.

 Ear, 161, 162.
 von Ebner, granules of, 57, 59.
Echidna, 36.
 Ectoderm, 108, 110 sqq., 156.
 Edentata, 207, 227.
 Edge of blastoderm, 122-7, 131.
 Efferent branchial arteries, 168.
 Elasmobranchs, 27, 36, 37, 40, 43, 46, 47, 49, 71, 78, 86, 90, 103, 105, 120 sqq., 130, 150, 162, 165, 170.
 Elementary organs, 10.
Elephas, 208, 227, 256.
 Embryonic area, 143.
 Embryonic knob, 108, 143, 195 sqq.
 — plate, 198 sqq.
 — shield, 105, 107, 135, 143, 144, 148.
 End-knob, 48.
 Endoderm, 105, 107, 110 sqq., 150.
 Endothelium, 168, 174, 179, 240, 241, 256.
 Entrance-eone, 81.
 Entrance-funnel, 81.
 Epidermis, 156.
 Epithelium, germinal, 26; of lens, 160; of uterus, 219 sqq., 220, 226, 229, 230, 234, 239, 241, 244, 245, 248, 252.
 Equator, of ovum, 40, 95.
Erinaceus, 36, 52, 195, 198, 207, 243-5, 253.
Esox, 52.
 Eustachian passage, 169, 182.
 Eutheria, 216.
 Evagination, 12.
 Extra-embryonic coelom, 179, 187, 196, 209, 246.
 Extravasation, 220, 224, 225, 227, 232, 236, 240, 246, 251.
 Eye, 159 sqq.
 Eyeball, 161.

 Factors, external, 16.
 Fallopian tube, 221, 226.
 False amnion, 108, 183, 187 sqq., 192.
 Farmer, 69.
 Fat, 37, 38, 44, 47, 52, 204, 220, 224, 232, 234, 238, 251.
 Feather-star, 92.
 Fehling, 16.
 Ferment, glycogen splitting, 241.
 Fertilization, 81, sqq., 221.
 Fibres, of lens, 161; of nervo roots, 156, 157; of optic nerve, 161.
 Fibrin, 232, 251.
 Filament, axial, 48, 54-7.
 Fin, 155.
 Flagellate spermatozoon, 48.
 Flattening of egg, 35, 95.
 Flexure, cranial, 158, 181; cervical, 181.
 Foetal membranes, 183 sqq.; of mammals, 192 sqq.
 Folds, medullary, 154, 156.
 Folliele, 28, 32, 43-5, 221; cells of ovary, 25, 32; of testis, 57
 Food, 15.
 Fore-brain, 153, 158, 175, 180.
 Fore-gut, 180.
Fringilla, 50.
 Frog, 15, 27, 35, 36, 37, 86, 89, 95 sqq., 111 sqq., 147, 149, 150, 153 sqq.
 Funnel, pronephrie, 167.
 Fusion of cell aggregates, 12.

- Galago*, 227.
 Ganglia, 154, 156.
 Ganoids, 36, 46, 127.
 Gastrulation, 111
 Genital ridge, 26.
 Germ-cells, vehicles of inheritance,
 9, 23 sqq.
 Germ-layers, 10, 110 sqq., 196; in-
 version of, 197.
 Germ-number of chromosomes, 66, 67.
 Germinal epithelium, 26, 29.
 — vesicle, 41.
 — wall, 171.
 Gibbon, 248, 251.
 Gill-plate, 154.
 Gill-slits, 169, 180, 181, 182.
 Gills, 155, 168.
Giraffa, 220.
 Glands of uterus, 204, 221, 229, 230,
 232, 246, 252, 253.
 Globules of yolk, 36.
 Glomus, 167.
 Glycogen, 220, 225, 226, 236, 237, 239,
 241, 251.
 Graafian follicle, 43, 221.
 Granules of von Ebner, 57, 59.
 — of yolk, 36, 73.
 Gray crescent, 89, 98, 100.
 Green border, 232.
 Growth, 10, 15 sqq., 23, 73.
 Guinea-pig, 17, 18, 20, 31, 36, 49, 50,
 52, 55, 74, 108, 195-7, 203, 204,
 239, 253.
 Gymnophiona, 36, 40, 102, 111, 131
 sqq., 136, 147, 148.
 Haematochlorine, 232.
 Haematogen, 38.
 Haematoporphyrin, 225.
 Haemoglobin, 220, 225, 227, 232,
 246.
 Haemorrhage, 220, 224, 227, 232, 236,
 240, 246, 251.
Halicore, 208, 226.
Halmaturus, 194.
 Head, length, 20.
 Head-fold of amnion, 175, 181.
 Head-process of primitive streak, 172.
 Head somites, 161, 162-4.
 Heart, 167, 168, 170, 179.
 Heat, 229.
 Hedge-hog, 36, 52, 195, 198, 207, 243-5,
 253.
 Hemispheres, 158, 181.
 Herlant, 86.
 Herring, 52.
 Hertwig's rules, 99, 100.
 Heterochromosomes, 81.
 Heterogeneous hybridization, 92.
 Heterotypic, 59, 67, 74, 75, 77.
 Hill, 107, 143, 193, 217.
 Hind-brain, 153, 158, 175, 180.
 Hind-gut, 180.
 Hippomanes, 206, 225, 227.
 Holoblastic, 94.
Homo, 19-21, 36, 52, 197, 209, 212,
 218, 248 sqq.
 Homocotypic, 71, 78.
 Homology, 151.
 Horse, 205, 219.
 Hubrecht, 198, 201, 207, 209, 210,
 234, 243, 245, 247.
 Human embryo, 15, 18, 19, 211-14,
 218, 248 sqq.
 Hybridization, 92.
 Hydroids, germ-cells, 34.
Hylobates, 248, 251.
 Hyoid arch, 155, 168, 169, 182.
 Hyomandibular cleft, 169, 182.
 Hyperaemia, 229.
 Hypertonic sea-water, 87.
 Hypertrophy, 220, 229.
Hypogeophis, 131.
 Hyraeidea, 227.
Hyrax, 227, 256.
 Ichthulin, 38.
Ichthyophis, 131.
 Idiozom, 54.
 Increments, percentage, 16.
 Indeciduate, 217, 218-28, 255.
 Individuality of chromatin and chro-
 mosomes, 75.
 Infundibulum, 159, 175.
 Inheritance, chromosomes in, 80, 87;
 cytoplasm in, 92, 93.
 — mechanism of, 9.
 Inner mass, 108, 143, 195.
 Insectivora, 203, 207, 218, 243 sqq.
 Intermediate cell-mass, 164, 165, 176;
 segmentation, 102; vitelline veins,
 186.
 Interruptions of continuity, 13.
 Invagination, 12.
 Investment by cells, 12.
 Iris, 160.
 Iron, 220, 224, 225, 246.
 Iso-bilateral segmentation, 97.
 Iter, 158.
 Jelly, 46.
 Julin, 204.
 Keratin, 46, 47.
 Kerr, 128.
 Kidney, 164, 165, 177.
 King, 51.
 Knob, embryonic, 108, 143, 195.
 — end, 48.
 von Korff, 50.

- Labyrinth, 161.
Lacerta, 47, 135.
 Lacunae, 232, 236, 240, 241, 244, 248, 253-5.
 Lamellae, 230.
 Lamprey, 27, 35, 36, 37, 46, 86, 102, 119, 129, 149, 150, 163, 170.
 Langhans, 250, 251, 254.
 Large-yolked, 39, 103.
 Latebra, 40.
 Lateral amnion folds, 176, 187.
 — lips of blastopore, 112 sqq.
 — plate, 162, 176.
 — vitelline veins, 186.
 Latitudinal, 96.
 Layers of yolk, 40.
 Leeithin, 38, 47, 52.
 Leg, length, 20.
 Lemuroidea, 208, 227, 255, 256.
 Length of head, 20; of leg, 20; of spermatozoon, 52; of vertebral column, 20.
 Lens, 159, 160, 161, 181.
Lepidosiren, 102, 128, 129, 147, 149, 150, 170.
Lepidosteus, 36, 40, 102, 103, 170.
 Leptotene, 59, 64, 72.
 Lepus, 29, 36, 196, 201, 203, 239-41.
 Leucocytes, 217, 220, 225, 229, 246.
 Lillie, 190.
 Liquor amnii, 188.
 Liquor folliculi, 43.
 Liver, 169, 182.
 Longet, 213, 249.
 Longitudinal division, 79.
 Loss of yolk, 203; of shell, 203.
 Lower layer, 104, 107, 122, 135, 143, 149, 150, 171, 195.
 Lumen uteri, reformed, 234, 238, 239.
 Lungs, 167, 169, 182.
 Lutein, 38, 44, 47.

Macacus, 248.
 Mackerel, 52.
 Magma, 73, 74.
 Mammalia, 29, 36, 46, 71, 77, 78, 143, 177, 190, 192 sqq.
 Mamillary sheet, 47.
 Man, 19-21, 36, 52, 197, 209, 212, 218, 248 sqq.
 Mandibular arch, 155, 168, 169, 182.
Manis, 227.
 Marsupialia, 46, 47, 48, 107-9, 143, 193, 216, 255.
 Maturation divisions, 23, 59, 62 sqq.
 Mechanical shock, 87.
 Mechanism of inheritance, 9.
 Medulla oblongata, 158.
 Medulla, of ovary, 31.
 Medullary folds, 153, 156, 174.
 Medullary groove, 156, 174.
 — plate, 153, 174.
 — tube, 154, 156, 174.
 Megalecithal, 39.
 Megalokaryocytes, 236, 248.
 Meiotic, 67.
 Membrana elastica interna, 169.
 Membrane, in fertilization, 89.
 Membranes of ovum, 45-8; of foetus, 183 sqq., 192 sqq.
 Meridional, 95.
 Meroblastic, 103.
 Merocyte, 86.
 Merogony, 87.
 Mesentery, 168.
 — germ-cells in, 27.
 Mesocardium, 168, 179.
 Mesoderm, 110 sqq., 162 sqq.
 Mesometric placenta, 232, 239, 242, 247.
 Mesonephros, 177.
 Metameric segmentation, 156, 162, 164.
 Metamorphosis of spermatid into spermatozoon, 52 sqq.
 Metanephros, 177.
 Metatheria, 216.
 Methods, in embryology, 9, 10.
 Meves, 50, 53, 55, 68.
 Microlecithal, 36, 95.
 Micropyle, 46.
 Mid-brain, 153, 158, 175.
 Middle-piece, of spermatozoon, 49.
 Migration, of cells, 11; of germ-cells, 27 sqq.
 Minot, 17-21, 213.
 Mitosis, 62.
 Mitsukuri, 138.
 Mole, 31, 36, 195, 207, 243, 245.
 Mollusc, 92.
 Monkeys, 197, 209, 212, 218, 248 sqq.
 Monotremata, 36, 43, 47, 48, 103, 106, 107, 143, 192.
 Montgomery, 69.
 Mouse, 31, 36, 52, 59, 86, 145, 195, 200, 203, 232 sqq., 253.
 Movements of cells and cell aggregates, 11-13.
 Mucin, 47, 226.
Mus, 31, 36, 52, 59, 86, 145, 195, 200, 203, 232 sqq., 253.
 Muscles of eye-ball, 161; of trunk and limbs, 166.
 Muscular wall of heart, 168, 179.
Mycetes, 248, 249, 251.
 Myocoel, 165, 166, 177.
 Myotom, 166, 177.
Myrmecophaga, 227.
Myxine, 71.
 Myxinoids, 35, 36, 40, 46, 103, 120, 130, 170.

- Navcl, 188.
 Neck, of spermatozoon, 49.
 Nephrocoel, 165, 177.
 Nephrotom, 165, 166, 176, 177.
 Nerves, cranial, 154, 156, 162, 163 ;
 spinal, 154, 156.
 Nervous layer, 160, 162.
 — system, 153, 156, 170, 175, 181.
 Neural crest, 154, 156, 162, 163, 181.
 Neurenteric passage, 134, 142, 145,
 153, 154, 170.
 Newt, 63, 86.
 Nolf, 208, 242.
 Nostril, 161.
 Notochord, 110 sqq., 169, 172, 174.
 Nuclear contributions to cytoplasmic
 structure, 73, 74.
 Nucleic acid, 52.
 Nuclein, 52.
 Nucleoli, 72, 73, 236, 248.
 Nucleo-plasma ratio, 22, 99.
 Nucleo-protein, 38, 73.
 Nucleus, decrease of, 21 ; in inheri-
 tance, 80, 87, 92, 93 ; of ovum, 41 ;
 of spermatozoon, 48.
 Nuclei in yolk, 103, 104.

 Obliques, 161, 162.
 Oestrus, 220, 221, 229.
 Oil, 37.
 Olfactory pit, 155, 161.
 — sac, 161, 170.
 Omphaloidean, 236, 238, 244.
 Oocyte, 25, 31.
 Oogonia, 24.
 Operculum, 155.
 Ophthalmicus, 163.
 Optic cup, 159, 181.
 — lobes, 158.
 — nerve, 161.
 — stalk, 159, 161.
 — vesicle, 159, 170, 180, 181.
 Orang, 248, 251.
Orca, 208, 227.
Oreas, 220.
 Organ-forming substances, 43, 102,
 150.
 Origin of germ-cells, 26 sqq.
Ornithorhynchus, 36, 48, 144.
Orycteropus, 227, 256.
 Ostracoda, 52.
 Outer layer, 108, 195.
 Ovary, formation of, 30, 31 ; of tad-
 pole, 72.
Ovis, 36, 196, 220 sqq.
 Ovo-albumin, 47.
 Ovo-mucoid, 47.
 Ovo-vitellin, 38.
 Ovulation, 43, 221.
 Ovum, 23, 35 sqq.

Pachytene, 32, 59, 66, 72.
 Pairing of chromatin filaments, 65, 80.
 Pancreas, 169, 182.
 Parablast, 105.
 Paraderm, 105.
 Parathyroid, 169.
 Parthenogenesis, 87.
 Partial segmentation, 103.
 Parturition, 238.
Perameles, 194, 217.
Perca, 51.
 Perforation of floor of archenteron,
 148.
 Perforatorium, 48, 54.
 Periblast, 91, 104.
 Pericardium, 168, 177, 179.
 Periods, in history of germ-cells, 23.
 Peritoneal cavity, 167, 177.
 Peritoneum, 168.
 Perivitelline fluid, 89.
 Peters, 211, 253.
Petromyzon, 27, 35, 36, 37, 46, 86, 102,
 119, 129, 149, 150, 163, 170.
 Pfüger, 31, 100.
 Phagocytosis, 12, 213, 221, 224, 229,
 230, 231, 236, 242, 244, 246.
Phalangista, 49, 50.
Phascolarctos, 48, 194.
 Phosphatides, 38.
 Pig, 195, 219.
 Pigment layer of retina, 159.
 — of cornea, 161 ; of ovum, 40 ; of
 uterus and placenta, 220, 225, 227,
 232, 246.
 Pituitary body, 169, 181.
 Pineal body, 159.
 Placenta, 192, 215 sqq.
 — reflexalis, 252.
 Placental mammals, 35, 36, 39, 41,
 46, 48, 108, 194 sqq., 217 sqq.
 Placentoid, 248.
 Plane, of symmetry, 100.
 — sagittal, 112.
 Plasmodi-trophoblast, 236, 240, 254.
 Platelets of yolk, 36.
Platydactylus, 135.
 Platyrrhine, 248.
 Pleural cavity, 177.
 Pleuro-peritoneal cavity, 168, 177.
 Polar bodies, 25, 77.
 — furrow, 96.
 — rings of Annelids, 35.
 Poles of egg-axis, 40.
 Polyspermy, 86.
Pontocypris, 52.
 Post-anal gut, 170.
 Posterior cardinal vein, 167.
 — intestinal portal, 180.
 — vitelline vein, 186.
 Potts, 15.

- Primates, 203, 218, 227, 246 sqq.
 Primitive groove, 139 sqq., 172, 174.
 — plate, 107, 135.
 — streak, 139 sqq., 172.
 Primordial germ-cells, 23 sqq., 26 sqq.
Pristiurus, 86.
 Pro-amnion, 172, 194.
 Proboscidea, 208, 227, 255.
 Proetodaeum, 153, 154, 156, 169.
 Pronephros, 166, 167, 177.
 Pronucleus, 83, 87.
 Pro-oestrus, 220, 221, 229.
 Prophases of first maturation division,
 23, 25, 64, 65, 71, 72.
 Prosencephalon, 158.
 Protamine, 52.
 Protein, 37, 38, 47, 204, 220, 224, 232,
 238.
 Protovertebrae, 162.
 Protozoa, 57.
Pteropus, 242.

 Qualitative division, 79.
 Quantitative division, 79.

 Rabbit, 29, 36, 196, 201, 203, 239–241.
 Radial type of cleavage, 96.
Raia, 52.
Rana, 15, 27, 35–7, 86, 89, 95, 97,
 111 sqq., 147, 149, 150, 153 sqq.
 Rate of division, 100.
 — of growth, 16 sqq.
 Ratio of nucleus to cytoplasm, 22, 99.
 Rauber's cells, 195 sqq., 234.
 Re-arrangement of material, 13.
 Reeti, 161, 162.
 Reduction of number of chromosomes,
 24, 66 sqq., 78 sqq.
 — of plasma-nucleus ratio, 22, 99.
 Regeneration, 9, 35.
 Reptiles, 28, 36, 40, 46, 47, 49, 78,
 86, 103, 105, 135 sqq., 190.
 Respiration, 188, 224.
 Retina, 158–160.
 Retro-peritoneal tissue, 28.
 Ridge, genital, 26.
 Ring-shaped centrosome, 54, 56.
 — chromosomes, 59, 66, 75.
 Rodents, 200, 203, 218, 232 sqq.
 Roots of nerves, 156, 157.
 Rotation of frog's egg, 113, 114; of
 sperm-head, 83.
 Rückert, 86.
 Rule of Balfour, 99.
 — of Hertwig, 99, 100.
 Ruminants, 220.

 Sagittal plane, 111.
 Salamander, 53.
 Salmin, 52.

 Salmon, 27, 52, 86.
 Salmonidae, 105.
 Salts, 38, 47, 226.
 Sarasin, 131.
 Schauinsland, 142.
 Schreiner, 69.
Sciurus, 203, 239.
 Sclerotic, 161.
 Sclerotom, 165, 177.
 Seombrin, 52.
 Scorpions, germ-cells, 34.
 Scott, 119.
 Secretion of cells, 221, 229, 230.
 Segmental duet, 177.
 Segmentation, 95 sqq.; significance
 of, 22, 99.
 — cavity, 97, 98, 132, 171.
 — of mesoderm, 162; of neural crest,
 156.
 Selenka, 197, 198, 211.
 Semiferous tubules, 34, 57.
Semnopithecus, 248.
 Semon, 128, 193.
 Senescence, 21.
 Sense organs, 156, 181.
 Sense-plate, 154.
 Septa of yolk-sac, 187; of placenta,
 251.
 Sero-amniotic connexion, 188.
 Serosa, 187.
Serranus, 125 sqq.
 Sertoli, cells of, 58–60.
 Sex, cords, 31, 34.
 — determination of, 81.
 Sheep, 36, 196, 220 sqq.
 Shell, 45, 47, 48, 172.
 — loss of, 203.
 Shell-membrane, 47, 48.
 Shield, embryonic, 105, 107, 135, 143,
 144.
 Side folds of amnion, 176, 187.
Simia, 248, 251.
 Simiidae, 248, 250.
 Sinus, 249 sqq.
 Sinus terminalis, 170, 186.
 Sinus venosus, 180.
Siredon, 41, 51, 52, 64, 77, 78, 81 sqq.,
 130.
 Sirenia, 208, 226, 255.
 Size of cells, 100; of ovum, 35, 36;
 of spermatozoon, 52.
 Skeleton, 165.
 Small-yolked, 36, 95.
 Soaps, 47.
 Sobotta, 127.
 Somatic number of chromosomes, 23,
 60, 66.
 Somatopleure, 166, 168, 177.
 Somites, 161, 162, sqq., 176.
Sorex, 196, 207, 243, 246.

- Sparrow, 142.
 Spec, Graf, 212.
 Sperm-aster, 83.
 Sperm-path, 83-5, 89, 100-2.
 Sperm-sphere, 83.
 Spermatid, 24, 52 sqq., 59.
 Spermatozoon, 23, 24, 48 sqq.
 Spermocytes, primary, 23, 59; secondary, 23, 24, 59, 67.
 Spermogonia, 23, 57, 59.
 Sphere of attraction, 54-7, 74, 78.
 Spinal cord, 156, 175.
 Spiracle, 157.
 Splanchnocoel, 165, 167, 177.
 Splanchnopleure, 168, 177.
 Splitting of cell aggregates, 12, 13.
 Spongiosa, 230, 251.
 Squirrel, 203, 239.
 Stature, growth of, 20.
 Stomata, 187.
 Stomodacum, 154, 156, 169.
 Strahl, 228.
 Stroma, 26, 30.
 Structure of germ-cells, 35 sqq.
 — increase of, 10.
 — of ovum, 14, 40, 41-43, 60, 95.
 Sturgeon, 36, 41, 52, 102, 127.
 Sturin, 52.
 Sub-germinal cavity, 135, 149, 171.
 Sub-intestinal vein, 170.
 Sucker, 154.
Sus, 195, 219.
 Symmetry of embryo, 90.
 — of ovum, 40, 41-3, 90, 95.
 — of segmentation, 99 sqq.
 Synaptene, 59, 65, 72.
 Syncytium, 171, 217, 230, 236, 250, 251, 254.

 Tail, of spermatozoon, 48, 54-7, 83;
 of tadpole, 155.
 Tail-fold of amnion, 176, 187, 210;
 gut, 170.
 Tail-sleeve, 56.
Talpa, 31, 36, 195, 207, 243, 245.
Tamandua, 227.
 Tangential division, 97, 103.
Tarsius, 195, 201, 209-11, 218, 246-8,
 255, 257.
 Teeth, 155.
 Telostei, 36, 37, 46, 49, 91, 103, 104,
 125 sqq., 130, 150, 170.
 Telolecithal, 38.
 Tendon, 11.
 Testis, origin of, 34; tubules of, 34,
 57.
Tetraceros, 220.
 Thalamencephalon, 158.
 Theca, 26, 28, 30, 44.
 Thickness, alterations of, 12.

 Thymus, 169, 182.
 Thyroid, 169, 181.
 Toad, 15, 51, 52, 129.
 Transverse division, 79.
Trionyx, 138.
Triton, 63, 86.
 Trophoblast, 107, 143, 144, 192 sqq.,
 215 sqq.
 Trophospongia, 234, 239, 243, 247.
Tropidonotus, 49, 50.
 Trout, 27.
 Truncus arteriosus, 180, 182.
 Tubes of Pflüger, 31.
 Tubules, of testis, 34, 57.
 — of kidney, 166, 177.
 Tunica albuginea, 34.
Tupaia, 195, 201, 207, 243, 246.
 Turner, 209.
 Tympanic cavity, 182.

 Umbilical arteries, 188, 212.
 — cord, 212, 214, 238, 247.
 — veins, 188, 190, 212.
 — vesicle, 108.
 Umbilicus, 187, 188, 196.
 Ungulates, 203, 204, 218 sqq., 255.
 Union of pronuclei, 85, 87.
 Upper layer, 104, 135, 143, 149, 171.
 Urodela, 50, 51, 60 sqq., 102, 129, 130,
 150.
 Uterine epithelium, 219, 220, 226, 229,
 230, 234, 239, 241, 244, 245, 248,
 252.
 — glands, 204, 220, 227, 229, 230, 232,
 252.
 — milk, 221, 227.

 Vegetative pole, 40, 95.
 Vein, anterior abdominal, 190.
 — cardinal, 167, 168, 179, 181.
 — subintestinal, 170.
 — umbilical, 188.
 — vitelline, 168, 175, 179, 180, 183-6.
 Ventral aorta, 182.
 — division of blastopore, 153, 154.
 — lip of blastopore, 113 sqq.
 — placenta, 248.
 — roots, 157, 163, 164.
 — stalk, 213, 246.
 Ventricles of brain, 158; of heart,
 180.
 Vertebral column, length, 20.
 — plate, 162, 176.
Vespertilio, 74, 145, 195, 208, 241, 242.
 Villi, 218, 219, 221 sqq., 226, 227, 229,
 250, 251, 252.
 Vitelline arteries, 171, 180, 186.
 — membrane, 45, 46.
 — veins, 168, 175, 179, 180, 186.
 Vitreous body, 159, 161.

- Water, absorption of, 15; in egg-white, 47; in yolk, 38.
 Weight, growth of, 20; of yolk, 40.
 White of egg, 46, 47.
 Will, 136, 137.
 Wilson, H. V., 105, 125 sqq.
 — J. T., 107, 143.
 von Winiwarter, 64, 69.
 Wolfian tubules, 177.
 Woods, 27.
 Worm, 92.
 Wrinkling of egg-surface, 95.
- Yolk, 35, 36 sqq., 73, 74, 99, 100.
 — loss of, 203.
 Yolk-blastopore, 124.
- Yolk-body, 40, 107; of Balbiani, 72, 74.
 Yolk-cells, 113 sqq., 128, 129, 150, 169.
 Yolk-nuclci, 103-105, 122.
 Yolk-nuclcus, 73, 93.
 Yolk-plug, 113, 114, 133, 135, 136, 142.
 Yolk-sac, 108, 169, 170, 177, 180, 183 sqq., 192, 203 sqq., 238, 241, 244, 246.
 Yolk-stalk, 27, 29, 170, 175, 180.
- Zona pellucida, 45, 107.
 Zona radiata, 46.
 Zonary placenta, 227, 229, 256.



OXFORD : HORACE HART, M.A.
PRINTER TO THE UNIVERSITY



