School of Medical Sciences - Anatomy

ANAT2241 Histology - Basic and Systematic

Covering and Lining Epithelia

m.hill@unsw.edu.au

Covering and Lining Epithelia

Lecture Objectives

1. Understand the function of epithelia
2. Understand the concept of covering and lining epithelia
3. Understand the classification of epithelia
4. Understand epithelial specialisations
5. Understand basement membrane and adhesion junctions

Resources

- Wheater's Functional Histology
  - II Basic Tissue Types - 5 Epithelial tissues pp82
- Practical Support Page
  - http://tiny.cc/ANAT2241_Epithelia

Epithelia Function

- Barrier, protection
- Secretion
- Absorption
- Transport
- Sensory
- Development
  - epithelium and mesenchyma

Resources

- Wheater's Functional Histology
  - II Basic Tissue Types - 5 Epithelial tissues pp82

Location of Epithelia

- **Covers** all free surfaces of the body
  - one side therefore free, and the other rests on basement membrane
- **Lines** the large internal body cavities
  - **Mesothelium**
- Internal surfaces of blood and lymph vessels
  - **Endothelium**

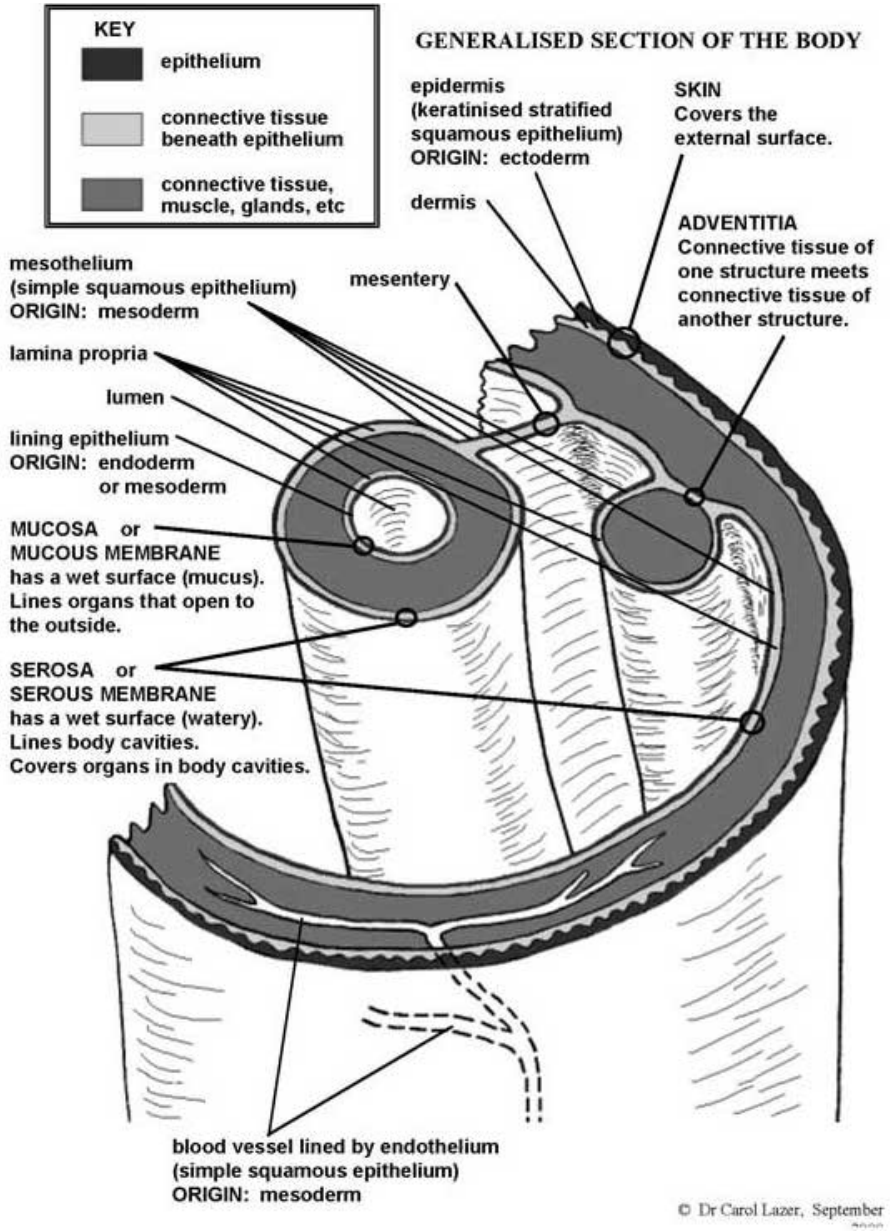

Basement Membrane

- Histological term for extracellular layer at base of an epithelium
  - ExtraCellular Matrix (ECM)
- Interface between epithelium and connective tissue
- Light microscope after staining
  - Not always visible
  - includes the **basal lamina**
    - Not visible by light microscope only EM

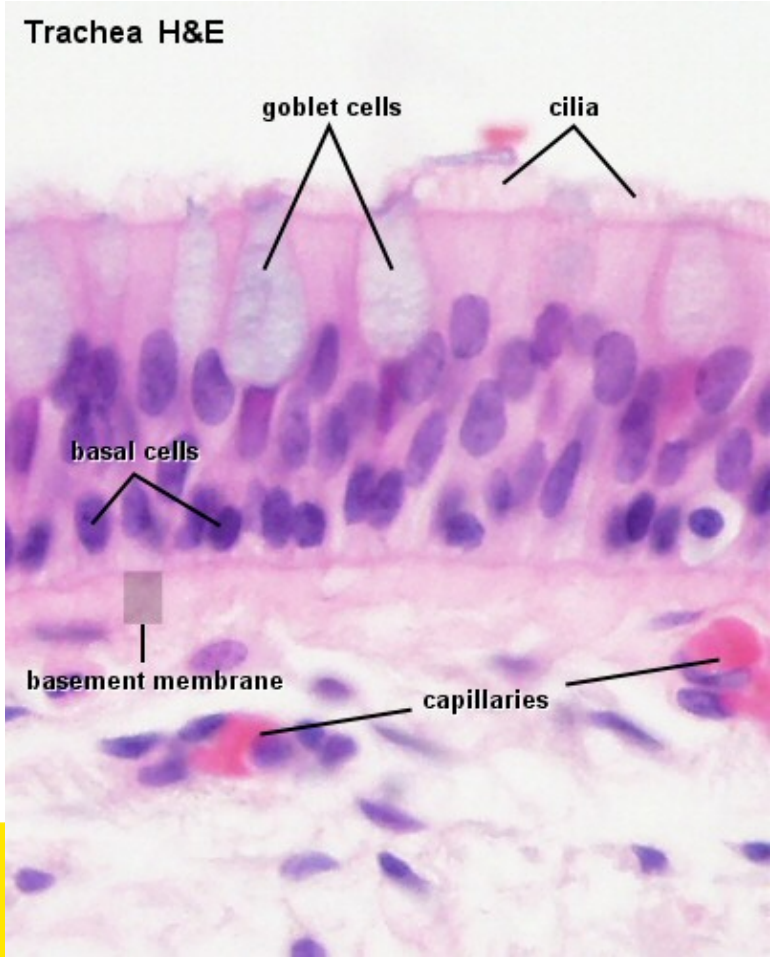

Classification of Epithelia

1. Number of cell layers
   1. Simple – one layer
   2. Pseudostratified – one layer
   3. Stratified – two or more layers



Classification of Epithelia

1. 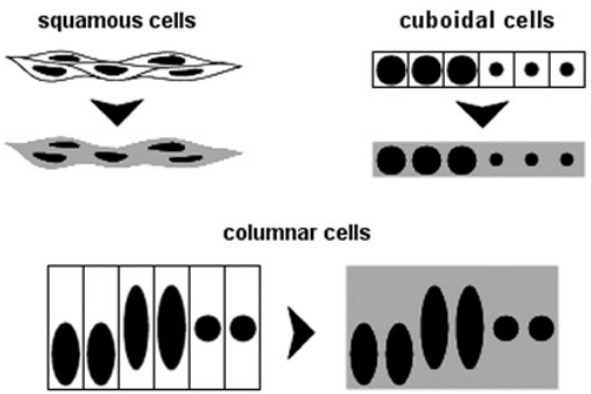

2. Shape of the cells in the **surface layer**
   1. squamous (scale- or plate-like)
   2. cuboidal
   3. columnar



Simple Squamous Epithelium

- Composed of a single layer of flattened, scale- or plate-like cells
- Common in the body
  - large body cavities, heart, blood vessels and lymph vessels
- Cell nuclei of the epithelial cells are often flattened or ovoid and located close to the centre of the cells

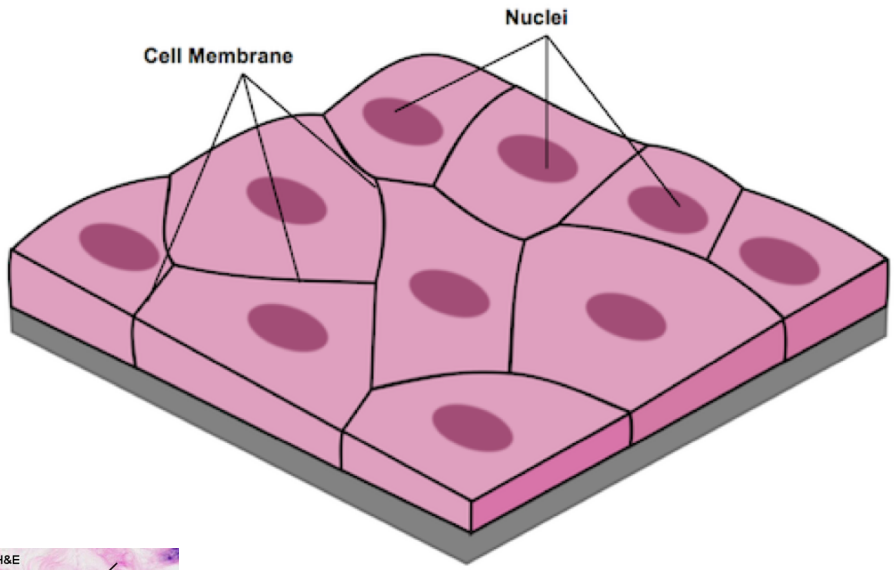

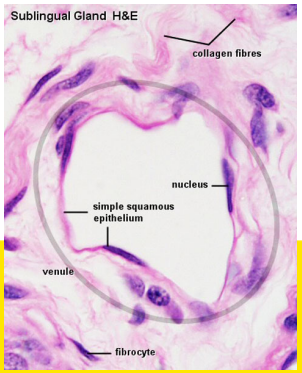

Simple Squamous Epithelium

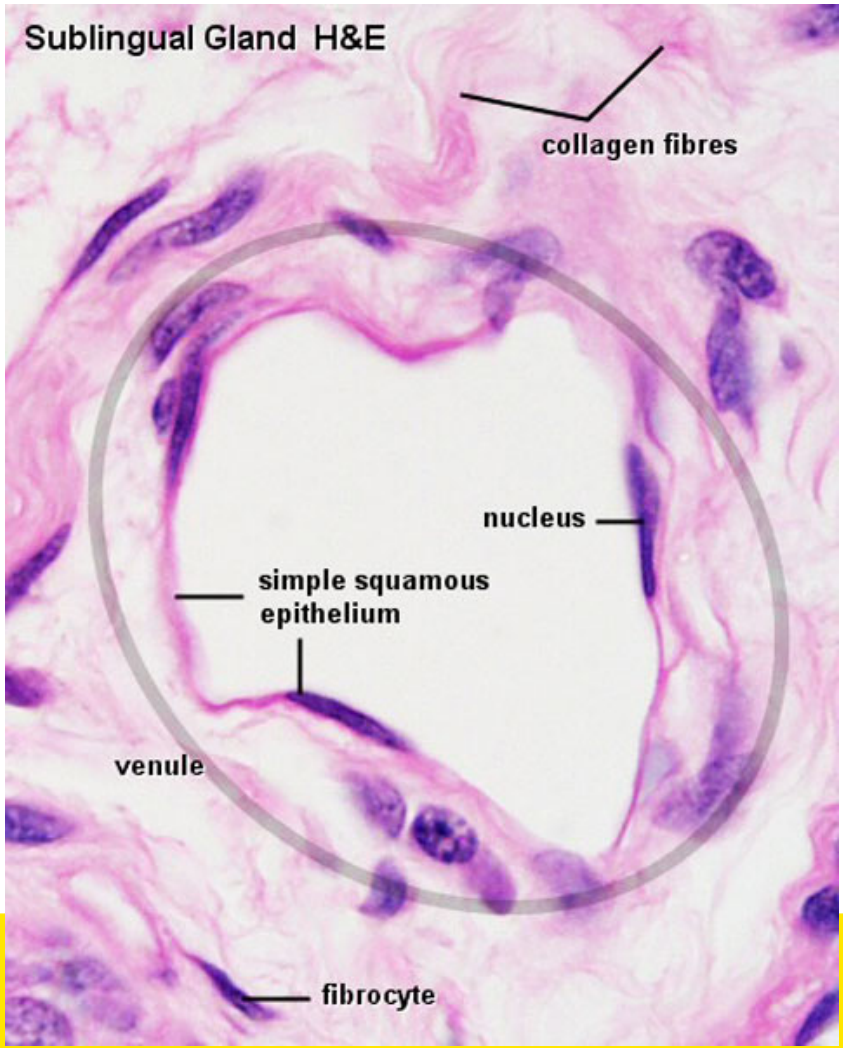

Simple Cuboidal Epithelium

- Cells appear cuboidal in sections perpendicular to the surface of the epithelium.
- Polygonal when viewed from the surface
- Locations
  - Glands - small excretory ducts
  - Thyroid gland - follicles
  - Kidney tubules
  - Ovary surface

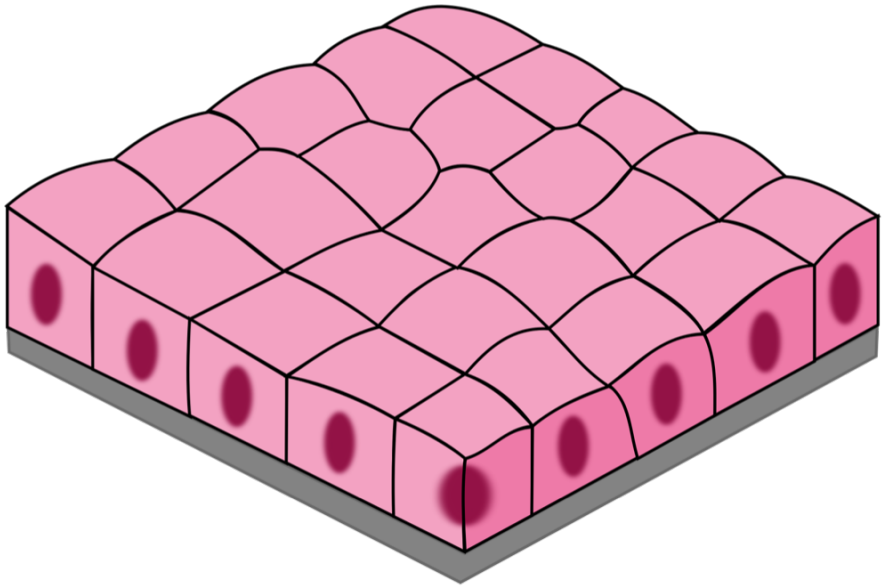

Simple Cuboidal Epithelium

Thyroid gland follicles

(cat)

Stain - H&E

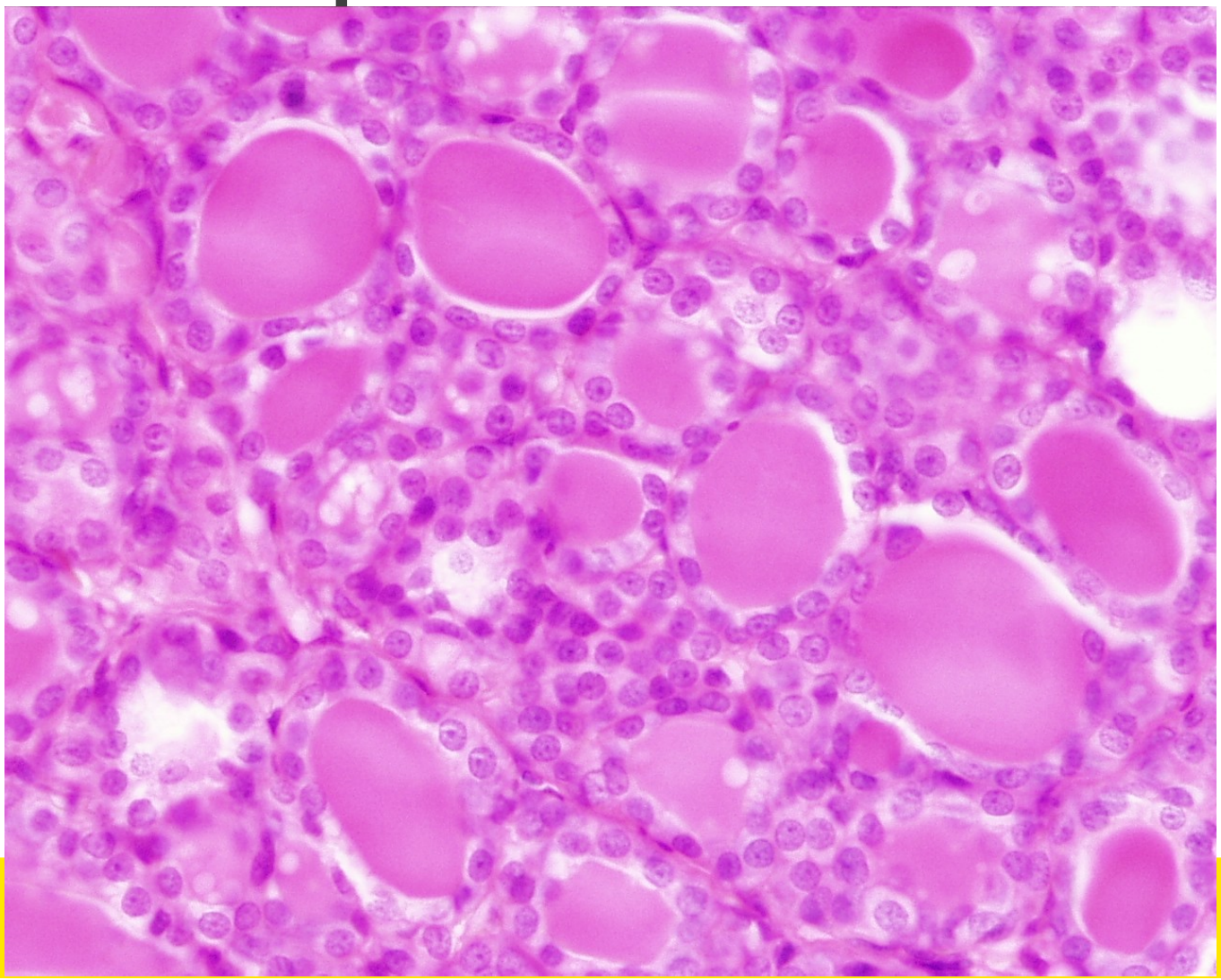

Simple Cuboidal Epithelium

Human Kidney

Nephron collecting duct

Distal tubule

Stain - H&E

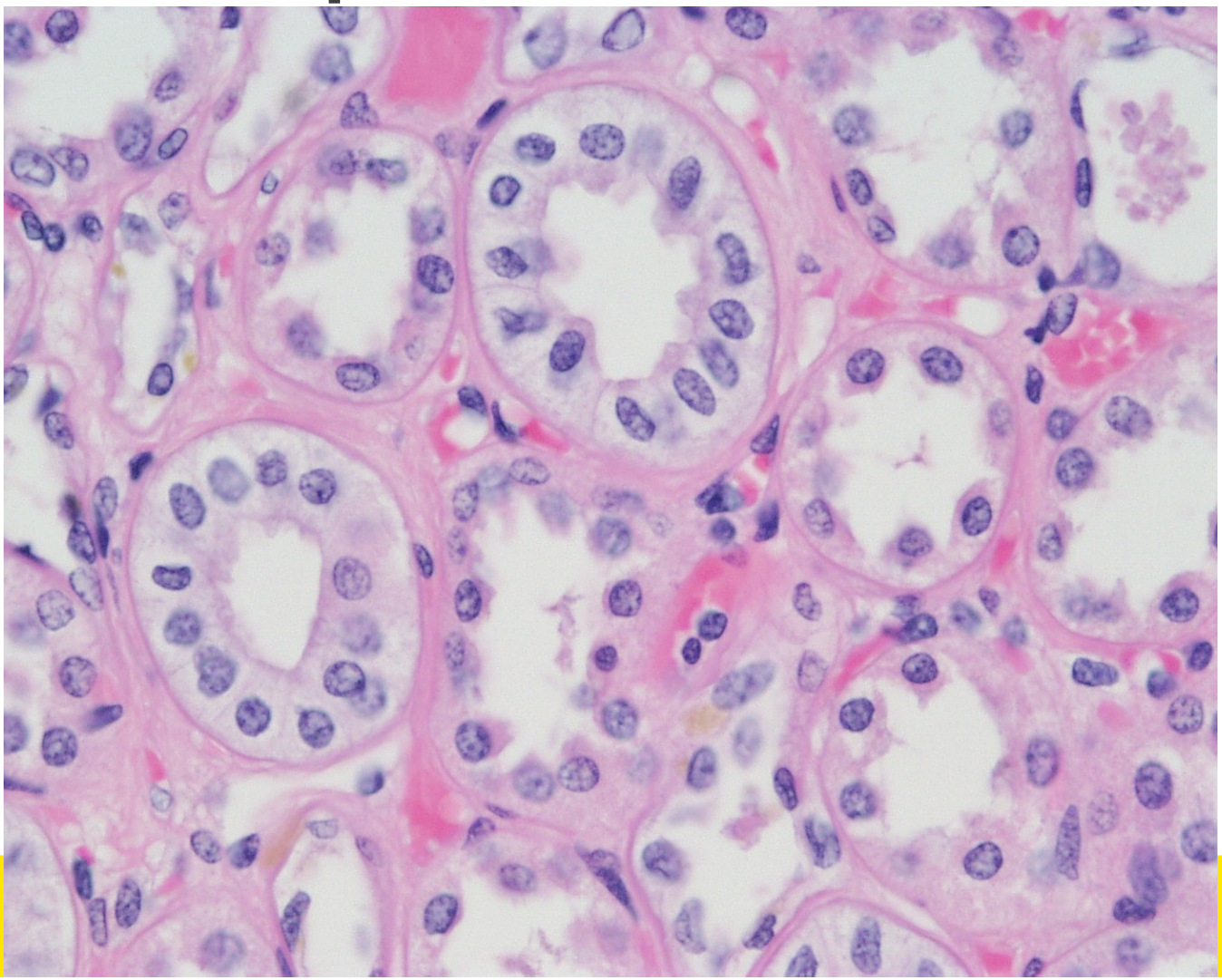

Simple Columnar Epithelium

- Cells are taller than they are wide
- Cell nuclei usually located at the same height
- Cell nuclei often close to base of the cytoplasm
- Gastrointestinal tract - from cardia of the stomach to the rectum

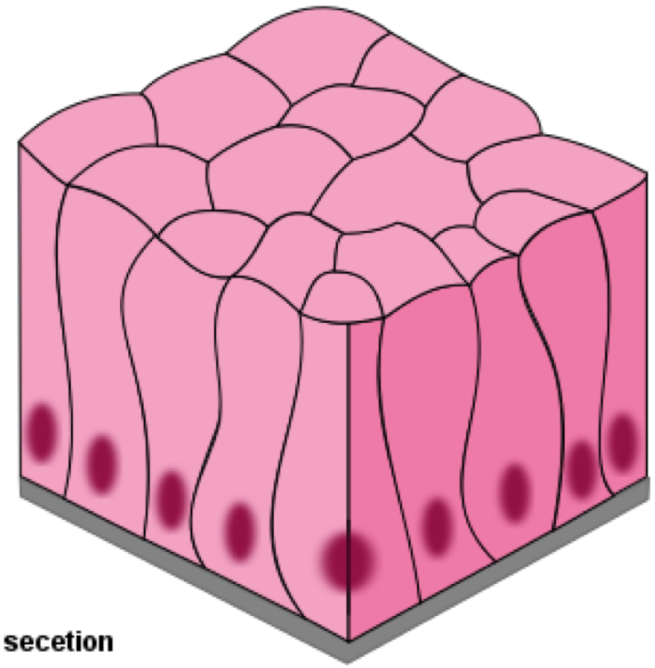

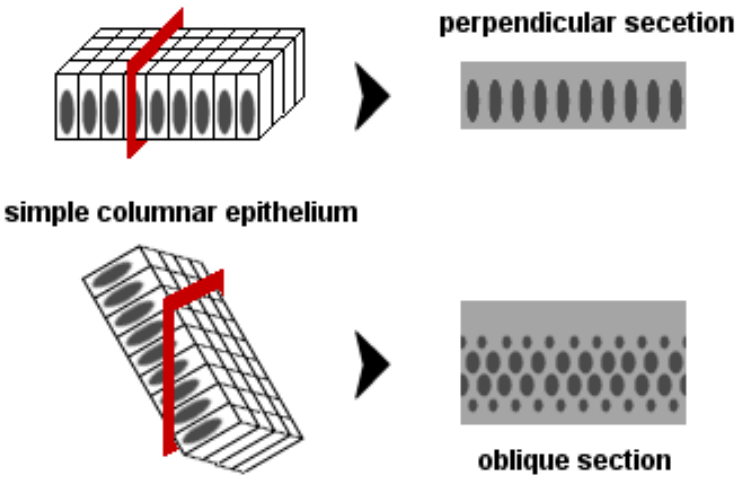

Simple Columnar Epithelium – Bile Duct

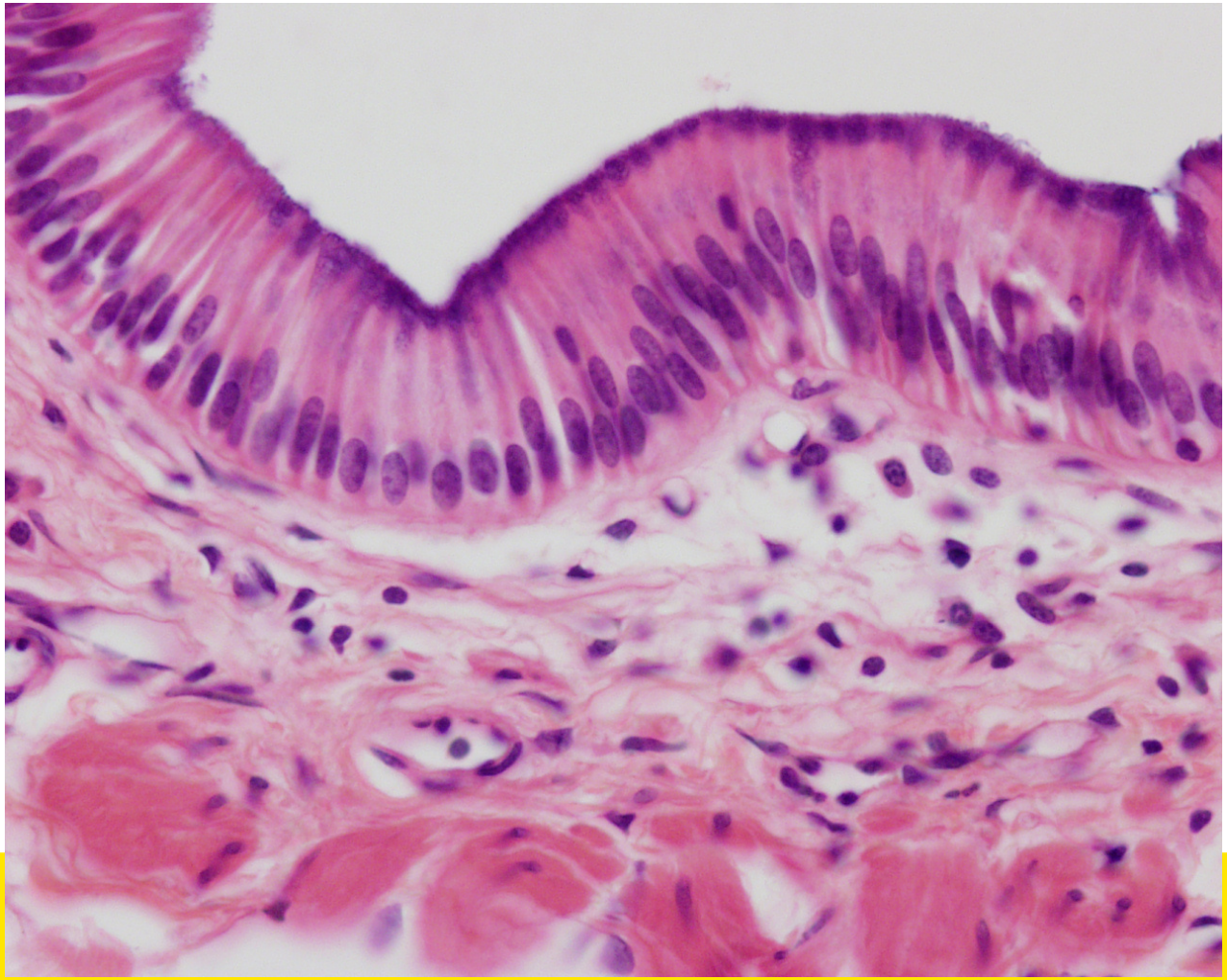

UNSW SYDNEY

Stratified Squamous Epithelium

- Skin, oesophagus, tongue, vagina
- Epithelium may vary in thickness
  - depends on the number of cell layers present
- Cells in contact with the basement membrane, are cuboidal or columnar in shape.
  - Basal cell layer
  - Basal cells mitotically active
- Next layers are polyhedral shaped
- Surface layers flattened

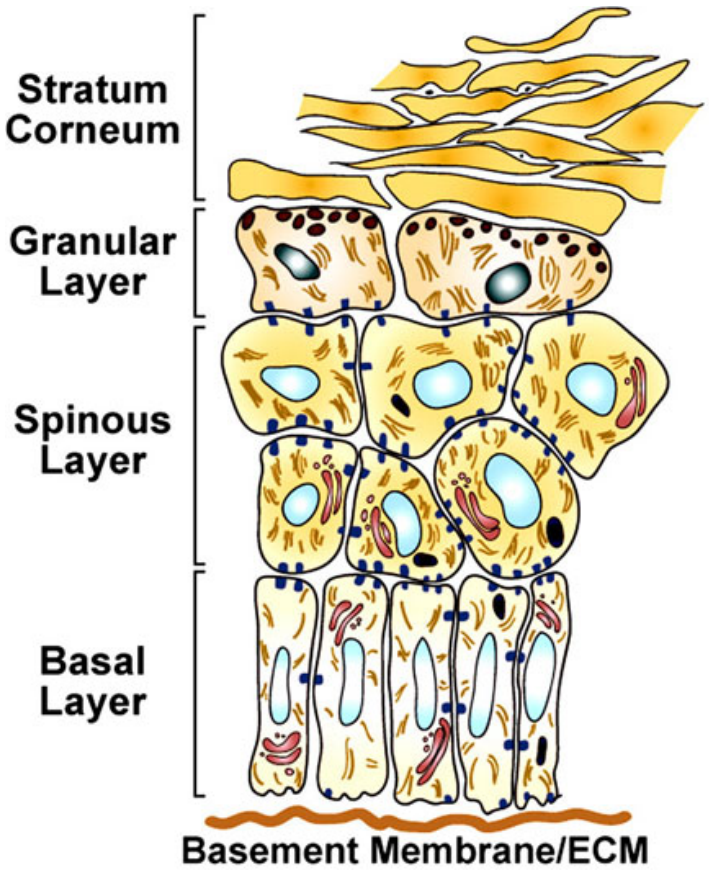

Stratified Squamous Epithelium

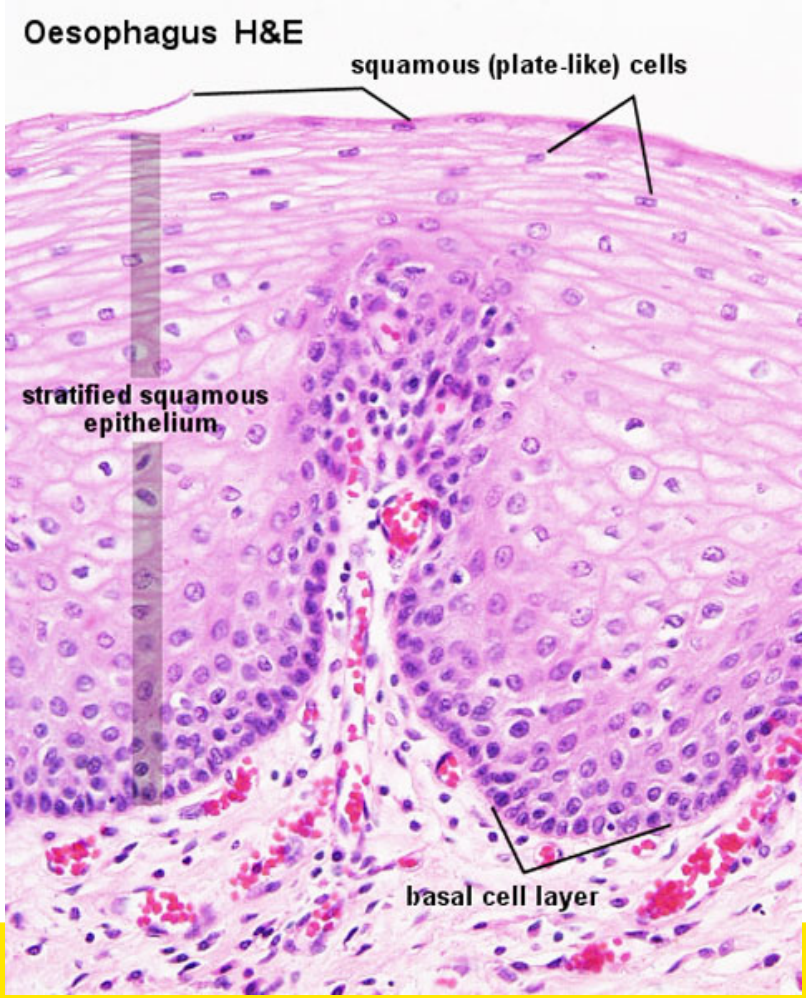

Stratified Cuboidal/Columnar Epithelium

- An uncommon type of epithelia
- Two-layered cuboidal epithelium
  - Sweat gland ducts
- Stratified columnar epithelia
  - Mammary and large salivary gland excretory ducts

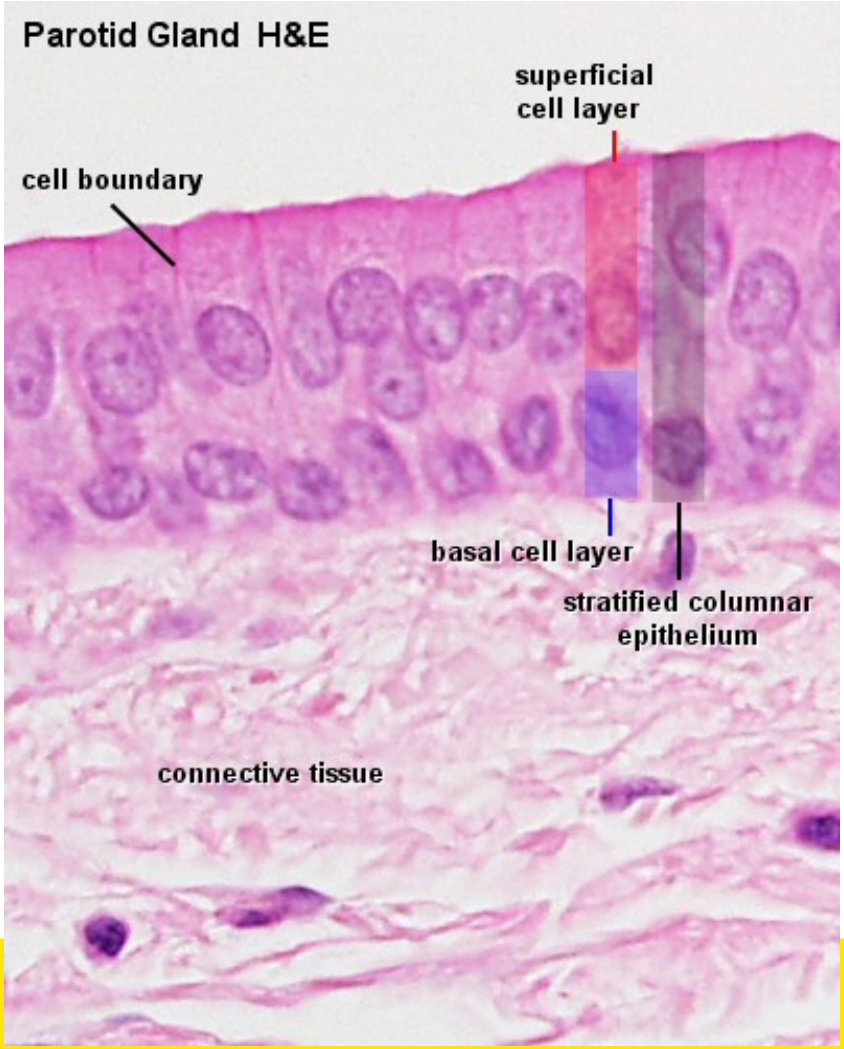

Stratified Columnar Epithelium - lactiferous duct

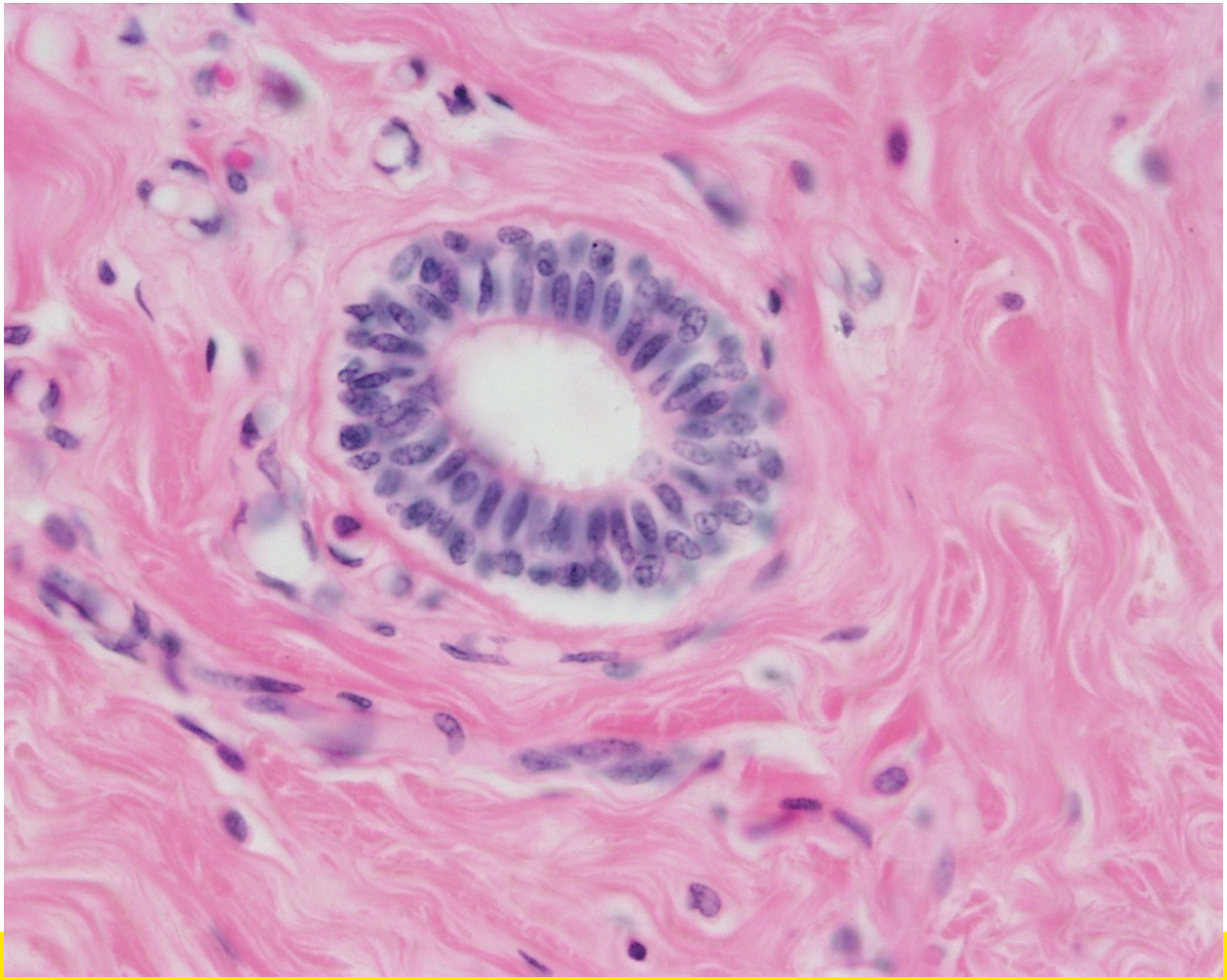

Stain - H&E

Pseudostratified Columnar Epithelium

- All cells contact the basement membrane
- Not all reach the epithelium surface
- Cell nuclei located in widest part of cell
- Nuclei often located at different heights
  - gives the epithelium a stratified appearance "pseudostratified"
- Testis epididymis, excretory ducts of many glands

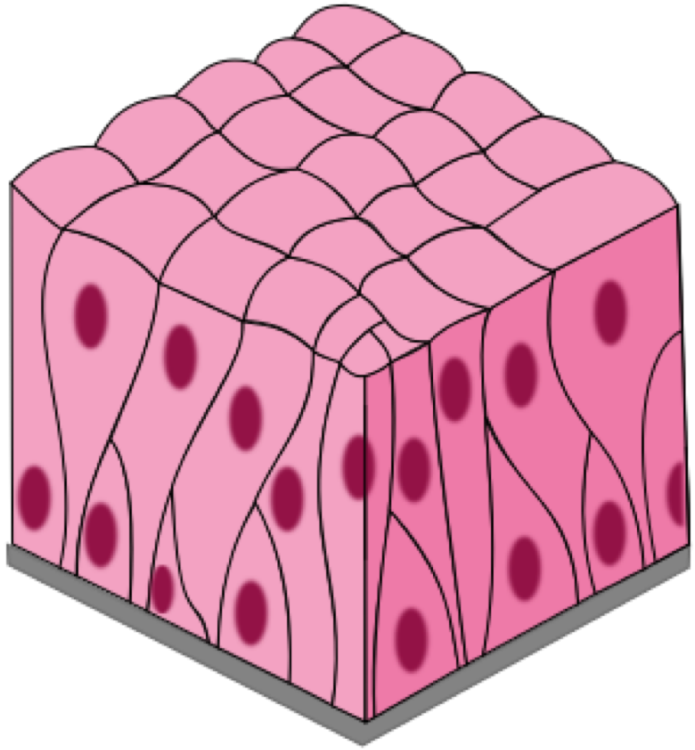

Pseudostratified Columnar Epithelium

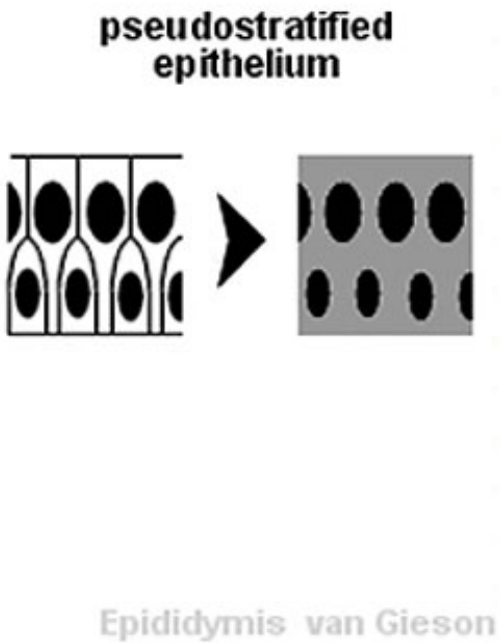

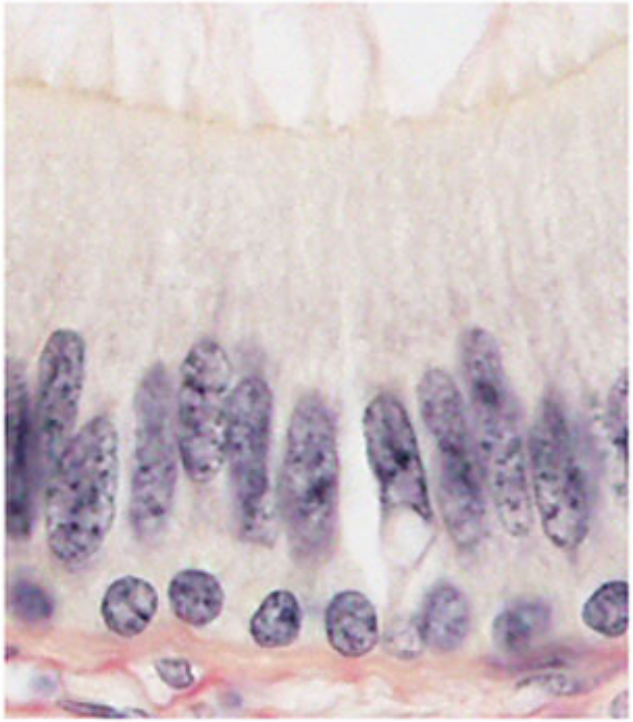

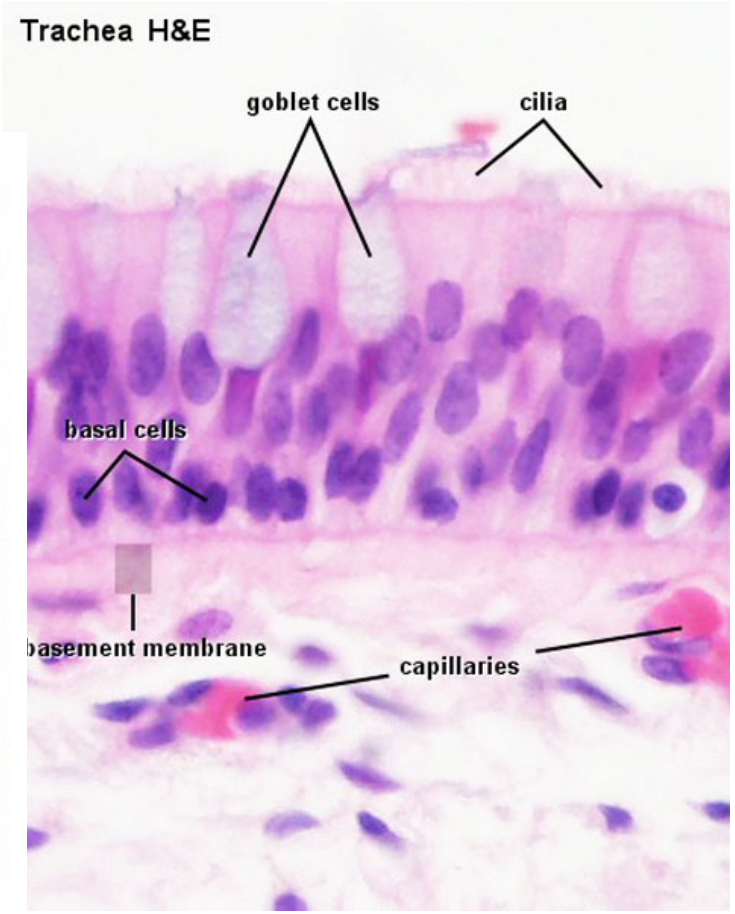

Pseudostratified Columnar Epithelium

Human vas deferens

Pseudostratified columnar epithelium

Basal cells

Stereocilia

Stain - H&E

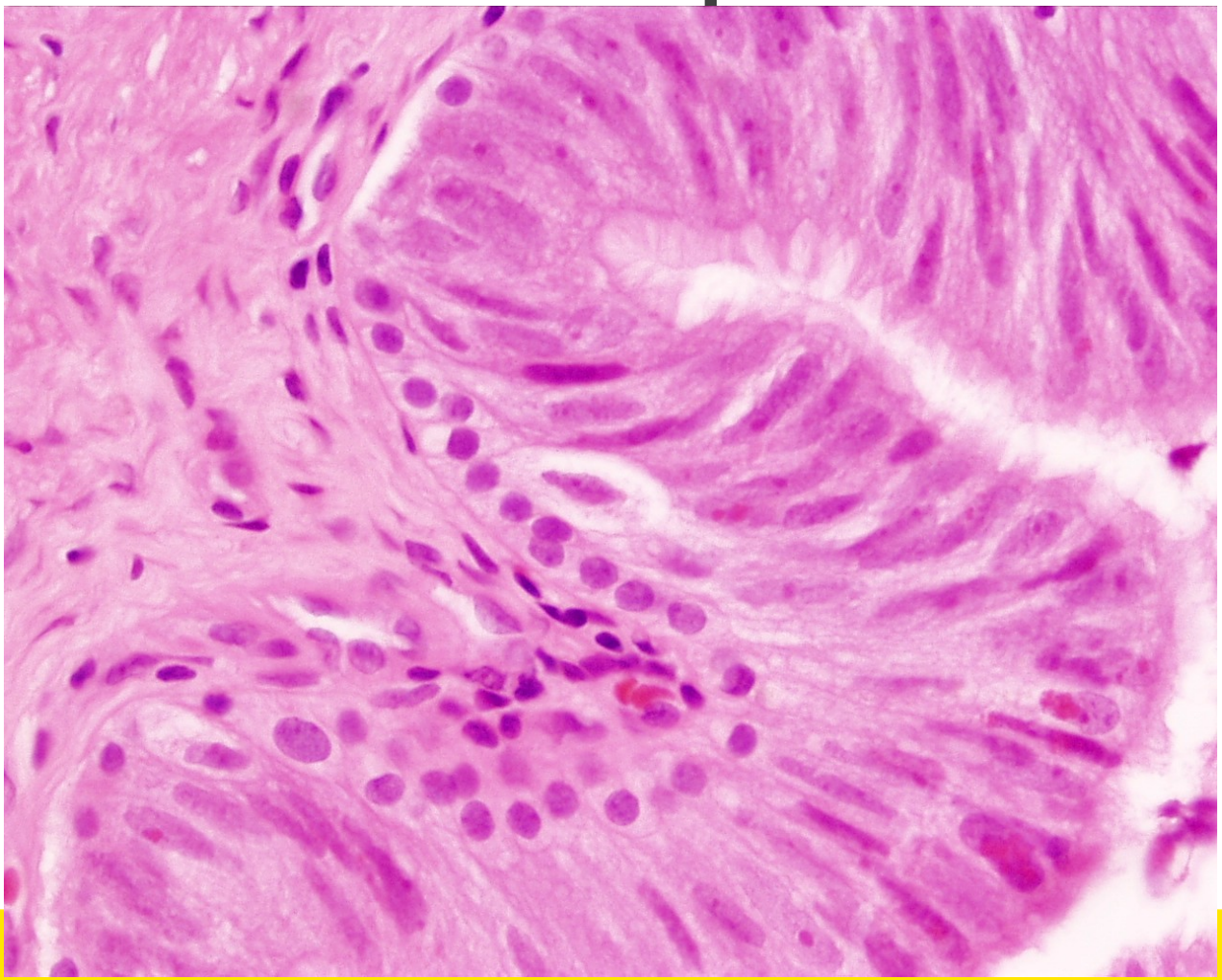

Transitional Epithelium

- Only in excretory urinary passages
  - renal calyces, pelvis, ureter, urinary bladder, and part of the urethra
- Surface cell shape varies depending upon tissue distension
  - “relaxed” appears as many cell layers
  - “distended” appears as only one or two layers

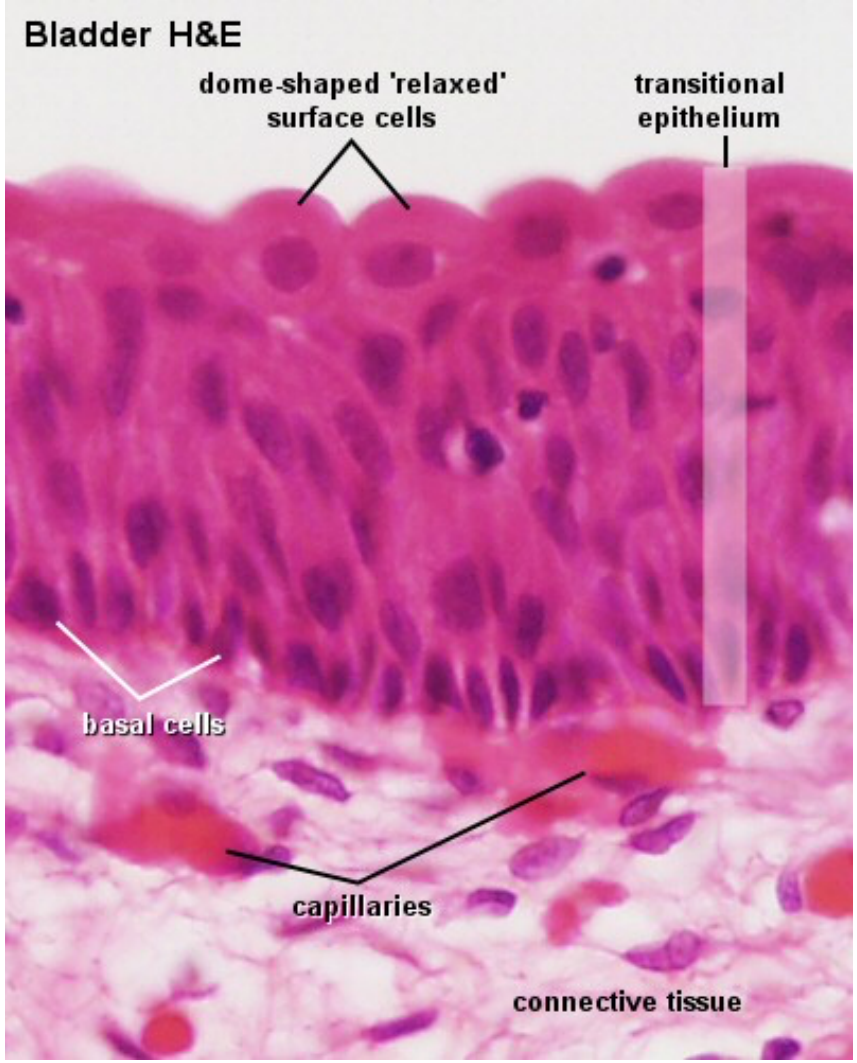

Apical Surface Specializations

- Epithelial cells can have a number of different apical specialisations
  - Microvilli
  - Cilia
  - Stereocilia

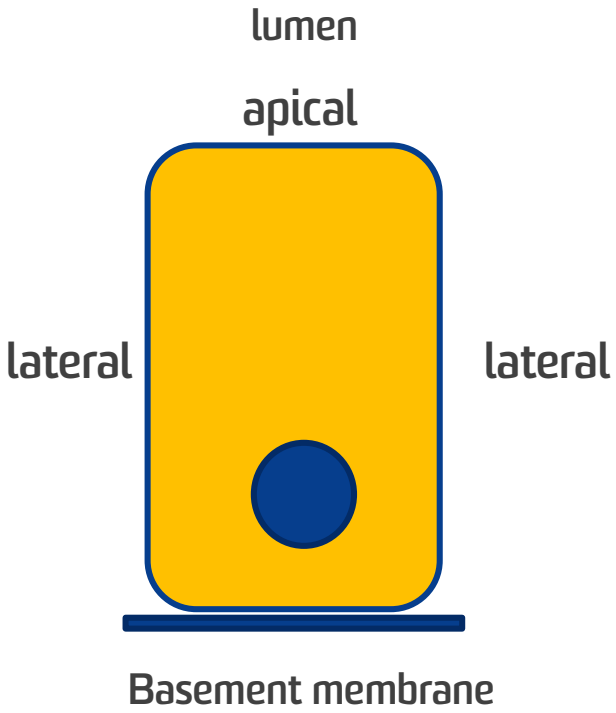

Microvilli Epithelium

- Microfilament filled
- Apical membrane extensions
- Increase surface area
- Absorption
- GIT - Small intestine

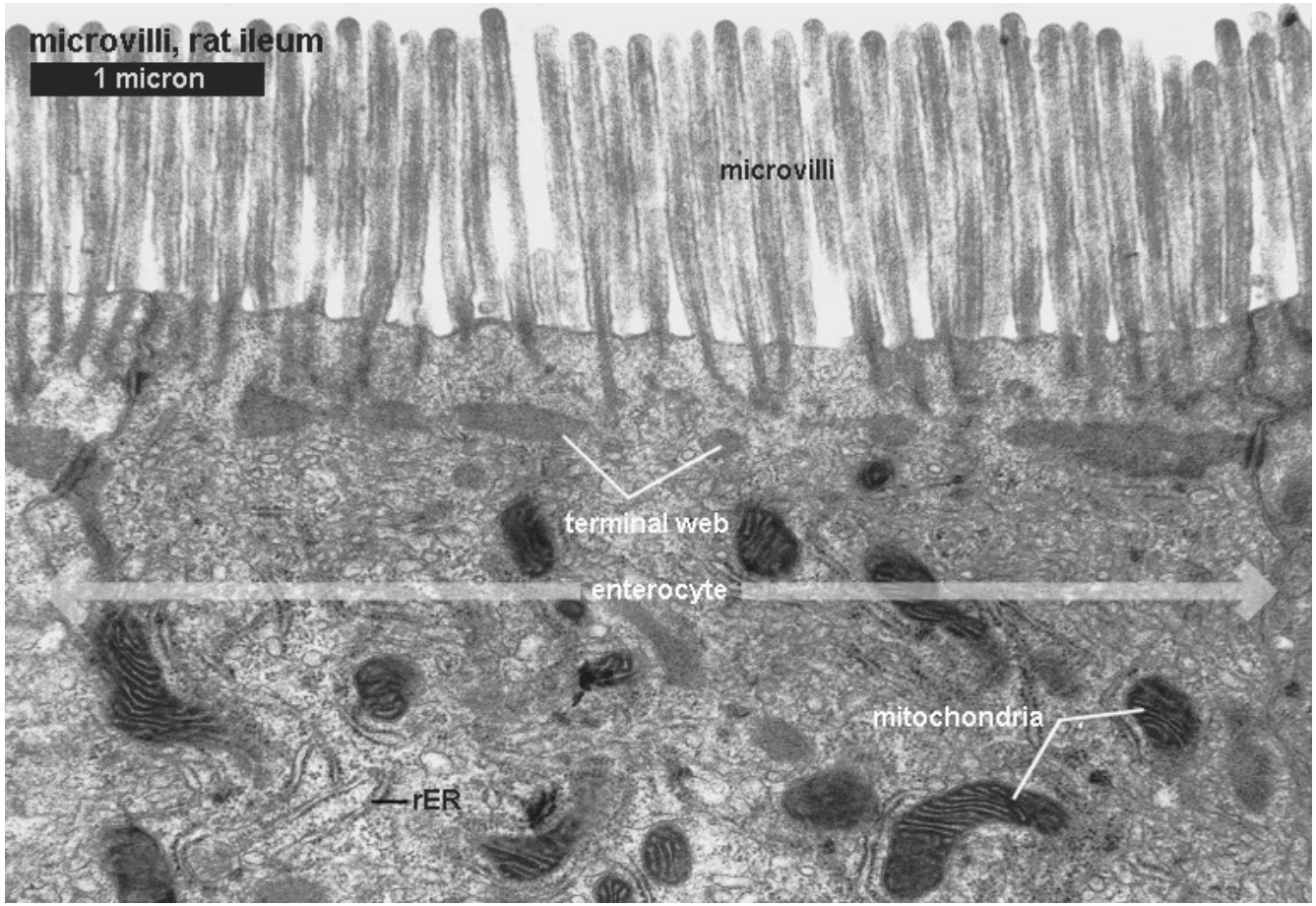

Ciliated Epithelium

- Microtubule filled
- Apical membrane extensions
- Motility
- Move lumen solutions
- Respiratory tract, uterine tube
  - Mucous movement

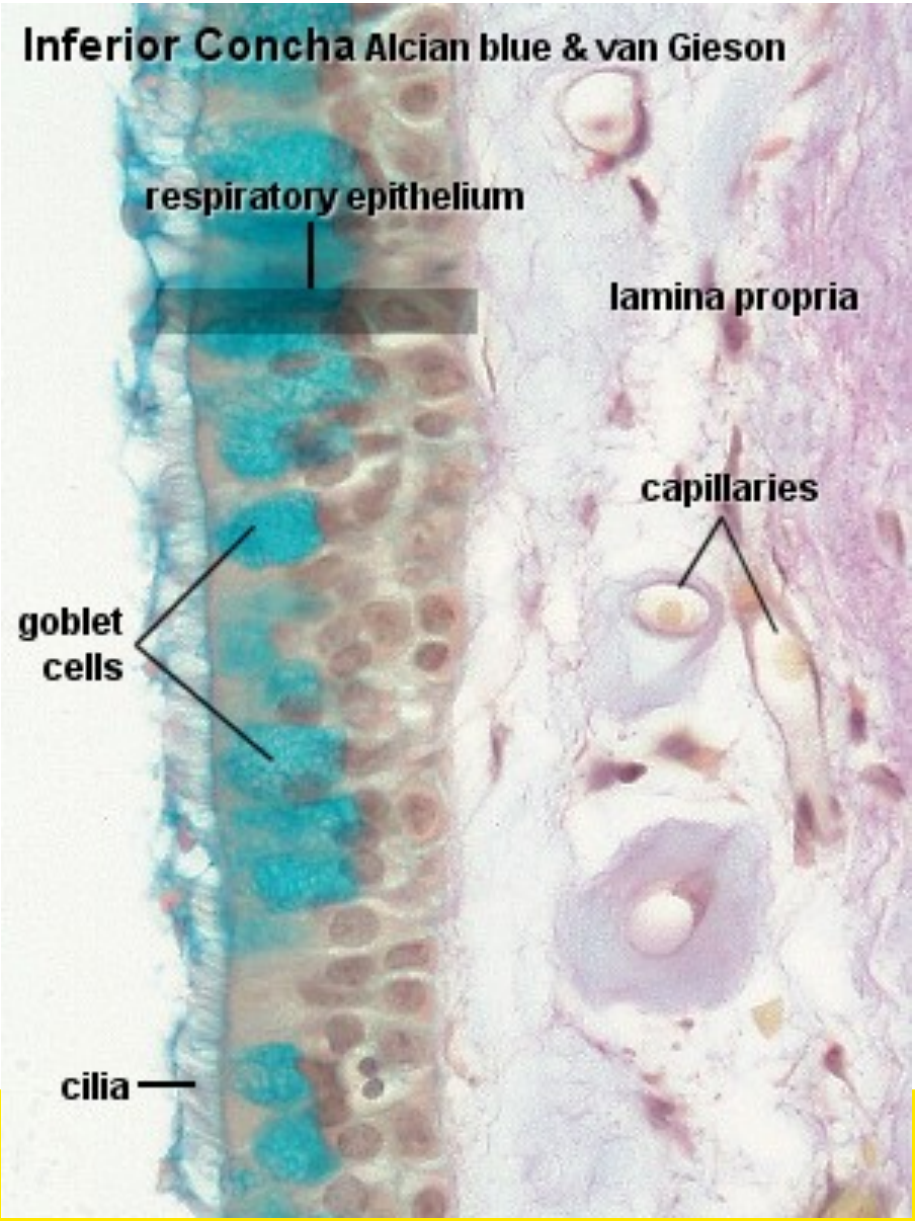

Ciliated Epithelium

Human bronchiole

Simple columnar epithelium

Ciliated

Stain – H&E

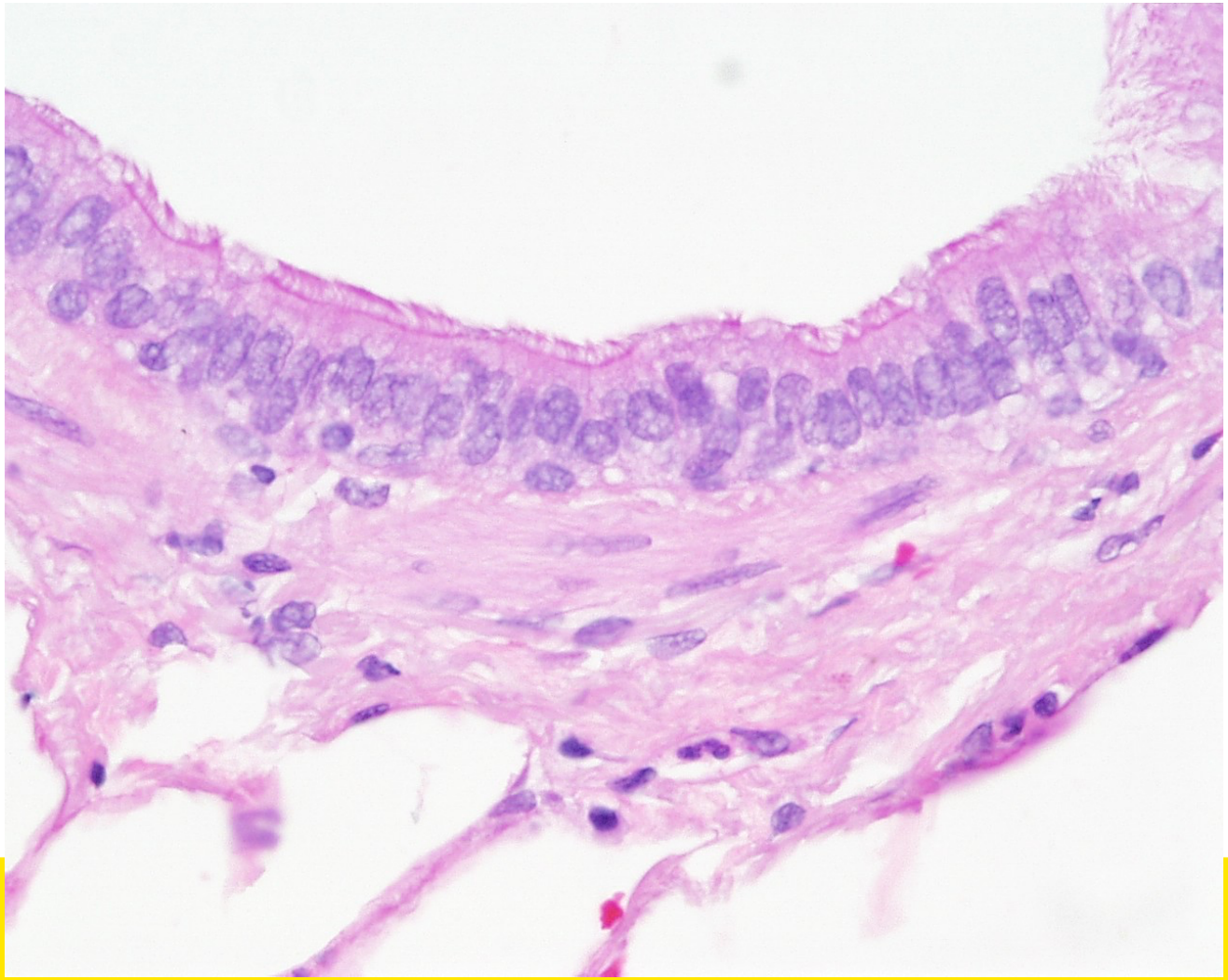

UNSW SYDNEY

Stereocilia Epithelium

- Microfilament filled
- Apical membrane extensions
- Not motile
  - Careful not “cilia” MT
- Epididymis, ductus deferens
  - facilitate absorption
- Cochlea hair cells
  - Signal transduction
  - Hearing

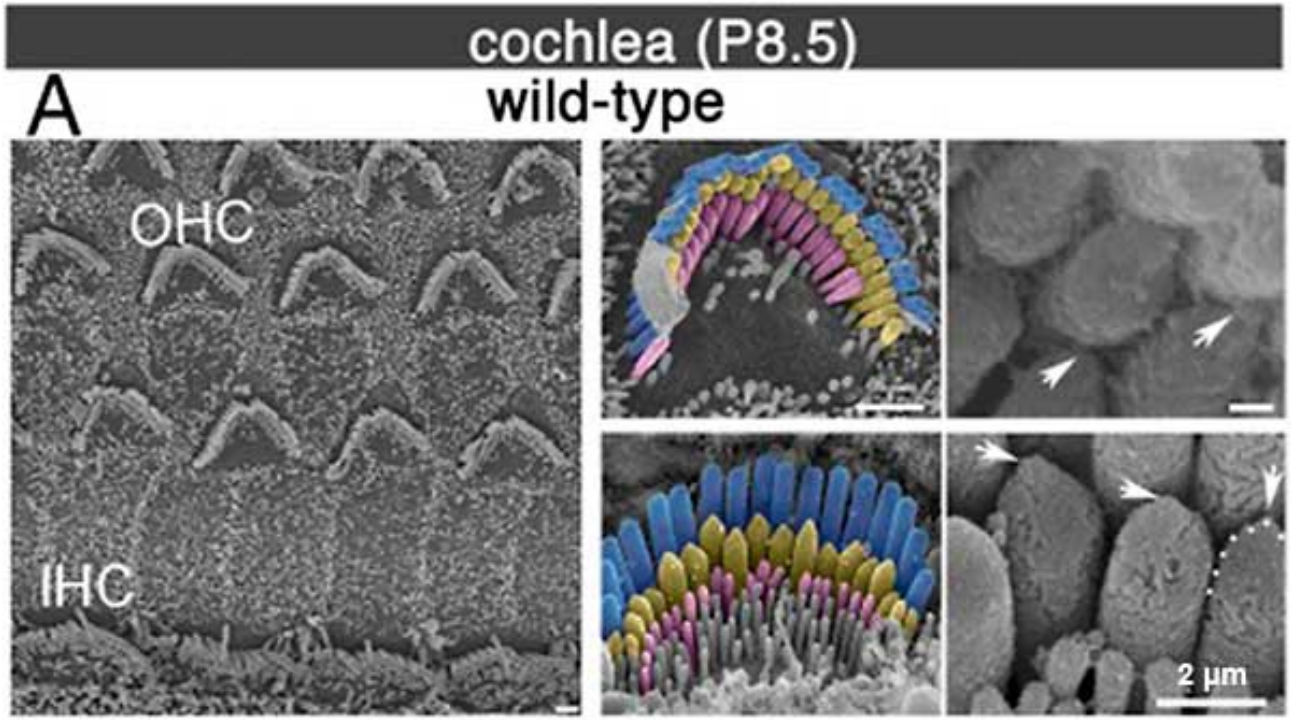

PMID: 28835534

Emptoz etal., (2017) PMID 28835534

UNSW SYDNEY

Pseudostratified Columnar Epithelium

Human vas deferens

Pseudostratified columnar epithelium

Basal cells

Stereocilia

Stain - H&E

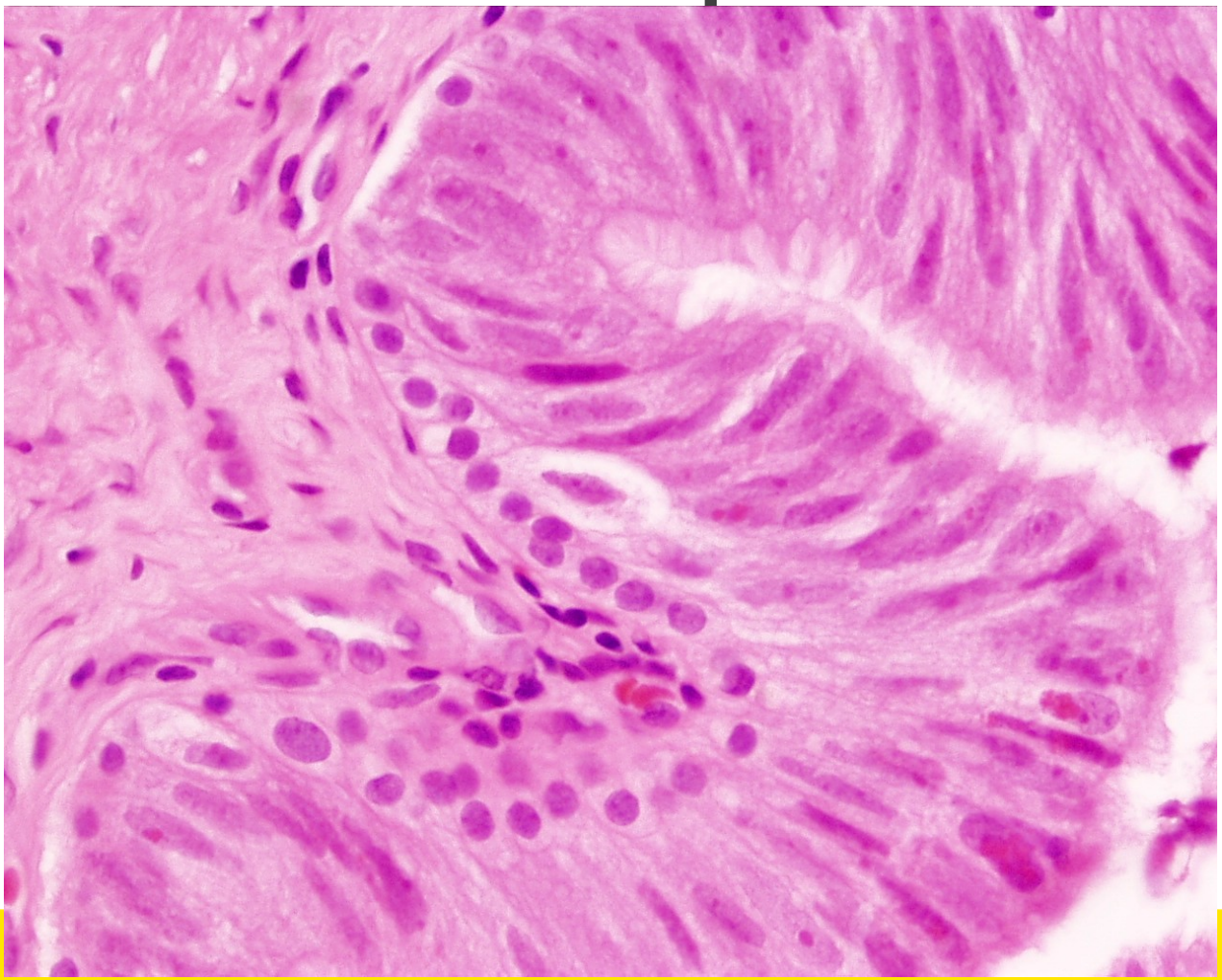

Lateral and Basal Surface Specializations

- **Adhesion junctions**
- Lateral – cell-cell junctions
- Basal – cell-basement membrane (ECM)
  - ECM - extracellular matrix

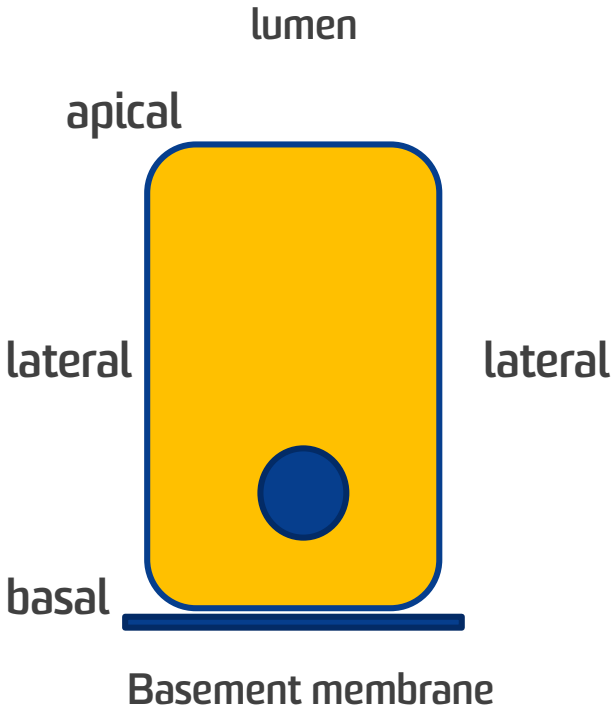

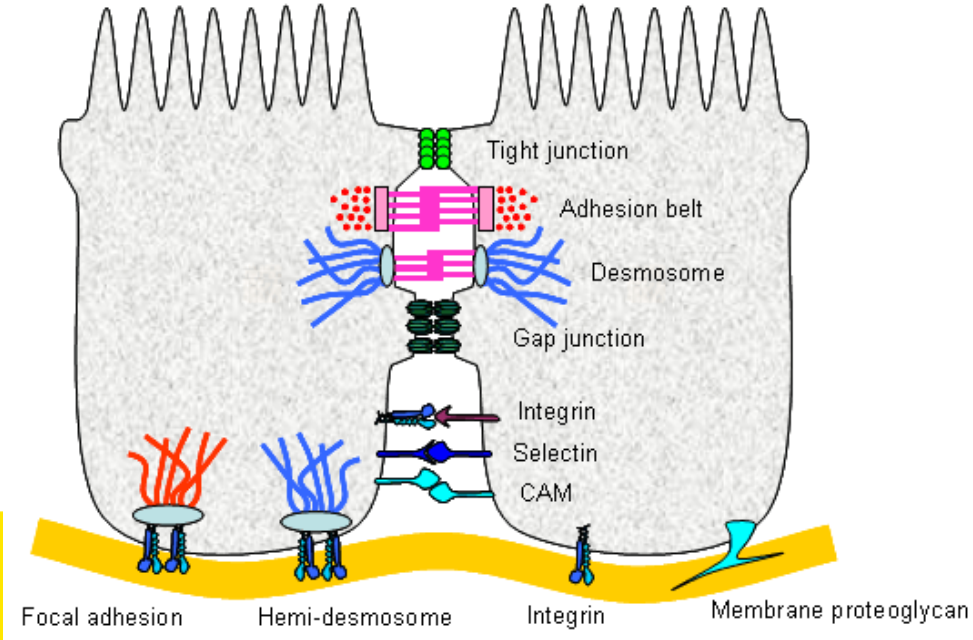

Cell-Cell Junctions

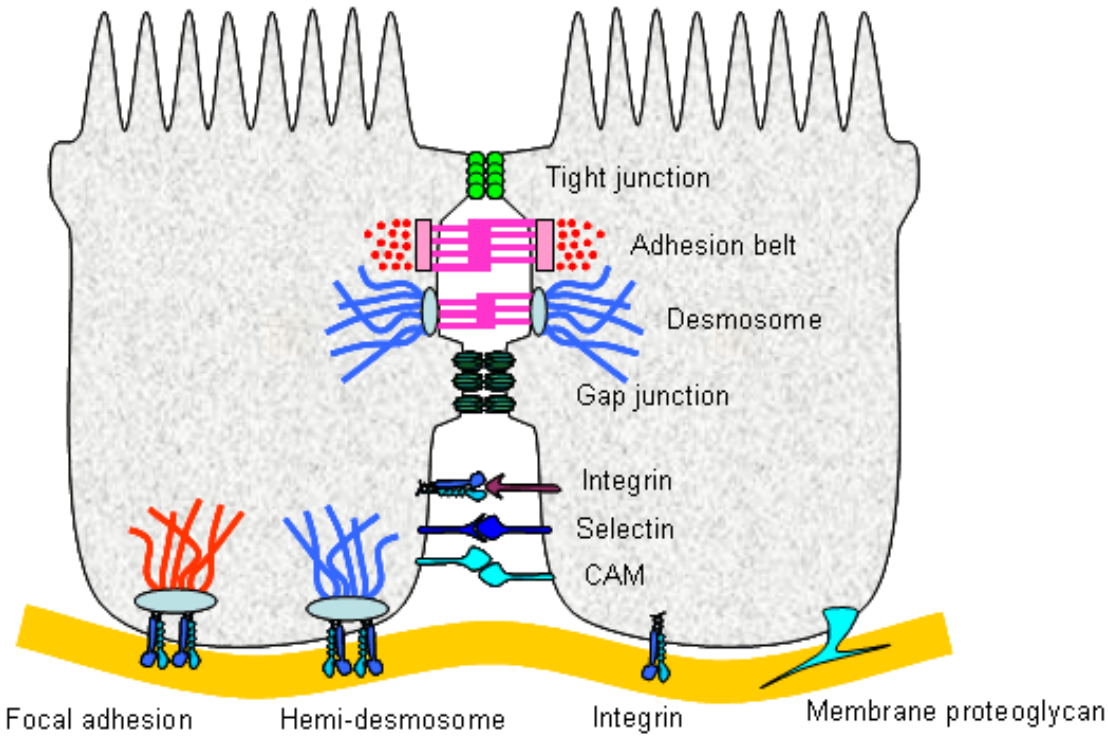

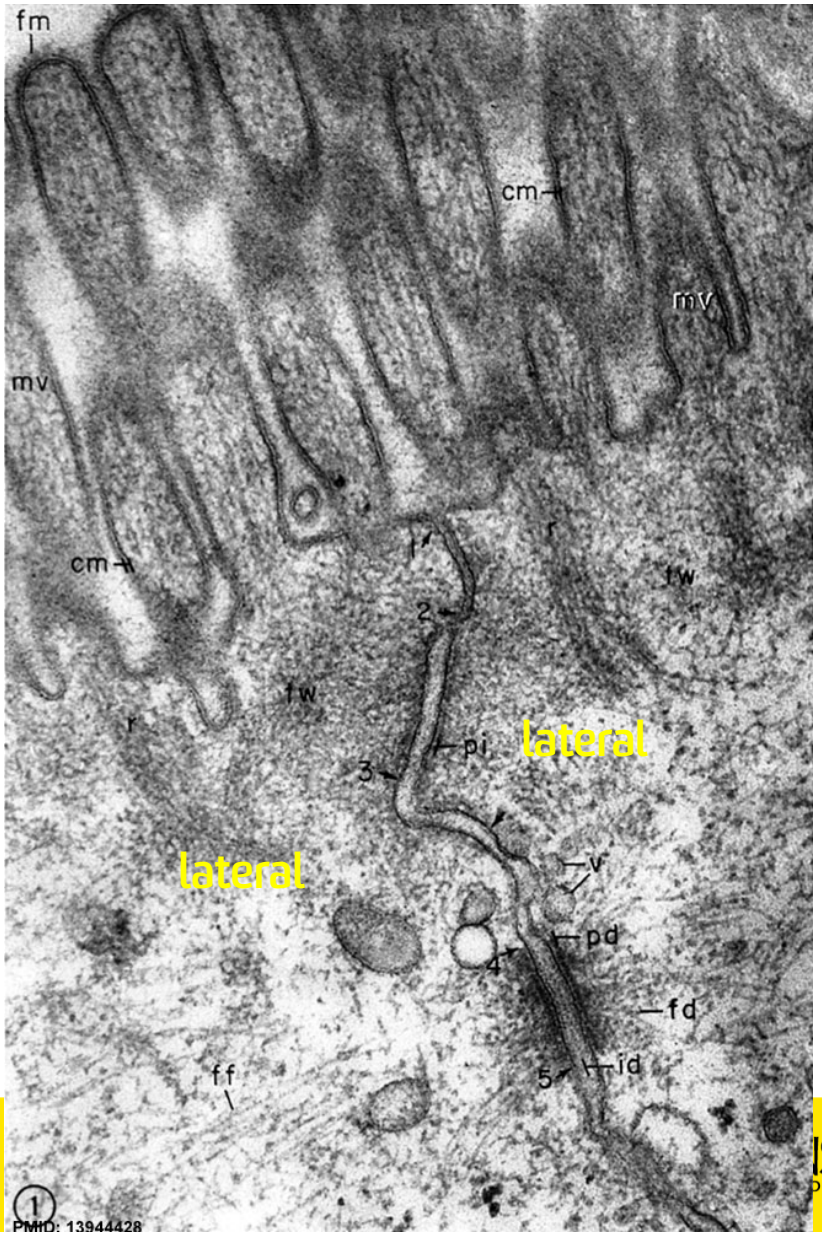

Electron micrograph

Lateral Surface Specializations

- Cell-Cell junctions
  - several different types in the one cell
- Tight Junction
- Adherens Junction
- Desmosome
- Gap Junction

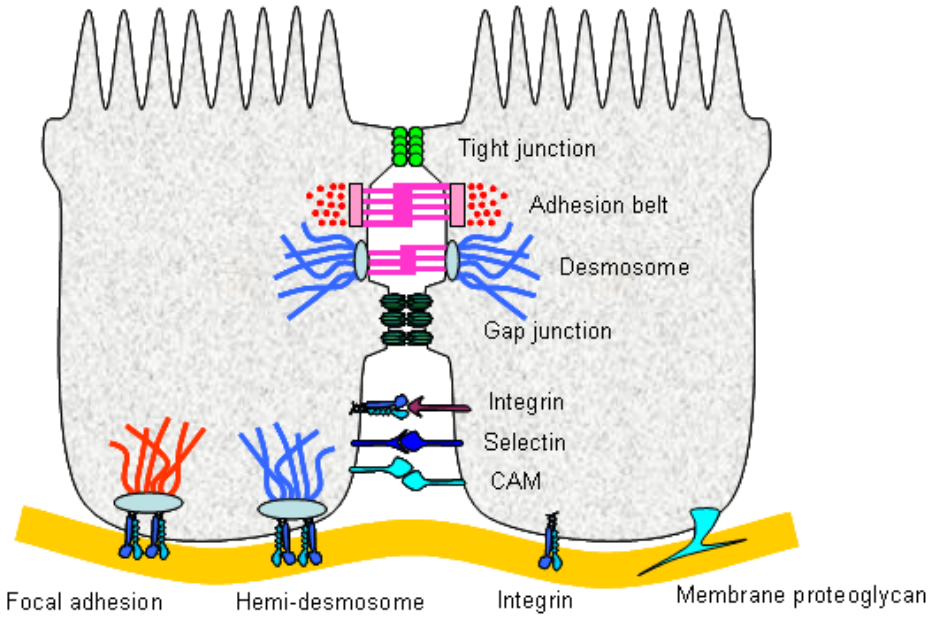

Tight Junction - zonula occludens

- Fusion of 2 plasma membranes
  - acts as a “seal”
- located on epithelia linings
  - digestive system gut, ducts, cavities of glands, liver, pancreas capillary walls urinary bladder
- central nervous system
- blood-brain barriers
  - brain capillaries and choroid plexus (modified cuboidal epithelium)

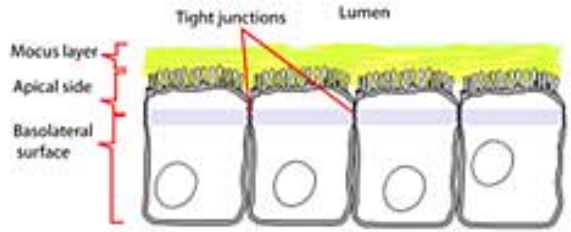

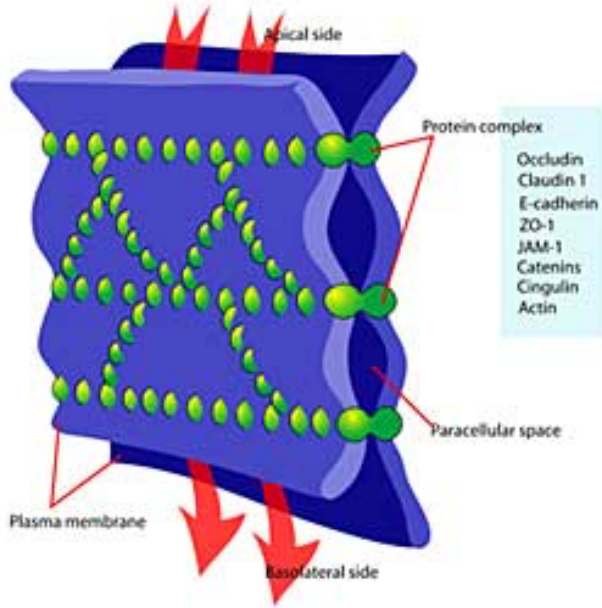

Adherens junctions - zonula adherens

- plasma membrane proteins linked to **microfilaments** (MF)
- anchor plaque occurs under membrane
- heart muscle, layers covering body organs, digestive tract

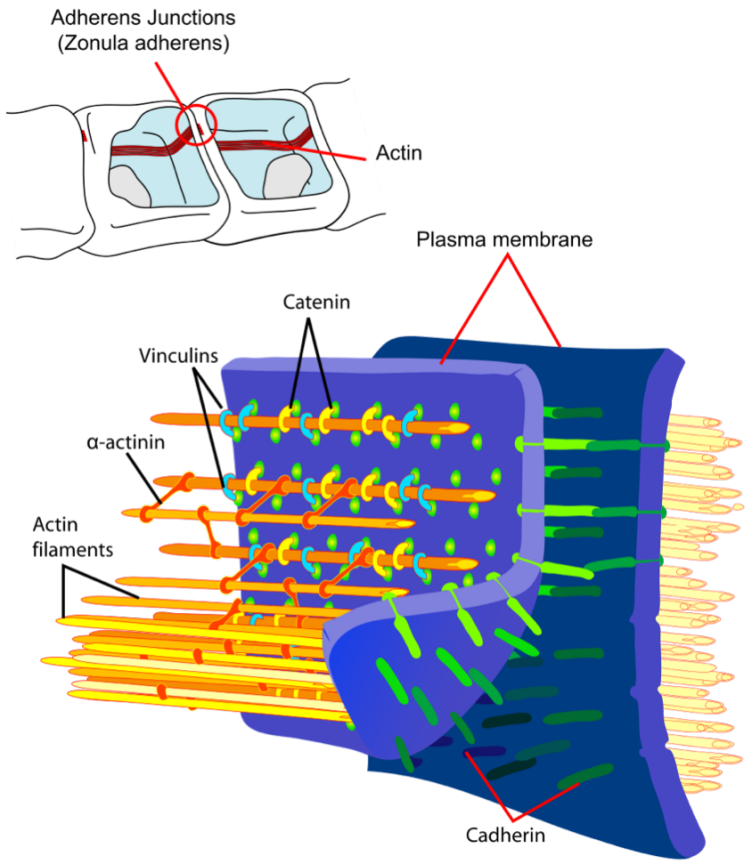

Desmosomes - macula adherens

- plasma membrane proteins linked to **intermediate filaments** (IF)
- dense plaque that occurs under the membrane
- *desmos* = bond
- skin, lining of internal body cavity surfaces
- disappear when cells are transformed

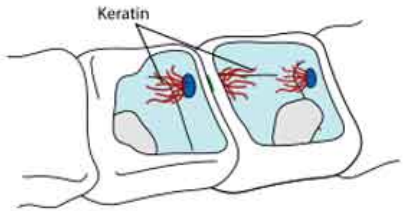

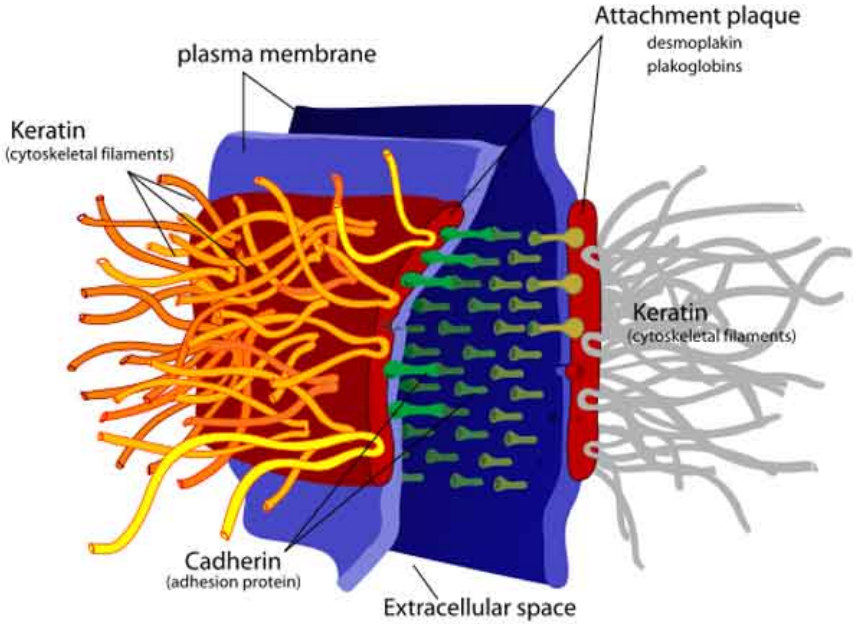

Gap Junctions

- Plasma membrane proteins linked to each other
  - two hemi-channels
  - form hollow 1.5 nm diameter cylinders
- Used for rapid communication
  - Electrical and chemical integration
  - Act as single functional unit
- Heart muscle, smooth muscle, embryo blastocyst cells

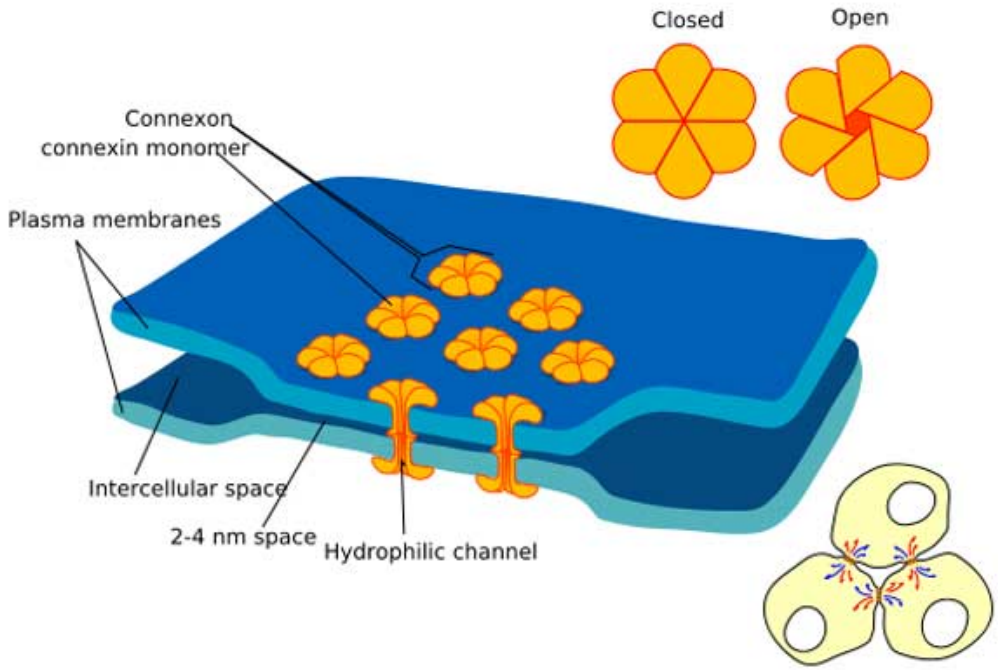

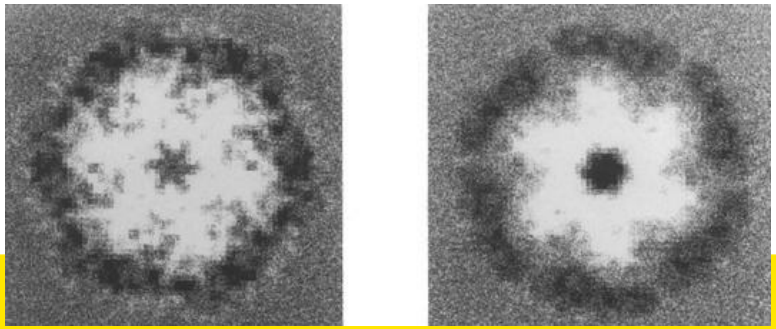

Electron micrograph

Basal Surface Specializations

- Cell-Basement Membrane junctions
  - several different types in the one cell
- Hemi-Desmosome (IF linked)
  - “hemi” (= half)
- Focal Adhesion (MF linked)
  - Half an adherens junction