AN INTEGRATED APPROACH TO TEACHING HUMAN EMBRYOLOGY

murray.smith@unsw.edu.au

Murray Smith & Mark Hill

m.hill@unsw.edu.au

Department of Anatomy

School of Medical Sciences

The University of New South Wales

Sydney, New South Wales 2052, AUSTRALIA

Background

- Presents our experiences of teaching Human Embryology for the past 30 years
- 1975: Development of Microfiche Card
  - 49 images (7 x7)
  - viewed using Canon Microfiche Readers

Microfiche Cards

- 6 mm pig embryo
  - Carnegie Stage (CS) 12/13
- 27 mm human embryo
  - Carnegie Stage (CS) 22
- 27 mm human embryo
  - Selected high power sections of organ systems

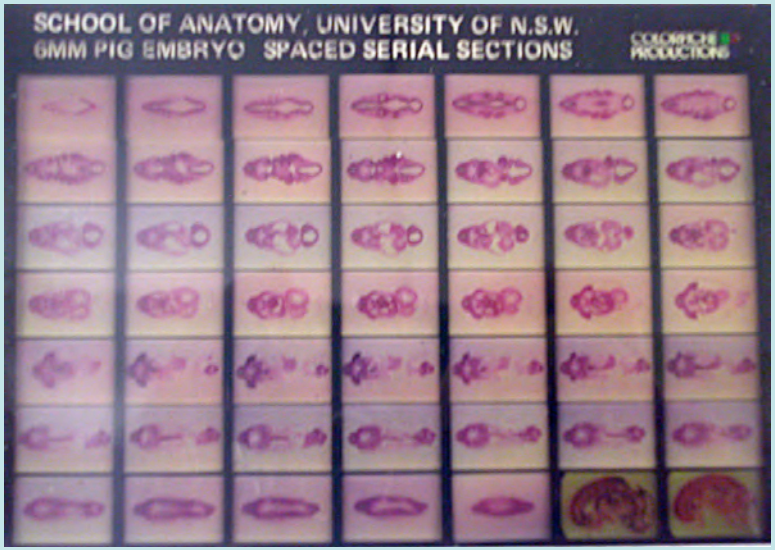

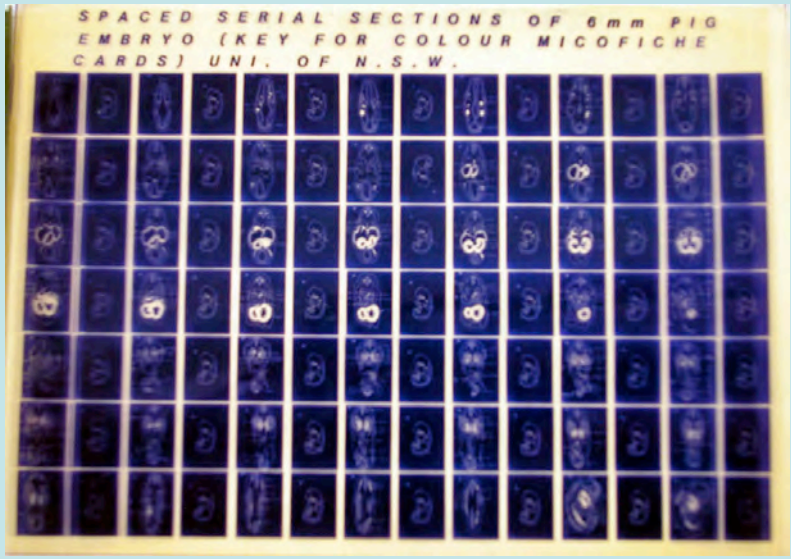

Learning Skills

- Allows students to study in groups of 4
  - Identify structures
  - Relationships
  - Concepts
  - Problems

Learning Skills

- Understand embryos and structures
  - 3D (three dimensions)
  - 4D fourth dimension of time (growth)

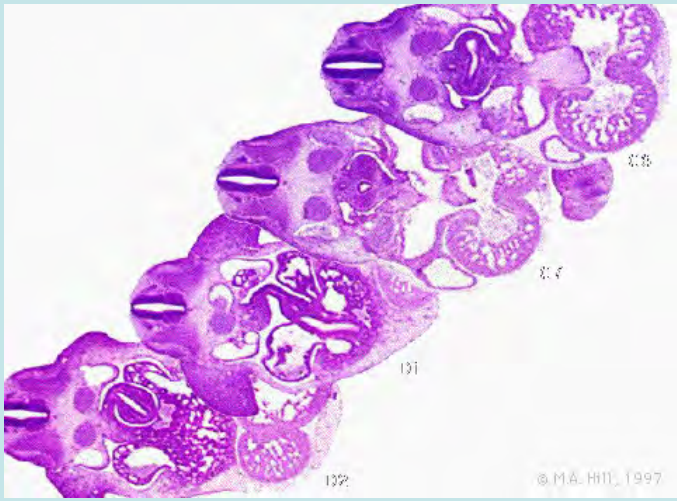

Stage 13/14

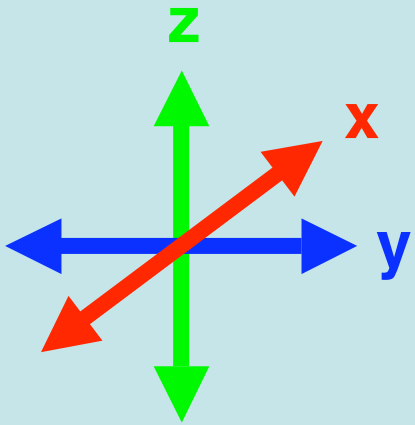

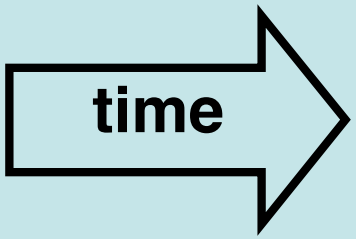

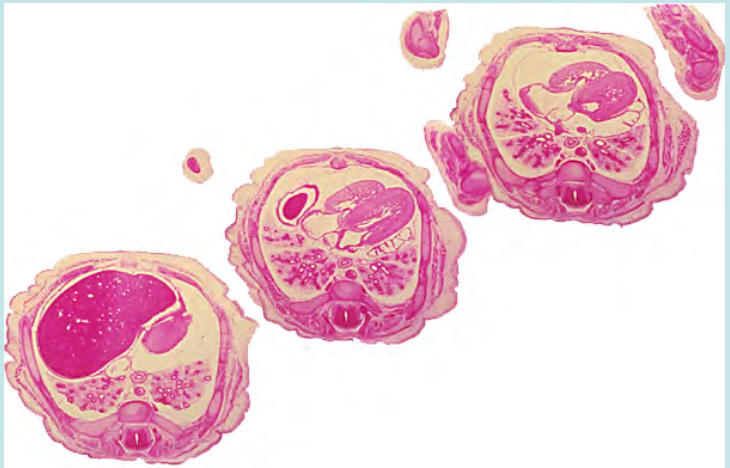

Stage 22

Project Development

- Computers as educational tools
- Microfiche images
  - Transferred to an internal network
  - Then to a CD ROM
  - Then to the web

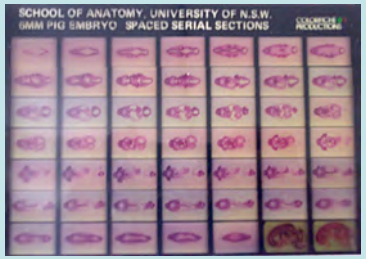



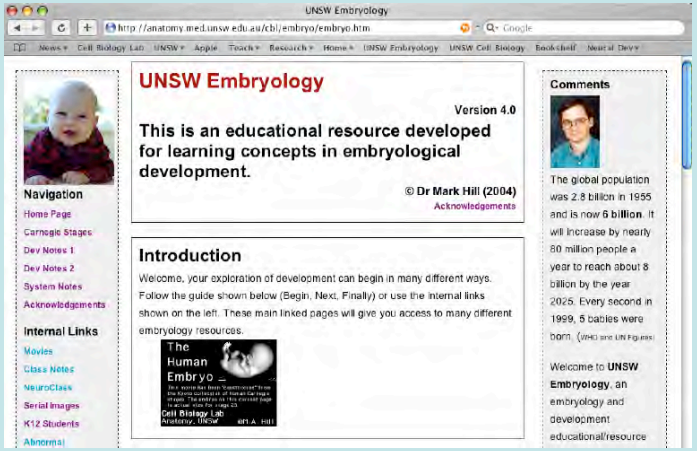

Serial Images

- Understanding Relationships
- computer aided teaching
- enabled individual images to be related to relevant associated sections in the serial array
- Carnegie stage 22 D6-E5

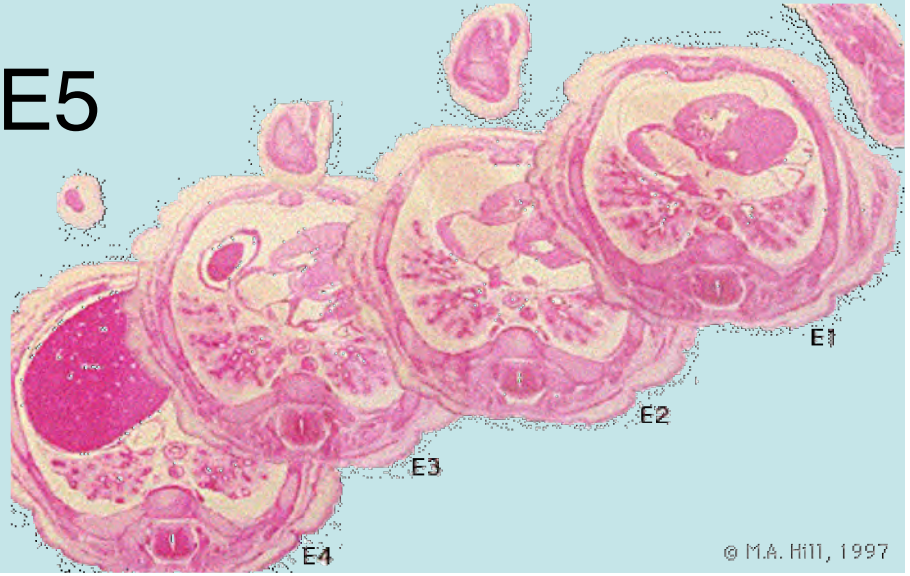

D6

D7

E1

E2

E3

E4

E5

Understanding Systems

- A series of images developed to enhance the understanding of individual organ systems
- For example
  - Cardiovascular
  - Gastrointestinal
  - Cs 22 F5, 6, 7

Cs 22 F5

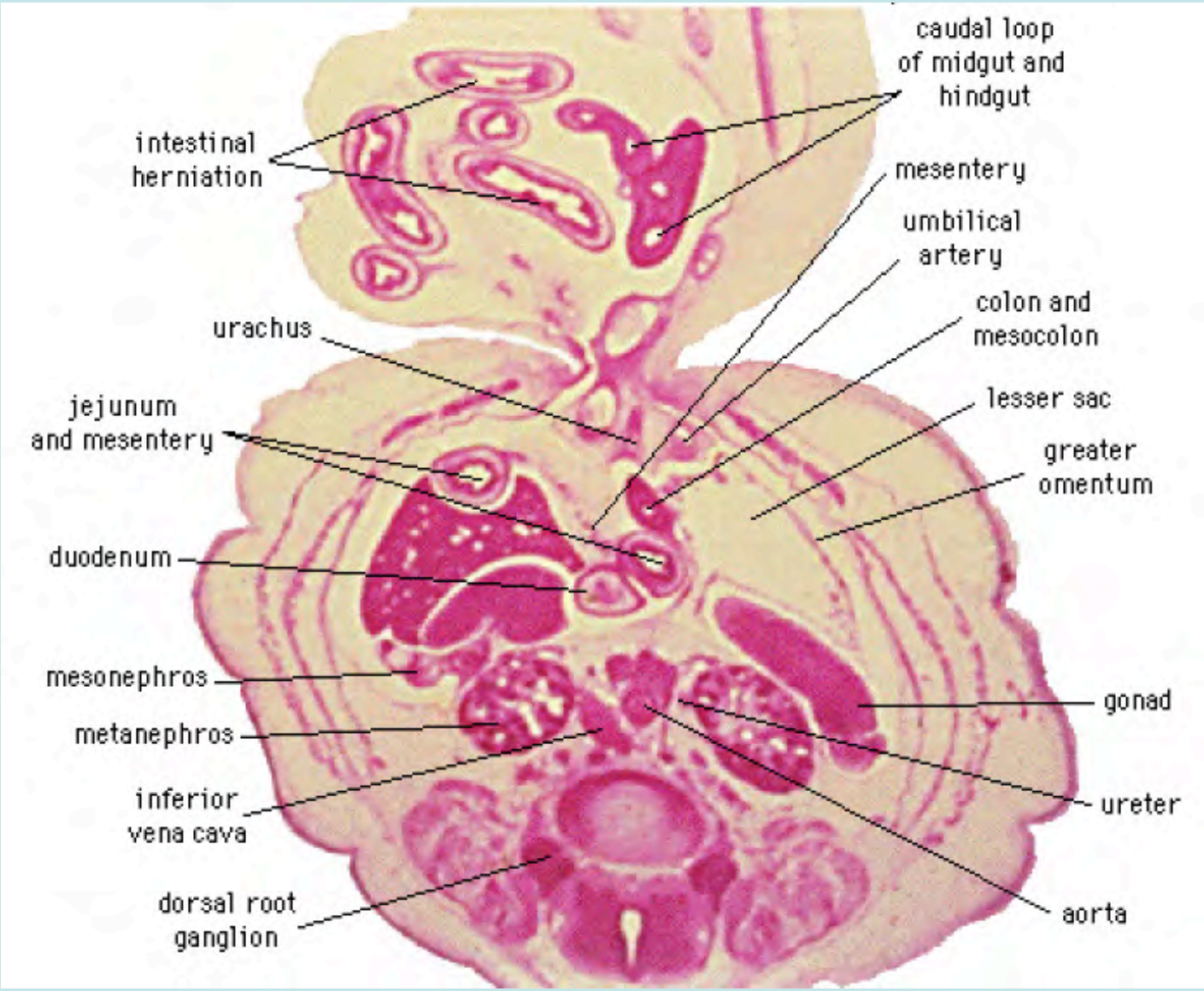
caudal loop
of midgut and
hindgut
intestinal
herniation
mesentery
umbilical
artery
colon and
mesocolon
urachus
lesser sac
jejunum
and mesentery
greater
omentum
duodenum
mesonephros
gonad
metanephros
ureter
inferior
vena cava
dorsal root
ganglion
aorta

Cs 22 F6

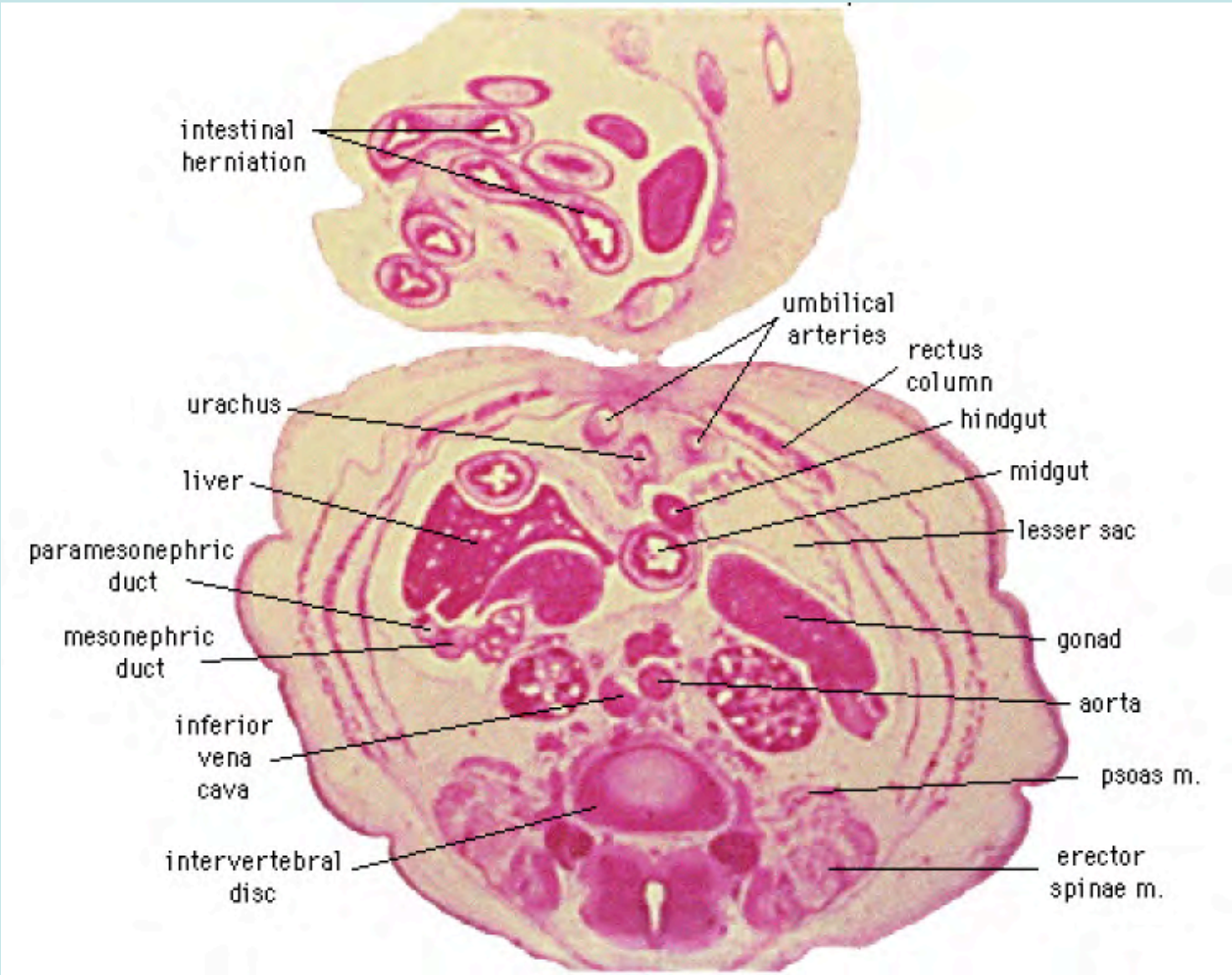
intestinal herniation
umbilical arteries
rectus column
urachus
hindgut
liver
midgut
lesser sac
paramesonephric duct
mesonephric duct
gonad
aorta
inferior vena cava
psoas m.
intervertebral disc
erector spinae m.

Cs 22 F7

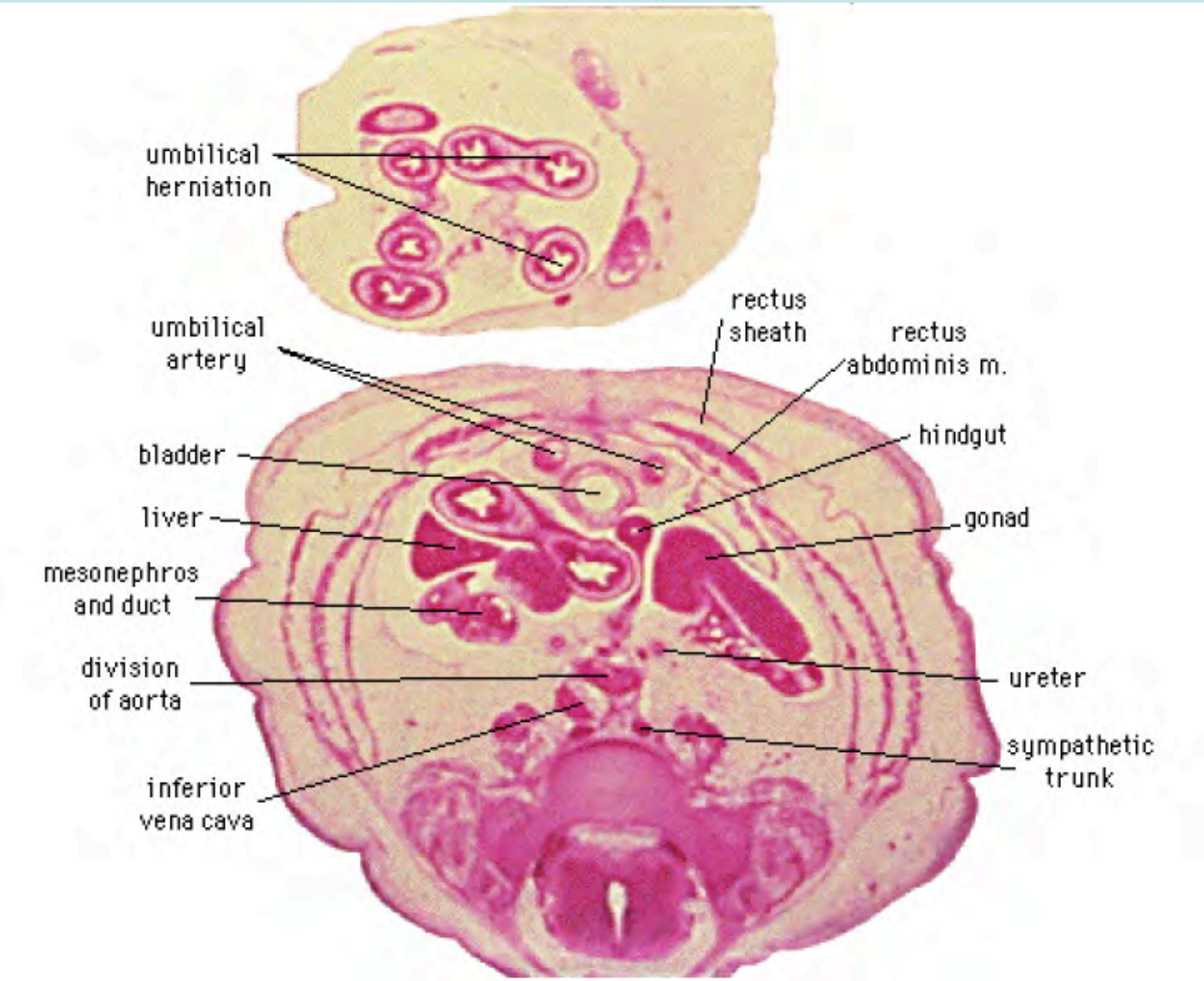
umbilical herniation
umbilical artery
rectus sheath
rectus abdominis m.
hindgut
bladder
liver
gonad
mesonephros and duct
division of aorta
ureter
sympathetic trunk
inferior vena cava

Additional 10 week Embryo

- Sagittal sections 40mm human fetus
  - 10 weeks
  - Set of whole embryo sections
  - Higher power sections of caudal region
    - Both labelled and unlabelled
- Aid to understanding relationships between the **GIT**, **Urinary**, **Endocrine** and **Reproductive** Systems



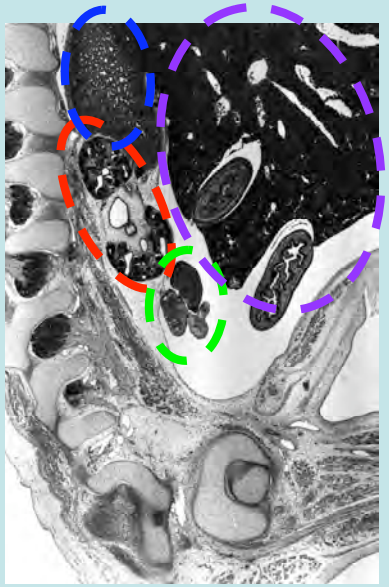

Sagittal D

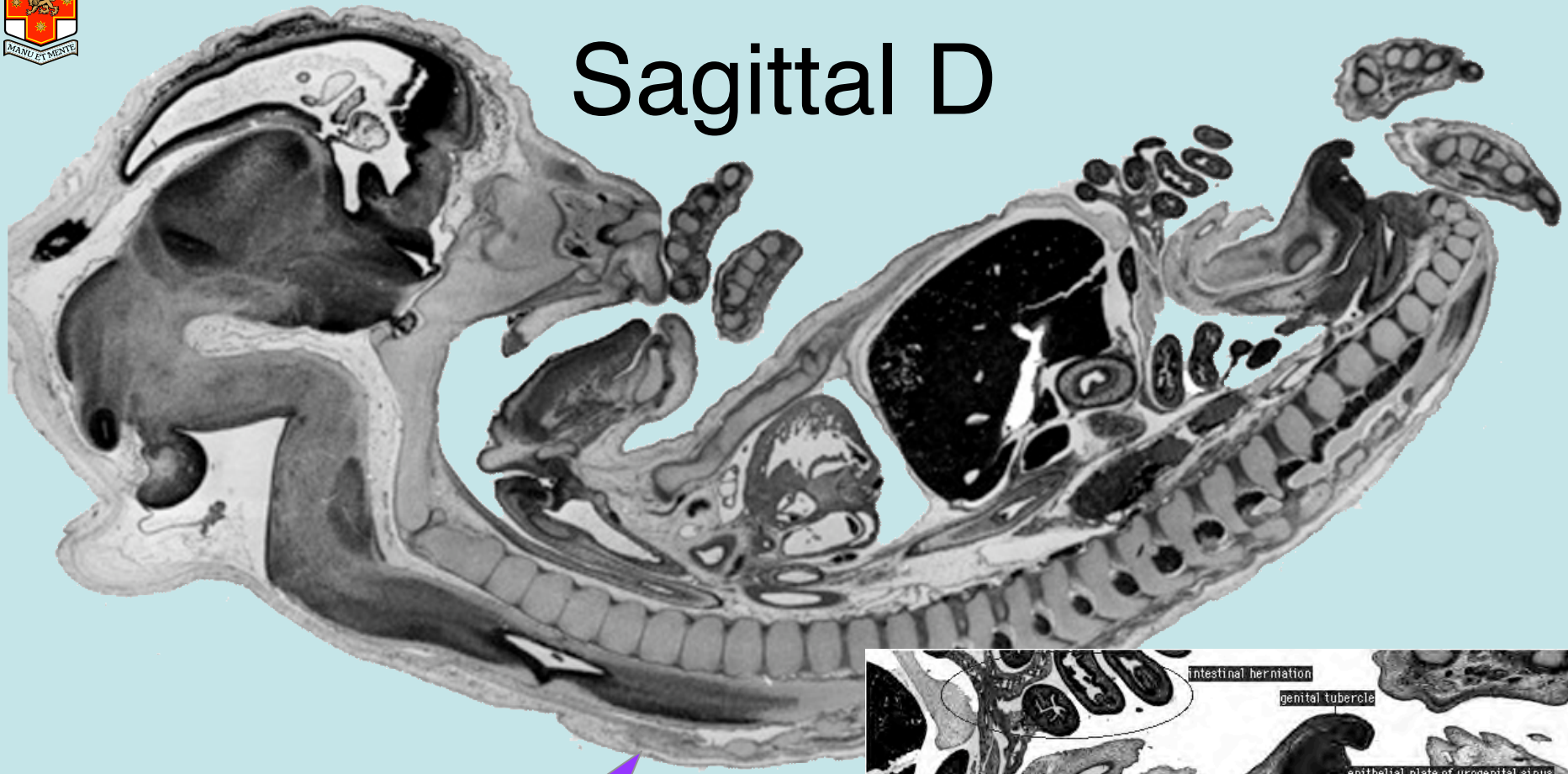

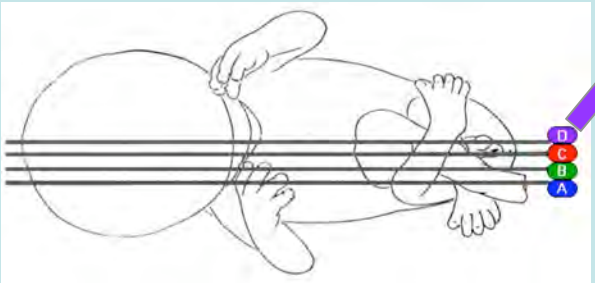
D
C
B
A

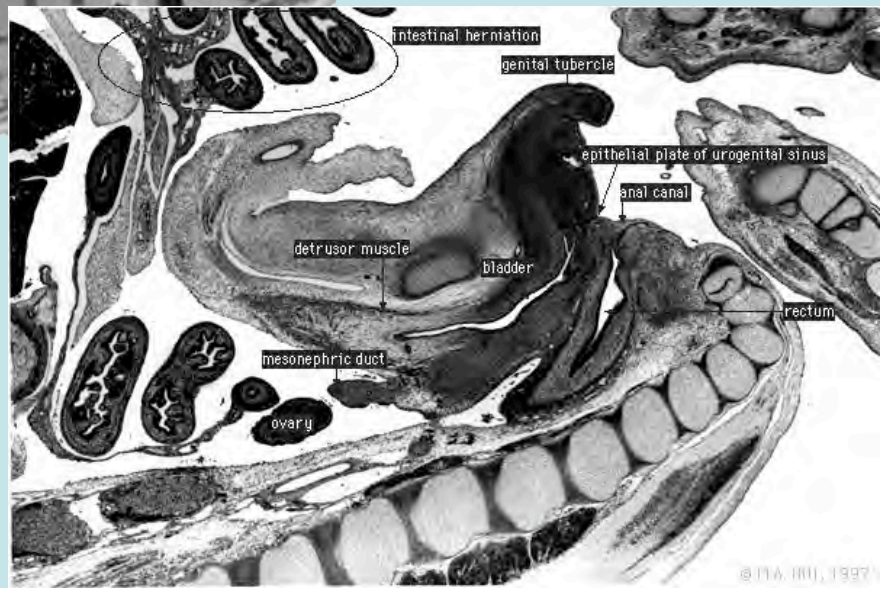
intestinal herniation
genital tubercle
epithelial plate of urogenital sinus
anal canal
detrusor muscle
bladder
rectum
mesonephric duct
ovary

Carnegie Stages

- Serial images from the Kyoto Collection of Human Embryos
  - Courtesy of Prof Kohei Shiota
- Animation combining the embryos into the developmental stages

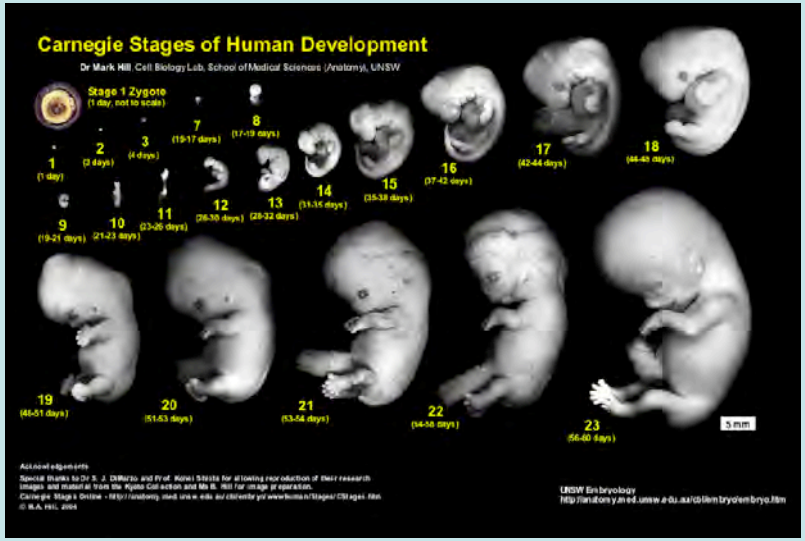

Kyoto Embryos

Stage 13

Stage 22

Current Project

- Integrated into a PC network
  - valuable educational tool for group teaching
- Additional
  - Notes, Movies, Abnormalities, News
  - Ultrasound, Molecular Dev
- Available online
  - http://embryology.med.unsw.edu.au/
- Available as a CD
  - from the Department of Anatomy, School of Medical Sciences, The University of New South Wales, Sydney 2052, NSW, Australia

Acknowledgments

- We would like to thank :
  - Charles Watson for original idea of microfiche cards
  - The late Istvan Tork for his intellectual input into the original program
  - To all the students and teaching staff who have made input and suggestions over the past 30 years particularly during the development of the computer aided programs
  - To Professor Kohei Shiota for allowing us to use the Kyoto Collection images

This presentation online at
http://embryology.med.unsw.edu.au/News/IFAA2004.htm

UNSW Embryology Online

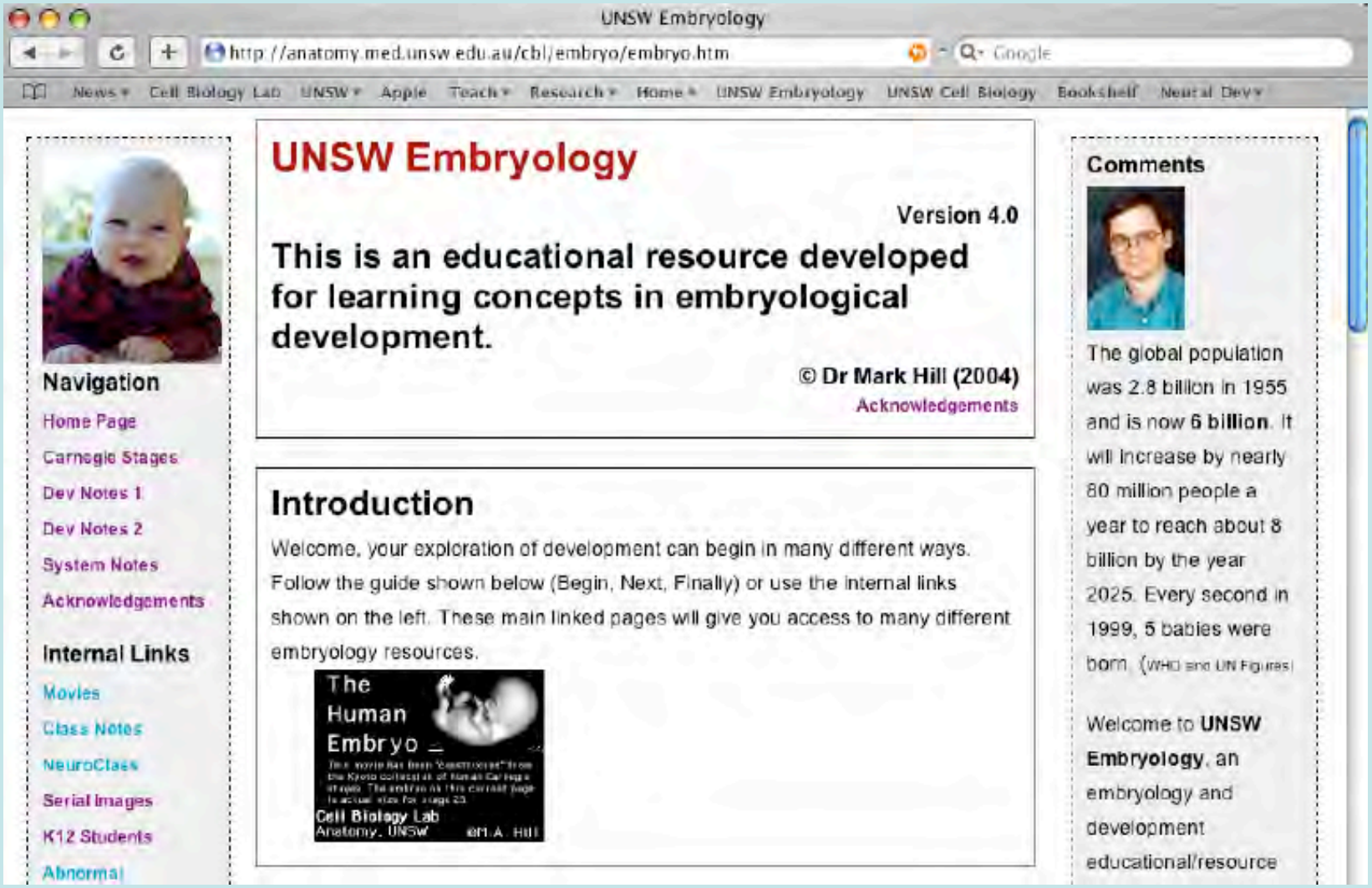

http://anatomy.med.unsw.edu.au/cbl/embryo

Carnegie Stages Poster